

## Alternative Methods for Reconstruction of Orbital Floor Defect other than Bone Graft

AMIR A. SAIDY, M.D.; MAURICE FEKRY, M.D. and SHERIF ABDEL RAHMAN, M.D.

*The Department of Plastic & Reconstructive Surgery, Mataria Teaching Hospital, Cairo*

### ABSTRACT

Orbital fractures are one of the most frequent consequences following midfacial trauma. If not treated they can lead to serious optical complications as; double vision (diplopia), restriction of ocular motility, enophthalmos. Autogenic bone graft although still wide and effectively used for reconstruction of fractured orbital wall present some disadvantages such as morbidity of donor site, resorption, time consuming procedure and long post-operative care. Because of that introduction of new materials for orbital reconstruction seems to be desirable.

### INTRODUCTION

The term orbital blowout fracture was first coined by Smith and Regan in 1957 [1] and categorized the pure form where the orbital floor is exclusively involved and the impure form of the injury when there was a concomitant fracture of the orbital rim [2]. The pathogenesis remains contentious as three distinct mechanisms of injury have been proposed: Increased intra-orbital hydraulic pressure, the buckling force theory [3] and the hypothesis of direct globe-to-wall contact [4,5].

Prevalence of pure orbital blowout fractures ranged from 2.8% in one study [6] to 21.4% in another [7] where orbital floor fractures were the second most common facial injury.

Recognized sequelae of orbital floor blowout fractures include enophthalmos, diplopia from extraocular muscle dysfunction, orbital dystopia and infraorbital paresthesia [8,9]. Special attention has to be paid to the posterior third of the orbit and the bony optic canal. Bony dislocations in these anatomical areas are more likely to be associated with traumatic optic nerve lesions.

A biomaterial is broadly defined as a natural or synthetic substance that is suitable to be incorporated into a living tissue particularly to aid healing, correct deformities and restore lost function [10].

A perfect biomaterial would be chemically inert, non-allergenic and non-carcinogenic. It should also be cost effective to place, readily available and sterilizable, easy to handle, has the ability to be stable and retain its shape once manipulated. Preferably, it thought to be radiopaque to enable radiographic evaluation but without producing artifacts which may mask important features on subsequent radiological examination [11-13].

Polypropylene is one of the most inert biomaterials used in surgery, and is available as a woven mesh (i.e., Marlex, Prolene). It is easy to suture, has good tensile strength, and demonstrates early fibrous tissue ingrowth that serves to fix and incorporate the mesh.

Titanium is the most recently developed alloy. It is available as pure titanium, as well as a stronger alloy of titanium in combination with aluminum and vanadium. In the unalloyed form, titanium is more malleable than stainless steel or Vitallium, which facilitates easy and precise molding to fit the contours of the facial skeleton.

The purpose of this series was to assess the aesthetic and functional outcome of the orbital floor reconstruction performed with prolene mesh and that with titanium mesh.

### MATERIAL AND METHODS

Ten cases of orbital blow out fractures treated at Plastic Surgery Department Mataria Teaching Hospital from April 2013 till January 2015 were considered in this study.

Clinical examination, patient satisfaction and radiological investigations were used (Fig. 1).

Five cases out of ten reconstructed by titanium mesh while the remaining five cases was reconstructed by prolene mesh.

Periorbital approaches are required for exposure of the medial orbital wall, lateral orbital wall, and orbital floor.

Reconstruction of the orbital floor has to respect the course of the infraorbital nerve in the orbital floor.

The forced duction test performed to determine ocular motility as soon as general anesthesia is induced.

As soon as the periorbita has been dissected another forced duction test performed to determine ocular motility.

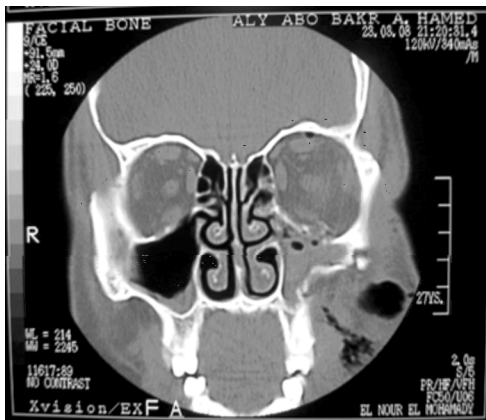


Fig. (1A): Orbital floor defect less than 1cm.

When using the fan-shaped plate, the outer circumference of the mesh is widest in the area of the infraorbital rim. The mesh should be trimmed so that the outer circumference is as small as possible but still provides enough width to cover the defect.

Care has to be taken that neither orbital fat nor muscles are entrapped.

If fixation is required, one screw will suffice in most cases. The screw can be placed into the floor of the orbit just posterior to the infraorbital rim.

In case of prolene mesh 3 prolene sutures 4-0 fixed to periosteum of the infraorbital rim usually enough to fix the mesh in place.

## RESULTS

Prolene mesh was used in five cases, titanium mesh was used in five cases. Nine patients had significant improvement in their esthetic appearance. Symmetry was restored in all cases. All ten cases had a noticeable improvement in the function.

After the insertion of any implant material, forced duction test to assure that the implant does not decrease the ocular motility.

A careful assessment of the defect size should be performed pre-operatively with the CT scan in the sagittal view which is in the course of the orbital nerve, plus the coronal view showing the transverse extent.

It is crucial that in case of combined fracture types (e.g, displaced zygoma fracture) the final defect size is only measured after proper repositioning of the outer frame. The defect size can be measured by the reading on the orbital retractor or any other instrument.



Fig. (1B): Orbital floor defect more than 1cm.

Six cases out of ten had diplopia pre-operatively, three recovered completely during the six months after the surgery. Three cases showed improvement later. All ten cases with enophthalmos recovered completely after surgery. Nine patients with infraorbital numbness, all recovered completely during the six months following surgery.

Nonpreformed titanium mesh were used in 5 patients for orbital floor repair.

One patient did not state follow-up period but there was improvement in the outcome measures of diplopia and enophthalmos in this patient.

In this study titanium mesh found to have good availability, stability, contouring, adequate in large three-wall fractures, radiopacity, spaces within the mesh to allow dissipation of fluids and no donor site needed, so titanium mesh found to have excellent results with defects more than 1cm.

The titanium was found to be expensive and possible sharp edges if not properly trimmed which may limit the ocular motility (Fig. 2).




Fig. (2): Orbital floor defects reconstructed by titanium mesh.

The prolene mesh found to have good availability, contouring, smooth edges and allows tissue ingrowth. While the disadvantages were, not radio-paque (not visible on post-operative images), lack

of rigidity when a very thin mesh is used and less drainage from the orbit than with titanium mesh, so prolene mesh found to be used in small defects 1cm<sup>2</sup> or less with better results (Fig. 3).




Fig. (3): Orbital floor defect reconstructed by prolene mesh.

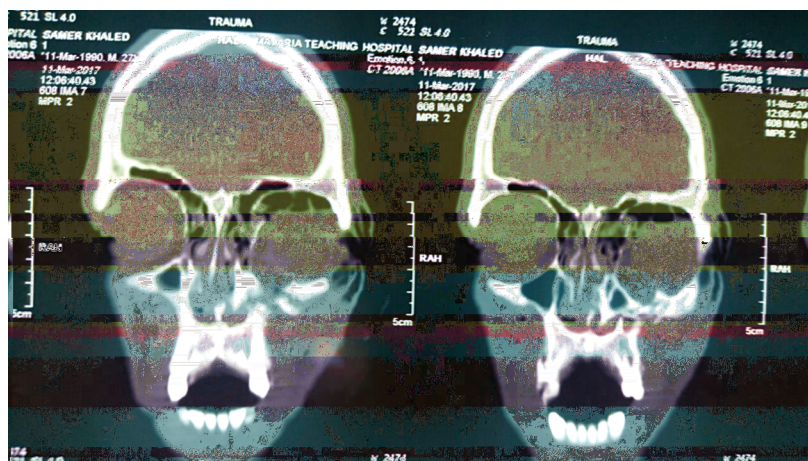


Fig. (4A): Orbital floor defect more than 1cm.

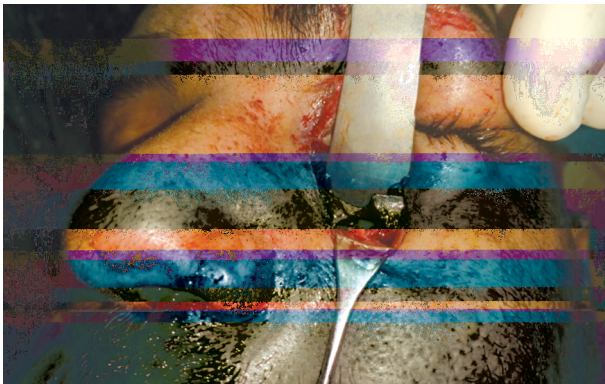

Fig. (4B): Orbital floor defect more than 1cm.




Fig. (4C): Titanium mesh.




Fig. (4D): Orbital floor defect more than 1cm reconstructed by miniplate, screws and Titanium mesh.

## DISCUSSION

The study recommend that polypropylene (prolen) meshes can be used for bone defects smaller than  $1\text{cm}^2$  for their pliability and their ability to deflect the weight of the orbit content when even up to three layers are overlapped [16-21]. It has been employed to reconstruct part of the orbit in cases where bone matter has been lost [22]. From the success obtained in other anatomical loci and with different functions [17-20], its utilization in reconstructing orbit bones is promising. The use of polypropylene mesh to rebuild orbits in the case of blow-out fractures has been reported in the literature [14,15,22,23].

Titanium is highly biocompatible, has a low infection rate with minimal resorption potential and well recognized osseointegration [25-28].

Large defects in the internal orbit have been reconstructed with titanium mesh with positive results as they are rigid enough to support the orbital contents, allowing better adaptation to individual anatomy [29-32].

No significant differences in orbital volume restoration were noted using either technique [24]. The authors concluded that both techniques were successful and allowed for close reproduction of the natural orbital volume and shape; reduction of Binocular Single Vision (BSV) loss area, correction of primary globe position and a significant improvement in upgaz [33].

Titanium mesh had its drawbacks such as the risk of graft extrusion or anticipated difficulty of removing these materials if needed because of the fibrous ingrowth and the possibility of osseous overgrowth but none of the studies reviewed reported about these incidences. Titanium mesh is well suited for orbital floor defects more than  $1\text{cm}^2$  [24].

## Conclusion:

Prolene mesh is recommended for small, linear defects measuring less than  $1\text{cm}^2$  with enophthalmos and restricted ocular movements, while in larger defects and impure blowout fractures involving the infraorbital rim, titanium mesh is recommended, the outcome of surgery with both materials was satisfactory. No post-operative complications were seen, titanium mesh, prolene mesh, has the potential to be useful reconstructive materials in orbital floor blowout fractures according to the defect size.

## REFERENCES

- 1- Smith B. and Regan Jr. W.F.: Blow-out fracture of the orbit: Mechanism and correction of internal orbital fracture. *Am. J. Ophthalmol.*, 44: 733, 1957.
- 2- Smith B. and Converse J.M.: Early treatment of orbital floor fractures. *Trans. Am. Acad. Ophthalmol. Otolaryngol.*, 61: 602, 1957.
- 3- Fujino T.: Experimental blowout fracture of the orbit. *Plast. Reconstr. Surg.*, 54: 81, 1974.
- 4- Pfeiffer R.L.: Traumatic enophthalmos. *Trans. Am. Ophthalmol. Soc.*, 41: 293, 1943.
- 5- Erling B.F., Iliff N., Robertson B. and Manson P.N.: Footprints of the globe: A practical look at the mechanism of orbital blowout fractures, with a revisit to the work of Raymond Pfeiffer. *Plast. Reconstr. Surg.*, 103: 1313, 1999.
- 6- Ellis E., El-Attar A. and Moos K.F.: An analysis of 2067 cases of zygomatico-orbital fracture. *J. Oral. Maxillofac. Surg.*, 43: 417, 1985.

