

Surgical Outcomes of Superior-Central Pedicle in Women with Huge Ptotic (Gigantic) Breasts

KHALED SADEK, M.D., M.R.C.S. and HATEM EL-SAHAR, M.D., M.R.C.S.

The Department of Plastic Surgery, Faculty of Medicine, Cairo University

ABSTRACT

Background: Gigantomastia is an annoying condition. It draws the attention of the cases and the surgeon because of its bad impacts of the whole life of the patients. Our aim of the study was to explore the superior-central pedicle technique as a reliable procedure for reduction mammoplasty for patients with severe gigantomastia with a sternal notch to nipple distance over 40cm.

Methods: The study was conducted in the Plastic Surgery Department, Cairo University Hospital, during the period from January 2012 to October 2016. We recruited females between 21 to 50 years presenting with gigantic breast (the sternal notch to nipple distance >40cm). All patients were evaluated by detailed history, careful physical examination and photographed pre and postoperative. All cases underwent superior central pedicle reduction mammoplasty. After surgery, all cases were followed-up for two years.

Results: Thirty subjects were included in the analysis of this study. The mean age of presentation was 32.47. The mean BMI was 32.68. Nine cases have positive family history while three were not married. The mean duration of the operation was 329 minutes.

Statistically, there was a significant ($p < 0.001$) reduction in the sternal notch to nipple distance post-operative than that measured pre-operatively both the left and right side. The weight of the resected tissue ranged from 1248 gram to 1657 gram with an average of 1440 gram.

The mean patients' satisfaction was 4.03 (0.85) with a minimum of 2.00 and a maximum of 5.00 where five means very high satisfaction and one means not satisfied at all.

No complications detected in 16 cases (53.3%), seroma in 3 (10.0%), hematoma in 2 (6.7%), infected horizontal wound (lateral or medial) in 2 (6.7%), infected T junction (lower or upper) in 2 (6.7%), infected vertical wound in 1 (3.3%), infected upper T junction and wound dehiscence in 1 (3.3%), wound dehiscence in lower T junction in 1 (3.3%), hypertrophic scar in 1 (3.3%) and numbness in 1 case (3.3%).

Conclusion: Finally, we conclude that the superior central pedicle technique may be a reliable option for gigantomastia. A further large-sample study is recommended to allow a real evidence and quantification of the success of this operation.

Key Words: Gigantomastia – SCP – Ptotic breasts.

INTRODUCTION

The primary goals of reduction mammoplasty, which is one of the most frequently performed operations in plastic surgery, are volume reduction of the large breasts with an ideal outcome of stable aesthetic shape, preserved sensation of the areolar complex, aesthetically acceptable scar and minimal complications [1].

Different types of techniques have been developed to achieve the goals mentioned above [2-6]. Different pedicle techniques have been designed and named according to the site as superior, inferior, medial, lateral central/posterior, or combinations of them. The decision which of them is suitable; is based upon the degree of macromastia, breast ptosis and preference or expertise of the surgeon [7-11].

The central pedicle technique for reduction mammoplasty was described for the first time by Balch and then by Hester [12,13]. The design of the central pedicle technique incorporates vascular contributions from different arteries through the pectoralis major muscle. These arteries are the lateral thoracic artery, the thoracoacromial artery, the intercostal perforators or the internal mammary perforators [13].

According to the blood and nerve supply to the NAC and breast parenchymal, central pedicle was practiced by many authors in breast reduction with a good cosmetic result and low complication rate [1].

Since the first description of central pedicle technique, it has undergone several modifications by Grant et al., and Datta et al., [1,14,15].

The central pedicle technique obtains the maximal blood supply chiefly through the pectoralis major muscle. It is a superior pedicle to avoid all

the inadequate perfusion of the remaining tissue. Due to this reason, it obtained a good result with little complications. There are few recognized postoperative complications noted when utilizing this technique primarily because of the degree of hypertrophy such as slight wound dehiscence, hematoma or seroma. There was no NAC necrosis reported. However, some reduction of the nipple sensation may occur temporarily [1].

The superiorly based dermal flap technique described elsewhere [16] was unreliable alone for long pedicles, resulting in compromised nipple viability and sensation [17,18]. It was designed to avoid the delayed late loss of projection while allowing the transposition of the NAC easily. However, its length was limited, and neurovascular compromise could occur with larger pedicles [17-20].

Thus, the rationale intended for this study was to explore the combined superior-central pedicle technique as a reliable procedure for patients with severe gigantomastia with a sternal notch to nipple distance over 40cm.

PATIENTS AND METHODS

The study was conducted during the period from February 2012 to October 2016. The purpose of this study was clearly explained in the Arabic language to all subjects before their enrollment to the study, and an informed consent form was signed by and obtained from all of those enrolled.

We recruited females between 21 to 50 years presenting with gigantic breast (the sternal notch to nipple distance >40cm). Exclusion criteria included: American Society of Anesthesia score 3 or 4 (high risk for anesthesia), patients with cancer breast, diabetes mellitus, and collagen vascular diseases, smokers, BMI more than 35, patients on anticoagulants and patients with bleeding tendencies.

Pre-operative patient assessment:

All patients were evaluated by detailed history, careful physical examination and photographed pre and post-operative.

History included: Age of the patient, onset of the problem, laterality, presence or absence of masses, presence or absence of nipple discharge or axillary lymphadenopathy. Besides, history of thyroid problems, liver disease, and renal disease, hypothalamic or pituitary disorders, recent drug intake, family history of breast cancer; or family history of the same condition. Obstetric and gynecological

history was taken in details, including the menarche age, menstrual cycle, pregnancies, any obstetric or gynecological events, menopause in females above 45 years old.

Adequate physical examination with stress on the following points was done: The general examination includes signs of renal failure or liver disease. Also, a local examination was done to exclude any sign of breast cancer as a solid breast mass, nipple discharge or suspicious axillary lymphadenopathy. Gigantic breast is defined by the sternal notch to nipple distance more than 40cm. Patients with underlying fungal infections were instructed to treat it and come back again after eliminating the infection.

We explained to the patient about the incision, the scars, the idea of the operation, discussion with her to know her expectations, telling the patient about the possibility to sensory and lactation affection.

Laboratory investigations:

Blood samples were taken from patients as routine preoperative preparation for complete blood picture, coagulation profile and liver and kidney functions, random blood sugar. Mammography and breast ultrasound were done routinely pre-operatively. Photos are taken pre-operative and post-operative in three views: Anteroposterior, right lateral and left lateral. Informed consent was taken from all patients.

Technique:

The night before surgery, the patient was instructed to take a shower and start fasting for 8 hours before the time of surgery. In the hospital, after taking the consent, while standing, the patient was instructed to expose her upper half of the body till umbilicus where we began by taking pre-operative photos. Then, we began to draw the essential lines, the midline, and the anterior axillary line, then starting to draw the line of mid breast plane, identifying the infra-mammary fold, then the new NAC position, positioned between 19-22cm, preferably put in the same level of the mid arm. The infra-mammary fold is about four fingers away from the lower border of the NAC. We then go for the wise pattern technique where we identify the area around the NAC to be de-epithelialized, the medial and lateral pillars and the inferior portion. After that, we drew the pedicle and checked that both sides have the same measures and were identical.

The operation started by general anesthesia, and antibiotic IV was administered. A urinary catheter was put. Then we began by de-epithelialization of the superior pedicle till below the NAC by two cm, then starting cutting the lateral and medial pillars, the horizontal incision was made where dissection from the inferior to the superior aspect, deepening into the pillars till reaching the pectoral fascia, and superiorly till the breast septum. Lateral total evacuation of the breast tissue and fat, while medial subtotal evacuation to preserve some breast tissue for aesthetic medial fullness. Good meticulous hemostasis was achieved. Semi-sitting position in 30 degrees was done. The mobilization of the pedicle with the NAC to its new site then closure of the skin of the vertical incision and the horizontal incision in 3 layers without any drains was made. Deep 2/0 Vicryl followed by superficial 3/0 Vicryl and finally subcuticular Monocryl 3/0. For the areola, two layers only where monocryl 3/0 was used to fixate the areola deeply followed superficially by monocryl 0 double barrel suture. Steri-strips application followed by a dressing of the wound. The patient wears a compressive bra garment with particular attention to more compression on the lateral aspect to exclude hematoma and seroma formation. The patient took postoperative one dose of IV antibiotic, 1500cc IV fluids. Discharged on the second day with prescription included an oral antibiotic, an analgesic, and an anti-inflammatory. The first visit would be on the 5th postoperative day to check for wounds, the viability of NAC and removal of the lateral compression, but still, the compressive bra garment was used till six weeks post-operative. The removal of the stitches occurred in the third week. Application of silicone creams for the wounds followed by one week.

Outcome measures:

The primary outcome measure was to assess the success of superior central pedicle technique in Women with Gigantic Breast. The secondary outcome measures were to quantify the short-term and long-term complications and patient's satisfaction with the operation.

Statistical analysis:

All statistical tests were done using a significance level of 95%. A value of $p < 0.05$ was considered statistically significant. SPSS software (Statistical Package for the Social Sciences, Version 20.0, SSPS Inc., Chicago, IL, USA) was used for the statistical analyses. Data were presented as (mean \pm SD) or median (range) for continuous

variables and as a frequency for categorical variables. Comparisons were made using the paired t -test for continuous variables.

RESULTS

All subjects with severe gigantomastia (sternal notch to nipple distance more than 40cm) and aged from 21 to 50. Operations were done between January 2012 and October 2014 with a 2 years follow-up to assess the long-term result of this pedicle.

Baseline characteristics and operative procedures:

Thirty subjects were included in the analysis of this study. The mean age of presentation was 32.47 (4.18) years with a range from 21 to 50 years old. The mean BMI was 32.68 (1.34) years with a range from 29.9 to 34.8. Nine cases (30%) have positive family history of gigantomastia. Twenty-seven cases (90%) were married with 5 cases primigravida, 10 cases gravida 2, 9 cases gravida 3 and 3 cases were gravida 4, as shown in (Table 1). The mean duration of the operation was 329 (45.93) minutes with a minimum of 285 and a maximum of 495 minutes.

Post-operative sternal notch to nipple distance and patients' satisfaction:

Statistically, there was a significant ($p < 0.001$) reduction in the sternal notch to nipple distance post-operative than that measured pre-operatively both the left and right side. The mean pre-operative sternal notch to nipple distance was 41.84 (1.52) cm for the right side and 42.02 (1.7) cm for the left side. However, the mean post-operative sternal notch to nipple distance was 22.61 (1.15) cm for the right side and 22.71 (1.21) cm for the left side. The weight of the resected tissue ranged from 1248 gram to 1657 gram with an average of 1440 (234) gram.

Patients were asked about overall satisfaction, particularly satisfaction with shape, reduction degree, scar length and visibility, nipple sensation, ease of performing work or usual activities, and improvement in back and shoulder pain after the operation. The mean patients' satisfaction was 4.03 (0.85) with a minimum of 2.00 and a maximum of 5.00 where five means very high satisfaction and one means not satisfied at all.

The most concerns of patients were about the global shape of the breast, the preservation of the lactation, the sensation and the position of the NAC. Lactation was observed only in 4 (out of 7)

cases that got pregnant after the operation during a follow-up period ranging from 6 to 17 months.

Surgeon's observations were the same as those of patients, plus the globular shape (upper fullness the breast), the position of NAC regarding the sternal notch to nipple distance, the direction of the projection of nipple, the healing and scarring of the wound.

Post-operative complications and nipple areola complex status:

Nipple Areola Complex (NAC) was viable in thirteen cases (43.4%), infected on one side in 3 cases (10.0%), sloughed (one side) in 3 (10.0%), superficial epidermolysis (one side) in 3 (10.0%), wound dehiscence in 1 (3.3%), partial loss on left side in 1 (3.3%) and not viable in 6 cases (20.0%).

No complications detected in 16 cases (53.3%), seroma in 3 (10.0%), hematoma in 2 (6.7%), infected horizontal wound (lateral or medial) in 2

(6.7%), infected T junction (lower or upper) in 2 (6.7%), infected vertical wound in 1 (3.3%), infected upper T junction and wound dehiscence in 1 (3.3%), wound dehiscence in lower T junction in 1 (3.3%), hypertrophic scar in 1 (3.3%) and numbness in 1 case (3.3%).

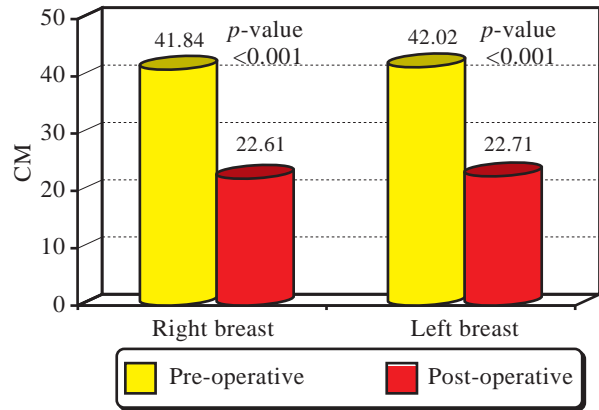


Fig. (1): Sternal notch to nipple distance before and after the operation.

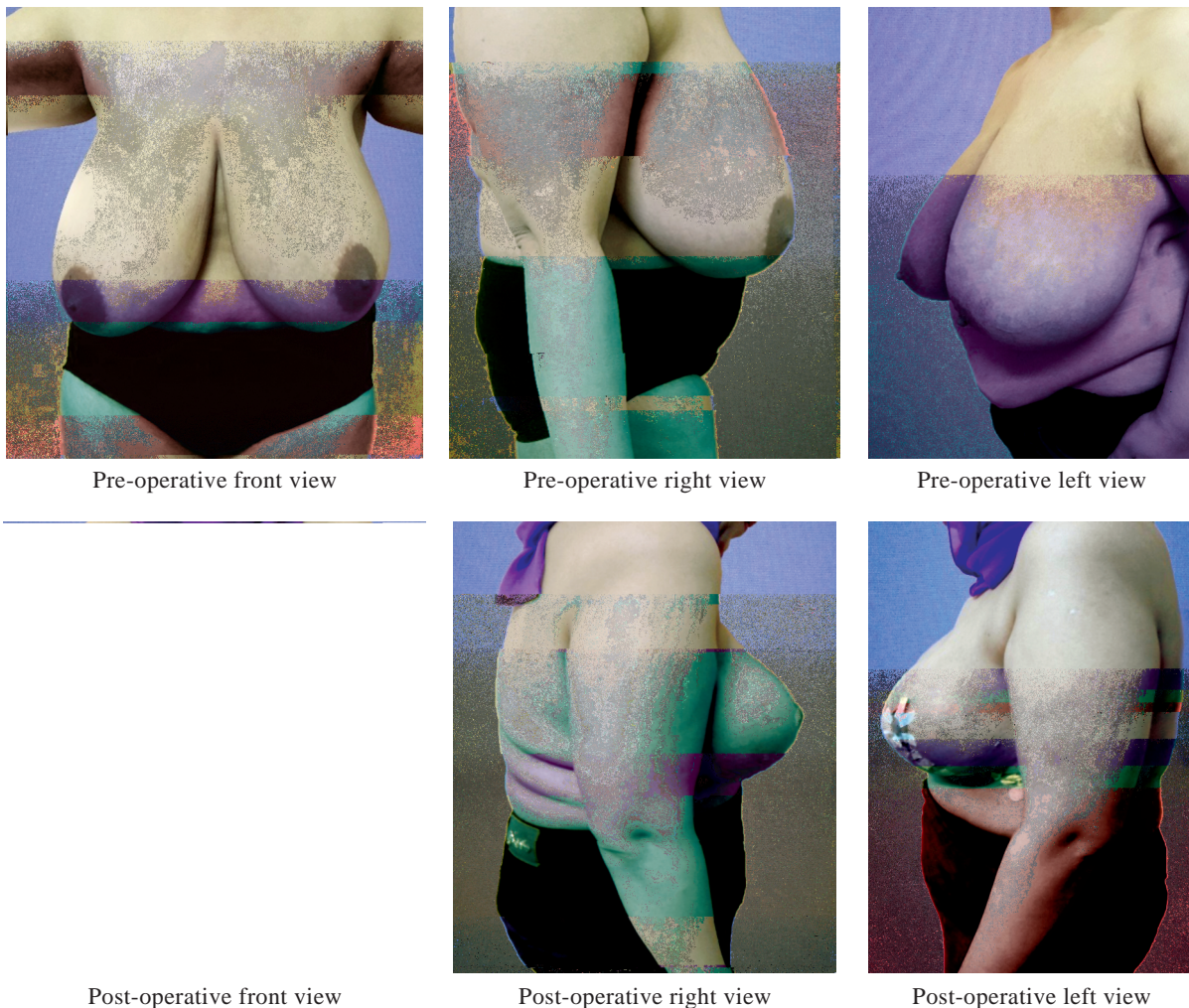
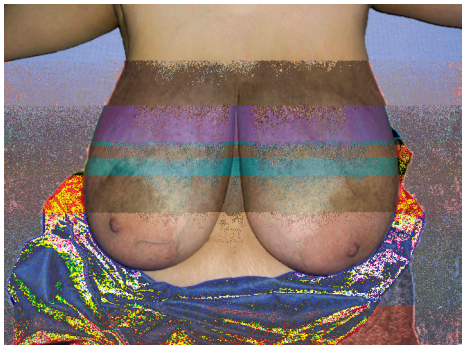

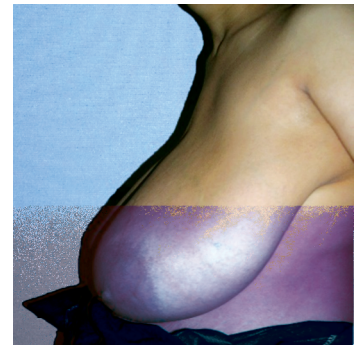Fig. (2): A case with huge ptotic breast with early follow-up, steri strips applied and NO drain was put.



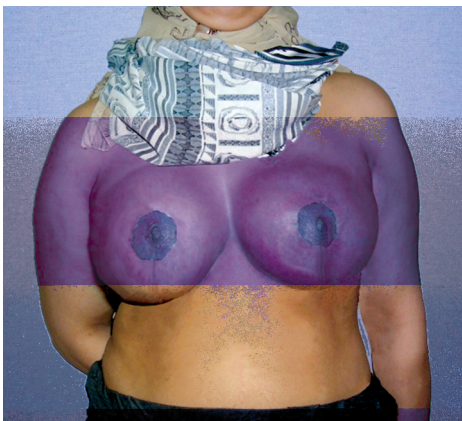Pre-operative front view



Pre-operative right view



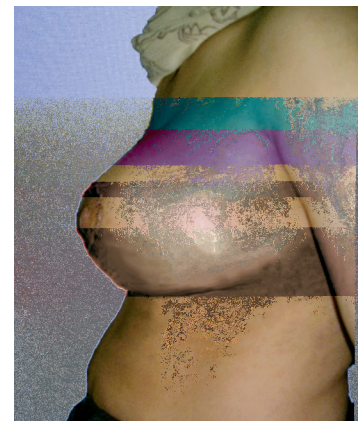
Pre-operative left view



Post-operative front view

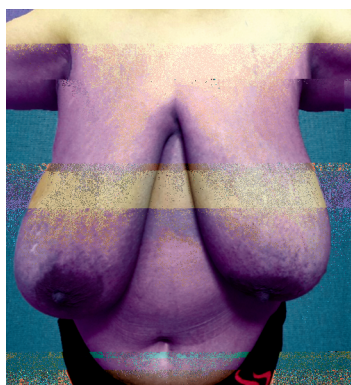


Post-operative right view

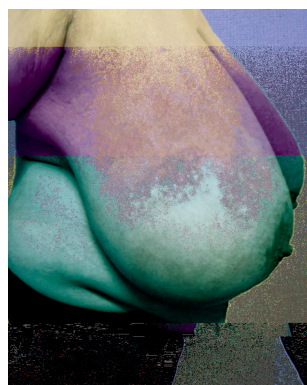

Post-operative left view

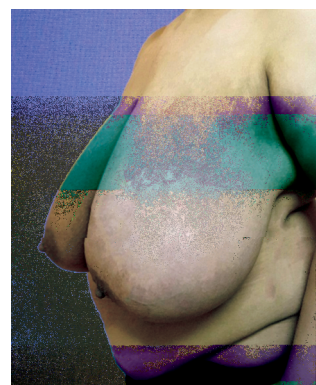Fig. (3): A case after 2 years post-operative.



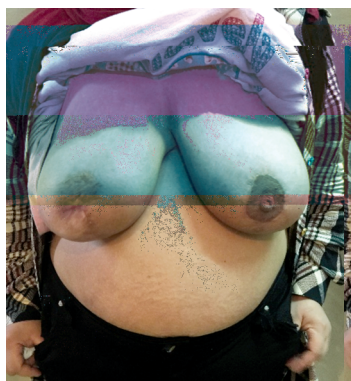Pre-operative front view



Pre-operative right view



Pre-operative left view



Post-operative front view



Post-operative right view



Post-operative left view

Fig. (4): A case with right nipple epidermolysis after 2 years post-operative.

Table (1): Patients' demographics and baseline characteristics.

	Mean (SD)	(Min-max)
• Age, years	32.47 (4.18)	(21-50)
• BMI	32.68 (1.34)	(29.9-34.8)
• Duration of operation, min	329 (45.93)	(285-495)
• Family history, positive family history, n (%)	9 (30%)	
• Marital status, married, n (%)	27 (90%)	
• Previous pregnancy, n (%):		
Virgin	3 (10%)	
Gravida 1	5 (17%)	
Gravida 2	10 (33%)	
Gravida 3	9 (30%)	
Gravida 4	3 (10%)	

Table (2): Sternal notch to nipple distance.

	Pre-operative		Post-operative		p-value
	Mean (SD)	(Min-max)	Mean (SD)	(Min-max)	
Right	41.84 (1.52)	(40.1-46.1)	22.61 (1.15)	(20.6-24.5)	<0.001
Left	42.02 (1.7)	(40.5-46.9)	22.71 (1.21)	(20.6-24.8)	<0.001

Table (3): Post-operative complications and nipple areola complex status.

	Number (%)
<i>Nipple Areola Complex (NAC):</i>	
Viable	13 (43.4%)
Infection (one side)	3 (10.0%)
Sloughed (one side)	3 (10.0%)
Superficial epidermolysis (one side)	3 (10.0%)
Wound dehiscence	1 (3.3%)
Partial loss on left side	1 (3.3%)
Not viable	6 (20.0%)
<i>Post-operative complications:</i>	
No complications	16 (53.3%)
Seroma	3 (10.0%)
Hematoma	2 (6.7%)
Infected horizontal wound (lateral or medial)	2 (6.7%)
Infected T junction (lower or upper)	2 (6.7%)
Infected vertical wound	1 (3.3%)
Infected upper T junction and wound dehiscence	1 (3.3%)
Wound dehiscence in lower T junction	1 (3.3%)
Hypertrophic scar	1 (3.3%)
Numbness	1 (3.3%)

DISCUSSION

Gigantomastia which is an excessive breast growth is an uncommon condition that can make psychological and physical disability to the woman. Despite its rarity, up till now, there is no universally accepted definition for this condition. Several authors define it as enlargement of the breast by over 1500g per one breast. Others described it as breast weight greater than 3% of the total body weight. On the other hand, there is an apparent discordance in the medical literature regarding the exact weight of the breast tissue yield by the reduction. However, it ranges from 800 to 2000gm. Moreover, this is a postoperative definition that is not practically useful regarding management [21,22].

In our study, we used a sternal notch to nipple distance more than 40cm as an objective measurement for defining gigantomastia where the breast is still full causing dragging sensation to the patient and sometime neck pains were met, the bra strap has left a skin mark on her chest and shoulder. In operation, the most appropriate location regaining the aesthetic shape of the breasts is the site at which both nipples be placed at the basal angles of an imaginary equilateral triangle having the apex at the sternal notch and each side measuring 19-22cm Fig. (2) [23,24]. Mallucci et al., studied pictures of hundred topless women from the tabloid paper "The Sun." they concluded that for a breast to be perfect in shape it should have a ratio of 45:55 between the upper and lower pole [24].

However, the breast reduction patients present at different ages and breast sizes, thus, there is an inferior migration of the nipple with ptosis and some lateral deviation [25].

In most cases of gigantomastia, the etiology is idiopathic with normal hormone levels. However, during puberty or pregnancy, we can find a hormonal imbalance of estrogen or prolactin. Drug-induced gigantomastia is a rare entity of an unusual etiology [26-29].

The large volumes in gigantomastia are typically associated with the hollowness of the upper breast pole, axillary extensions, and ptosis. Thus, the blood vessels are stretched down, following the ptotic hypertrophic breast, but this vascular supply remains unmodified. The increased sternal notch to nipple distance raises the issue of the vascular safety of the NAC as a primary concern in many management [30].

The criteria for a breast reduction to be considered ideal as set forth by Biesenberger were the symmetry of the two breasts, the proportionality to other parts of the body, the appropriateness of NAC location without jeopardizing the blood supply, the preservation of the breast function, and minimal scars [31].

The method of reduction mammoplasty by amputation/free nipple graft is used less frequently than the various pedicled reduction methods. Some strong reservations about this technique are decreased nipple-areola sensation, decreased capacity of breastfeeding, nipple flattening, diminished erectile response of the nipple and nipple hypopigmentation. A suboptimal breast shape is another possible drawback. However, amputation and free nipple grafting offer improved safety compared

with pedicled reduction mammoplasty, particularly for patients at high anesthetic risk. Some of their indications include advanced age, gigantomastia, systemic disease with poor wound-healing or poor microcirculation. For the success of this method requires careful selection of patients. It is not a good choice for those young patients concerned with breastfeeding or nipple-areola sensation. Attention to the details of operative planning and execution can minimize the potential aesthetic liabilities of this technique. However, when properly used, this technique provides excellent patient safety and satisfaction [32].

Pedicled reduction mammoplasty using the different types of pedicles such as the inferior, the superior, the superomedial or the lateral pedicle models do not jeopardize the adequacy of the blood supply to the NAC in the case of mammoplasty in the normal-sized breast. However, in cases of gigantomastia, they might not include sufficient blood supply to the NAC [33].

Modifications of the superior pedicle or other pedicles potentially providing enhanced vascular impact might be considered with a suprasternal notch to nipple distance more than 30 to reduce vasculature-related complications of the NAC [34].

Therefore, to render this technique applicable to gigantomastia, we intended in our study to combine the superior pedicle technique with the central pedicle technique.

Gigantomastia with the largely ptotic breast under the inframammary fold makes all branches of the blood vessels to have a vertical direction. Hence, superomedial or superolateral pedicles are not needed. In this condition, the superior pedicle receives the blood supply from the internal mammary artery, the lateral thoracic artery, and the thoracoacromial artery. Nevertheless, the preservation of the perforators of the fourth and fifth anterior intercostal artery enhances the blood supply to the NAC and the breast parenchyma [2,3].

The superior pedicle could be plicated without difficulties. This was connected to the thinness of the pedicle distally and to dissect enough space at the superior pole, to which the breast will glide. In medially or laterally based pedicles, the pedicle is rather rotated than plicated, which can be an additional advantage but may cause torsion of the nipple-areola complex-bearing pedicle. The limited undermining between gland and skin decreases the risk of vascular compromise of the breast tissue [30].

The innervations of the nipple-areola complex are provided by the fourth intercostal nerve, which runs close to the anterior intercostal arterial supply [35]. As a result, the preservation of the perforators from the anterior intercostal arteries would spare the corresponding sensitive nerves in all types of breast reduction, thus respecting the sensitivity of the nipple-areola complex [3,36].

Some complications can occur after reduction mammoplasty. Bottoming out which is the gradual descent of breast parenchyma below the original location of the inframammary fold location with the result that the NAC appears to be displaced superiorly. The dog-ears is a lump of skin, usually at the beginning or end of a scar when sutured. Fat necrosis due to cell injury which results in premature death of fat cells due to inadequate blood supply. A hypertrophic scar is raised scar, often with a reddish color, that does not grow beyond the boundaries of the original wound. The keloid scar is raised scar formation that grows beyond the wound boundaries. Skin necrosis is due to cell injury that results in premature death of epithelium and dermal tissue due to inadequate blood supply. Tactile hyperesthesia which is the pain caused by a stimulus that not normally provoke pain. Seroma which is a collection of fluid that sometimes appears within the operated tissue after surgery. Finally, wound dehiscence can occur [37].

In this current study, we used a combination of superior and central pedicle technique for patients with a sternal notch to nipple distance beyond 40cm. This method prevented the occurrence of bottoming out, preserving the superior fullness, giving more projection to the breast and a reliable blood supply to the NAC. Nipple sensation and lactation was preserved to a great extent. We think that this technique of reduction mammoplasty showed success in those patients as evaluated by the surgeons and by the overall satisfaction of patients which makes the technique is a reliable option for those kinds of patients. However, further studying of the factors affecting the success of the operation is mandatory to select which patient is a candidate for this technique without complications.

Conclusion:

We can conclude that the superior central pedicle technique may be a reliable option for gigantomastia. A further large-sample study is recommended to allow a real evidence and quantification of the success of this operation.

Declaration of interest:

All authors declare that no conflict of interest could be perceived as prejudicing the impartiality of the research reported.

Funding:

This research did not receive any specific grant from any funding agency in the public, commercial or not-for-profit sector.

REFERENCES

- 1- See M.H.: Central pedicle reduction mammoplasty: A reliable technique. *Gland Surgery*, 3 (1): 51-54. Doi: 10.3978/j.issn.2227-684X.2014.02.09, 2014.
- 2- Ricbourg B.: Applied anatomy of the breast: Blood supply and innervation. *Ann. Chir. Plast. Esthet.*, 37: 603-20, 1992.
- 3- Würinger E., Mader N., Posch E., et al.: Nerve and vessel supplying ligamentous suspension of the mammary gland. *Plast. Reconstr. Surg.*, 101: 1486-93, 1998.
- 4- Würinger E.: Refinement of the central pedicle breast reduction by application of the ligamentous suspension. *Plast. Reconstr. Surg.*, 103: 1400-10, 1999.
- 5- Schlenz I., Rigel S., Schemper M., et al.: Alteration of nipple and areola sensitivity by reduction mammoplasty: A prospective comparison of five techniques. *Plast. Reconstr. Surg.*, 115: 743-51; discussion 752-4, 2005.
- 6- Cho B.C., Yang J.D. and Baik B.S.: Periareolar reduction mammoplasty using an inferior dermal pedicle or a central pedicle. *J. Plast. Reconstr. Aesthet. Surg.*, 61: 275-81, 2008.
- 7- Lista F. and Ahmad J.: Vertical scar reduction mammoplasty: A 15-year experience including a review of 250 consecutive cases. *Plast. Reconstr. Surg.*, 117: 2152-65; discussion 2166-9, 2006.
- 8- Courtiss E.H. and Goldwym R.M.: Reduction mammoplasty by the inferior pedicle technique. An alternative to free nipple and areola grafting for severe macromastia or extreme ptosis. *Plast. Reconstr. Surg.*, 59: 500-7, 1977.
- 9- Georgiade N.G., Serafin D., Morris R., et al.: Reduction mammoplasty utilizing an inferior pedicle nipple-areolar flap. *Ann. Plast. Surg.*, 3: 211-8, 1979.
- 10- Ribeiro L., Accorsi A. Jr., Buss A., et al.: Creation and evolution of 30 years of the inferior pedicle in reduction mammoplasties. *Plast. Reconstr. Surg.*, 110: 960-70, 2002.
- 11- Nahabedian M.Y., McGibbon B.M. and Manson P.N.: Medial pedicle reduction mammoplasty for severe mammary hypertrophy. *Plast. Reconstr. Surg.*, 105: 896-904, 2000.
- 12- Balch C.R.: The central mound technique for reduction mammoplasty. *Plast. Reconstr. Surg.*, 67: 305-11, 1981.
- 13- Hester T.R. Jr., Bostwick J. 3rd, Miller L., et al.: Breast reduction utilizing the maximally vascularized central breast pedicle. *Plast. Reconstr. Surg.*, 76: 890-900, 1985.
- 14- Grant J.H. 3rd and Rand R.P.: The maximally vascularized central pedicle breast reduction: Evolution of a technique. *Ann. Plast. Surg.*, 46: 584-9, 2011.
- 15- Datta G. and Carlucci S.: Selective breast reduction: A personal approach with a central-superior pedicle. *Plast. Reconstr. Surg.*, 123: 433-42, 2009.
- 16- Weiner D.L., Aiache A.E., Silver L., et al.: A single dermal pedicle for nipple transposition in subcutaneous mastectomy, reduction mammoplasty, or mastopexy. *Plast. Reconstr. Surg.*, 51: 115-20, 1973.
- 17- Georgiade N.G., Serafin D., Riefkohl R., et al.: Is there a reduction mammoplasty for "all seasons"? *Plast. Reconstr. Surg.*, 63: 765-73, 1979.
- 18- Bostwick J.I.I.I.: Breast reduction, in *Plastic and Reconstructive Breast Surgery*. St. Louis, MO, Quality Medical Publishing, Inc., 1990.
- 19- Hugo N.E. and McClellan R.M.: Reduction mammoplasty with a single superiorly based pedicle. *Plast. Reconstr. Surg.*, 63: 230-4, 1979.
- 20- Orlando J.C. and Guthrie R.H. Jr.: The superomedial pedicle for nipple transposition. *Br. J. Plast. Surg.*, 28: 42-5, 1975.
- 21- Dancy A.I., Khan M., Dawson J. and Peart F.: Gigantomastia-a classification and review of the literature. *J. Plast. Reconstr. Aesthet. Surg.*, 61 (5): 493-502, 2008.
- 22- Heine N., Eisenmann-Klein M. and Prantl L.: "Gigantomasty: Treatment with a Short Vertical Scar". *Aesthetic Plastic Surgery*, 32 (1): 41-7. Doi: 10.1007/s00266-007-9005-x. PMID 17874160, 2008.
- 23- Penn J.: Breast reduction. *Br. J. Plast. Surg.*, 7: 357-71, 1955.
- 24- Mallucci P. and Branford O.A.: Shapes, Proportions, and Variations in Breast Aesthetic Ideals: The Definition of Breast Beauty, Analysis, and Surgical Practice. *Clinics in Plastic Surgery*, 42: 451-64, 2015.
- 25- Brown T.P., Ringrose C., Hyland R.E., Cole A.A. and Brotherton T.M.: A method of assessing female breast morphometry and its clinical application. *Br. J. Plast. Surg.*, 52: 355-9, 1999.
- 26- Dancy A., Khan M., Dawson J. and Peart F.: Gigantomastia-a classification and review of the literature. *Journal of Plastic, Reconstructive & Aesthetic Surgery: J.P.R.A.S.*, 61: 493-502, 2008.
- 27- Rezai S., Nakagawa J.T., Tedesco J., et al.: Gestational Gigantomastia Complicating Pregnancy: A Case Report and Review of the Literature. *Case Reports in Obstetrics and Gynecology*, 892369, 2015.
- 28- Rohrich R.J., Thornton J.F. and Sorokin E.S.: Recurrent mammary hyperplasia: Current concepts. *Plastic and Reconstructive Surgery*, 111: 387-93; Quiz 394, 2003.
- 29- Kulkarni D., Beechey-Newman N., Hamed H. and Fentiman I.S.: Gigantomastia: A problem of local recurrence. *Breast*, 15: 100-2, 2006.
- 30- Ali Mojallal, Michel Moutran, Christo Shipkov, Michel Saint-Cyr, Rod J. Rohrich and Fabienne Braye: Breast Reduction in Gigantomastia Using the Posterosuperior Pedicle: An Alternative Technique, Based on Preservation of the Anterior Intercostal Artery Perforators. *Plastic and Reconstructive Surgery*, (125) 1: 32-43, 2010.
- 31- Biesenberger H.: Eine neue Methode der mammoplastik. *Zentralbl. Chir.*, 55: 2382, 1928.

- 32- Richard J. Restifo and Janice F. Lalikos: Amputation/free nipple graft reduction mammoplasty. *Operative Techniques in Plastic and Reconstructive Surgery*, 3 (3): 184-8, 1996.
- 33- Rodier-Bruant C., Wilk A., Rosenstiel M., Nisand G. and Meyer C.: Does the choice of mammoplasty pedicle influence the shape of the reduced-sized breast? (in French). *Ann. Chir. Plast. Esthet.*, 40: 404-11, 1995.
- 34- Dan Mon O'Dey, Peter Baltes, Ahmet Bozkurt and Norbert Pallua: Importance of the suprasternal notch to nipple distance (SSN:N) for vascular complications of the Nipple Areola Complex (NAC) in the superior pedicle vertical mammoplasty: A retrospective analysis *Journal of Plastic Reconstructive & Aesthetic Surgery*, 64 (10): 1278-83.
- 35- Schlenz I., Kuzbari R., Gruber H. and Holle J.: The sensitivity of the nipple-areola complex: An anatomic study. *Plast. Reconstr. Surg.*, 105: 905-9, 2000.
- 36- Hamdi M., Van Landuyt K., Tonnard P., Verpaele A. and Monstrey S.: Septum-based mammoplasty: A surgical technique based on Würinger's septum for breast reduction. *Plast. Reconstr. Surg.*, 123: 443-54, 2009.
- 37- Kling R.E., Tobler W.D. Jr., Gusenoff J.A. and Rubin J.P.: Avoiding Complications in Gigantomastia. *Clinics in Plastic Surgery*, 43 (2): 429-39, 2016.