

## Evaluation of the Use of Nd:YAG Laser in the Treatment of Infantile Hemangiomas

NADER EL-MELEGY, M.D.; WAEL H. MAHMOUD, M.D. and YASSER EL-HAWARY, M.D.

*The Department of Plastic and Reconstructive Surgery, Faculty of Medicine, Tanta University*

### ABSTRACT

**Background:** Hemangiomas are common vascular neoplasms in infancy. They have the potential for involution spontaneously. Therefore, a "watchful waiting" strategy frequently seems to be appropriate. Nevertheless, an active treatment is necessary in certain cases. Various therapeutic modalities to infantile hemangiomas have been described with variable results. One such treatment includes laser therapy. This study aimed to evaluate the outcomes of infantile hemangiomas treated with percutaneous 1064nm Nd:YAG laser.

**Methods:** A prospective study was conducted between March 2012 and March 2014 of 30 patients (9 boys, 21 girls), with 31 cutaneous infantile hemangiomas, with mean age of 7.45 months, underwent Nd:YAG laser therapy. All subjects were evaluated regarding the possible side effects of laser therapy. The final results were assessed by two independent plastic surgeons based on improvement in thickness, texture and color after treatment. Parents' subjective satisfaction was also assessed.

**Results:** The mean number of treatment sessions was 5.6 sessions. The period of follow-up ranged from 7 to 48 months. Erythema and edema occurred in all patients, blisters and crusts in 4 (13.3%) cases, ulceration in 3 (10%) cases, hypopigmentation in 2 (6.7%) cases, hyperpigmentation in one (3.3%) case, atrophic scarring in four (13.3%) cases and cicatricial alopecia in one (3.3%) case. Six (20%) patients had excellent response, 18 (60%) patients had good response, 5 (16.7%) patients had fair response and one (3.3%) patients had poor response. Sixteen (53.3%) of the parents were satisfied with the treatment response, while 10 (33.3%) were partially satisfied and 4 (13.3%) were dissatisfied with the results.

**Conclusion:** We believe that Nd:YAG laser, is a superior method in the management of mixed and deep infantile hemangiomas, results in higher rates of clearance. However epidermal cooling is essential to improve cosmetic results and reduce the adverse events and the number of sessions required for treatment.

**Key Words:** Nd:YAG – Laser therapy – Infantile hemangioma.

### INTRODUCTION

Infantile hemangiomas are considered to be the most prevalent type of benign tumors in infancy;

their incidence is higher in premature infants with low birth weight (22-30%) and is more frequent in girls 3-5 times than boys [1]. These vascular lesions have a characteristic clinical course; usually are absent at birth, then appear during the early weeks of life and continue to grow rapidly during the following 6-9 months (proliferative phase). After the child's 1<sup>st</sup> birthday, gradual regression follows in most patients (involution phase), with almost complete evanescence by the age of 5-10 years [2]. Thanks to this benign course, the majority of infantile hemangiomas can be managed only by watchful waiting and simple observation. However, in 10-20% of cutaneous infantile hemangioma patients, complications occur such as ulceration, bleeding, functional impairment and/or cosmetic disfigurement. These complications would entail an active treatment [3].

Conventionally, infantile hemangiomas have been treated by corticosteroids, vincristine, interferon alpha, sclerotherapy, radiotherapy, cryotherapy, surgical intervention, propranolol and laser therapy [4]. Treatment of infantile hemangiomas with different laser systems has been used since the 1980s. The use of laser photocoagulation as a treatment option presents a more conservative, yet efficient therapeutic modality [5]. However, an ideal laser that can efficiently treat vessels of different sizes and depths, hasn't been built yet. Vascular lasers including: Potassium titanyl phosphate (KTP, 532nm), pulsed dye laser (PDL, 585-595nm) and neodymium-yttrium aluminium garnet (Nd:YAG, 1064nm) lasers [6].

PDL has been shown to be useful in treating superficial infantile hemangiomas but is less effective for deeper lesions due to its limited depth of penetration (1.2mm) [7]. The 1064nm Nd:YAG laser can penetrate the tissues up to 5-6mm. Therefore, it can affect moderately deep and large caliber vessels. Moreover, it is mainly absorbed by tissue

proteins resulting in excellent tissue coagulation [8,9]. Nd:YAG laser can be applied directly to the skin surface which is known as the percutaneous technique or can be introduced into the tissue by a bare fiber, using a 16-gauge needle which is known as the intralesional technique [10]. In this study, we aimed to evaluate the outcomes of infantile hemangiomas treated with percutaneous Nd:YAG laser.

## **MATERIAL AND METHODS**

This prospective study was conducted from March 2012 to March 2014 at Plastic Surgery Department, Tanta University Hospitals on 30 patients (21 girls and 9 boys), having 31 cutaneous infantile hemangiomas, ranging in age from 3 to 20 months.

Patients were included for the following reasons: Cosmetic disfigurement 10(33.3%), ulceration and/or bleeding 14 (46.7%) and functional impairment 6 (20%). Cases who received previous therapy for their hemangiomas were excluded from the study. The parents gave written informed consent regarding the line of treatment and photography. After the University Ethical Committee has approved the study protocol, all patients were subjected to detailed history taking, standard clinical examination, coagulation profile and complete blood picture.

Our treatment sessions were done in the outpatient clinic of our Laser Unit. We used topical anesthesia cream containing lidocaine 2.5% and prilocaine 2.5% (EMLA cream) for at least 1 hour under occlusion before each session. Xylocaine spray was applied for intra-oral portion of any lesion. For lesions near the eyes, metal eye shields were used after corneal anesthesia with eye drops containing tetracaine 0.7% solution. A 1064nm Nd:YAG laser associated with chilled air cooling system (Cynosure, Smartcool, USA) was used for all treatments. We used the percutaneous technique and our laser parameters were; 5-7mm spot size, 15-25ms pulse duration, 60-70 J/cm<sup>2</sup> energy fluence and 50ms delay time between pulses.

The parameters varied according to hemangioma and patient characteristics, including lesion thickness, skin type and response to previous treatments. Immediately after each session, parents were instructed to apply ice packs for 5-10 minutes then topical antibiotic with steroid cream (Fucicort cream) for 5 days to the lesions, avoid trauma to treated areas and use sun screen cream for sun exposed areas.

Table (1): Characteristics of the study population and hemangiomas

<i>Age at start of treatment, months:</i>	
Range	3-20
Mean ± SEM	7.45±0.63
<i>Sex, n (%):</i>	
Male	9 (30%)
Female	21 (70%)
<i>Location of hemangiomas, n (%):</i>	
Head & Neck	22 (73.3%)
Extremities	3 (10%)
Trunk	5 (16.7%)
<i>Surface area of hemangiomas, cm<sup>2</sup>, n (%):</i>	
<2	10 (33.3%)
2-10	13 (43.3%)
>10	7 (23.3%)
<i>Distribution of hemangiomas, n (%):</i>	
Solitary	29 (96.7%)
Multiple	1 (3.3%)
<i>Type of hemangiomas, n (%):</i>	
Superficial	11 (36.7%)
Mixed	14 (46.7%)
Deep	5 (16.7%)
<i>Phase of hemangiomas, n (%):</i>	
Proliferative	26 (86.7%)
Involution	4 (13.3%)
<i>Indication of treatment, n (%):</i>	
Ulceration and/or bleeding	14 (46.7%)
Cosmetic disfigurement	10 (33.3%)
Functional impairment	6 (20%)

Table (2): Outcome data.

<i>Number of treatment sessions:</i>	
Range	3-10
Mean ± SEM	5.6±0.49
<i>Duration of follow-up, months:</i>	
Range	7-48
Mean ± SEM	18.4±2.55
<i>Adverse events, n (%):</i>	
Erythema and swelling	30 (100%)
Blisters and crusts	4 (13.3%)
Ulceration	3 (10%)
Hypopigmentation	2 (6.7%)
Hyperpigmentation	1 (3.3%)
Atrophic scars	4 (13.3%)
Hypertrophic scars	0
Cicatricial alopecia	1 (3.3%)
Regrowth of hemangiomas, n (%)	1 (3.3%)
<i>Degree of response, n (%):</i>	
Excellent	6 (20%)
Good	18 (60%)
Fair	5 (16.7%)
Poor	1 (3.3%)
<i>Parents' satisfaction, n (%):</i>	
Satisfied	16 (53.3%)
Partially satisfied	10 (33.3%)
Dissatisfied	4 (13.3%)

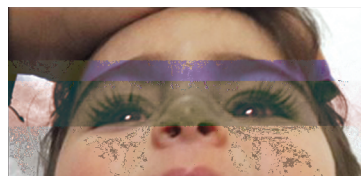
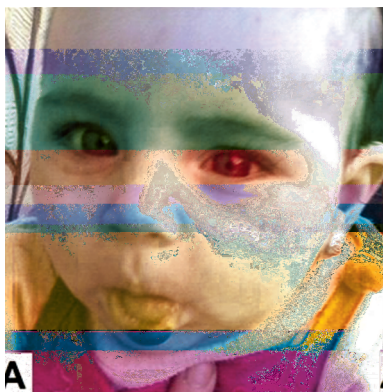

Fig. (1): (A) Five-month-old girl with a superficial infantile hemangioma on the lower lip. (B) Excellent response after 3 treatment sessions.

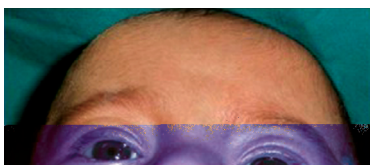

Fig. (2): (A) Four-month-old boy with two superficial infantile hemangiomas on the lower lip and above the left eye brow. (B) Excellent response after 4 treatment sessions.




Fig. (3): (A) Twelve-month-old girl with a mixed infantile hemangioma on the right shoulder. (B) Good response after 7 treatment sessions.

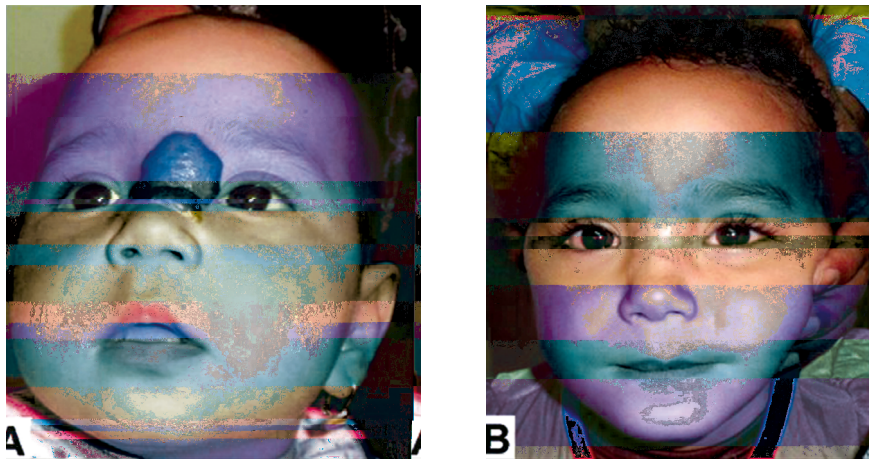


Fig. (4): (A) Seven-month-old girl with a superficial infantile hemangioma on the dorsum of the nose. (B) Good response after 4 treatment sessions.

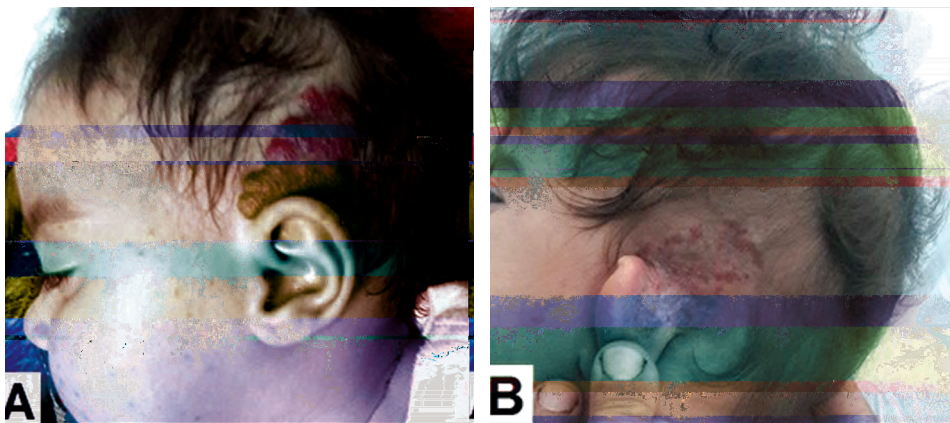


Fig. (5): (A) Nine-month-old boy with a mixed infantile hemangioma on the scalp. (B) Good response after 5 treatment sessions.

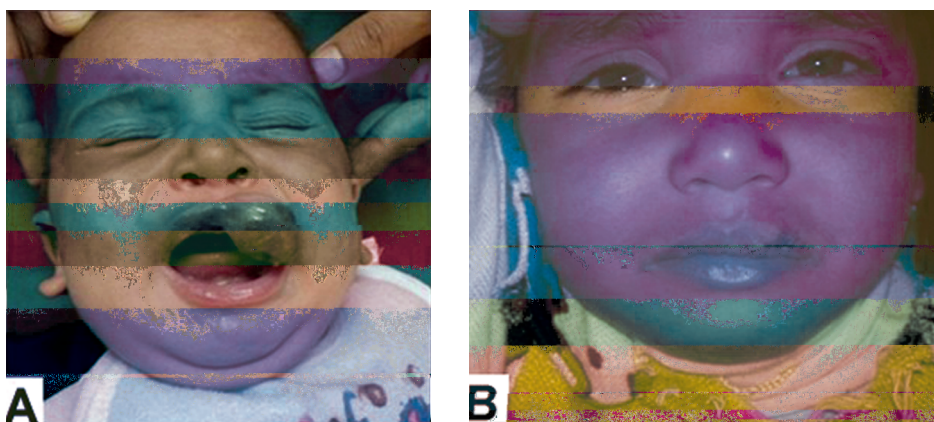


Fig. (6): (A) Six-month-old girl with a deep infantile hemangioma on the upper lip. (B) Good response after 10 treatment sessions.

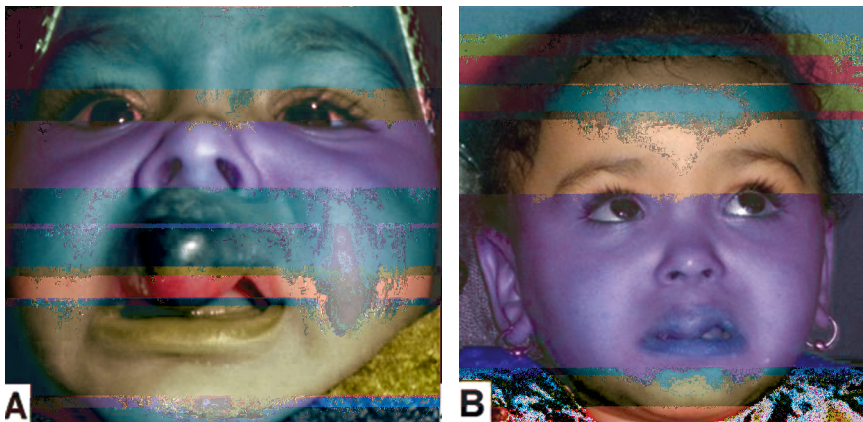


Fig. (7): (A) Eleven-month-old girl with a mixed infantile hemangioma on the upper lip. (B) Fair response after 8 treatment sessions.

## DISCUSSION

Over the last few years and due to the unpredictable behavior of infantile hemangiomas, early active treatment has been gaining a rising approval and establishing itself as a prevalent practice. Several therapeutic modalities to infantile hemangiomas have been described with variable results; each of them has specific merits and limitations. Oral and intralesional corticosteroids have been considered the 1<sup>st</sup>-line therapy for proliferative infantile hemangiomas. However, growth retardation, impaired immunity, hypertension, hyperglycemia and cushingoid facies are major drawbacks [9]. Interferon alfa-2a is used to treat life-threatening or severe steroid-resistant hemangiomas, but is limited by elevation of liver enzymes, neutropenia and spastic diplegia [11]. Cryotherapy is effective and useful in treatment of small superficial infantile hemangiomas. However, atrophic scarring and hypopigmentation are true handicaps [12].

The use of propranolol has revolutionized the treatment of infantile hemangiomas with its good efficacy and safety profile. However, hypotension, hypoglycemia, bronchospasm, bradycardia and heart failure are reported serious side effects [13]. Surgery seems to be an appropriate option, when infantile hemangiomas have failed to respond to other modalities or residual lesions exist, but the risk of intra-operative hemorrhage, injury to vital structures and post-operative scarring are the main limitations [4]. According to Lang [14], laser technology has added greatly to the armamentarium for treatment of infantile hemangiomas. Landthaler et al. [15] treated a series of 37 hemangiomas with different lasers. They reported a good to excellent response in the superficial lesions with the PDL; but the deep parts of the lesions weren't affected by the PDL due to its limited effective depth (1.2mm). For deeper lesions, laser systems with

deeper penetration are crucial. One such laser is the Nd:YAG laser.

In this work, we aimed to evaluate the outcomes of infantile hemangiomas after treatment with percutaneous Nd:YAG laser for 3-10 sessions and our parameters were; 5-7mm spot size, 15-25ms pulse duration and 60-70J/cm<sup>2</sup> energy fluence. In a similar study, Groot et al. [6] used percutaneous Nd:YAG laser therapy with parameters: 7mm spot size, 35ms pulse duration, 60J/cm<sup>2</sup> energy fluence to treat hemangioma in the upper lip and obtained good results after a single session. In another study, Saafan et al. [6] used sequential PDL and Nd:YAG lasers in treatment of infantile hemangiomas. The Nd:YAG laser parameters were; 10mm spot size, 15ms pulse duration and 25-35J/cm<sup>2</sup> energy fluence. They obtained excellent results in 72% of patients after 4-12 laser sessions and explained the reduction in energy fluence by; application of PDL at 1<sup>st</sup> increases the absorption of Nd:YAG laser by about three to five folds than that of normal blood.

In our study, we noticed that all patients developed post-treatment erythema and edema which should be considered as signs of effective treatment rather than side effects, four (13.3%) patients had blisters and crusts, 3 (10%) had ulcerations, 4 (13.3%) had atrophic scarring, one (3.3%) had hyperpigmentation, two (6.7%) had hypopigmentation and one (3.3%) had cicatricial alopecia. We had a fewer side effects than Raulin et al. [17], who used PDL and frequency-doubled Nd:YAG lasers, and found that all patients had transient swelling, 60% had purpura, 18% had crusts and blisters, 12% had hyperpigmentation, 10% had hypopigmentation and 4% had atrophic scar. Like us, Tawfik et al. [18] observed that cicatricial alopecia is a common complication for laser treatment of hemangiomas in the hairy areas which could be attributed to the photothermal effect of the laser on the hair follicles. In contrary to us, Vlachakis

et al. [8] used Nd:YAG laser to treat infantile hemangiomas in 110 patients and had a low complication rate (8.8%), which could be explained by the proper cooling of epidermis with ice before, during and after the treatment sessions. Also, Alcantara-Gonzalez et al. [19] had a very few adverse effects (18.18%); one (4.5%) case had edema and ulceration, two (9.1%) had mild atrophy and one (4.5%) had hyperpigmentation. They demonstrated that the use of sequential PDL and Nd:YAG lasers can reduce the adverse events resulting from Nd:YAG laser as a monotherapy.

Our study demonstrated that 20% of our patients had excellent response, 60% had good response, 16.7% had fair response and only 3.3% had poor response. Similar to our study, Grantzow [20] reported 77-98% decrease in size of the hemangiomas treated with Nd:YAG laser. Also, Ulrich et al. [10] treated 20 hemangioma patients with Nd:YAG laser and noticed that complete remission occurred in 20% of cases, partial remission occurred in 66% of patients while no response to therapy was detected in 14% of patients. Civas et al. [21] described a 80% success rate after Nd:YAG laser treatment of 25 cases with hemangioma.

In another study, Tan et al. [22] treated 97 hemangioma patients with Nd:YAG laser and propranolol. They divided the patients into 3 groups; group A patients were treated by Nd:YAG laser with propranolol, group B patients were treated by Nd:YAG laser only and group C patients were treated by propranolol only. They observed that complete remission occurred in 28.1% of cases in group A, 8.6% in group B and 14% in group C. Tawfik et al. [18] investigated the therapeutic effect of dual PDL and Nd:YAG lasers on infantile hemangiomas and reported an excellent response in 10%, good response in 23.3%, moderate response in 30%, mild response in 23.3% and no response in 13.3%. In a recent study, Dementieva et al. [13] studied the efficacy and safety of 940nm diode laser and propranolol in the therapy of infantile hemangiomas and concluded that combination of laser therapy to propranolol is well tolerated and has a very satisfactory cosmetic result.

Therefore, we recommend for further studies on a larger number of cases and to benefit from the combination of different laser systems or laser with other treatment modalities to improve the outcomes of infantile hemangiomas.

*Conclusion:* We believe that Nd:YAG laser, is a superior method in the management of mixed and deep infantile hemangiomas, results in higher

rates of clearance. However epidermal cooling is essential to improve cosmetic results and reduce the adverse events and the number of sessions required for treatment.

## REFERENCES

- 1- Kilcline C. and Frieden I.J.: Infantile hemangiomas: How common are they? A systematic review of the medical literature. *Pediatr. Dermatol.*, 25: 168-73, 2008.
- 2- Vlachakis I., Arbiros I., Velaoras K. and Charissis G.: Different modes cooling the epidermis with ice during Nd:YAG laser treatment of hemangiomas in children. *Med Laser Appl*, 19 (1): 19-23, 2004.
- 3- Maguiness S.M. and Frieden I.J.: Current management of infantile hemangiomas. *Semin Cutan Med. Surg.*, 29: 106-14, 2010.
- 4- Craig L.M. and Alster T.S.: Vascular Skin Lesions in Children: A Review of Laser, Surgical and Medical Treatments. *Dermatol. Surg.*, 39: 1137-46, 2013.
- 5- Brauer J.A. and Geronemus R.G.: Laser Treatment in the Management of Infantile Hemangiomas and Capillary Vascular Malformations. *Techniques in Vascular & Interventional Radiology*, 16 (1): 51-4, 2013.
- 6- Saafan A.M. and Salah M.M.: Using pulsed dual-wavelength 595 and 1064nm is more effective in the management of hemangiomas. *J. Drugs Dermatol.*, 9: 310-4, 2010.
- 7- Hunzeker C.M. and Geronemus R.G.: Treatment of superficial infantile hemangiomas of the eyelid using the 595-nm pulsed dye laser. *Dermatol. Surg.*, 36: 590-7, 2010.
- 8- Vlachakis I., Gardikis S., Michailoudi E. and Charissis G.: Treatment of hemangiomas in children using a Nd:YAG laser in conjunction with ice cooling of the epidermis: techniques and results. *BMC Pediatr.*, 3: 2, 2003.
- 9- Elflein H.M., Stoffelns B.M. and Pitz S.: Laser and other treatment options in the therapy of infantile capillary eyelid and periorbital hemangiomas: An overview. *Med. Laser Appl*, 25: 242-9, 2010.
- 10- Ulrich H., Bäumlner W., Hohenleutner U. and Landthaler M.: Neodymium-YAG Laser for hemangiomas and vascular malformations - long term results. *J. Dtsch Dermatol. Ges.*, 3 (6): 436-40, 2005.
- 11- Michaud A.P., Bauman N.M., Burke D.K., Manaligod J.M. and Smith R.J.: Spastic diplegia and other motor disturbances in infants receiving interferon-alpha. *Laryngoscope*, 114 (7): 1231-6, 2004.
- 12- Eltayeb A.A., Ibrahim N.H., Moeen S. and Herdan R.: Oral propranolol versus cryotherapy in the management of cutaneous hemangioma in infants and children. *Egypt J. Surg.*, 35: 29-34, 2016.
- 13- Dementieva N. and Jones S.: The treatment of problematic hemangiomas in children with propranolol and 940nm diode laser. *J. Ped. Surg.*, 51 (5): 863-8, 2016.
- 14- Lang P.G. Jr.: Laser technology: Its application in the management of hemangiomas and vascular malformations of the head and neck. *Facial Plast Surg. Clin. North Am.*, 9 (4): 577-83, 2001.

- 15- Landthaler M., Hohenleutner U. and El-Raheem T.A.: Laser therapy of childhood hemangiomas. *Br. J. Dermatol.*, 133: 275-81, 1995.
- 16- Groot D., Rao J., Johnston P. and Nakatsui T.: Algorithm for Using a Long-Pulsed Nd:YAG Laser in the Treatment of Deep Cutaneous Vascular Lesions. *Derm. Surg.*, 29 (1): 35-42, 2003.
- 17- Raulin C. and Greve B.: Retrospective clinical comparison of hemangioma treatment by flashlamp-pumped (585nm) and frequency-doubled Nd:YAG (532nm) lasers. *Lasers in Surgery and Medicine*, 28 (1): 40-3, 2001.
- 18- Tawfik A.A. and Alsharnoubi J.: Topical Timolol Solution Versus Laser in Treatment of Infantile Hemangioma: A Comparative Study. *Pediatr Dermatol.*, 32 (3): 369-76, 2015.
- 19- Alcántara-González J., Boixeda P., Truchuelo-Díez M.T., Pérez-García P., Alonso-Castro L. and Olasolo P.J.: Infantile Hemangiomas Treated by Sequential Application of Pulsed Dye Laser and Nd:YAG Laser Radiation: A Retrospective Study. *Actas Dermosifiliogr*, 104 (6): 504-11, 2013.
- 20- Grantzow R.: Differential therapy of hemangiomas – When cryotherapy, laser therapy or operation? *Kongressbd Dtsch Ges Chir Kongr*, 118: 521-4, 2001.
- 21- Civas E., Koc E., Aksoy B. and Aksoy H.M.: Clinical experience in the treatment of different vascular lesions using a neodymium-doped yttrium aluminum garnet laser. *Dermatol. Surg.*, 35 (12): 1933-41, 2009.
- 22- Tan M., Duan B., Zhou C.M. and Gong H.: The therapeutic effect of propranolol with 1064nm Nd:YAG laser on proliferating hemangioma in body surface. *Zhonghua Zheng Xing Wai Ke Za Zhi*, 28 (3): 164-8, 2012.