

# The Hammock Mammoplasty

HASSAN ADEL BADRAN, M.D., FRCS, FRCSEd

The Department of Plastic Surgery, Faculty of Medicine, Ain Shams University, Cairo, Egypt

## ABSTRACT

**Background:** Several techniques, were described, to correct breast ptosis. The results of these techniques showed, in many instances, lack of superior breast pole fullness and coning. In this article a novel technique is presented which is designed to address these two issues as well as improving lateral mammary fold definition.

**Methods:** This technique was used, in the period from 2004 till present, to treat 32 patients with breast ptosis. In this technique, a superiorly based lower central dermoglandular flap is created as an extension of the superior nipple areola complex (NAC) pedicle. The flap is folded on itself and is inset into a created sub glandular upper central pocket. The flap is fixed to the pectoralis fascia at the level of the second space with one or two nonabsorbable or PDS sutures. The two pillars are released from their peripheral attachments to the chest wall and are moved centrally. They are overlapped, like a hammock, below the areola. In cases requiring reduction, excision of all the remaining parenchyma in lower breast, is done.

**Patients:** Were divided, according to the indications for the operation, into four groups. In the first group 12 patients were operated for correction of breast ptosis by auto augmentation mastopexy. In the second group ten patients had the surgery for reduction mastopexy. In the third group 8 patients were operated for secondary correction of an unsatisfactory result, done elsewhere. The fourth group consisted of two patients for immediate correction of explanation deformity. A team composed of the surgeon, another qualified plastic surgeon, a qualified nurse and the patient herself, evaluated results. A study of pre & post-operative photographs was also done to help obtain a better evaluation.

**Results:** Based on the opinion of the evaluation team, the results were very good in 27 cases. In 5 cases the result was considered good. Correction of ptosis and supra areolar fullness was achieved in all breasts reviewed during the follow-up period. Coning was achieved in 27 cases. The base width of the breast was reduced by an average of 10-15% in all cases. The lateral mammary fold definition also improved.

**Conclusion:** Based on the results achieved in these 32 patients, it is recommended to add this technique to the armamentarium of the breast surgeon to achieve supra areolar fullness, lateral mammary fold definition and coning.

**Level of Evidence:** Level IV.

**Key Words:** Hammock – Mammoplasty.

## INTRODUCTION

Many techniques were described in the literature for correction of breast ptosis [1-23]. The objective of these techniques is mainly to elevate the nipple areola complex (NAC) to its normal position and to remove the excess skin and/or parenchyma when necessary. The results of these techniques produced, in many cases, a flat or concave upper pole with a square shape.

The correction of upper pole deficiency was addressed in several publications [1-21]. Almost all the proposed techniques used an inferiorly based dermoglandular flap to augment the upper pole. Swanson [2] reviewed 82 of these published papers and stated that none of them really improved upper pole deficiency. The main disadvantage of these flaps was their limited mobility to reach the upper pole.

The use of a superiorly based dermoglandular flap for the same purpose was described by De la Plaza [7] who termed it the hammock flap. For a better mobility, Losken [15] used a superomedial pedicle flap to augment deficiencies in the upper breast.

The reported method aims at correction of superior pole deficiency, improving projection and getting rid of the boxy postoperative shape. It is the result of several modifications and additions to the original Lejour [4] technique. These modifications included the following:

- 1- Mobilizing the vertical limbs of the dome pattern leaving only the transverse component of the dome attached.
- 2- Extending the superior NAC pedicle downwards to include the lower central breast.
- 3- Releasing the pillars from their peripheral attachment to the chest wall.

- 4- No attempt was made to gather the skin in the breast segment during closure.
- 5- No liposuction in the breast.

## PATIENTS AND METHODS

### *Preoperative evaluation:*

All patients were subject to medical examination to confirm their fitness for surgery. The operation was discussed in detail with the patient to make sure that the expected result meets her expectations.

Preoperative examination included patient's weight and BMI. Local examination included the position of NAC in relation to the breast, the degree of ptosis and the volume of the existing parenchyma. In case the volume of the remaining parenchyma was adequate, this technique of auto augmentation (or parenchymal rearrangement) mastopexy was recommended. In cases where ptosis is associated with hypertrophy, the technique was considered suitable if the required reduction was reasonable (600-800 grams). In cases presenting for secondary correction, the type of the residual deformity is documented and the suitability of this technique was discussed with the patient. In cases of explanation the patient was advised that the shape will be restored but the volume will diminish.

### *Marking:*

The patient was marked in the standing position. All the anatomical landmarks were identified (sternal notch, breast meridian, new nipple position, and inframammary fold). The median sternal line, inframammary crease line, and midbreast line were marked first. The new nipple position was marked on the breast meridian line by transferring the lowest point of the inframammary fold (IMF) to the anterior surface of the breast. This mark represents the upper border of the areola and not the nipple. Usually it is located 19 to 22cm from the sternal notch.

The mosque dome pattern of the Lejour technique [4] was used. The distance between the two vertical limbs was determined by shifting the breast medially and laterally, marking the line to match the abdominal extension of the breast meridian as in Lejour technique [4]. In addition the pinch test was used for more accurate judgment for the extent of skin deepithelialisation.

### *Surgical technique:*

The operation was done under general endotracheal anaesthesia in a hospital. Different areas of the breast were infiltrated with 1:100000 solution

of adrenaline to minimize bleeding. The areola was outlined under maximum tension by a circular cutter 4.2 in diameter. Incisions were made to the dermis level along the outline of the whole pattern followed by deepithelization.

The deepithelialised area extended down to include the planned central flap (the downward extension of the superior pedicle) (Figs.1A, 2A). Following deepithelialisation, incisions were deepened to the subcutaneous level starting from the point A & A' at the upper border of the neo areola marking (Figs. 1A, 2A). Incisions are then extended down from the periareolar area into the sides of the central flap (Fig.1A). Subcutaneous undermining in this periareolar area is kept to minimum. Just enough to mobilize the skin to easily wrap it around the shifted areola. The rest of subcutaneous undermining started from the blocking triangle area of the pattern at points B & B' and extended to expose the whole lower breast.

Subglandular undermining was then done to the level of the NAC separating the whole lower part of the breast from the chest wall. This was further mobilized by separating its medial and lateral peripheral attachments. Undermining was continued upwards under the areola to the level of the second space, creating a pocket that is prepared to receive the central de-epithelized lower flap.

The mobilized lower breast was then incised to create three flaps. (Fig. 1B) one central, one medial and one lateral pillars. The three flaps were 6-8cm in width and 7-9cms in length (Figs.1B, 2A,B). Their thickness was equal to the thickness of the lower gland i.e. no debulking was done to ensure vascularity. Excision of the excess parenchyma, if present, was done from the tissues between the three flaps and any excess that was present caudal to the 7-9cms length of the flaps. The NAC with its parenchyma was then moved upwards to its new position. It was secured with 2-3 PDS 3"0" sutures to the upper border of dome (Fig. 1D).

The central flap was folded on itself, taking its apex under the areola with its deepithelialised surface facing the pectoral fascia, into the created upper pocket (Fig. 1D). It was stitched with 2"0" PDS sutures to the pectoral fascia at the level of the second intercostal space.

The two mobile pillars were then shifted centrally and overlapped over each other like a hammock below the areola and sutured in place, (Figs. 1E, 2C).

The wound was closed in two layers in a vertical fashion. No breast parenchyma was included in the sutures and no attempt was made to gather the excess skin in the breast section of the closure as was recommended by Lejour [4] (Fig. 3A). Early in the study, the excess skin in the lower part of the wound was allowed to extend into the area between the old and new IMF (3A). In the last fifteen cases the redundant skin was gathered upwards to the new IMF level by a purse string suture. The wound was drained for 24 hours using a rubber drain (Fig. 3B).

#### *Post-operative management:*

Patients were usually discharged next morning, at which time the drains were removed. Recovery was uneventful in all patients. They were followed-up at the office one week, one month, three months and six months.

#### *Complications:*

Suture spitting occurred in 30% of cases but had no effect on the final scar. Partial areola desquamation occurred in 2 cases of reduction mastopexy which healed with simple dressings. Asymmetry of areola size occurred in one patient and was corrected under local anesthesia.

Delayed healing occurred at the end of the vertical scar at the inframammary fold in 14 cases. They all healed with simple dressings.

Evaluation of the results was done by a team which included the surgeon, the patient, a qualified nurse and another plastic surgeon. A table with the relative importance of evaluation criteria, was provided to the team (Table 1). Each item of evaluation criteria was given a score with a total of 150 points. Evaluation was done using the aesthetic eye judgment plus tape measurements of distances between key structures of the breast. These included nipple, sternal notch, midclavicular point, IMF, chest mid line, mid arm level and the lateral edge of the pectoralis muscle. Photographic analysis was also done to confirm the team's evaluation. Pre & post-operative photographs with similar magnification ratio were imported to Microsoft paint software. Lines were drawn on patient's photographs to create angles. We compared angles rather than linear measurements because angles are not affected by magnifications.

The angle of lateral mammary ptosis was determined on the oblique lateral photos (Fig. 4C, 4D). It is the angle of divergence between two

lines representing the lateral edge of the pectoralis major muscle and the lowest point of the lateral mammary fold.

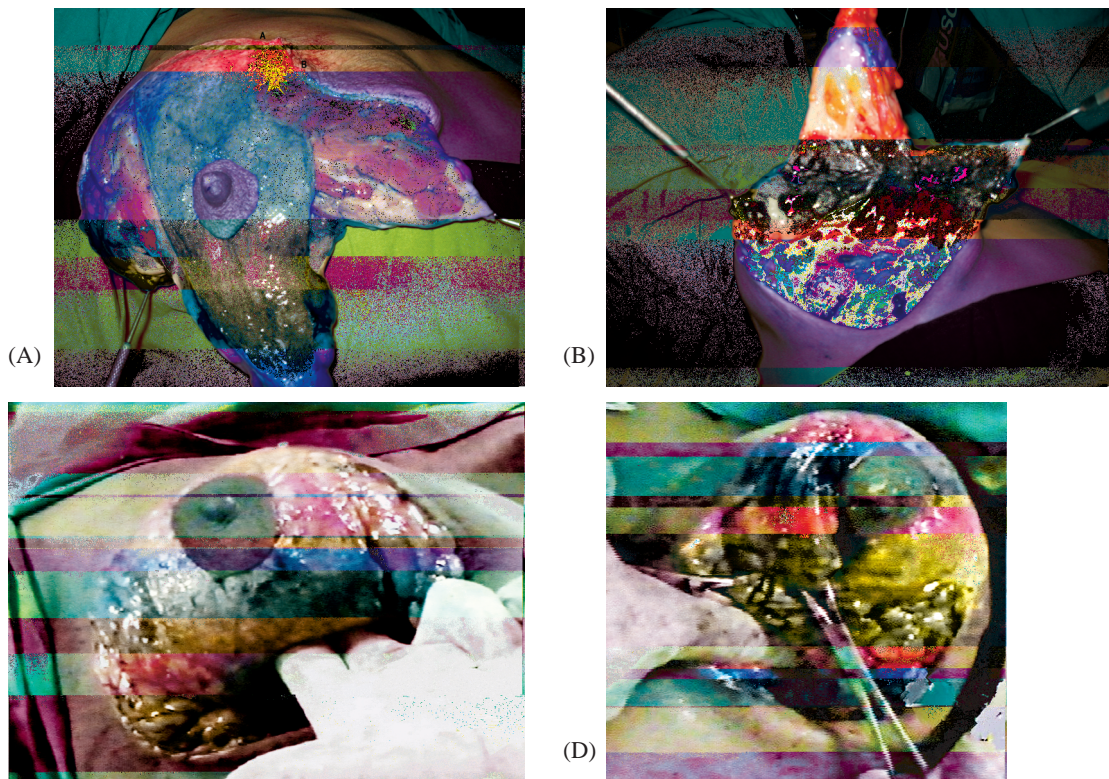
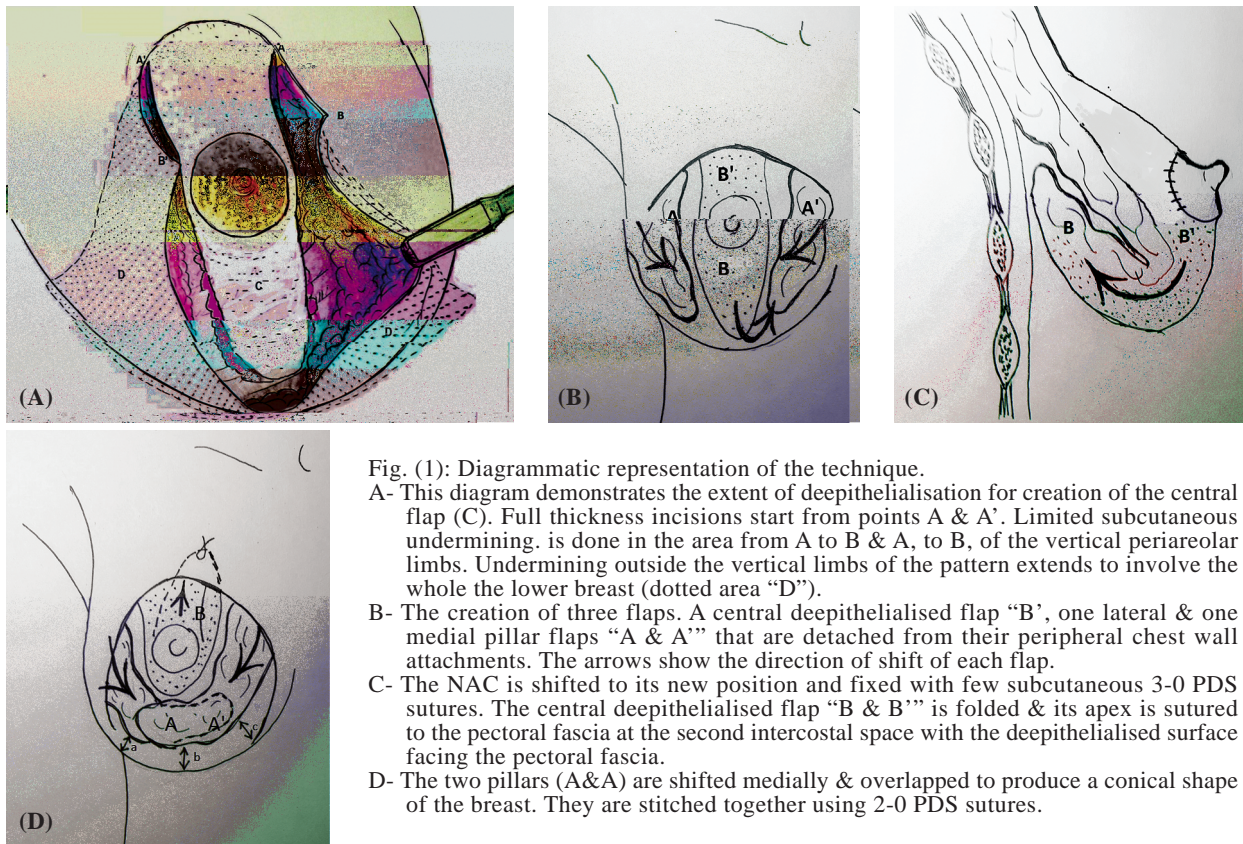
The angle for projection and vertical ptosis correction was measured on lateral photographs (Fig. 4A,B). It was measured between a vertical line from the sternal notch passing through the base of the breast and a horizontal line at the proposed ideal projection level, at the level of the mid arm. A line from this intersection was drawn to represent the actual position of the nipple. Angle A represented the amount of correction of vertical ptosis and angle B, if present, represents the deficit needed for ideal nipple position. A result of 60-65% was considered acceptable. A score of 65-75% was considered a good result. Above 75% was very good and above 85% was excellent. Scores below 60% was considered poor.

## **RESULTS**

The first group included 12 patients, the second group 10 patients, the third group 8 patients and the fourth group 2 patients. All patients had varying degree and types of ptosis. The average vertical ptosis distance was 8cms. The Body Mass index (BMI) was within normal (18- 25) in 25 patients. Five patients were overweight (BMI 25-30). The biggest resection in the second group was 800 grams from each breast (case No. 28). The smallest was 400 grams (case N. 30) with an average resection of 600 grams. We encountered no hematomas or seromas in the reported cases. Evaluation of seroma existence was clinical. Wound healing occurred in a normal way.

Follow-up ranged between 2-6 months. Patients were followed-up until they were completely satisfied with the result. They were not willing to come for longer evaluation after that. A ten year follow-up was obtained from one patient from the fourth group.

Based on the evaluation team rating, (clinical & photographic), the results were very good in 27 cases. In 5 cases the result was considered good. Ptosis correction and supra areolar fullness were achieved in all breasts reviewed during the follow-up period. Projection and coning was achieved in 85% of cases. The base width of the breast was reduced by an average of 10-15% in all cases. Lateral mammary fold definition also increased by average 20% in all cases.






Fig. (3): Photographic assessment of the results.

- A- The angle of vertical ptosis & projection correction: It is the angle between a vertical line dropped from the sternal notch & a horizontal line from the mid arm representing the ideal location of the nipple. In cases of ptosis, a line is drawn from the point of intersection of the two lines to the nipple position. This creates two angles; (A) is the existing angle of ptosis & (A') represents the amount of elevation needed for correction.
- B- This angle should be 90 postoperatively.
- C- The angle of lateral ptosis Correction: It is the angle between two lines starting at anterior axillary fold line representing the lateral edge of the pectoralis major muscle & a line touching the lower edge of the breast.
- D- This represents the degree of postoperative improvement.

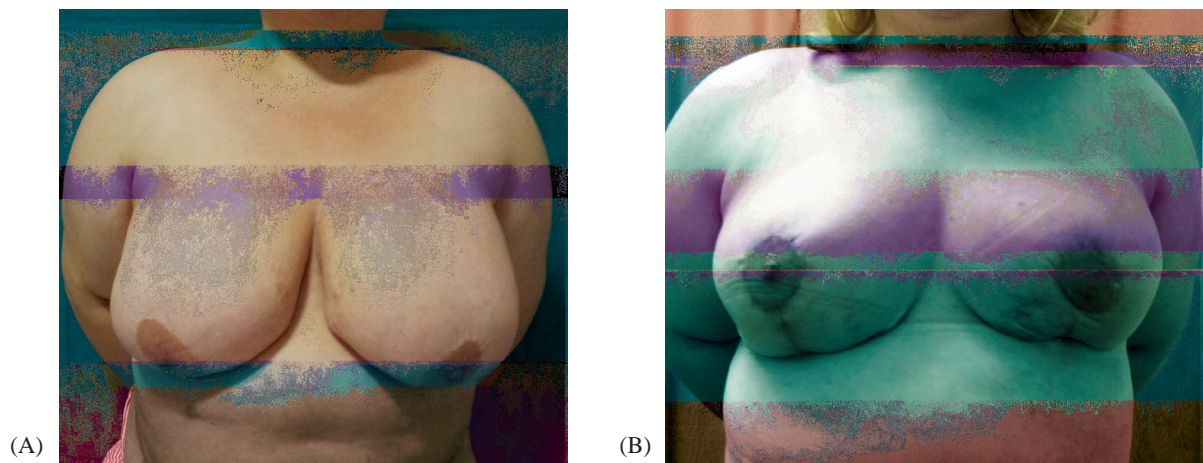


Fig. (4): This 40 year's old lady presented with large ptotic breasts. The ptosis distance was 8cm. 700 grams of breast tissue were removed from each breast.

A- Pre-operative front view.

B- Post-operative view.

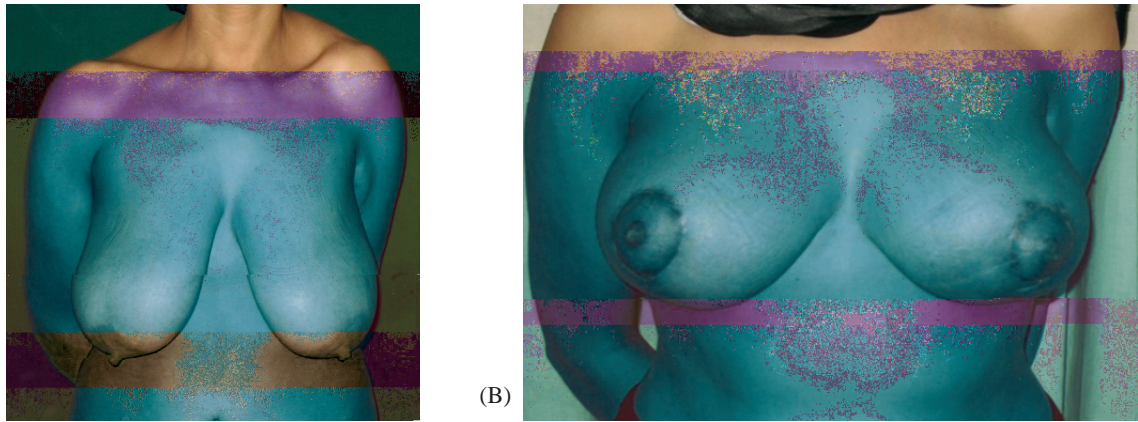


Fig. (5): This 30 year old girl presented for correction of severe breast ptosis. Her ptosis distance was 10 cms. & the vertical ptosis angle was 35 degrees. Examination showed adequate volume of the remaining breast parenchyma. Her deformity was corrected using our technique.  
 A- Preoperative front view showing the degree of ptosis.      B- Postoperative photo showing the correction at one month.




Fig. (6): This 28 year old female presented for correction of unsatisfactory result of primary reduction mammoplasty. Examination showed a boxy shaped flat breast. The scar of the primary operation was an inverted T. At operation the primary pedicle was found to be a superiorly based one. Therefore our technique was applied with a short downward extension of the central flap to ensure its vascularity.  
 A- Pre-operative front view.      B- Post-operative view showing coning of the breast.

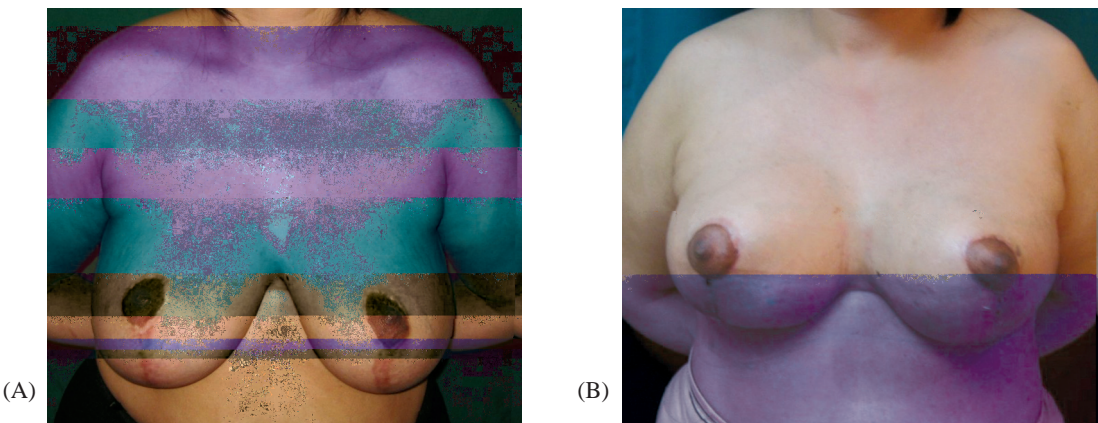


Fig. (7): This 45 year old female presented for secondary correction of unsatisfactory result of reduction mammoplasty. Examination showed a boxy shaped flat breast with lateral mammary ptosis.  
 The primary operation ended by a vertical scar & therefore it was assumed that the surgeon has used a superiorly based pedicle. At operation the length of the central deepithelialised flap was therefore shortened to ensure its vascularity. The two pillars were mobilized & overlapped.  
 A- Preoperative front view. The oblique lateral view is used in Fig. (4A) to demonstrate the angle of lateral breast ptosis which was 30 degrees in this case.  
 B- Post-operative front view. The oblique lateral view is used in Fig. (4B) to demonstrate the angle of lateral breast ptosis, which was reduced to 26 degrees.

Table (1): Indications for which the technique was used. It also shows the numbers of patients for each indication.

Indications	Number of Patients
Ptosis with normal remaining parenchymal volume	12
Ptosis with increased parenchymal volume	10
Unsatisfactory shape following previous mammoplasty	8
Reshaping the breast following the removal of implants	3

Table (2): Relative weights of the evaluation criteria. Patient satisfaction was given the highest score because this is the main objective of the operation.

Element of evaluation	Given Points
Shape (square, pyramidal)	15
Projection & upper pole fullness	15
Correction of vertical & lateral ptosis	15
Position of NAC in relation to breast mound & to IMF	10
Degree of volume reduction (adequate, excessive, not enough)	10
Degree of base width reduction	10
Quality of scars	10
Patient satisfaction	40
Symmetry	10
<b>Total Points</b>	<b>135</b>

## DISCUSSION

The concept of using breast tissue to augment its deficient areas has a long history. It dates to Ribeiro [1] who described an inferiorly based parenchymal flap transposed to the upper pole in an effort to simulate a breast implant. Subsequently, many articles were published claiming to increase upper pole fullness or breast projection without an implant [2-23].

Most of the reported articles used an inferiorly based central dermoglandular flap with a short-scar pattern mastopexy [1-12]. The blood supply of these flaps came from the fourth through sixth intercostal vessels. Often their dermal plexus was left attached at the level of the inframammary fold to retain additional blood supply. This design restricted the free movement of the flap to the superior aspect of the breast. Hammond [8] suggested basing the lower island transposition flap on the breast septum and releasing its dermal

attachments, in an attempt to improve the mobility of the flap. Perez Macias [7] described a combination of inferior pedicle design with retro pectoral suspensions. He used dermal slings taken from the sides of the inferior pedicle flap for that purpose. His technique aimed at pushing the inferior pedicle upwards and to prevent the displacement of breast tissue toward the inferior mammary pole. He called his method the hammock technique.

Pascone [22] also used the three-dermoglandular flaps principle for improving breast support, projection and shape. His technique is a modified inferior pedicle/inverted T scar.

Hamdi et al. [15] used the excess lateral tissue based on the lateral intercostal artery perforators to autoaugment volume depleted breasts in massive weight loss patients.

The use of a superiorly based lower central dermoglandular flap was described in 2005 by De la Plaza [7]. He transposed it to the upper pole and called it the hammock flap. The flap was fixed like a hammock to the pectoral fascia and the wedge-shaped donor defect was closed without undermining by approximation and fixation of the medial and lateral pillars with absorbable sutures, thus releasing the tension in the skin suture line.

Losken et al. [15] used the extended superomedial flap of Findlay [14] to provide additional volume in certain locations within the breast mound. He stated that this flap has a well-vascularized pedicle and has an arc of rotation that is ideal for transfer to the lateral or upper breast region. The superomedial technique also allowed plication of the medial and lateral pillars with the benefits of a vertical mammoplasty technique. Kim et al. [25] recently showed minimal complications and high patient satisfaction using a superior pedicle autoaugmentation mastopexy technique.

The presented operation and its name were developed independently as a gradual modification of Lejour [4] technique. In our technique more mobilization of the lower breast segment was done, detaching it from its peripheral attachment to the chest wall. The lower central tissue that is excised in Lejour technique, was used as an extension of the superiorly based pedicle, to augment the upper pole.

Mobilizing the skin of the vertical limbs of the dome pattern made it easier to wrap the skin around the shifted NAC and solved a difficult problem in Lejour technique.

Folding and shifting the superiorly based deepithelialised flap upwards under the areola and upper pole not only helped to create projection, but it also facilitated moving the NAC to its new location. This flap has a better upward reach than that of the inferiorly based flaps and therefore is more efficient in filling the created pocket with a better upper pole fullness. Its blood supply comes from the superior pedicle and is adequate, as long as a good amount of subcutaneous fat (usually the full thickness of the gland) is kept in the flap.

The idea of overlapping the two pillars to increase projection was used by different authors as a part of their technique. Ship et al. [3] proposed the use of two superiorly based dermoparenchymal flaps for that purpose. He also proposed minimal undermining of the medial and lateral new periareolar marking to facilitate the inset of the areola to its new position. However, he did not address superior pole deficiency and ended by an inverted T scar.

Benelli [4] proposed interdigitating the pillars to increase breast projection in his round block mastopexy technique. However, he did not release the peripheries of the pillars to reduce the transverse width of the breast base.

In Lejour technique the pillars were kept attached to chest wall on their peripheries and were stitched side by side. This mainly stretched the breast base rather than diminishing its width and in some cases produced a boxy postoperative shape. Moving the pillars as freely mobile flaps helped diminishing the breast base width. It also led to a better definition of the lateral mammary fold. Overlapping the pillars helps to prevent recurrence of ptosis. It also leads to rounding of the inferior pole and helps in the production of a pyramidal breast shape.

Dealing with the horizontal skin excess was corrected in Lejour [4] technique, by gathering the skin taking unequal bites while stitching it to the underlying breast tissue. This usually led to an irregular wound that takes some time to settle. Hammond [9] stated that in vertical patterns the wound often crosses the IMF, which is a frequent area of skin bunching and wound breakdown. He recommended curving the incision laterally along the inframammary fold, to enhance wound healing while still preserving a short scar strategy.

In the author's technique the wound was closed in two layers with no attempt to gather the skin or attach it to the underlying parenchyma. Early in the development of this technique the wound ex-

tended into the zone between the old and the new IMF. However, later the author used a purse string suture with its knot attached deeply and superiorly at the new IMF level.

Many methods were used by different authors to evaluate postoperative results. Swanson [2] used retrospective photographic analysis for evaluation. He calibrated photographs using the upper arm length for reference. A length of 32.5cm was assigned to the upper arm for all his patients. He justified the use of such a reference length because it is the difference between preoperative and postoperative values that was being studied. His conclusions claimed that none of the existing techniques really produced superior pole fullness.

Honig et al. [3] evaluated his results by comparing breast distances. In all his patients, the distances between the nipple and the sternal notch (N-SN), between the nipple and the inframammary fold (N-IMF), and the intermammary distance (IMD) were measured preoperatively and at 6 and 12 month postoperatively. Photographs were also taken at the time of clinical examination and were reviewed by two residents. His results were semi quantitated and a mean score was calculated. Keck [24] evaluated her results at 6 month by clinical examination. At 12 month the evaluation was done by a questionnaire.

Our evaluation team used the criteria present in Table (1) for judgment. Methods of evaluation included clinical aesthetic eye examination, comparison of pre & postoperative clinical measurements and photographic confirmation. In these criteria the patient satisfaction was given the highest score because we felt that this is our main objective. Since the main complaint of the patients was always ptosis, lack of projection and improper breast shape, these criteria were given the next highest score. The final result was a percentage out of 150 points total score.

The time required for an acceptable follow-up also varies in different publications. An average follow-up in most published papers is between 6&12 month. In Swanson [2] retrospective study of 82 published papers on autoaugmentation mastopexy, a minimum follow-up interval of 3 months was used. He stated that in a number of the reviewed publications the follow-up interval was not specified.

Keck et al. [24] conducted a study to evaluate the results of 72 patients after vertical mammoplasty. Her follow-up was for 12 months. She stated that the main changes, following vertical mammo-



plasty, took place during the first three months after surgery.

Our follow-up was 2-6 months but we were able to demonstrate the stability of the results through a 10 year follow-up in one patient who presented for another cosmetic procedure (Fig. 4).

This technique, gives good results with a high patient satisfaction. I recommend adding it to the armamentarium of the breast surgeon.

#### *Acknowledgement:*

The author declares that he has no conflicts of interest to disclose.

### REFERENCES

- 1- Ribeiro L.: A new technique for reduction mammoplasty. *Plast. Reconstr. Surg.*, 55: 330-334, 1975.
- 2- Swanson Eric M.D.: A Retrospective Photometric Study of 82 Published Reports of Mastopexy and Breast Reduction *Plast. Reconstr. Surgery*, 1282: 1301, 2011.
- 3- Honig Johannes F., Frey H.P. and Hasse F.M.S.N.: Inferior Pedicle Autoaugmentation Mastopexy After Breast Implant Removal *Aesth. Plast. Surg.*, 34: 447-454, 2010.
- 4- Lejour M.: Vertical mammoplasty and liposuction of the breast. *Plast. Reconstr. Surg.*, 94: 100-14, 1994.
- 5- Ship A.G., Weiss P.R. and Engler A.M.: Dual-pedicle dermoparenchymal mastopexy. *Plast. Reconstr. Surg.*, 83: 281, 1989.
- 6- Benelli L.: A new periareolar mammoplasty: The "round block" technique. *Aesthetic Plast. Surg.*, 14: 93, 1990.
- 7- De la Plaza, Rafael, De la Cruz, Moreno, Carlos and Luis: Mastopexy utilizing a dermoglandular hammock flap. *Aesthetic Surgery Journal*, 25 (1): 31-6, 2005.
- 8- Pérez-Macias J.M.: Long-lasting evolution of ptosis control after reduction mammoplasty using the hammock technique *Aesthetic Plastic Surgery*, 31 (3): 266-74, 06/2007.
- 9- Hammond D.C., Alfonso D. and Khuthaila D.K.: Mastopexy using the short scar periareolar inferior pedicle reduction technique. *Plast. Reconstr. Surg.*, 121: 1533-1539, 2008.
- 10- Graf R.M., Mansur A.E., Tenius F.P., Ono M.C., Romano G.G. and Cruz G.A.: Mastopexy after massive weight loss: Extended chest wall-based flap associated with a loop of pectoralis muscle. *Aesthetic Plast. Surg.*, 32: 371-374, 2008.
- 11- Graf R., Biggs T.M. and Steely R.L.: Breast shape: A technique for better upper pole fullness. *Aesthetic Plast. Surg.*, 24: 348-352, 2000.
- 12- Graf R. and Biggs T.M.: In search of better shape in mastopexy and reduction mammoplasty. *Plast. Reconstr. Surg.*, 111: 309-317, 2002.
- 13- Rubin J.P. and Khachi G.: Mastopexy after massive weight loss: Dermal suspension and selective auto-augmentation. *Clin. Plast. Surg.*, 35: 123-129, 2008.
- 14- Hall-Findlay and Elizabeth J.: A simplified vertical reduction mammoplasty: Shortening the learning curve. *Plast. Reconstr. Surg.*, 104: 748-759, 1999.
- 15- Losken A. and Holtz D.J.: Versatility of the superomedial pedicle in managing the massive weight loss breast: The rotation-advancement technique. *Plast. Reconstr. Surg.*, 120: 1060-1068, 2007.
- 16- Hamdi M., Van Landuyt K., Blondeel P., Hijjawi J.B., Roche N. and Monstrey S.: Autologous breast augmentation with the lateral intercostal artery perforator flap in massive weight loss patients. *J. Plast. Reconstr. Aesthet. Surg.*, 62: 65-70, 2009.
- 17- MODOLIN M., CINTRA W. Jr., SILVA M.M., RIBEIRO L., GEMPERLI R. and FERREIRA M.C.: Mammoplasty with inferior pedicle flap after massive weight loss. *Aesthetic Plast. Surg.*, 34: 596-602, 2010.
- 18- Thornton D.J. and Fourie le R.: Autologous augmentation-mastopexy after bariatric surgery: Waste not want not! *Aesthetic Plast. Surg.*, 34: 519-524, 2010.
- 19- Okada A., Saito F.L., Hiraki P.Y., et al.: Mastopexy after massive weight loss: Dermal suspension, parenchymal reshaping, and augmentation with autologous tissue. *Rev. Bras. Cir. Plast.*, 27: 283-289, 2012.
- 20- Daniel M.: Mammoplasty with pectoral muscle flap. Paper presented at: 64<sup>th</sup> Annual ASPRS/PSEF/ASMS Scientific Meeting; October 7-11, Montreal, Quebec, Canada, 1995.
- 21- Cerqueira A.A.: Mammoplasty: Breast fixation with dermoglandular mono upper pedicle flap under the pectoralis muscle. *Aesthetic Plast. Surg.*, 22: 276-283, 1998.
- 22- Pascone M., Di Candia M. and Pascone C.: The three dermoglandular flap support in reduction mammoplasty. *Plast. Reconstr. Surg.*, 130: 1e-10e, 2012.
- 23- Botti G.: Vertical scar mammoplasty: Stable padding of the superior pole by means of a posteriorly based pedicle autoprosthesis. *Aesthet. Surg. J.*, 19: 116-123, 1999.
- 24- Keck M., Kaye K., Thieme I. and Ueberreiter K.: Vertical mammoplasty: Postoperative changes, complications and patient evaluation. *Can. J. Plast. Surg.*, 15 (1): 41-43, 2007.
- 25- Kim P., Kim K.K. and Casas L.A.: Superior pedicle autoaugmentation mastopexy: A review of 34 consecutive patients. *Aesthet. Surg. J.*, 30 (2): 201-10, 2010.