

## Clinical and Functional Outcomes of Three-Dimensional Free Anterolateral Thigh (ALT) Flap in Oropharyngeal Reconstruction

TAREK ABULEZZ, M.D.<sup>1</sup>; MAHMOUD A. HIFNY, M.D.<sup>2</sup>; KAMEI YUZURU, M.D.<sup>3</sup>; SAMIA SAIED, M.D.<sup>1</sup> and MANSOUR KABBASH, M.D.<sup>4</sup>

The Department of General Surgery, Plastic Surgery Unit, Faculty of Medicine, Sohag<sup>1</sup>, South Valley<sup>2</sup>, Nagoya, Japan<sup>3</sup> and Aswan<sup>4</sup> Universities

### ABSTRACT

**Background:** Oral and oropharyngeal cancers have a profound impact on the quality of life of patients and their families. Even with reconstructive procedures, the patient's quality of life can be significantly altered by these functional problems. Although the primary intended outcome of head and neck cancer surgery is still the disease-free survival of the patient, quality of life is now considered as an essential goal and its assessment in head and neck cancer patients has become an important aspect of postoperative care. The aim of this study is to evaluate the functional outcomes of the three-dimensional template design free anterolateral thigh flap in reconstruction of intra-oral soft tissue defects that result after oral and oropharyngeal ablative surgery.

**Patients and Methods:** 27 patients were classified into 3 groups according to the extent and geometry of the postresection defect. The resection involves oral tongue and floor of mouth in Group I (n=10), while in Group II, the resection involves tongue base, oral floor and lateral wall (n=6) and in Group III, the resection involves oral tongue, tongue base, oral floor and lateral wall (n=11). Immediate reconstruction was performed with a three-dimensional anterolateral thigh tailored according to the defect. Functional outcome was evaluated using the University of Washington-Quality of Life Questionnaire.

**Results:** The Postoperative functional evaluation showed no significant differences between the three groups for the pain, appearance, activity, recreation, chewing, taste, speech, and shoulder domains. However, there was a significant difference between the groups for the swallowing, anxiety and mood domains and very highly significant difference in the saliva domain with the worst results in Group II.

**Conclusion:** The four-lobed anterolateral thigh flap is reliable reconstructive technique for various complicated three-dimensional tongue and oropharyngeal defects and it can achieve reproducible good functional results. However, further refinement is required to deal with lower saliva production in Group II patients.

**Key Words:** Tongue cancer – Oropharyngeal reconstruction – Anterolateral thigh flap – Quality of life questionnaire – Functional outcome.

### INTRODUCTION

Cancer of the oral cavity and oropharynx can create devastating damage to patients by interfering

with the critical vegetative functions of the patient. Speech, swallowing, chewing, taste, and salivation can be compromised either by the tumor or after tumor resection. Patients who develop oral cavity cancer often present with late stage disease which requires radical surgery. Resection of tongue and oropharyngeal cancers can result in a quite disturbing post-resection intraoral defect with possible interference with speech and feeding. That's why the concept of immediate reconstruction following tumor resection was introduced in as early as 1951 and has been considered the gold-standard treatment for oral cavity cancers [1]. However, reconstruction of such defects is usually challenging because of the critical role of this area both esthetically and functionally [2].

The reconstructive surgeon should consider not only the anatomical coverage of the defect, but also the restoration of the lost function. Flap design and inset techniques play an important role in optimizing the functional outcome and improving global patients' quality of life. An ideal reconstruction should mimic the missing tissue with regard to structure and tissue characteristics. Moreover the reconstruction should restore the unique three-dimensional geometry of this important area. So flap shaping and design play an important role in the functional results and in improving patient's quality of life [3]. A geometric design of the free anterolateral thigh flap was proposed and published in 2008 to address all these important points concerning the reconstruction of such oral and oropharyngeal defects [4].

As the oral cavity is responsible for many different functions, such as swallowing and speech, a functional deficit leads to obvious changes in patients' Quality of Life (QOL) [5]. Therefore, assessment of the patient's postoperative QOL has become an aim of the therapeutic approach and the endpoint of the evaluation of head and neck

methods of reconstruction [6]. This study was designed to assess the quality of life in patients who were operated upon for tongue and/or oropharyngeal tumors and the three-dimensional antero-lateral thigh flap was used to reconstruct the defects resulted after tumor resection.

## PATIENTS AND METHODS

This study was done from July 2013 to March 2015 on patients admitted to Nagoya University Hospitals, Nagoya University, Japan. Twenty-seven patients, with oral cavity and oropharyngeal cancer who underwent ablative radical resection of malignant tumors and immediate microsurgical reconstruction with free Anterolateral Thigh (ALT) flaps, were enrolled in our study.

*Mapping of the defect:* After tumor resection and neck dissection, the resulting defect was classified into one of three types according to the extension of resection, Type I, the resection involves oral tongue and floor of mouth (n=10), Type II, the resection involves tongue base, oral floor and lateral wall (n=6) and Type III, the resection involves oral tongue, tongue base, oral floor and lateral wall (n=11).

*Flap design:* The anterolateral thigh flap was designed and harvested as described by Yagi et al., in 2008 [7] and it consists of four lobes Fig. (1), Lobe A: Reconstructs the defects of the tongue between tip of tongue and the circumvallate papilla; Lobe B: Reconstructs the tongue base defect; Lobe C: Reconstructs oral floor defect and Lobe D; reconstructs lateral pharyngeal wall defects Fig. (1).

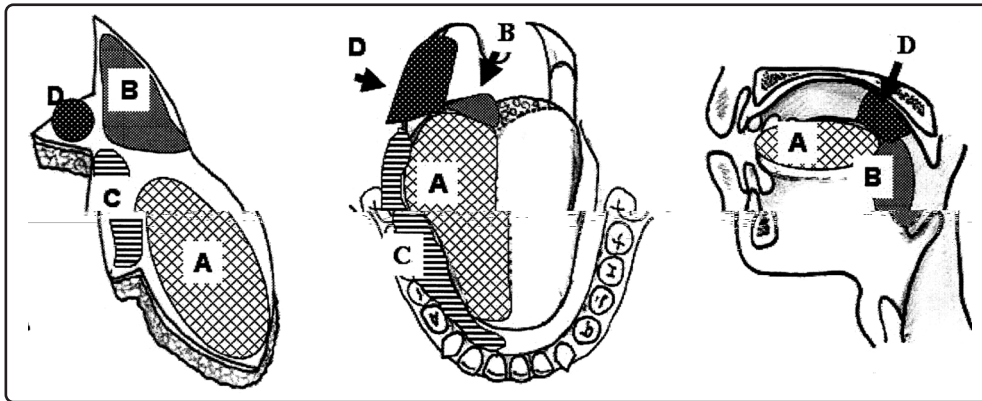


Fig. (1): A diagram illustrating the relationship between the four-lobed design of the ALT flap and the intraoral and pharyngeal defects. The flap basically consists of four lobes: Lobe A: Reconstructs the defects of the tongue between tip of tongue and the vallate papilla; Lobe B: Reconstructs the tongue base defect; Lobe C: Reconstructs oral floor defect; Lobe D: Reconstructs lateral pharyngeal wall defects (Yagi et al., 2008).

*Patient groups:* The patients cohort were divided into three group according to ALT template used for each defect: Group I (n=10): We use lobe (A + C) to reconstruct defect in oral tongue and ipsilateral oral floor (type I defect). Group II (n=6): We use lobe (B + C + D) to reconstruct defects in tongue base, oral floor and lateral pharyngeal wall (type II defect). Group III (n=11): We use lobes (A + B + C + D) to reconstruct defect in oral tongue, oral floor, tongue base and lateral pharyngeal wall.

*Clinical and functional evaluation:* The clinical evaluation included: Flap size, type of neck dissection, recipient vessels, donor site morbidity, starting of oral intake and associated complications at the operative site. The functional evaluation was performed using the self reported University of Washington-Quality of Life Questionnaire (UW-QOL) to assess and compare the outcome among

the three groups. The UW-QOL provides a broad measure of QOL for patients with head and neck cancer with good acceptability, practicality, validity, reliability, and responsiveness [4]. The questionnaire is filled in the out-patient clinics during regular follow-up visit at least six months post-operative. It is composed of 15 domains: 12 address disease-specific areas (pain, appearance, activity, recreation, swallowing, chewing, speech, shoulder, taste, saliva, mood, and anxiety) and 3 are global questions. Each of the 12 disease-specific questions has 3 to 5 response options. The domains are scored on a scale ranging from 0 (worst) to 100 (best). There are 2 composite scores: That for "physical function" and another for "social function". The physical function score is calculated as the average of 6 domain scores: Chewing, swallowing, speech, taste, saliva, and appearance. The social function is also calculated as the average of 6 domain scores: Anxiety, mood, pain, activity, recreation, and shoul-

der function. There are also 3 "global QOL" items. Besides the 15 questions, patients were asked to choose no more than 3 of the 12 disease-specific domains that had been the most important to them in the preceding 7 days. We scored the individual domains in accordance with the UW-QOL guidelines. The standard UW-QOL is available as a Japanese version and has been validated for a Japanese population.

*Statistical analysis:* Data were recorded, and then analyzed with the help of the Statistical Package for the Social Sciences (SPSS version 16.0, SPSS Inc., IBM). Probabilities of less than 0.05 were accepted as significant.

## RESULTS

There were 20 males (74.1%) and 7 females (25.9%), with an average age of 55.85 years (range, 25-81 years). Donor site was closed primarily in all patients except in two (7.4%) in Group III where a skin graft was needed for coverage and it healed with no reported complications. Six patients, two patients in each group, had received both chemotherapy and radiotherapy for tumor downstaging preoperatively. Seventeen patients had received post-operative radiotherapy; 6 (60%) in Group I, 4 (66.6%) in Group II and 7 patients (63.6%) in Group III.

*Oncological data:* As shown in Fig. (2), the site of the primary tumor was located in: Oral tongue in 11 patients (40.74%), floor of mouth in 7 patients (25.9%), tongue base in 2 patients (7.4%), lateral wall of oropharynx in 6 patients (22.2%), and tonsillar fossa in 1 patient (3.7%). Pathological findings were Squamous Cell Carcinoma (SCC) in 25 cases (92.59%) and Adenoid Cystic Carcinoma (ACC) in 2 cases (7.4%). Based on TNM staging system: 11 (40.7%) patients had T2 cancer, 6 (22.2%) had T3 cancer, and 10 (37.1%) had T4 cancer. Fourteen patients (51.9%) had N0, 7 patients (25.9%) had N1 and 6 patients (22.2%) had N2. None of the patients presented with distant metastases at the time of surgery.

*Operative data:* A free Anterolateral Thigh flap (ALT) with four lobes design was used in all patients to reconstruct post-ablative oral cavity and oropharyngeal defects Figs. (3,4). The average ALT flap size in Group I and Group II defect was 5.6 X 6.7cm, and 5.8 X 9.5cm, respectively, with the largest ALT size was found in Group III 10 X 14cm. Twenty-two flaps (81.4%) healed uneventfully without any problems, while two flaps (7.4%) suffered a small area of wound dehiscence and

healing by secondary intention. Two patients (7.4%) suffered local wound infection which was managed successfully with local wound management and antibiotics. Only one patient (3.7%) suffered from lymphorrhea that lasted about 6 weeks to resolve. There was no hematoma, seroma or fistulas at flap inset site and no revisions of microsurgical anastomosis were necessary. The defect was closed primarily with the flap in 25 patients (92.5%), while in 2 patients (7.4) of Group III, a skin graft was used to complete the closure of the defect. Microvascular arterial anastomosis were done to using the transverse cervical artery as a recipient vessel in 7 cases (25.59%), the superior thyroid artery in 19 cases (70.3%) and facial artery in one case (3.7%). For venous anastomosis, the external jugular vein was used in 14 cases (51.8%) and internal jugular vein in 13 cases (48.1%). All the 27 patients underwent neck dissection: Radical neck dissection in 3 patients (11.1%), modified radical neck dissection in another 3 patients (11.1%), supraomohyoid neck dissection in 14 patients (51.8%) and superior jugular neck dissection in 7 patients (25.9%). Recovery time: The average time for resumption of oral alimentation was 20.00, 19.83, and 20.81 days for Group I, II, and III respectively.

*Functional evaluation:* In total of 27 patients, the postoperative function was largely satisfactory Fig. (5). The average score of total global QOL for Group I ( $969.40 \pm 78.93$ ) and III ( $974.45 \pm 159.23$ ) was almost equal but the worst score was found in Group II patients ( $779.50 \pm 158.00$ ). There were no significant differences between the three groups for the pain, appearance, activity, recreation, chewing, taste, speech, and shoulder domains. However, there was a significant difference between the groups for the swallowing and anxiety domains ( $p < 0.05$ ), a highly significant difference ( $p < 0.001$ ) between groups in the mood domain and a very highly significant difference ( $p < 0.0001$ ) in the saliva domain Fig. (6).

In swallowing assessment, patients had good swallowing score in Group I (20% of patients could swallow as before and 80% of patients could not manage certain solid food) and Group III (27.2% of patients could swallow as before and 72.7% could not manage certain solid food) than in Group II (66.6% of patients could not manage certain solid food and 33.3% remained on a liquid diet). The mean score of swallowing domain in Group I, II and III was ( $73.60 \pm 13.91$ ,  $55.66 \pm 17.55$  and  $76.00 \pm 15.41$ ) respectively and there was significant difference in swallowing function among the three groups ( $p < 0.04$ ).



In saliva domain score assessment, 10 patients (37%) had normal saliva, 9 patients (33.3%) had less saliva than normal but still enough, and 8 patients (29.6%) patients have too little saliva. 60% of patients in Group I had normal saliva and 40% had less saliva than normal but still enough and in Group III: 36.3% of patients had normal saliva, 45.5% had less saliva than normal but still enough and the rest of patients had too little saliva, however in Group II: 83.3% of patients had too little saliva. The mean score of saliva domain in Group I, II and III was ( $86.80 \pm 17.04$ ,  $38.67 \pm 13.88$  and  $72.81 \pm 25.09$  respectively, with a highly significant difference among the three groups ( $p < 0.0001$ ).

The mean scores of mood and anxiety domains were also worst in Group II with a significant difference among the three group ( $p < 0.01$ ).

*In speech domain assessment:* Six patients (22.2%) achieved normal speech, 15 patients (55.5%) achieved intelligible speech that can be understood through phone, and 6 patients (22.2%) had slurred speech that can be only understood by family member. The mean scores of speech domain in Group I, II and III were ( $76.80 \pm 22.48$ ,  $61.17 \pm 25.28$  and  $60.72 \pm 20.30$ ) respectively, with no significant difference among the three groups ( $p = 0.22$ ). None of the patients required a permanent tracheostomy.

Taste sensation score was worst in Group II with 66.6% of patients could not taste most foods normally with a mean score of  $66.83 \pm 21.18$ . Although patients in Group I and Group III had a better taste score,  $76.80 \pm 22.48$  and  $85.00 \pm 17.23$  respectively, however there was no significant difference in taste function among the three groups ( $p = 0.77$ ). Also the mean scores for chewing and mastication function were ( $75.80 \pm 26.35$ ,  $55.50 \pm 39.0$  and  $77.27 \pm 26.11$  for Group I, II and III respectively, with no significant difference among the three groups ( $p = 0.32$ ).

There were no significant differences between the three groups for the pain, appearance, activity, recreation, chewing, taste, speech, and shoulder domains.

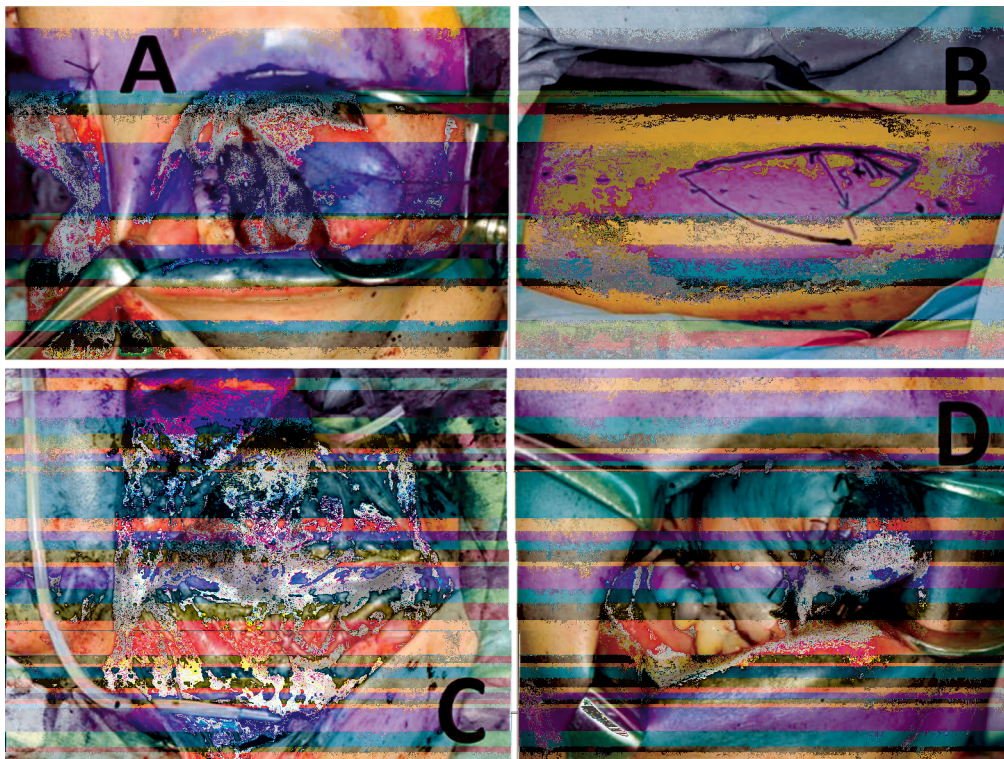


Fig. (3): (A) Intraoperative photograph of a patient of Group I, the oral defect consists of the right half of the oral tongue and oral floor; (B) ALT flap was harvested and designed to have lobes A and C; (C) The flap pedicle was anastomosed to the superior thyroid artery; (D) Intraoral view immediately postoperatively.






Fig. (4): (A) Intraoperative photograph of patient of Group III, the oral defect consists of the right half of the oral tongue, tongue base, oral floor and lateral wall; (B) ALT flap was harvested. Flap design consist of lobes A,B,C,D; (C) After the flap was harvested; (D) The flap pedicle was anastomosed to the superior thyroid artery; (E) Intraoral view post-operatively.

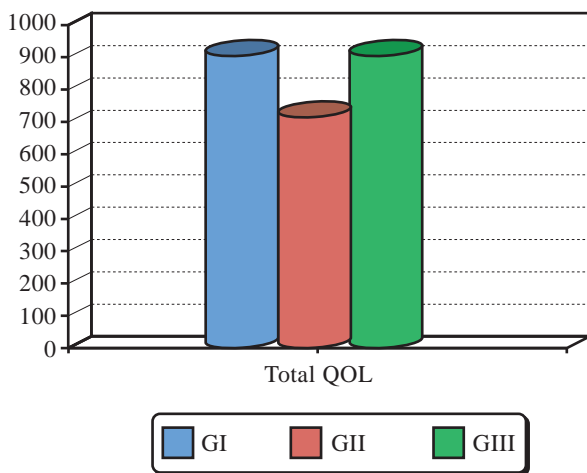


Fig. (5): A graph showing the overall total QOL of the three groups of the study with the significant difference between Group II and the other two groups.

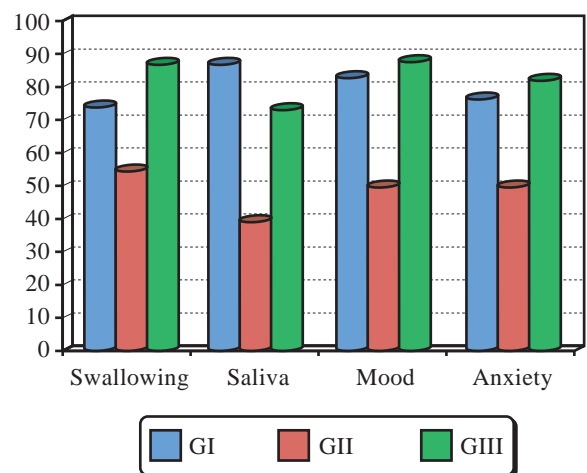


Fig. (6): A graph showing the mean score in swallowing, saliva, mood and anxiety domains in the study groups.

**DISCUSSION**

In the past, surgical options largely followed the reconstructive ladder, with widespread use of primary closure and skin grafts. Over time, many

local and regional flaps were introduced to address the reconstruction like, the deltopectoral flap [8], pectoralis major myocutaneous flap [9], and latissimus dorsi myocutaneous flap [10] or the trapezius islandized pedicle flap [11]. Such technique allows

good covering potential and filling of dead space but they fail to restore good functional outcomes due its tethering effect by its pedicle which restricts flap free mobility. In addition their thick, rigid skin paddle does not provide a pliable intraoral lining and difficult to modify to fit to the tongue [12].

The Anterolateral Thigh flap (ATL) has become a standard procedure in reconstructive microsurgery. It is frequently used now for head and neck reconstruction, largely replacing the radial forearm flap in reconstruction of tongue and intra-oral defects. Flap dissection and preparation of the recipient area can usually be performed simultaneously by two teams. Additional advantages include the low donor site morbidity, the different possibilities of tissue composition, the long vascular pedicle and the flap can be adapted to three-dimensional intraoral defects [13]. Furthermore Li and colleagues found that patients reconstructed with free anterolateral thigh perforator flaps had better quality of life score especially in appearance, shoulder function, and social functioning domain than patients who had undergone radial forearm free flap reconstruction, and this should be considered for future surgical planning [14].

Very little has been reported in the literature for reconstruction of combined oral cavity and oropharyngeal defects which can include both oral tongue, tongue base defect, together with oral floor and lateral pharyngeal walls defects. In 2003, Lew et al., in described a technique for oropharyngeal reconstruction using a unique design of radial forearm flap. The basic concept of their design is to divide the flap into three parts, including the oral tongue, the oral floor, and the soft palate [15]. However, insufficient attention was paid to importance of tongue base defect. In our study, we classified our patients into three groups according to the extent of resection and resulting defect. In Group I patients the defect was in oral tongue and ipsilateral oral floor (type I defect), we applied the bi-lobed flap design to this group of patients. Group II patients had defects in tongue base, oral floor and lateral pharyngeal wall (type II defect), we applied a tri-lobed flap design for reconstruction. For reconstruction of Group III patients, who had a combined defect in oral tongue, oral floor, tongue base and lateral pharyngeal wall (type III defect), we applied quadri-lobed ALT flap as described by Yagi and colleagues [7].

A bi-lobed flap was designed to reconstruct the postresection defects in patients of Group I, one lobe replaced the oral tongue and the other one reconstruct the mucosal layers of the oral floor

defect. Historically the bi-lobed design was introduced by Urken et al., in 1994, he used a radial forearm flap with bi-lobe pattern with one lobe to reconstruct the mobile tongue, while the second lobe was used to resurface the floor of mouth [16]. As the relationship between the oral tongue and the floor of mouth is important in maintaining tongue mobility, attempts should be made to reconstitute a sulcus between the tongue and the mandibular alveolus to prevent or minimize tethering of the tongue and allowing optimum postoperative rehabilitation of speech and swallowing [17]. To enhance tongue mobility, Yagi recommend to keep the angle between the two lobes ~30 degrees and to maintain the lobe used for oral floor reconstruction slightly shorter than oral tongue lobe [7]. This modified bi-lobed design was applied to Group I of our patients with improved postoperative global quality of life.

QOL has become an integral part of assessing the outcome of treatment for patients with oral cancer. As the oral cavity is responsible for many different functions, such as chewing of food, swallowing, production of saliva, speech, and breathing, a functional deficit leads to obvious changes in patients' QOL [5]. The changes in quality of life after head and neck tumor resection and reconstruction can be demonstrated through a specifically designed questionnaire. A relatively large number of specific questionnaires for the head and neck exist [18]. This questionnaire was first described by Hassan and Weymuller in 1993 and has been extensively validated, particularly in oral cancer patients treated by primary surgery [19]. The UW-QOL is considered broad based, assesses disease specific functional status, and is suitable for routine low cost assessment. It has also been considered to be best suited to patients undergoing primary surgery and is the most common questionnaire used by clinicians in a survey of the British Association of Head and Neck Oncologists. The current version is version 4, which has additional mood and anxiety domains added [4].

Comparing the functional outcomes and global quality of life between the three groups using UW-QOL questionnaire, we found that xerostomia and decreasing saliva production play an important factor in decreasing overall functional result in Group II patients. Xerostomia also affect another function in the oral cavity especially ease of swallowing. Although in Group II patients we reconstruct the tongue base defect and adjacent lateral pharyngeal wall using our tri-lobed ALT flap design, the swallowing scores is significantly lower in these patients group.



**Conclusion:**

The four-lobed ALT flap can be used for reconstruction of various complicated three-dimensional tongue and oropharyngeal defects. We could achieve reproducible functional results with about 77% of our patient could achieve intelligible speech and more than 92% of our patients can eat most of solid food without difficulty which improve patients post-operative global quality of life. However, further refinement is required to deal with lower saliva production that play an important factor in decreasing overall functional result that found in Group II patients.

**REFERENCES**

- 1- Edgerton M.T., Jr.: Replacement of lining to oral cavity following surgery. *Cancer*, 4 (1): p. 110-9, 1951.
- 2- Bianchi B., Ferri A., Ferrari S., Copelli C., Boni P., Ferri T. and Sesenna E.: The free anterolateral thigh musculocutaneous flap for head and neck reconstruction: One surgeon's experience in 92 cases. *Microsurgery*, 32 (2): p. 87-95, 2012.
- 3- Caliceti U., Piccin O., Sgarzani R., Negosanti L., Fernandez I.J., Nebiaj A., Contedini F., Cipriani R. and Ceroni A.R.: Surgical strategies based on standard templates for microsurgical reconstruction of oral cavity and oropharynx soft tissue: A 20 years' experience. *Microsurgery*, 33 (2): p. 90-104, 2013.
- 4- Rogers S.N., Laher S.H., Overend L. and Lowe D.: Importance-rating using the University of Washington quality of life questionnaire in patients treated by primary surgery for oral and oro-pharyngeal cancer. *Journal of cranio-maxillo-facial surgery: Official publication of the European Association for Cranio-Maxillo-Facial Surgery*, 30 (2): p. 125-32, 2002.
- 5- Chandu A., Smith A.C. and Rogers S.N.: Health-related quality of life in oral cancer: A review. *J. Oral. Maxillofac. Surg.*, 64 (3): p. 495-502, 2006.
- 6- Bozec A., Poissonnet G., Chamorey E., Casanova C., Laout C., Vallicioni J., Demard F., Peyrade F., Follana P., Bensadoun R.J., Benezery K., Thariat J., Marcy P.Y., Sudaka A., Weber P. and Dassonville O.: Quality of life after oral and oropharyngeal reconstruction with a radial forearm free flap: Prospective study. *J. Otolaryngol. Head Neck Surg.*, 38 (3): p. 401-8, 2009.
- 7- Yagi S., Kamei Y., Nakayama B., Toriyama K. and Torii S.: A new design for free flap reconstruction of the tongue and oropharynx. *J. Reconstr. Microsurg.*, 24 (3): p. 211-9, 2008.
- 8- Bakamjian V.Y.: A Two-Stage Method for Pharyngoesophageal Reconstruction with a Primary Pectoral Skin Flap. *Plast. Reconstr. Surg.*, 36: p. 173-84, 1965.
- 9- Ariyan S.: The pectoralis major myocutaneous flap. A versatile flap for reconstruction in the head and neck. *Plast. Reconstr. Surg.*, 63 (1): p. 73-81, 1979.
- 10- Quillen C.G., Shearin J.C., Jr. and Georgiade N.G.: Use of the latissimus dorsi myocutaneous island flap for reconstruction in the head and neck area: Case report. *Plast. Reconstr. Surg.*, 62 (1): p. 113-7, 1978.
- 11- Chen W.L., Yang Z.H., Li J.S. and Huang Z.Q.: Reconstruction of the tongue using an extended vertical lower trapezius island myocutaneous flap after removal of advanced tongue cancer. *British Journal of Oral & Maxillofacial Surgery*, 46 (5): p. 379-82, 2008.
- 12- Koh K.S., Eom J.S., Kirk I., Kim S.Y. and Nam S.: Pectoralis major musculocutaneous flap in oropharyngeal reconstruction: Revisited. *Plast. Reconstr. Surg.*, 118 (5): p. 1145-9, 2006.
- 13- Wei F.C., Jain V., Celik N., Chen H.C., Chuang D.C. and Lin C.H.: Have we found an ideal soft-tissue flap? An experience with 672 anterolateral thigh flaps. *Plast. Reconstr. Surg.*, 109 (7): p. 2219-26; discussion 2227-30, 2002.
- 14- Li W., Xu Z., Liu F., Huang S., Dai W. and Sun C.: Vascularized free forearm flap versus free anterolateral thigh perforator flaps for reconstruction in patients with head and neck cancer: Assessment of quality of life. *Head Neck*, 35 (12): p. 1808-13, 2013.
- 15- Lew D.H., Choi E.C. and Tark K.C.: Standardization of flap design for oropharyngeal reconstruction after cancer ablation surgery. *Yonsei. Med. J.*, 44 (6): p. 1078-82, 2003.
- 16- Urken M.L. and Biller H.F.: A new bilobed design for the sensate radial forearm flap to preserve tongue mobility following significant glossectomy. *Arch. Otolaryngol. Head Neck Surg.*, 120 (1): p. 26-31, 1994.
- 17- M.J. DelGaudio and Chen A.Y.: Oral Cavity and Oropharynx, in *Anatomic Basis of Tumor Surgery*, W.C. Wood, C.A. Staley, and J.E. Skandalakis, Editors., Springer Berlin Heidelberg: Berlin, 2010.
- 18- Gliklich R.E., Goldsmith T.A. and Funk G.F.: Are head and neck specific quality of life measures necessary? *Head Neck*, 19 (6): p. 474-80, 1997.
- 19- Hassan S.J. and Weymuller E.A.: Assessment of Quality-of-Life in Head and Neck-Cancer Patients. *Head and Neck-Journal for the Sciences and Specialties of the Head and Neck*, 15 (6): p. 485-96, 1993.