

Dermofascial Suspension of the Breast in Cases of Gigantomastia

MOSTAFA AWAD, M.D.; IMAN M. AL-LEITHY, M.D.; MOHAMED M. ABD-AAL, M.D. and NADA MAHMOUD, M.Sc.

The Department of Plastic Surgery, Faculty of Medicine, Ain Shams University.

ABSTRACT

Between February 2004 and March 2005, 20 patients (40 breasts) with gigantomastia underwent reduction mammoplasty using Findlay's technique with dermofascial suspension of the medially-based dermoglandular pedicle of the breast in a trial of prevention of the postoperative sagging (bottoming out). We used the anterior layer of the superficial fascia with the deep dermis as one unit to suspend the remaining breast tissue. We've got encouraging results with a follow up period of six months to one year. There was no bottoming out or sagging of the breast tissue. The aesthetic shape of the breast was satisfying for both the authors and the patients. The harvesting of the fascial flap is easy giving versatile, safe and reliable tissue which avoids dismerits and problems of the other suspension techniques.

INTRODUCTION

While descriptions of reduction mammoplasty can be seen as early as Paulus of Aegina (625-690 A.D), not until the late nineteenth century was emphasis placed on correcting the post-operative sagging (bottoming out) which follow most of the techniques of breast reduction and mastopexy. In recent years, refinements of the aesthetic results of reduction mammoplasty has become an important goal in plastic surgery. Several reduction techniques have been championed in an attempt to accomplish the ideal aesthetic result, an appropriate shape, a preserved anatomic and functional unit as well as to prevent postoperative complications. Long lasting aesthetic results in all degrees of breast ptosis and hypertrophy is the work horse of all techniques. Mammary ptosis is a pathophysiologic expression of the rupture of elastic tissue fibers of the integument following glandular hypertrophy. As a consequence, the integument does not carry out its supporting function anymore, thus causing aesthetic deformity [1-6]. In a trial of overcoming such a complication, lots of trials and procedures had been evolved through different ideas. Dermal suspension, with or without glandular reshaping, is a classic description of mastopexy (and breast reduction) but it is always unreliable, resulting in inad-

equately long term outcome [7-10]. Other techniques depend on the application of foreign materials as polyester mesh or silicone supporting sheet to prevent the gravitational effect upon the newly assembled breast [11-13]. However, they did not find a good acceptance among surgeons [11]. Others used suspension sutures to counteract the effect of weight of the remaining breast tissue on the integument [14]. However, many authors were against this method [13,17]. In 1990, Ted Lockwood presented the superficial fascial system (SFS) as the primary structural support of the skin and fat of the body [15]. Breast tissue is encased by this system with fibrous bands extending through the breast tissue [15]. So, SFS, according to Ted Lockwood, is a connective tissue network that extends from the subdermal plane to the underlying muscle fascia. It consists primarily of one to several thin, horizontal membranous sheets separated by varying amounts of fat with interconnecting vertical or oblique fibrous septae [16]. Bostwick, in 1990, showed that the anterior layer of superficial fascia is near the dermis but is indistinct from it [17]. However, in both anatomic and clinical study presented by Ted Lockwood in 1991 & 1999 respectively [15,16,18], he stated that the anterior layer of the superficial fascia is an indistinct fibrous-fatty layer that is separate from the dermis and the breast tissue. This layer can be used for suspension of high tension wound repair of the breast contouring procedures [18]. Furthermore, we studied the anatomy and histology of the superficial fascia of the breast in patients who underwent reduction mammoplasty and mastopexy procedures [19]. We found it a distinct layer of collagenous bundles, interrupted by some elastic fibers, in a thickness ranging from 1.5 to 3.0mm (with a mean of 2.0mm) which are parallel to the skin surface. We reported the absence of subdermal space between the fascia and the caudal border of the dermis. Anatomically, we could dissect the superficial layer of the superficial fascia, together with the deep layer of the

dermis as one unit. So, the idea of using SFS for suspension of the remaining breast tissue, to reduce the incidence of post-operative ptosis and sagging that provides more secure, predictable and long lasting breast contour needs further clinical study.

PATIENTS AND METHODS

Reduction mammoplasty using dermofascial suspension of the pedicle was performed on 20 patients (40 breasts) with a follow up period ranging from 6 to 12 months. The primary indication is hugely enlarged breasts resulting mainly from familial factors, weight gain or fibroadenosis. This age of the patients ranged from 19-50 yrs. The patient skin texture was determined by the skin pinch test. Presence of striae and scars also was noted for spreading and healing qualities. Accordingly, we rate the skin elasticity into poor, fair or good. Most patients have fair elasticity. The degree of ptosis was severe (the transposition of the areola-nipple complex ranged from 10 to 17cm).

Planning:

The patient is marked in a standing position. The breast meridian, the patient meridian, and the inframammary fold (IMF) are marked. The nipple position is marked just at the level of the IMF (because the breast bottoms less in this technique). Then we draw the Mosque-type pattern around the nipple. The lateral and medial extent of the resection are marked with a breast displacement technique. The medial and lateral lines are curved and connected to form the most inferior part of the incision. The length of the vertical line above the IMF depends on the size of the breast. It ranges from 5 to 7cm. The circumference of the nipple areola complex is marked with a 50-mm diameter maleable ruler. The medial pedicle is a minimum of 10cm in width (up to 13cm). Then we mark the fascial flap in a rectangular fashion, the base of which is the inferior border of the medial dermoglandular pedicle with the same length of the pedicle Fig. (1).

Surgical Technique:

The pedicle is de-epithelialized first. Then we de-epithelialize the pre-marked fascial flap (leaving only the very deep layer of the dermis). An inferior dermofascial flap (including the deep layer of the dermis and the anterior layer of the superficial fascia as one unit) is then developed along the entire length of the medial pedicle in a width of 5 to 7cm and dissected off the lower parenchymal pole of the breast Fig. (2). The inferior tissue is completely resected just deep to the dermis and to the chest wall fascia. No tissue is left at the bottom of the breast. Lateral and superior breast tissue is

resected as needed to achieve the desired breast size. In most of our cases, we did minimal excision from the superior portion to get an upper pole fullness. After hemostasis, we insert the areola in place. Then, the breast tissue is retracted as high as possible to suspend the dermofascial flap at the 3rd intercostal space taking about three to four stitches with 2-0 PDS (Ethicon) or nylon sutures Fig. (3). A corner suture is placed at the base of the Mosque incision with 2-0 nylon suture then we complete the closure of the vertical line of the breast in layers (buried dermal sutures with 2-0 vicryl and running subcuticular 2-0 nylon sutures). A transverse incision is sometimes needed specially in very huge breasts to help in getting a good final result. We always use suction drains which are usually removed in 4 to 5 days.

RESULTS

Reduction mammoplasty using dermofascial suspension was performed on 20 patients (40 breasts) giving us preliminary encouraging results. Photography was taken preoperatively and post-operatively at 12w, 6 months and 12 months. The weight excised ranged from 1500-2800gm/breast except in one case in which we excised 900gm per breast. The results, as regards the incidence of sagging, are good to excellent. No bottoming out in all cases. Upper pole fullness is maintained with a perky breasts. Patients' satisfaction was excellent Fig. (4) through (13). We didn't encounter any seroma (or hematoma) which denotes good vascularity of the dermofascial flap. However, we had one case of bilateral partial loss of the areolae due to accidental undermining of the nipple-areola complex which needed reconstruction of both areolae by free grafts. Three cases needed revision of the scars being wide and hypertrophic. Dog-ear revision was performed in three cases (out of sixteen) in whom a vertical-scar closure was done.

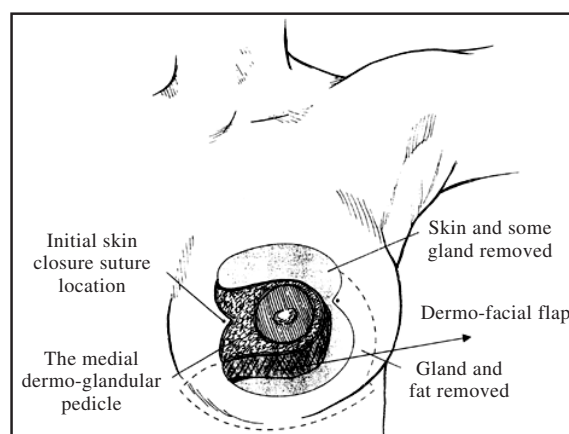


Fig. (1): Schematic representation of the operative plan for medial pedicle breast reduction with harvesting of the dermo-facial flap.



Fig. (2): A superiorly-based dermo-fascial flap is dissected off the skin and the lower parenchymal breast pole.



Fig. (3): Insertion of the dermo-fascial flap at the 3rd intercostal space.





Fig. (4): A 24-year-old patient with severe mammary hypertrophy. 1700gm of breast tissue has been resected from each gland (Above) frontal and lateral preoperative views (Below) maintained projections 6 months postoperatively.




Fig. (5): A 45-year-old lady with severe mammary hypertrophy. 2500gm of mammary tissue has been resected from the right and 2400gm from the left side (Above) frontal and lateral preoperative views (Below) the same projections without bottoming out 1 year postoperatively.




Fig. (6): A 19-year-old patient with severe mammary hypertrophy. 1900gm of mammary tissue has been resected from the right and left breast (Above) frontal and lateral preoperative views (Below). No bottoming out 1 year postoperatively.

DISCUSSION

In the last decades, lots of techniques for reduction mammoplasty have been evolved which attempted to obtain the best and long lasting aesthetic results and to decrease the incidence of post-operative complications specially in gigantomastia. Post-operative bottoming out, as a result of sagging of the remaining breast tissue below the submammary fold and hence apparent upward migration of the nipple-areola complex, is a complication which hinder good cosmetic results. It leads to dissatisfaction of both the surgeon and the patient. In an effort to overcome this complications, many authors tried to suspend the remaining breast tissue through variable procedures so as to minimize the effect of gravity and weight of the breast. Dermal suspension had been tried [6-10] with some success as the assembled breast shape does not change significantly with time. However, this technique is more suitable for small sized breasts or mastopexy because the dermis is usually unreliable, as the skin ability to support the breast tissue depends on the individual quality of the skin and the age of the patient. Alternative suspension techniques include dermal straps to pectoralis muscle [9] and glandular-subcutaneous sutures [20,21]. However, dermal suspension is not much valid specially for huge breast size. In Benelli's technique, suspension included circular non-absorbable dermal sutures with glandular shaping which is an inconsistent anchor [22]. Wuringer, 1999 described a horizontal fibrous septum originating from the pectoral fascia along the level of the fifth rib, heading towards the nipple. It is a mesentery-like structure carrying the nerve and blood supply to the nipple areola complex. At its borders the septum curves upwards into a vertical medial and lateral ligament, which attach the breast to the lateral edge of the pectoralis minor. These ligaments, with the septum, form a sling of dense connective tissue that acts as a brassiere-like suspensory system [23].

The author demonstrated that this suspensory connective tissue is able to lift and shape the breast through tightening of the medial and lateral ligaments [23]. However, dissection of those structures is difficult, needs experience and time-consuming. In addition, loss of elastic fibers within them, as in the course of aging, may contribute to loss of their supporting function as well as the shape of the breast [23]. She also stated that the force of gravity is the major problem that might need more anchoring of the pedicle to the thoracic wall and more tightening of the ligaments. Those two procedures needs longer follow up because more

anchoring means more foreign materials and more tightening can lead to complications [23]. Application of polygalactine or mixed (polygalactine and polyester) mesh was used to provide a more resistant lining structure [13]. This technique proposed that this mesh allows the operated breast to preserve the ideal shape assembled during surgery and allows cutaneous retraction of the skin as well as cicatrizations. The author suggested that: This method holds the ideal shape avoiding the effect of the gravitational force caused by the weight of the breast. However, the use of this mesh results in a firm structure, avoiding the accommodation of the assembled breast that would cause a consequent loss of the anterior projection of the mammary cone [13]. Bustos, [11], used a silicone supporting sheet to replace the injured integument in order to prevent recurrences. However, the implantation of a foreign body in the breast was not accepted among surgeons because of expected complications as infection, seroma and interference with radiologic examination [11]. Our study presents a different method for suspension of the dermoglandular pedicle, specially in cases of gigantomastia in which the rate of post-operative sagging is much higher because the remaining breast tissue is still voluminous. The role of the superficial fascia of the breast in maintaining the breast contour and shape and its use for suspension of the parenchyma is not published previously. Based on our previous anatomic and histologic study of the superficial fascial system of the breast [19] together with the work of Ted Loockwood [15,16,18] on the SFS, we used it, with the deep dermis, in suspension as an alternative procedure to the methods used before. The use of the dermis is to support the fascia because it is sometimes, tiny and weak layer in gigantomastic breasts. It could not be separated from the dermis easily. We dissect it as a dermo-fascial unit taking the very deep layer of the dermis together with the anterior layer of the superficial fascia covering the gland. We anchor it as a shelf carrying the pedicle preventing its descent and hence post-operative sagging (bottoming out). The use of SFS as a supporting layer and for suspensory function avoids the introduction of a foreign material inside the breast tissue avoiding its hazards. So, the use of SFS is superior to the application of materials as the polyester mesh or the silicone sheet [11,13]. It is also superior to the use of dermis alone for suspension as the dermal suspension is not reliable because it depends on the skin quality and texture. Most of our patients lack good skin tone even in younger age group having striae and severe ptosis. Hence, the idea of using the dermis alone is not expected to give long lasting results

specially in those having bad skin texture preoperatively. Therefore, incorporation of the fascia with the dermis strengthens the dermis preventing its overstretch which keep the breast tissue as assembled intraoperatively. Actually dissection of the fascia is easy and does not consume time, adding about fifteen minutes to the timing of each breast. We did 20 cases (40 breasts) who complained of severe hypermastia. The excised weight per each breast ranged from 1500gm to 2800gm which is considered, by definition, a gigantomastia. The follow up period is from six months to one year which gave us a preliminary encouraging results. The result analysis both by photography and the authors was satisfying regarding the absence of sagging (bottoming out) in the follow up period. In spite of using this method for suspension of the medially-based dermoglandular pedicle, it can also be used with other pedicle designs as superior, lateral, or inferiorly-based pedicles.

REFERENCES

- 1- Webster J.P.: Mastectomy for gynecomastia through semicircular intra-areolar incision. *Ann. Surg.*, 124: 557, 1964. Quoted from Bustos A.R.: Periareolar mammaplasty with silicone supporting lamina in *Plast. Reconstr. Surg.*, 89: 646, 1992.
- 2- Arie G.: Una neuva tecnica de mostoplastia. *Rev. Lat. Am. Cir. Plast.*, 3: 22, 1957 (Quoted from Bustos A.R.: Periareolar mammaplasty with silicone supporting lamina in *Plast. Reconstr. Surg.*, 89: 646, 1992).
- 3- Dufourmentel G. and Mouly R.: Plastic mammaire par le methode optique. *Ann. Chir. Plast.*, 6: 45, 1961. (Quoted from Bustos A.R.: Periareolar mammaplasty with silicone supporting lamina in *Plast. Reconstr. Surg.*, 89: 646, 1992).
- 4- Pitanguy I.: Breast hypertrophy. In proceedings of the Second Congress of International Society of Plastic Surgeons, London, p. 509, 1959. (Quoted from Bustos A.R.: Periareolar mammaplasty with silicone supporting lamina in *Plast. Reconstr. Surg.*, 89: 646, 1992).
- 5- Marchac D. and Des Olarte G.: Reduction mammaplasty and correction of ptosis with short inframammary scar, *Plast. Reconstr. Surg.*, 69: 45, 1982 (Quoted from Bustos A.R.: Periareolar mammaplasty with silicone supporting lamina in *Plast. Reconstr. Surg.*, 89: 646, 1992).
- 6- Aufricht G.: Mammaplasty for pendulous breasts. *Plast. Reconstr. Surg.*, 4: 13, 1949 (Quoted from Loockwood T., Reduction mammaplasty and mastopexy with superficial fascial system suspension in *Plast. Reconstr. Surg.*, 103: 5, 1999).
- 7- Strombeck J. Loockwood: Mammaplasty: Report on new technique based on the two-pedicle technique. *Br. J. Plast. Surg.*, 13: 79, 1960 (Quoted from Loockwood T., Reduction mammaplasty and mastopexy with superficial fascial system suspension in *Plast. Reconstr. Surg.*, 103: 5, 1999).
- 8- McKissock P.: Reduction mammaplasty with a vertical dermal flap. *Plast. Reconstr. Surg.*, 49: 245, 1972 (Quoted from Loockwood T., Reduction mammaplasty and mastopexy with superficial fascial system suspension in *Plast. Reconstr. Surg.*, 103: 5, 1999).
- 9- Hindrer U.: The dermal brassiere mammaplasty. *Clin. Plast. Surg.*, 3: 349, 1976 (Quoted from Loockwood T., Reduction mammaplasty and mastopexy with superficial fascial system suspension in *Plast. Reconstr. Surg.*, 103: 5, 1999).
- 10- Goulian D.Jr.: Dermal mastopexy. *Plast. Reconstr. Surg.*, 47: 105, 1971 (Quoted from Loockwood T., Reduction mammaplasty and mastopexy with superficial fascial system suspension in *Plast. Reconstr. Surg.*, 103: 5, 1999).
- 11- Bustos A.R.: Periareolar mammaplasty with silicone supporting lamina *Plast. Reconstr. Surg.*, 89: 4, 1992.
- 12- Ryan J.J. Alowen: Thoracic advancement flap in breast reconstruction after mastectomy. *Plast. Reconstr. Surg.*, 70: 153, 1982.
- 13- Joa G. Sampio Goes: Periareolar mammaplasty: Double skin technique with application of polygalactine or mixed mesh. *Plast. Reconstr. Surg.*, 97: 5, 1996.
- 14- Lejour M. and Abbound M.: Vertical mammaplasty without inframammary scar and with breast liposuction. *Perspect. Plast. Surg.*, 4: 67, 1996.
- 15- Loockwood T.: Superficial fascial system (SFS) of the trunk and extremities: A new concept, presented at the 23rd Annual Meeting of the American Society for Aesthetic Plastic Surgery, Chicago, 111, April 3, 1993.
- 16- Bostwick J.: *Plastic and Reconstructive Breast Surgery*. St Louis: Quality Medical Publishing, 1990.
- 17- Loockwood T.: Superficial fascial system (SFS) of the trunk and extremities: A new concept. *Plast. Reconstr. Surg.*, 37: 1009, 1991.
- 18- Loockwood T.: Reduction mammaplasty and mastopexy with superficial fascial system suspension. *Plast. Reconstr. Surg.*, 103: 1411, 1999.
- 19- Al-Liethy I. and Emara M.: Superficial fascial system of the breast: A histologic study. *Sc. J. Al-Azhar*, 26: 2, 2005.
- 20- Pitanguy I.: Surgical treatment of breast hypertrophy. *Br. J. Plast. Surg.*, 20: 78, 1967. Quoted from Loockwood T., Reduction mammaplasty and mastopexy with superficial fascial system suspension in *Plast. Reconstr. Surg.*, 103: 5, 1999.
- 21- Lassus C.: A 30 year experience with vertical mammaplasty. *Plast. Reconstr. Surg.*, 97: 373, 1996.
- 22- Wuringer E., Mader N., Posch E. and Hall J.: Nerve and vessel supplying ligamentous suspension of the mammary gland. *Plast. Reconstr. Surg.*, 101: 1486, 1998.
- 23- Wuriger E.: Refinements of the central pedicle breast reduction by application of the ligamentous suspension *Plast. Reconstr. Surg.*, 103: 1400, 1999.