

Assessment of Distracted Bone Tolerance to Mechanical Stress, an Experimental Study on Rabbit Mandibles*

MOHAMAD F.M.A. FARAG, M.D.*; HAZEM M.M. ALI, M.D. and HASSAN A. BADRAN, F.R.C.S., F.R.C.S. Ed.

The Department of Plastic Surgery, Faculty of Medicine, Ain Shams University.

ABSTRACT

Methods of evaluation of the quality of newly formed bone following distraction osteogenesis are radiological, histological, or mechanical. Review of literature revealed only few studies about the mechanical evaluation, which has investigated this aspect only in long bones. This study has discussed the tolerance of new bone; formed by distraction of rabbit's mandible; to a gradually increasing compression force. This was done in relation to the nonoperated contralateral side as a control. Comparison to bone grafts as an alternative technique for mandibular reconstruction was also discussed. 48 New-Zealand white rabbits were selected and divided into 2 groups. In the 1st group the specimens were examined 6 weeks post-operatively. In the 2nd group, this was done at 12 weeks. The results showed that the distraction new bone could tolerate compression forces more than could the bone grafts did at any of the examination times. The differences were statistically significant.

INTRODUCTION

Report about mandibular distraction by McCarthy et al. (1992) and the wide clinical experience of Molina and Monasterio (1995). The increased popularity of that new technique came from its numerous advantages over the conventional techniques of facial skeletal reconstruction which utilized mainly bone grafts. This new technique not only avoided the donor site morbidity of bone grafts, but it also added new bone that should have the same structural characters of the original bone. It also has the advantage of simultaneous growth of the surrounding functional matrix [48-52]. For these reasons, the technique has attracted the interest of many research workers and there have been many experimental studies that investigated different aspects related to this technique and its

application to the facial skeleton, starting from Snyder et al. [13-33].

There have been many methods for evaluation of new bone quality after distraction. These included radiological [34-40], histological [17,21,41] and mechanical methods [42]. All of these studies have proved osteogenesis, after gradual distraction across the osteotomy gap. However, only few studies evaluated new bone tolerance to mechanical stress [42]. This was studied only in long bones by application of torsion loads. No previous studies were found in the literature that evaluated this aspect in the mandible. By conducting this study, our aim is to evaluate the mechanical strength of the newly formed bone after mandibular distraction, in comparison to the strength of bone grafts; as an alternative treatment modality; at certain postoperative time.

MATERIAL AND METHODS

In this study, 48 adult male New Zealand white rabbits were used. The animals were divided according to the time of sacrifice into two groups:

The First Group: Was sacrificed at 6 weeks post operatively (29 animals).

The Second Group: Was sacrificed at 12 weeks post operatively (19 animals).

Each Animal Group was Further Divided Into Two Subgroups According to the Surgical Procedure:

Subgroup (1): In which the procedure was the use of bone graft to reconstruct a created mandibular defect (a total of 22 animals; 14 + 8).

Subgroup (2): In which the procedure was mandibular lengthening by distraction (a total of 26 animals: 15 + 11).

* Presented at the 34th Annual Meeting of the Egyptian Society of Plastic and Reconstructive Surgeons Conjoint with Society Francaise De Chirurgie Plastique Reconstructive Et Esthetique, in Sharm El-Sheikh, Egypt, February 24-27, 2004.

Operative Procedures:

Anesthesia: General anesthesia was given as follows: 20 minutes before the operation, sparine 0.1 ml/kg i.m. [43] or xylazine, 5 mg/kg i.m. [45] was given as a sedative and analgesic. Then, ketamine hydrochloride, 30 mg (0.6ml)/kg i.m. that could be repeated once during surgery, combined with sparine 0.1 ml/kg [43]. In some animals; vascular access for I.V. anesthesia was done through the lateral auricular vein, after an initial i.m. combination of xylazine and ketamine [44-45]. The rate of I.V. infusion was 1mg/min ketamine and 0.1 mg/min xylazine. Then, endotracheal intubation was done to save the airway and to assist ventilation [45,46].

Operation: Subgroup (1): Skin incision about 2-3 cm/length below and parallel to the inferior border of the mandible was made. The superficial fascia, platysma were divided. The muscles covering the inferior border of the mandibular body were sharply divided. The periosteum was then incised and elevated to expose the body of the mandible. Care was taken to preserve the periosteum intact during its elevation from the buccal and then from the lingual surfaces. The site of the planned osteotomy was marked by a sterile pencil (Fig. 1-A).

A rectangular block of bone was removed from the lower half of the mandibular body, about 0.5cm in dimensions. A small disc-shaped electric saw was used, with saline irrigation for cooling. The excised piece of bone was used again as a bone graft. Above the middle of the defect a bicortical fine drill hole was made by a 1.5-mm drill. A fine stainless steel wire was passed through the hole. The bone graft (the excised piece) was repositioned to its place and the wire was twisted over it for its fixation (Fig. 2). The wound was then closed in layers by 4-0 absorbable sutures.

Subgroup (2): The same method for exposure of the mandibular body was done as described for subgroup (1). The site of osteotomy was marked as a longitudinal line in a site corresponding to that of bone graft in subgroup (1) (Fig. 1-B). The osteotomy was done using a side-cutting Lindman burr applied to a straight hand piece of an electric motor, with saline irrigation for cooling. At both sides of osteotomy, bicortical pins were applied for the distractor (using a hand drill). The pins were put parallel to each other on a line perpendicular to the osteotomy (Fig. 3). The pins were serrated 2 mm K-wires. After application of the 2 pins, a fine osteotome was used to complete the osteotomy. Then, the wound was closed and the

distractor was applied. It is a custom-made distractor exactly similar to Molina's baby distractor produced by Wells Johnson Company (Fig. 4).

Post Operative Care and Follow-up: The animals were put separately in cages labeled with date and type of operation. They were allowed to eat immediately and food consumption was observed. The suture lines were daily irrigated with antiseptic solution. Prophylactic antibiotics were given for 6 days. In distraction subgroup, the distraction began on the 5th post-operative day. The distraction rate was 1 mm/day (0.5 mm twice daily), for 7 days. The animals were observed during distraction for occlusal changes and stability of the device. Pin sites were observed for signs of infection.

Animal Sacrifice and Specimen Preparation: At the planned time, all living animals of both subgroups were sacrificed. The mandibles were harvested and examined grossly by naked eyes. Then, specimens were prepared for the mechanical study. Some representative samples of each subgroup were prepared for histology. These were taken with the covering periosteum, sectioned through the symphysis, and put in formaline 10% solution for few days. The involved part of the body of the mandible was cut, and the corresponding part of the control side. Then the specimens were immersed in nitric acid for about one week; for decalcification; and processed to form paraffin sections.

Specimen Preparation for the Mechanical Study: The periosteal remnants were removed, and the mandibles were preserved by freezing till arranging with the laboratory. At the time of examination specimens were cut full thickness from the parts to be examined, 0.5 cm in dimensions using an electric saw. The cut surfaces were parallel to each other and perpendicular to the mandibular border. The surface area of the cut surface was measured by the use of its ink impression on a graphic paper. Then, the specimens were carried to a special machine for material testing [Universal Testing Machine, LLOYD Instruments LTD, LR 300 K, its capacity = 30 ton = 300 KN (kilo Newton)] (Fig. 5). This machine applies gradually increasing compression forces on the cut surface of the examined specimen till the break point. The break point for each specimen was recorded and a stress-strain curve was drawn. This test was done in the laboratory of metallurgy, Faculty of Engineering, Ain Shams University. The recorded data of each sample (maximum applied force, surface area and maximum stress) were collected and statistical analysis (student *t*-test) was done.

RESULTS

A- Results of Surgical Procedures:

1- First Animal Group:

This included 29 animals which were planned to be sacrificed at 6 weeks.

a- *Subgroup (1):* Bone Graft Surgery (14 animals): All animals started normal feeding few hours after recovery. Two animals died, at 10 days and at 6 weeks post-operatively. The first was excluded. The cause of death was GIT infection.

Naked eye examination of the mandibles (at 6 weeks) revealed that 77% of the samples (10 among 13) showed evidence of good healing. The borders of bone grafts were nearly not identifiable from the surrounding bone. Eight samples were prepared for the mechanical studies. The other samples were prepared for histology. Healing was not considered good in three samples (excluded from the mechanical studies). One of them showed excessive white creamy material. Culture from that material showed no growth. This was explained to be a reaction to the wire of fixation (metal allergy) [47].

Microscopically, all the examined specimens (five) shared in showing mainly osteoid tissue with minimal amount of bony trabeculae. The junction between the graft and the normal bone was formed of bone trabeculae in a fibrous background. No cartilage was found in any area of the specimen.

b- *Subgroup (2):* Mandibular distraction (15 animals): The procedure was well tolerated by the animals. They started to eat normally on the second to third postoperative day (Fig. 6). Two animals were completely excluded from the results. One of them had lost the device, and the other died immediately postoperative.

Postoperative Fate of the Remaining 13 Animals was One of 4 Different Patterns:

- 1- Early death and early device loss: 2 animals.
- 2- Early death with a stable device: 1 animal.
- 3- Survival with device loss (early or late): 7 animals.
- 4- Survival with stable device: 3 animals.

Early death occurred 5-15 days after the distraction stopped. The cause of death was GIT infection (severe diarrhea). 2 animals had got device extrusion earlier than 2 weeks of consolidation. 5 animals lost the device later (more than two weeks consolidation). Progressive occlusal changes occurred in all animals during the distrac-

tion period. These were mainly lateral cross bite (toward the non-operated side) (Fig. 7), in some animals this was associated with class III mal occlusion (Fig. 7-B). The loss of incisor contact secondary to the developing mal occlusion resulted in over eruption of the incisors (Fig. 7-C) which took about one month to occur. No further intervention was done to the animals after extrusion of the device after 7 days fixation specially that the occlusal changes were stable [51].

Naked eye examinations of the mandibles at the time of sacrifice (6 weeks): With early loss of the device (2 samples), the length of distraction gap was < 5 mm (relapse) and the healing was not complete. The gap was clearly distinguishable from the bony ends and allowed some degree of mobility. The material of tissue reaction was minimal. In animals that lost the device later (5 samples), the healing varied according to presence of tissue reaction substance and the length of fixation period. In all, the amount of bone lengthening was less than 6mm (relapse): In 3 samples, no tissue reaction was found. The healing was complete the distraction gap was filled with bone, its middle was still distinguishable as a lighter color strip. While, in the other 2 samples the reaction material was found, and the healing was not yet completed. There was still some mobility around the osteotomy. The distraction gap had bone only near the bony edges these two incompletely healed samples were not selected for mechanical studies. With stable device till the time of sacrifice: The area of distraction gap was filled with newly formed bone. The pins were strongly attached to the bone (Fig. 8). The material of tissue reaction was not found. The distance between the pin holes was about 6-7 mm > intra-operative distance. Six samples were selected from the completely healed mandibles for mechanical studies the other samples were examined histologically.

Microscopic examination of the distraction zones of animals died at different postoperative times helped to show different phases of osteogenesis. New bone was formed through endochondral ossification. Larger amount of cartilage was observed with more unstable fixation or shorter duration of fixation. With proper fixation for longer times, bony fusion started to occur. On both sides new bone trabeculae was found to bridge the distraction gap over the central zone parallel to the direction of distraction vector.

2- Second Animal Group:

This included 19 animals, which were planned to be sacrificed at 12 weeks.

a- *Subgroup 1:* Bone graft surgery: (8 animals). All animals survived with a good health till the sacrifice time. Naked eye examination of the mandible at 12 weeks showed that the healing was complete in 6 animals. The white material of tissue reaction was found in 2 animals among 8. In these 2 animals the borders of the graft were still seen which indicates incomplete healing. Five mandibles were devoted to the mechanical studies and the others were examined histologically.

Microscopic examination showed more mature and remodeled bone with cortical bone outside continuous with the original cortex and normal bone marrow inside. The osteoid tissue was still found. The amount of bone trabeculae was less than the control side, which indicates resorption.

b- *Subgroup 2:* Mandibular distraction, (11 animals) Mortality rate was 0%. Device extrusion during the course of distraction occurred only in one animal. There were five animals of the other 10 had the device stable in place for a complete consolidation period of 4 weeks. In the remaining five spontaneous device extrusion occurred after a period ranged from a week to 2 weeks from the end of distraction. The occlusal changes were the same.

Naked eye examination at 12 weeks showed that with stable device for 4 weeks, there was bone lengthening of the distracted side by about 7mm. The area of distraction was filled with newly formed well-remodeled bone, not distinguishable from the rest of mandibular bone. In the animals that showed premature spontaneous device extrusion, remnants of the material of tissue reaction was found in variable amounts. The healing was not properly completed. Six samples were selected for the mechanical studies. The others were for histological assessment.

Microscopic examination showed that no cartilage was seen any more with stable fixation. The new bone had been differentiated into a cortex and marrow space. In that time, the structure is very similar to the non-operated control side. However, some samples from animals that had premature device extrusion were still showing islands of cartilage in the central area.

B- Results of Mechanical Studies:

These are the results of application of gradually increasing compression forces on 14 bone graft samples and the corresponding controls; 8 of 1st group and 6 of 2nd group, and 11 distraction samples and the corresponding controls: 5 of 1st group

and 6 of 2nd group. The maximum stress that could be tolerated by the sample till the fracture point was expressed in N/mm². (Neuoten/square millimeter). This is the force exerted for fracture of the sample per/unit surface area exposed to that force. For the samples from bone grafts at 6 weeks, the mean of this stress was 12.6 N/mm² (SD±5.7). The control samples had mean maximum stress of 21.3 N/mm² (SD±6.5). The difference between experimental and control values is statistically significant (*p* < 0.05 by student *t*-test). Samples from distraction zones at the same post operative time could tolerate a mean maximum stress of 57.5 N/mm² (SD±2.2). Their controls tolerated a mean of 12.2 N/mm² (SD±3.3). This difference is highly significant (*p* < 0.001). Distraction samples at this post-operative time showed deformation (flattening) rather than fracture under the effect of mechanical stress that was a different reaction from that shown by bone graft or nonoperated control. This might be explained by the presence of cartilage in the distraction zone, which enabled it to withstand greater amount of stress without fracture. In contrast to bone graft which appeared to be fragile and rather brittle as compared to the control. At 12 weeks post operatively, bone graft samples tolerated stress with a mean of 21.3 N/mm² (SD±2.8). The control value was 24.5 N/mm² (SD±2.1). This difference is statistically non-significant (*p* > 0.05)/Distraction samples at that time tolerated a mean of 31.3 N/mm² (SD±5.8) with a control value of 20.1 N/mm² (SD±2.1). This difference is statistically significant (*p* < 0.05). These data are summarized in Table (1).

Table (1): Mean and standard deviation of the maximum tolerable stress, surface area and applied force for samples of different groups comparing experimental to control samples.

| Statistical groups | Experimental Mean ± SD | Control Mean ± SD | <i>p</i> | Sig. |
|---------------------|------------------------|-------------------|----------|------|
| 1- (b.g. at 6 wks) | S = 12.6±5.7 | 21.3±6.5 | < 0.05 | S |
| | SA = 33.2±12.6 | 32.5±9.9 | > 0.05 | NS |
| | F = 363.8±96.5 | 591.1±73.1 | < 0.01 | HS |
| 2- (d. at 6 wks) | S = 57.5±2.2 | 12.2±3.3 | < 0.001 | HS |
| | SA = 34±11.5 | 20.7±1.2 | > 0.05 | NS |
| | F = 1941.3±587.3 | 254.2±82.9 | < 0.01 | HS |
| 3- (b.g. at 12 wks) | S = 21.3±2.8 | 24.5±2.1 | > 0.05 | NS |
| | SA = 31.7±6.5 | 29.7±6.5 | > 0.05 | NS |
| | F = 684±223 | 721.6±120.5 | > 0.05 | NS |
| 4- (d. at 12 wks) | S = 31.3±5.8 | 20.1±2.1 | < 0.05 | S |
| | SA = 42±5.3 | 29.3±2.3 | < 0.01 | HS |
| | F = 1327.8±410.5 | 589.8±79.4 | < 0.05 | S |

b.g. = Bone graft. P = Probability of error.
 d. = Distraction. Sig. = Statistical significance.
 S = Stress. S = Significant.
 SA = Surface area. NS = Non-significant.
 F = Force. HS = Highly significant.

Fig. (1): Planning of the osteotomy lines marked on a dry specimen:

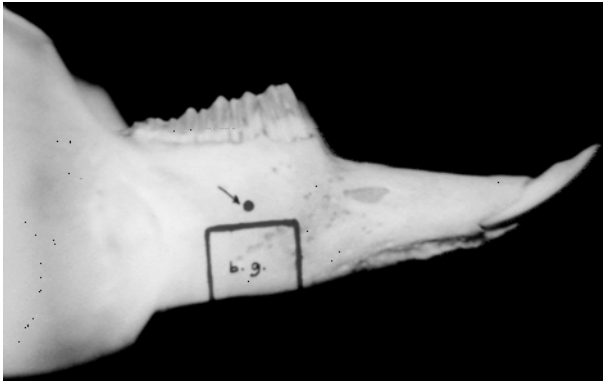


Fig. (1-A): For bone graft: notice the site of the drill-hole above the graft site.

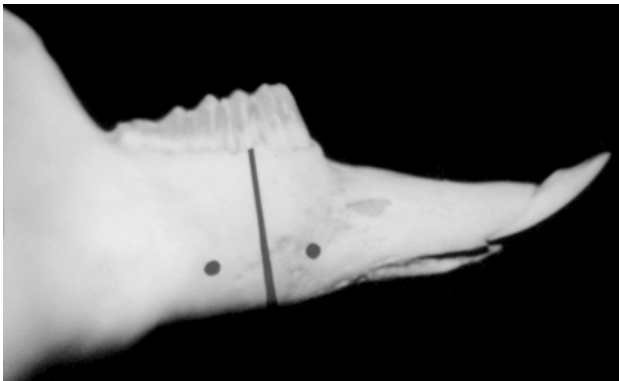


Fig. (1-B): For distraction: notice the sites of application of pins.

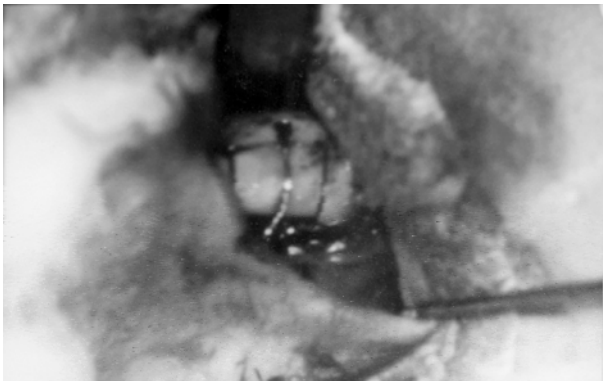


Fig. (2): In situ fixation of the bone graft, an intra-operative view.

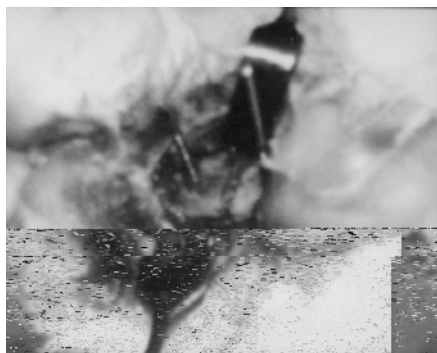


Fig. (3): Osteotomy and pins applied parallel to each other on a vector perpendicular to the osteotomy, an intra-operative view.

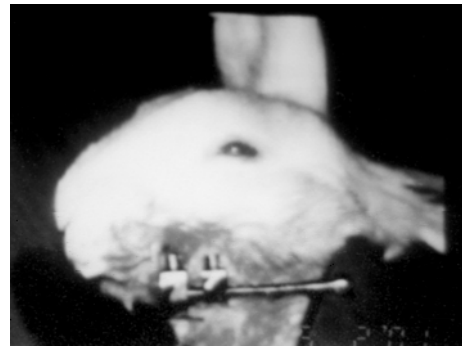

Fig. (4): Skin closed and the distractor in place.




Fig. (5): The universal testing machine.




Fig. (6): An animal of distraction, returned to normal feeding behavior, 2 days postoperative.

Fig. (7): The occlusal changes in the animals of distraction subgroups.

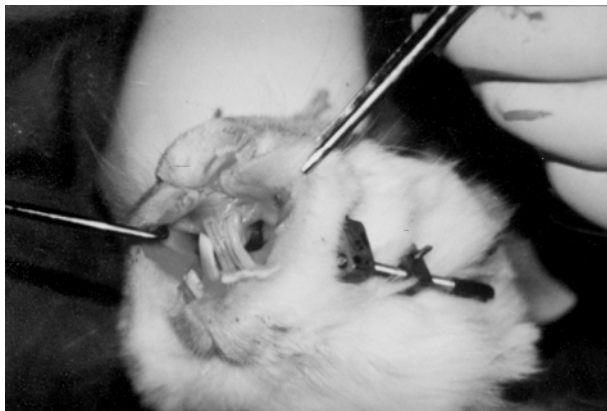


Fig. (7-A): Lateral cross bite (shift towards the non-operated side).

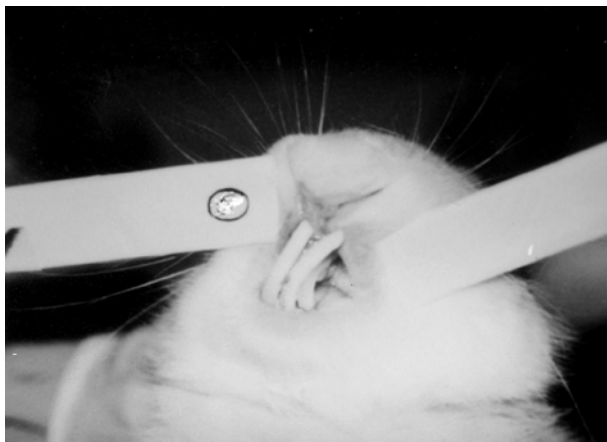

Fig. (7-B): Lateral cross bite and class 3 malocclusion.

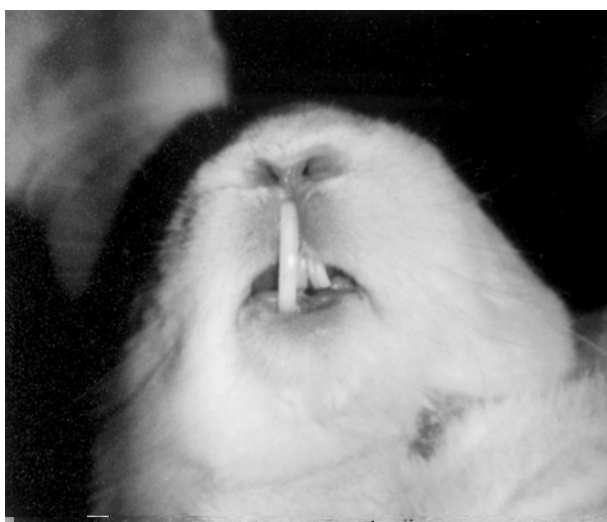

Fig. (7-C): Over eruption of the incisors → loss of one of the lower.

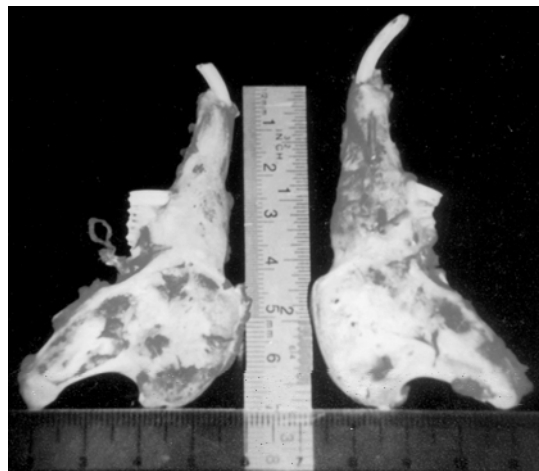


Fig. (8): Distracted mandible 6 weeks postoperatively, with stable fixation till the sacrifice time. Notice the difference in length between the two sides.

DISCUSSION

Few reports exist concerning the mechanical evaluation of distracted bones. A similar method using torsion loads was previously described in long bone lengthening [42]. However, no previous studies were found that compared the strength of the newly formed bone after distraction to the strength of bone grafts at a certain postoperative time. This has been done in the present study. This study was also the first to evaluate such aspect in distracted mandibles, and presented a successful new method for mechanical evaluation of distracted bone that tested the bone tolerance to compression stress. The compression force, rather than torsion or traction loads was selected as it was found to be similar to the natural forces applied to the mandible.

The present study compared the mechanical properties of the distracted bone to an in-situ bone graft, using the same animal as control. By the use of this pattern of bone graft in which the alveolar continuity was preserved, the occlusion was not changed, and the needed stability for bone graft fixation was allowed. Thus optimum conditions for bone graft healing were available. This is also because it is the best matched graft to the recipient defect. These conditions make it the best bone graft (best potential for healing). This method also saves the animal an additional surgical trauma of harvesting the graft from a distant site. Naked eye examination of samples at the sacrifice times showed complete healing in more than 75% of bone graft samples. However, the mechanical evaluation showed that it could not tolerate the compression stress that was normally tolerated by the

non-operated controls in all the examined samples, even after allowing a longer time (12 weeks) in the 2nd group. Yet, the differences between test and control at 12 weeks were statistically non-significant. This is in contrast to the distraction samples, that showed high tolerance to compression without fracture, more than their control. This was explained to some extent by presence of cartilage in the course of healing of distraction samples with different mechanical properties. For that reason, these differences were more evident (statistically highly significant) in samples of the 1st group (6 weeks postoperative) which had more cartilage content, as proved by the histologic examination. When healing became more complete (at 12 weeks), with decreased cartilage content, the mechanical properties became nearer to the control than at 6 weeks. However, the differences were still statistically significant.

The presence of variable amounts of cartilage as noticed from the histologic examination of specimens from distraction gaps indicates endochondral ossification. This is in agreement with the previous works [21,41] who studied this in rabbits. The amount of cartilage formation could be correlated to the stability of fixation which also goes in agreement with the other findings [8,21].

From these results we could conclude that the new bone formed as a result of gradual distraction could resist compression forces more than bone grafts at the same postoperative time. Thus, its quality could be considered better. It has similar mechanical characters; if not better than that of the original (old) bone.

REFERENCES

- 1- Abbott L.C.: The operative lengthening of the tibia and fibula. *J. Bone and Joint Surg.*, 9: 128-152, 1927.
- 2- Aldegheri R., Renzi-Brivio L. and Agostini S.: The callotasis method of limb lengthening. *Clin. Orthop.*, 241: 137-45, 1989.
- 3- Anderson W.V.: Leg lengthening. *J. Bone and Joint Surg.*, 34-B: 150-152, 1952. Quoted from Potparic et al., 1996.
- 4- Coleman S.S. and Noonan T.D.: Anderson's method of tibial lengthening by percutaneous osteotomy and gradual distraction. *J. Bone and Joint Surg. Am.*, 49A: 263-279, 1967.
- 5- Ilizarov G.A.: A new principle of osteosynthesis with the use of crossing pins and rings. In collection of scientific work of the Kingan Regional Scientific Medical Society USSR. Kingan, 145-160, 1954. Quoted from McCarthy et al., 1995.
- 6- Ilizarov G.A.: Basic principles of transosseous compression and distraction osteosynthesis. *Orthop. Travmatol. Protez*, 32 (11): 7, 1971. Quoted from Ilizarov, 1989a.
- 7- Ilizarov G.A., Devyatov A.A. and Karnerin V.K.: Plastic reconstruction of longitudinal long bone defects by means of compression and subsequent distraction. *Acta Chir. Plast.*, 22: 32-41, 1980, Quoted from Potparic et al., 1996.
- 8- Ilizarov G.A.: The tension-stress effect on the genesis and growth of tissues: Part 1. The influence of stability of fixation and soft-tissue preservation. *Clin. Orthop.*, 238: 249-281, 1989a.
- 9- Ilizarov G.A.: The tension-stress effect on the genesis and growth of tissues: Part 2. The influence of the rate and frequency of distraction. *Clin. Orthop.*, 239: 263-285, 1989b.
- 10- De Bastiani G., Aldegheri R., Renzi-Brivio L. and Trivella G.: Limb lengthening by callus distraction (callotasis). *J. Pediatr. Orthop.*, 7: 129-34, 1987.
- 11- Ilizarov G.A.: Clinical application of the tension-stress effect for limb lengthening. *Clin. Orthop.*, 250: 8-26, 1990.
- 12- Wagner H.: Surgical lengthening or shortening of femur and tibia. Technique and indications. In: *Progress in orthopaedic surgery. Leg length discrepancy.* 71-94. Ed. by: Hungerford D.S., Publisher: Springer-Verlag, Berlin, 1977.
- 13- Snyder C.C., Levine G.A., Swanson H.M. and Browne E.Z.: Mandibular lengthening by gradual distraction; preliminary report. *Plast. Reconstr. Surg.*, 51: 506-508, 1973.
- 14- Kutsevliak V.I. and Suckachev V.A.: Distraction of the mandible in an experiment. *Stomatologia Mosk.*, 64 (4): 13, 1984.
- 15- Karaharju-Suvanto T., Karaharju E.O. and Ranta R.: Mandibular distraction: An experimental study in sheep. *J. Cranio-maxillofac. Surg.*, 18: 280-283, 1990.
- 16- Karp N.S., Thome C.H.M., McCarthy J.G. and Sissons H.A.: Bone lengthening in the craniofacial skeleton. *Ann. Plast. Surg.*, 24: 231-237, 1990.
- 17- Karp N.S., McCarthy J.G., Schreiber J.S., Sissons H.A. and Thorone C.H.M.: Membranous bone lengthening a serial histological study. *Ann. Plast. Surg.*, 29: 2-7, 1992.
- 18- Remmler D., McCoy F.J., O'Neil D., Willoughby L., Patterson B., Gerald K. and Morris D.C.: Osseous expansion of the cranial vault by craniotaxis. *Plast. Reconstr. Surg.*, 89 (5): 787-797, 1992.
- 19- Block M.S., Daire J., Stover J. and Mathews M.: Changes in the inferior alveolar nerve following mandibular lengthening in the dog using distraction osteogenesis. *J. Oral Maxillofac. Surg.*, 51: 652, 1993.
- 20- Rachmiel A., Potparic Z., Jackson I.T., Sugihara T., Clayman L., Topf J.S. and Forte R.A.: Midface advancement by gradual distraction. *Br. J. Plast. Surg.*, 46: 201-207, 1993.
- 21- Komuro Y., Takato T., Harii K. and Yonemara Y.: The histologic analysis of distraction osteogenesis of the mandible in rabbits. *Plast. Reconstr. Surg.*, 94: 152-159, 1994.
- 22- Gantous A., Phillips J.H., Catton P. and Holmberg D.: Distraction in the irradiated canine mandible. *Plast. Reconstr. Surg.*, 93: 164-168, 1994.

- 23- Glat P.M., Saffenberg D.A., Karp N.S., Holliday R.A., Steiner G. and McCarthy J.G.: Multidimensional distraction osteogenesis the canine zygoma. *Plast. Reconstr. Surg.*, 94: 753-758, 1994.
- 24- Guerrissi J., Ferrentino G., Margulies D. and Fiz D.: Lengthening of the mandible by distraction osteogenesis: Experimental work in rabbits. *J. Craniofac. Surg.*, 5: 313-317, 1994.
- 25- Tschakaloff A., Losken H.W., Mooney M.P., Siegel M.I., Losken A. and Swan J.: Internal calvarial bone distraction in rabbits with experimental coronal suture immobilization. *J. Craniofac. Surg.*, 5: 318-326, 1994.
- 26- McCormick S.U., McCarthy J.G., Grayson B.H., Staffenberg D. and McCromick S.A.: Effect of mandibular distraction on the temporomandibular joint: Part 1 canine study. *J. Craniofac. Surg.*, 6 (5): 358-363, 1995.
- 27- Lalikos J.F., Tschakaloff A., Mooney M.P., Losken H.W., Siegel M., Losken A., Reitz P. and Wright M.: Internal calvarial bone distraction in rabbits with experimental coronal suture immobilization: Effects of over distraction. *Plast. Reconstr. Surg.*, 96: 689-697, 1995.
- 28- Staffenberg D.A., Wood R.J., McCarthy J.G., Grayson B.H. and Glasberg S.B.: Midface distraction advancement in canine without osteotomies. *Ann. Plast. Surg.*, 34: 512-517, 1995.
- 29- Schmelzeisen R., Neumann G. and von der Fecht R.: Distraction osteogenesis in the mandible with a motor-driven plate: A preliminary animal study. *British Journal of Oral and Maxillofacial Surgery*, 24: 375-378, 1996.
- 30- Block M.S., Chang A. and Crawford C.: Mandibular alveolar ridge augmentation in the dog using distraction osteogenesis. *J. Oral Maxillofac. Surg.*, 54: 309-314, 1996.
- 31- Rachmiel A., Levy M., Laufer D., Clayman L. and Jackson I.T.: Multiple segmental gradual distraction of facial skeleton: An experimental study. *Ann. Plast. Surg.*, 36: 52-59, 1996.
- 32- Fisher E., Staffenberg D.A., McCarthy J.G., Miller D.C. and Zeng J.: Histopathologic and biochemical changes in the muscles affected by distraction osteogenesis of the mandible. *Plast. Reconstr. Surg.*, 99: 366-71, 1997.
- 33- Farhadieh R.D., Dickinson R., Yu Y., Gianoutsos M.P. and Walsh W.R.: The role of transforming growth factor-beta, insulin-like growth factor I, and basic fibroblast growth factor in distraction osteogenesis of the mandible. *J. Craniofac. Surg.*, 10: 80-85, 1999.
- 34- Friedrich R.E., Hellner D., Plambeck K. and Schmelzle R.: Application of B scan ultrasonography for analysis of callus distraction in vascularized fibular grafts of the mandible: A report of three patients. *J. Oral Maxillofac. Surg.*, 55: 635, 1997.
- 35- Young J.W.R., Kostrubiak I.S., Resnik C.S. and Paley D.: Sonographic evaluation of bone production at the distraction site in Ilizarov limb-lengthening procedures. *Am. J. Roentgenol.*, 154: 125-28, 1990.
- 36- Maffulli N., Hughes T. and Fixsen J.A.: Ultrasonographic monitoring of limb lengthening. *J. Bone Joint Surg. Br.*, 74: 130, 1992.
- 37- Eyres K.S., Bell M.J. and Kanis J.A.: Methods of assessing new bone formation during limb lengthening. *J. Bone Joint Surg. Br.*, 75: 358, 1993.
- 38- Harp J.H., Aronson J. and Hollis M.: Noninvasive determination of bone stiffness for distraction osteogenesis by quantitative computed tomography scans. *Clin. Orthop.*, 301: 42-8, 1994.
- 39- Hughes T.H., Maffulli N., Green V. and Fixsen J.A.: Imaging in bone lengthening: A review *Clin. Orthop.*, 308: 50-53, 1994.
- 40- Roth D.A., Gosain A., McCarthy J.G., Stracher M.A., Lefton D.R. and Grayson B.H.: A CT scan technique for quantitative volumetric assessment of the mandible after distraction osteogenesis. *Plast. Reconstr. Surg.*, 99: 1237-1247, 1997.
- 41- Kojimoto H., Yasui N., Goto T., Matsuda S. and Shimomura Y.: Bone lengthening in rabbits by callus distraction: The role of periosteum and endosteum. *J. Bone Joint Surg. Br.*, 70B: 543-9, 1988.
- 42- Schickendantz M.S., Watson J.T., Sferra J.J. and Kambic H.E.: A model for evaluating the strength of bones lengthened by distraction osteogenesis. *Clin. Orthop.*, 275: 248, 1992.
- 43- El-Sayed A.: Prof. of anesthesiology, Faculty of Veterinary Medicine, Cairo University. Personal Communication, 1999.
- 44- Melich D.: Method for chronic intravenous infusion of the rabbit via the marginal ear vein. *Lab. Anim. Sci.*, 40: 327, 1990.
- 45- Lipman N.S., Marini R.P. and Flecknell P.A.: Anaesthesia and analgesia in rabbits, chapter in anaesthesia and analgesia in laboratory animals Ed. by Kohn D.F., Wixson S.K., White W.J. and Benson G.J. Published by Academic Press, 205-232, 1997.
- 46- Schuyt H.C. and Leene W.: Improved method of tracheal intubation in the rabbit. *Lab. Anim. Sci.*, 27: 690-693, 1977.
- 47- Saavedra M.D.: Director of the investigation department, Hospital General Dr. Manuel Gea Gonzalez, Mexico and Head of Mexican Human Genetic Medical Association, Personal Communication.
- 48- McCarthy J.G., Schreiber J., Karp N., Thorne C.H. and Grayson B.H.: Lengthening of the human mandible by gradual distraction. *Plast. Reconstr. Surg.*, 89: 1-8, 1992.
- 49- McCarthy J.G., Staffenberg D.A., Wood R.J., Cutting C.B., Grayson B.H. and Thorne C.H.: Introduction of an intraoral bone-lengthening device. *Plast. Reconstr. Surg.*, 96: 978-981, 1995.
- 50- Molina F. and Monasterio F.O.: Mandibular elongation and remodeling by distraction: A farewell to major osteotomies. *Plast. Reconstr. Surg.*, 96: 825-840, 1995.
- 51- Monasterio F.O.: Personal communications.
- 52- Potparic Z., Jakson I.T. and Rachmiel A., et al.: The application of the Ilizarov technique on facial skeleton Ch. in recent advances in Plastic Surgery Ed. by Jakson and Sommerland, Churchill Livingstone, First Published, 1996.