

Full Thickness Skin Graft for Burned Face

HAMDY BASHA, M.D.

The Department of Plastic Surgery, Matarreya Teaching Hospital, Cairo.

ABSTRACT

Since 1999, 8 cases of post-burn complications of the face were managed by full thickness skin graft. 7 females and one male child suffered from keloid, cicatrix and face motulation after burn. Expansion of the doner site and application of full thickness skin graft were used to cover various big surface areas. The procedures are simple and the results are discussed.

INTRODUCTION

Post-burn facial skin deformities were managed by many techniques [1,2,5-8] according to the shape and extent of the lesion. Split thickness skin graft resurfacing, fullthickness skin graft application and various types of flaps were the main lines of treatment [1,2,5-8].

Other procedures like dermabrasion or chemical pelling had limited indication.

The application of skin graft either split or full thickness as a stastic unit provided a solution. The use of free or pedicled flaps had also its indication [7,9].

The application of large areas of full thickness skin graft had been mentioned and applied by many authors [1-4].

MATERIAL AND METHODS

Seven females and one male suffered from post burn facial skin deformities and unaccepted look. Their age ranged from 7:45 years, two of them were at school age and the rest were housewives. 7 cases suffered direct flame burn and one scolded. The surface area affected ranged 80 cm²: 252 cm², with the longest vertical diagonal was 14 cm and the longest transverse diagonal was 27 cm. In 7 cases the abdomen was the doner area and in the last one the back was the doner site. The doner abdominal site for expansion can be closed primarily but the back doner site was closed by split thickness

skin graft. The proceedure started by accurate calculation of the surface area of the lesion, insertion of the proper expander either rounded or rectangular in shape. Skin expansion of the abdominal infraumbilical region were done in 7 cases. The expander was inserted submuscular in the last case as the back was the doner site of choice. Low suction drain was used in all cases.

Expansion was completed within 21:30 days with two to three injections weekly. The expanders were removed and the recipient site was prepared by excision of the lesion and adequate haemostasis. The doner site full thickness skin was prepared by adequate defatening as one piece. The doner sites were closed by primary sutures or grafted. The full thickness skin graft was sutured to the recipient site by 4/0 stitches. Untight dressing were applied in all cases.

RESULTS

The site of the lesion, the extent of it, the presence of keloid or hypertrophic scar, the presence of contracted band and the colour of the lesion or the grafted skin were factors that affect the strategy of the surgical interference.

The full thickness graft take, the colour of it, the presence of bad scars and the presence of contracting bands were parameters to evaluate the outcome of the procedure. The final picture of the face after surgery must be compared by the preoperative picture to evaluate this procedure.

The lower third of the face was the lesion site in 5 cases, the middle third was affected in two cases and the upper and middle thirds were affected in one case. Keloid was present in two cases, hyperpigmentation of graft or burned area were present in all cases and contracted bands were present in three cases. All cases complained of undesirable facial look and appearance.

The graft take was: 80% in 4 cases, 60% in 3 cases and 50% in one case. Haematoma occurred in all cases and it was the probable cause of the lost parts of the overlying graft. The colour and appearance of the graft were about normal after one year postoperatively although it was not the same colour of the normal facial skin. The surface area of the full thickness skin graft as one piece for replacement ranged from 80 cm² to 252 cm² with average of 156 cm². The donor site showed

no complications and closed primarily in 6 cases, one case was infected and expander exposure supervened in one case. The direct closure was hard to achieve as the surface area was too big and the donor area was grafted by split thickness graft.

The preoperative picture compared by the post-operative one indicate the validity of the procedure in seven cases as shown in Figs. (1-A,B; 2-A,B and 3-A,B).

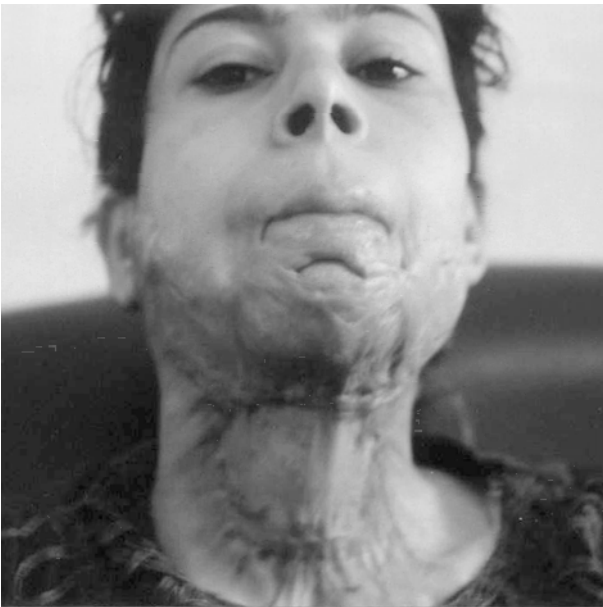

Fig. (1-A): Preoperative picture of post-burn keloid of the young lady affecting the whole lower third of her face.

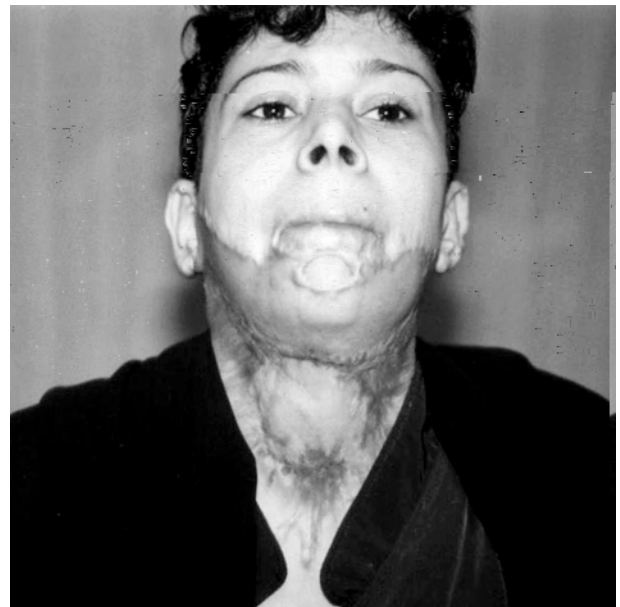


Fig. (1-B): Late post-operative picture after one piece full thickness grafting of the lower third. One year postoperative view.

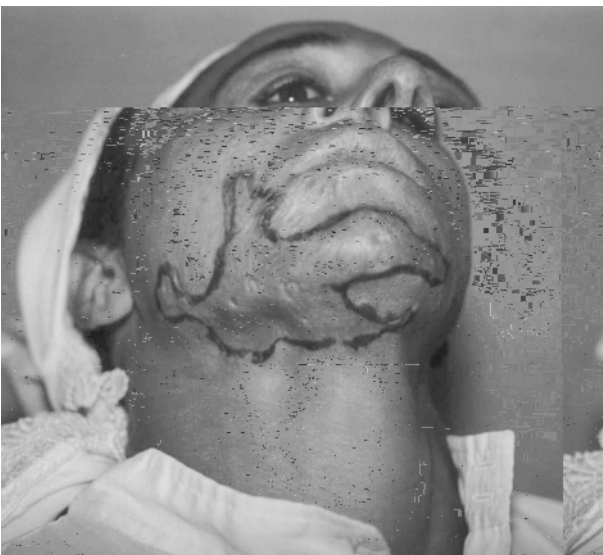

Fig. (2-A): Preoperative view of hyperpigmented hypertrophic cicatrix.

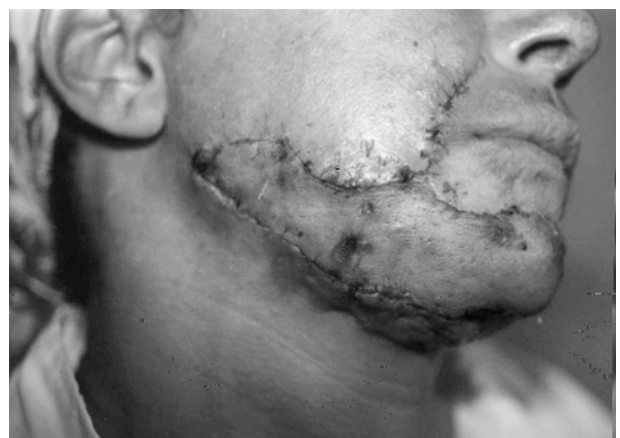

Fig. (2-B): Early postoperative view after 20 days.

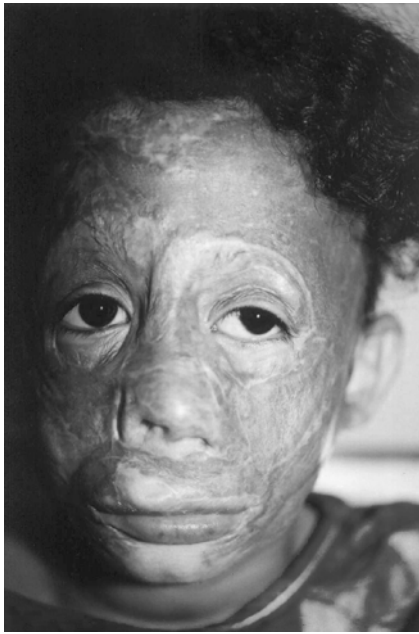

Fig. (3-A): Preoperative view of post burn complication of 75% of the face.




Fig. (3-B): Postoperative view after full thickness one sheet resurfacing (2 months postoperative).

DISCUSSION

Management of post-burn complications affecting the face depends on the concept of facial static units using either split thickness or full thickness skin graft.

Split thickness graft provides an easy and rapid solution to resurface burn ulcers in the face or elsewhere. But the modest cosmetic results as well the bands and scars resulted from the graft pieces interfered with the final outcome of the facial picture.

On the otherhand, the full thickness skin graft provides the normal texture and appearance of the skin. The application of one sheet graft may overcome the contracted bands that arised after the use of graft pieces according to the static units (Fig. 3-B).

The evaluation process of the results is still vague. The terms of good or bad results are still not accurate when brought in mind. A scoring procedure according to the analysis of the lesion items and the percentage of correction after surgery may provide a more accurate method for evaluation. The scoring procedure suggested as follows:

1- Lesion analysis:

- a- Ulcer: Present = 1, not present = 0
- b- Contracture: Present = 1, not present = 0
- c- Hyperpigmentation: Present = 1, not present = 0

d- Keloid or hypertrophic scar: Present = 1, not present = 0

e- Texture of the skin: Normal = 0, abnormal = 1

f- Appearance: Normal = 0, abnormal = 1

2- Percentage of correction e.g. in Fig. (3-A,B), the patient had the following scoring 5/6 as he had contracted bands, hyperpigmented dark skin, abnormal appearance, abnormal texture and hypertrophic scars.

The surgical procedures eliminated 90% of the contracted scars, 80% of abnormal pigmentation, 80% of the abnormal texture, 50% of the abnormal appearance and 60% of the hypertrophic scars. The percentage mean will be 72% of the overall picture.

The expansion of the doner area decreased the doner site morbidity as it could be closed primarily in most of cases except the case in which the 75% of the face had to be reconstructed (Fig. 3-A).

Adequate defatening and careful haemostasis affected the graft take, a proceedure must be considered. The impregnation of the graft in saline with insulin in fat graft were discussed but in this work we used a solution of 1:1 ringers and 5% glucose with the equivalent units of regular insulin and the full thickness skin graft was impregnated in it for 30 minutes. In this case the graft was 252 cm² surface area and the take of the graft was 75%; i.e. 190 cm² of the graft take without complications. We could not say that there was a solution effect

as so many factors interfere with the graft take. We think that it is too early to judge the solution effect but still it must be considered and discussed by other surgeons.

Conclusion:

The advantages of full thickness skin graft provide solution of many postburn complications of the face. The expansion of the doner site provide big surface area to be applied and in the same time decreases the doner site morbidity. In extensive facial deformities with big surface area the one sheet full thickness skin graft provide a solution to produce marked improvement. The possibility of resurfacing of 75% of the face by full thickness skin graft may allow in the future the possibility of total face transplant.

REFERENCES

- 1- Iwuagwu F.C., Wilson D. and Bailie F.: The use of skin graft in post burn contracture release: A 10 year review. *Plast and Reconst. Surg.*, 103 (4), 1999.
- 2- Bauer B.S., Vicari F., Richard M.E., et al.: Expanded full thickness skin graft in children: Case selection, planning and management. *Plast. and Reconst. Surg.*, 92: 59, 1993.
- 3- Sawhney C.P.: Contracture of skin grafts and its relation to cleavage line of skin. *Br. J. Plast. Surg.*, 24: 233, 1971.
- 4- Melaizeau J.P., Gayet C., Schmitt M. and Prevot J.: The use of free full thickness grafts in the treatment of complications of burns. *Prog. Pediatr. Surg.*, 14: 209, 1981.
- 5- McGergor I.A.; *Fundamental techniques of plastic surgery and their surgical applications*. 8th Ed. Edinburg: Churchill Livingstone pp. 39-63, 1989.
- 6- Jankanskas S., Cohen I.K. and Grabb W.C.: *Basic techniques of plastic surgery*. In J.W. Smith and S.J. Aston (Eds). *Grabb and Smith's Plastic Surgery* 4th Ed. Boston: Little brown pp. 3-90, 1991.
- 7- Chi-Yu Jia, Bi Chen, Ying-Jun SU: Pre-Fabricated lined axial flaps for reconstruction of extensive post burn facial and forehead full thickness composite defect. *Burns*, 28 (688-690), 2002.
- 8- Khouri R.K., Ozbek M.R., Hruza G.J., et al.: Facial reconstruction with pre-fabricated induced expanded (PIE) supraclavicular skin flaps. *Plast. and Reconst. Surg.*, 96 (6), 1995.
- 9- Foster R.D., Anthony J.P., Singer M.I., et al.: Microsurgical reconstruction of the mid face. *Arch. Surg.*, 131 (9), 1996.