

Clinical Outcome of Superior Pedicle Technique with Mammary Base Closure for Reduction Mammoplasty

ZAYED E., M.D.

The Department of Plastic and Reconstructive Surgery, Tanta University Hospitals, Tanta, Egypt.

ABSTRACT

Reduction mammoplasty is one of the most frequent procedures in plastic surgery with a large number of technical variations and modifications. Few procedures in the field of plastic surgery test the artistry and versatility of the surgeon to the degree that reduction mammoplasty does. In this work, we evaluated the use of superior pedicle technique with mammary base closure for reduction mammoplasty. This study included thirty-eight patients presented with different degrees of macromastia and breast ptosis. Evaluation of the results was done by testing patient's satisfaction, relief of the pre-operative symptoms, nipple-areola vascularity and sensibility, possibility of lactation, scar formation and other complications. Patient's satisfaction with the final results was acceptable in most cases.

Conclusion: The superior pedicle technique with mammary base closure is considered an excellent and effective method for breast reduction. It provides a conical breast with a pleasing and durable shape, minimal scarring with a highly acceptable nipple areola sensation and vascularity.

INTRODUCTION

The symbolic importance of the breast can not be overstated. The breasts symbolize fertility and is related to the sensuality and sexual expression [1]. Patients seeking a breast reduction are usually motivated by a desire to get rid of the physical symptoms related to macromastia [2].

The excess weight and size of the breast results in physical, psychological and social discomfort that directly limit many activities [3]. Sometimes, patients requiring primary correction of ptosis often seek improvement of their aesthetic appearance and are more worried about scar without any compromise in the natural shape of the reduced breast [4]. Breast reduction demands thoughtful and accurate preoperative planning and constant attention to the vascular status of the skin, nipple and gland in addition to innervations of the nipple-areola complex [5].

Reduction mammoplasty had developed numer-

ous techniques in attempting to make the procedure safe, more effective with an aesthetic result. Strömbeck [6] set a golden standard with his mammoplasty technique in 1960. A few years later Pitanguy [7] showed improved shape of the reduced breast and the position of the nipple-areola complex "NAC". Some authors [8,9,10] had introduced the inferior pedicle technique. Reduction mammoplasty with a vertical scar either with liposuction or through a medially based pedicle had been later developed [11,12].

PATIENTS AND METHODS

This study included thirty-eight patients - with age ranging from 18 to 40 years with a mean of 27.5 years - who had been operated upon in the period between April 2002 and April 2004. Thirty-five patients presented with different degrees of symptomatic macromastia including breast pain, back pain, neck pain, shoulder pain, painful bra strap grooves, presence of inframammary intertrigo and difficulty in fitting closing or doing physical activities. Three patients presented with moderate to severe form of breast ptosis with a mild degree of macromastia.

All patients were subjected to preoperative evaluation as regards age, severity of the presenting symptoms, cup size, suprasternal notch to nipple distance, patients dis-satisfaction and its degree. All patients were subjected to routine preoperative laboratory investigations, breast ultrasonography to take a general information about the breast component after clinical examination. Mammographic preoperative assessment gave a correct evaluation of both nature and consistency of the breast tissue. Its use was only restricted to the patients above the age of 40 years, patients with family history of cancer breast or patients with suspicious breast lump.

Preoperative markings: (Fig. 1)

Location of the correct position of the NAC is the most important component of the preoperative markings. All markings were performed with the patient standing in a military position. The transverse inframammary line was marked 1 cm above the actual fold and its medial and lateral ends should be limited to the medial and lateral breast ends to hide the inframammary scar. A line was then drawn $\frac{1}{2}$ -1 cm lateral to the midclavicular point crossing the nipple and extending to the inframammary line representing the breast meridian which is usually 10-12 cm from the midline. The future site of the nipple was chosen by projecting the tip of the index finger anteriorly on a point located at the intersection of the vertical axis of the breast with inframammary fold. By pushing and rotating the breast to the right and to the left, two lines were marked on each side in continuity with the previously drawn vertical axis. The length of these two vertical lines ranged between 5-6 cm according to the breast size and degree of ptosis.

The lower borders of these vertical lines were joined by curved line to both medial and lateral ends of the transverse inframammary line. The upper borders of the two vertical lines were joined by the future periareolar circumference which was drawn in the form of mosque-dome shape ranging between 14-16 cm in diameter with the future nipple site in its center. This characteristic shape and circumference allows perfect areolar circle formation without any risk of scar widening. As the areolas were frequently large and irregular in shape, their sizes were reduced proportionally using standard areolar markers with a diameter of 4-5 cm.

Operative technique: Under general anaesthesia sterilization and draping were done. Prophylactic intravenous antibiotics was given prior to surgery. The upper arms should be slightly abducted "60°". Local infiltration of saline-adrenaline in a concentration of 1:200000 in the lower half of the breast below the NAC and above the pectoral fascia decreases blood loss during dissection. The areola was cut superficially according to its newly designed diameter and shape.

All previously marked lines were cut leaving about 1 cm of de-epithelialized tissue before deep cutting which distributed the suture line tension on the deep dermis which is a helpful step in prevention of future scar widening. De-epithelization of the skin in the supra-areolar region and extending below the lower border of the areola till the lower borders of the vertical lines. This

step became easier with over-stretching the breast tissue by the assistant hands.

Starting from the de-epithelialized edge of the transverse inframammary incision, the breast tissues were perpendicularly cut leaving a thin layer of about 1 cm above the pectoral fascia especially in the lateral aspect of the breast to avoid injury of the sensory nerve of the nipple-areola complex. Dissection was extended in this plane upwards about 3 cm below the site of the future areolar margin. Two stay sutures were applied, one at the center of the future areolar margin and the second just below the inferior margin of the newly cut areola. The assistant pulls both stay sutures upward to create a tent like form and now the desired amount of the breast tissue is resected by gentle holding the infra-areolar breast tissue and going up with scalpel under this flap leaving tissue thickness of about 1.5 cm to secure sufficient NAC vascularity.

By gentle traction on the reduced specimen, resection of the medial site of the breast leaving a flap thickness of about 3 cm, while the lateral flap thickness is about 1 cm. Careful attention should be taken to evacuate all fatty tissue on both medial and lateral angles of the transverse inframammary line to avoid future dog-ear formation. Meticulous hemostasis can be done easily with unipolar diathermy. The wounds were gently irrigated with warm saline solution and the skin envelope was washed with an antiseptic solution. Insertion of negative suction tube drain in the wound cavity provided that its end was extruded through the corresponding axilla after its fixation of 2/0 silk suture. The upper central point of the areola is then sutured to its newly designed point at the center of the dome of the designed areola. The lower central part of the areola was then sutured with 3/0 Monocril to both upper ends of the two vertical lines.

A single stitch that brings and closes the mammary base at the pectoral fascia was taken with 0 PDS suture material. This step elevates the mammary cone and gives better projection and fullness of the superior poles. A triple suture was taken at the point of junction between the lower ends of that vertical lines and the point of breast meridian on the inframammary line. Flexion of the operative table (its upper half) by 30° degrees and standing at the feet of the patient allows comparison of the shape, size, symmetry and breast projection on both sides.

Closure of the vertical line in two layers, the

deep one with Monocril 3/0 which approximate both medial and lateral breast pillars together. The most distal ends of the two vertical lines should be sutured to the corresponding point on the inframammary line without any tension otherwise ischaemia and sloughing of this triangle will occur. The second layer of the vertical line was closed with 4/0 Monocril subcuticularly. The areola was closed with 4/0 Monocril subcuticularly after taking four orientation sutures at each areolar corner. Finally, the transverse inframammary incision was closed with 2/0 Monocril suture material without leaving any dog-ears. Sterile skin tapes, oriented longitudinally to the line of skin closure were applied to all skin incisions. The areola was covered by a piece of gauze with antibiotic ointment with separate closure for easy postoperative follow up.

Finally, the breast was supported with adhesive plaster and net dressing. Postoperatively, the patient was kept in bed with the head of the bed elevated at 30 degrees for approximately 8 hours. The patient was then allowed to walk with assistance. Movements of the shoulders were restricted for 7 days and gradually advanced to full range over the following weeks. The breast was examined every 4 hours for nipple-areola perfusion, softness and signs of bleeding. Postoperative treatment include oral antibiotics, analgesics and vitamins.

The suction drain was removed before discharge of the patient on the second or third post-operative day. If the amount of the suction drain was above 30 ml per day, it was left for 4 to 5 days and removed at the first outpatient visit. The patient was advised to wear an athletic brassieres to support the reduced breast for 2-3 months.

RESULTS

This study was carried out on thirty-eight patients in the period between April 2002 and April 2004 with a follow-up period that ranged from 1-25 months. The preoperative cup bra size ranged between C and DD with a mean of D size. The postoperative cup bra size ranged between B and C with a mean of B size. The preoperative suprasternal notch to nipple distance ranged between 26-33 cm and the nipple transposition distance (NTD) ranged between 6-12 cm with a mean of 10 cm. All patients were operated upon under general anaesthesia and the operative time ranged between 1.30-2.30 hours with a mean of 2 hours. The excised specimens were 380-790 gm per breast with a mean of 620 gm.

In this study, there was marked improvement in the preoperative symptoms and discomfort prob-

lems especially neck, shoulder and back pain, painful bra strap grooves, back kyphosis and inframammary intertrigo.

In this series, partial or complete necrosis of the nipple areola complex (NAC) was not recorded in any case. Some difficulty was recorded in one case at which the NTD was 12 cm in a highly glandular breast tissue at which slight inversion "dimpling" was manifested intraoperatively. This necessitated a risky thinning of the subareolar tissues. Fortunately the vascularity of NAC was not affected.

In this work, sensation of the NAC was acceptable in thirty patients. The remaining eight patients developed significant decrease in NAC sensibility. In six patients there was moderate to severe form of altered sensation in the form of tingling and numbness. In the other two cases there was complete unilateral total insensitive NAC. All these eight patients regained their NAC sensibility under medical treatment in the form of vitamin B complex within a period of 4-10 months.

Minor complications were recorded in six patients. Four of them presented with triangular wound healing problem at the site of junction of the vertical and the transverse inframammary line. All of them were treated conservatively with restriction of arm movements with daily dressing with saline, topical antibiotic. These triangles healed completely within 2-4 weeks. In one patient there was a localized hematoma which was subjected to aspiration twice and resolved completely. One patient presented with an area of traumatic fat necrosis of 2 x 2 cm and was followed-up regularly with ultrasonography and mammography till complete resolution. Infection was not reported in any case.

In this work the possibility of lactation was not tested in all patients. It was possible to evaluate that point only in three patients. Two of them reported inability to breast feed their babies. The third stated that breast feeding was not affected.

In this study, thirty-four patients were highly satisfied as regards size, shape, symmetry with an excellent projection and good upper pole fullness. Figs. (2-4) illustrate some clinical results. The other four patients were dissatisfied as regards the development of hypertrophic scars. Three of them had unacceptable transverse inframammary scars while the last one was unhappy with both periareolar and vertical scar. Scar revision was done to all these four patients with an acceptable result in three of them.

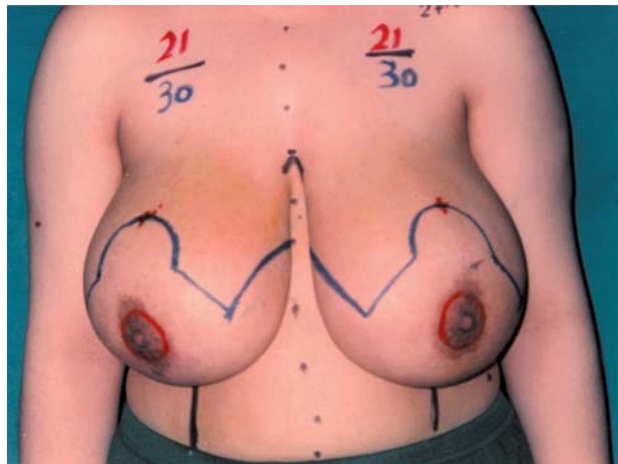


Fig. (1): Preoperative photograph showing preoperative markings in a young girl.

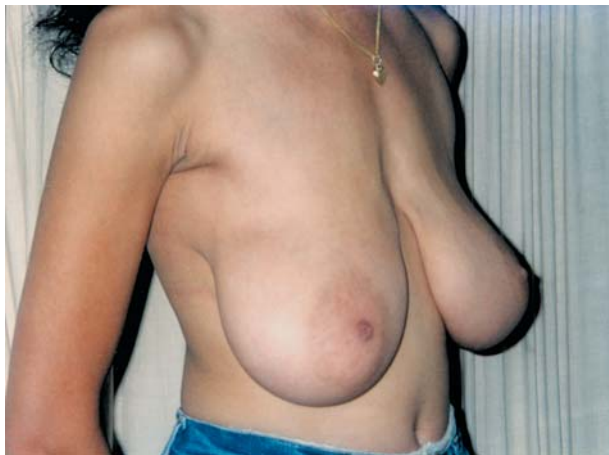

Fig. (2-C): Preoperative photograph "right oblique view" of the same patient.

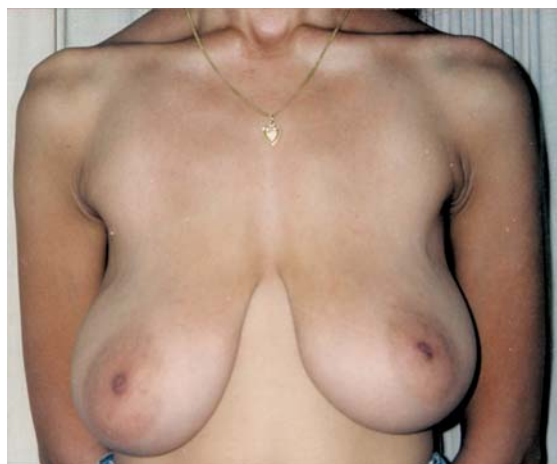

Fig. (2-A): Preoperative photograph "antero-posterior view" of a young lady showing 2nd degree of breast ptosis with flattened upper breast poles.

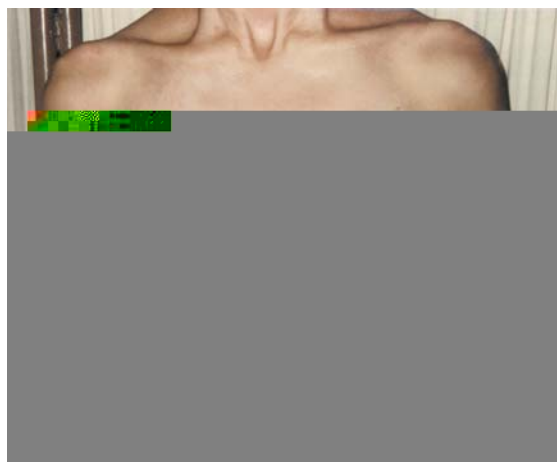

Fig. (2-B): Postoperative photograph after correction of ptosis with upper pole fullness.

Fig. (2-D): Postoperative photograph showing highly acceptable breast projection with upper pole fullness.

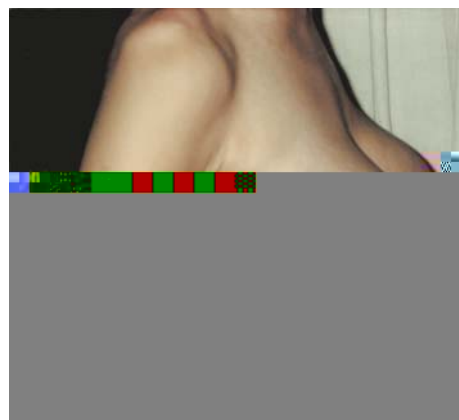

Fig. (2-E): Preoperative photograph "left oblique view" of the same patient.

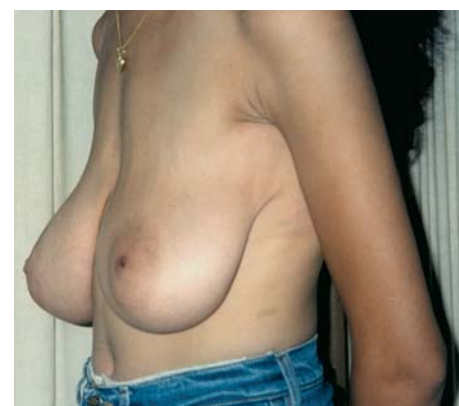
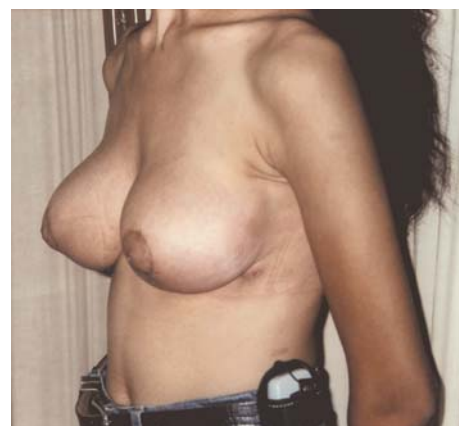
Fig. (2-F): Postoperative photograph showing highly acceptable breast projection with upper pole fullness.



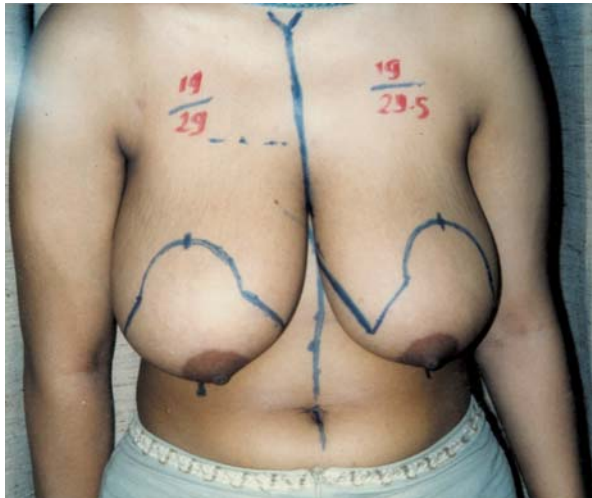


Fig. (3-A): Preoperative photograph, "antero-posterior view" showing a young girl with 3rd degree of breast ptosis and moderate form of macromastia.

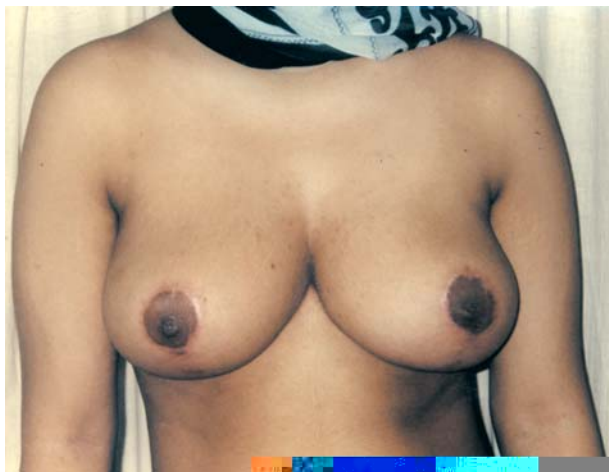

Fig. (3-B): Postoperative photograph showing acceptable breast size, shape, symmetry and projection.



Fig. (3-C): Preoperative photograph "right lateral view" showing severity of breast ptosis with back kyphosis.

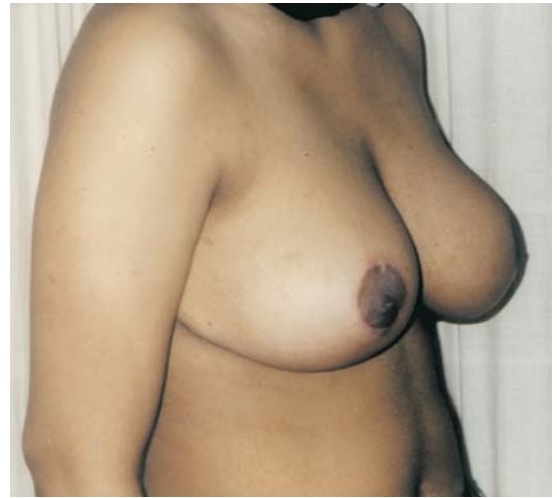

Fig. (3-D): Postoperative photograph showing good protection with correction of both ptosis and back kyphosis.

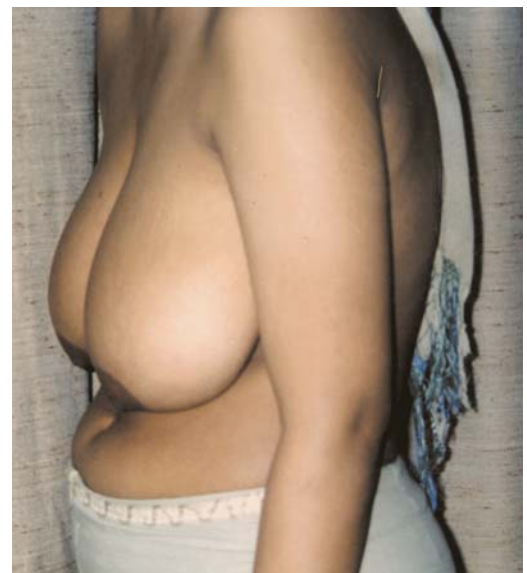

Fig. (3-E): Postoperative photograph "left lateral view" showing breast ptosis and back kyphosis.

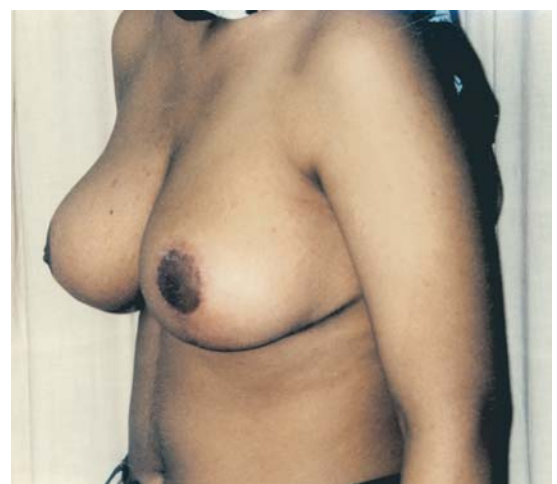

Fig. (3-F): Postoperative photograph after correction of the presenting problems.

Fig. (4-A): Preoperative photograph “antero-posterior view” of a middle age lady with 3rd degree of breast ptosis and moderate form of macromastia.

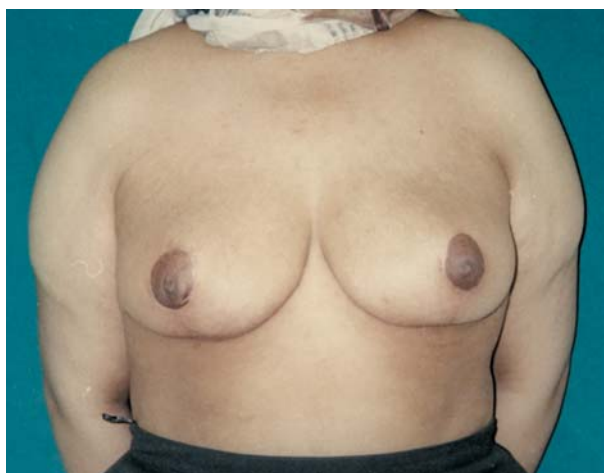

Fig. (4-B): Postoperative photograph with good size, shape, projection and symmetry.

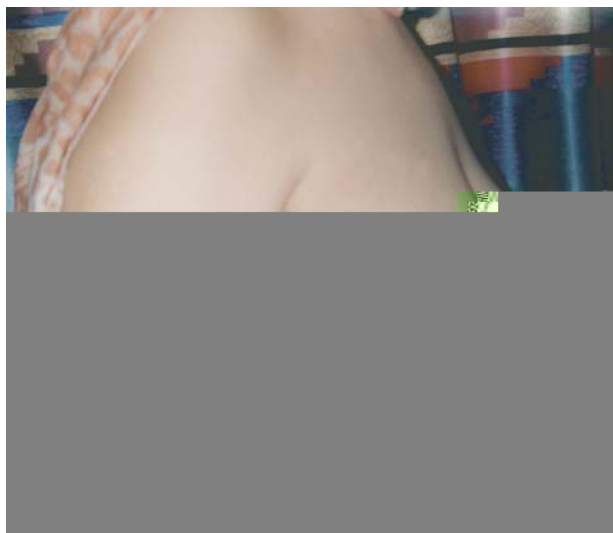

Fig. (4-C): Preoperative photograph “right lateral view” of the same patient.

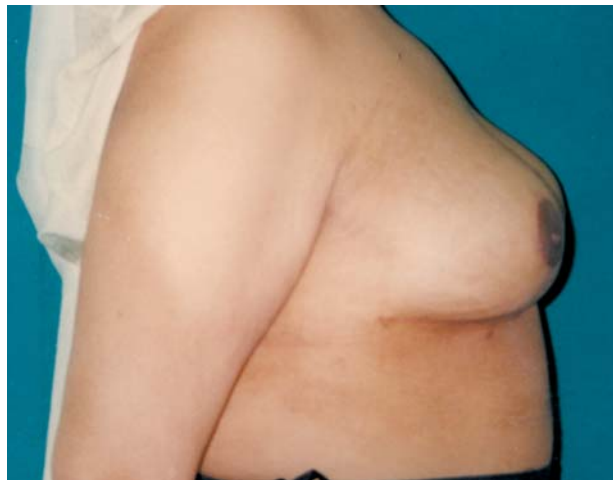

Fig. (4-D): Postoperative photograph showing correction of the presenting problems with upper pole fullness.

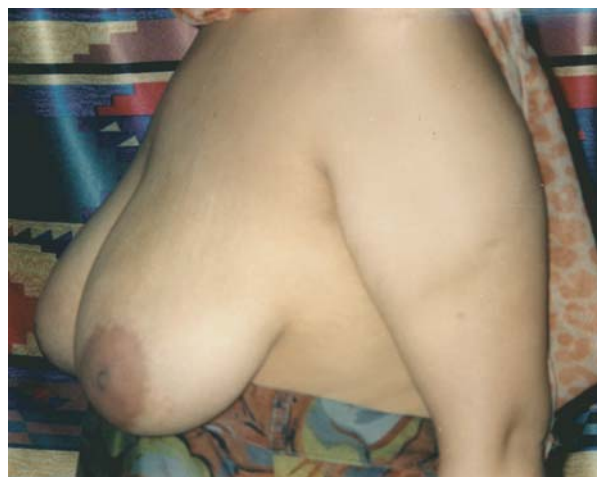

Fig. (4-E): Preoperative photograph “left lateral view” of the same patient.

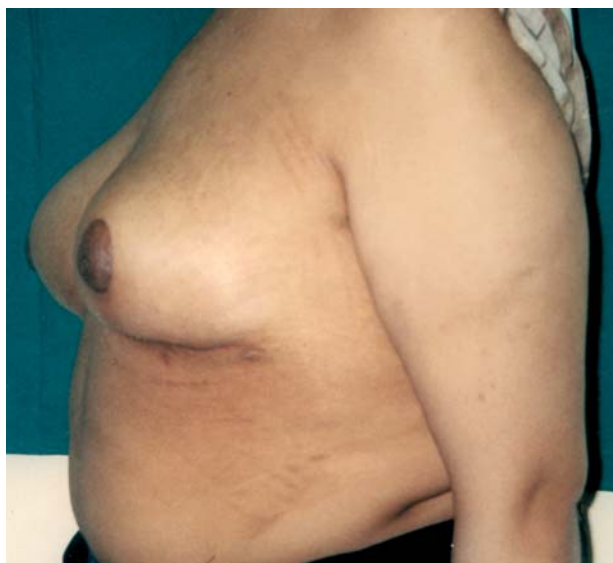

Fig. (4-F): Postoperative photograph good breast size and projection.

DISCUSSION

In this study, the youngest patient was 18 years old. Chiari [13] and others [14,15,16] had done reduction mammoplasty to patients 13 years old. We were conservative as regards the age limit.

In this study, the preoperative cup size ranged between C and DD with a mean of D size. The postoperative cup size ranged between B and C with a mean of B size. Beschert et al. [10] and Davis et al. [17] had reported that, they reduced the breast size by an average two and half cup size. Also, Di Giuseppe [16] had recorded breast reduction of three cup size. However, we regard that reduction of two cup size is sufficient to our cases. They prefer a breast with good volume and cosmetic shape and projection.

The NTD in this study was 6-12 cm with a mean of 10 cm. However, the case at which the NTD was 12 cm showed difficulty in transposition of the NAC to its newly designed site and resulted in nipple inversion. Gonzalez et al. [18] and Hudson and Skoll [14] in their series of parenchymal and inferior pedicle techniques reported transposition of NAC in a range of 10-14 cm. However, Frey's [11] maneuver of superior pedicle technique with dermis suspension can be used with NTD up to 10 cm without complications.

In this work, the excised tissue was 380-790 gm per breast with a mean of 620 gm. Chiari [13] in his series of 155 macromastia patients reported that the excised tissue ranged between 382-1280 gm per breast. However, this was 39 to 43 gm per breast in 23 patients with breast ptosis. Camarena and Vergara [19], using the superior-lateral pedicle, excised 310-1380 gm per breast with a mean of 520 gm. The average reduction weight with inferior pedicle, which can deal with breasts of large size was about 910 gm per breast [20]. However, in their series of solely inframammary approach, Schoeller et al. [15] excised 260-520 with an average 420 gm per side. Finally, any patient having the standard symptoms associated with macromastia should be considered a candidate for reduction mammoplasty regardless the amount of tissue to be removed [21].

Improvement in the preoperative symptoms especially neck, shoulder and back pain, painful bra strap grooves, back hyphosis and inframammary intertrigo were reported in our patients. Satisfaction with the cup size and nipple projection were recorded in thirty-four patients immediately postoperatively. In four cases, some re-touch was necessary to gain satisfaction. A greatest relief of the preoperative symptoms had been reported in many

series [17,22]. The patients were able to wear a T-shirt and bathing suit which was previously unsuitable for them and this improved both physical and social interaction [10].

In this study, partial or complete necrosis of the nipple-areola complex NAC was not recorded in any case. However, difficulty was recorded in one case at which the NTD was 12 cm in a highly glandular breast tissue, at which slight inversion was manifested. This necessitated a risky thinning of the subareolar tissue without affection of NAC vascularity. No nipple, areola or skin necrosis had been reported even in extremely large breast of superior pedicle technique of Marchac and Olarte [23] or parenchymal pedicle technique of Walton and Gonzalez [24]. In superior pedicle technique of Chiari [13], there was a slough of less than 10 percent of one areola probably due to excessive tension when the breast was reshaped. However, Davis et al. [17] reported an incidence of 6 percent in a series of 780 patients. This incidence was about 1.5 percent in the cases of Camarena and Vergara [19] using the superior-lateral pedicle technique. So, superior pedicle technique is not safe, regarding the vascularity NAC if NTD is more than 10 cm. For that reason Grant and Rand [25] recommended the central pedicle technique for such cases. Also, for large breasts with NTD greater than 10 cm, the inferior pedicle technique had the minimal risk of impairment of the blood supply of the NAC [26].

In this study, the sensibility of the NAC was affected in eight cases. This ranged between decreased sensibility to total unilateral anaesthesia. All of them recovered completely conservatively within a period of 4-10 months. There is a great controversy about the skin and NAC sensation. Most of the authors had agreed that regardless of the technique used there was a transient decrease or even loss of the NAC sensibility in about 25 percent of cases [12,23,24,17]. However, no patient had an insensitive NAC or breast skin after one year postoperatively regardless to the technique used [27,28]. It was reported that there is an inversely proportionate relationship between NAC sensibility and both of the amount of the excised tissue and the nipple transposition distance [18,27,29].

Terzis [30] and Farina et al. [31] recorded that sensation was present in the early postoperative period following reduction mammoplasty using free nipple-areola grafting technique and may continue to improve with time. The neurophysiologic basis for this observation is that the nipple-areola graft is placed onto a recipient bed that has

a rich dermal innervation from the supraclavicular nerves and the third intercostal nerve.

In this work, the possibility of lactation after breast reduction was tested only in three patients. Two of them reported that, they were unable to breast feed their babies. The third patient, stated that she had normal lactation. Preservation of most or all lactiferous ducts gives the maximal chance for possibility of lactation regardless to the reduction technique [11,24,19]. The importance of nipple-areola sensibility in neurologic feedback control of lactation process had been recorded [24].

In Scheoller et al. [15] study, which included 10 patients, for whom of a solely inframammary approach for reduction mammoplasty was done. Two patients became pregnant during the follow-up period and reported undisturbed breast feeding. Finally, Tairych et al. [32] stated that breast feeding was possible after all techniques except for free-nipple grafting.

In this study, complications as partial or complete NAC necrosis, breast abscess or total wound disruption were not recorded. However, triangular wound healing problems were presented in four patients (9.5%). Localized hematoma was found in one patient and fat necrosis in another one. All of them were treated conservatively. Walton and Gonzalez [24] recorded delayed wound healing as a result of partial or complete necrosis at the inverted T junction of the medial and lateral skin flaps in 10% of patients. Excessive tension on the skin flaps closure especially in smokers are liable to wound problems. So, it was advisable to stop smoking two weeks preoperatively. Walton and Gonzalez [24] reported fat necrosis in 10 percent of fatty smoker patients. Most of them resolved completely with conservative treatment within six weeks. However, excision biopsy was mandatory in one case to exclude carcinoma.

In this study, thirty-four patients (91.5%) were satisfied with the size, shape, symmetry of their breasts with an excellent projection and upper pole fullness. The other four patients were dissatisfied due to the developed hypertrophic scars. These scars were corrected later on. Davis et al. [17] reported satisfactory rate of 87% in their series of 780 patients and those who were dissatisfied gave unacceptable scarring as the most likely reason. However, marked over all patient's satisfaction secondary to scar reduction had been recorded [7,8,33].

Finally, the superior pedicle technique with mammary base closure is considered an excellent

option for reduction mammoplasty for moderately enlarged breast. It gives relief of all symptomatic macromastia and provides a conical breast with pleasing upper pole fullness and durable shape. It can also maintain an excellent NAC vascularity and acceptable sensibility. However, breast feeding can not be guaranteed to a great extent. Since the early reports of reduction mammoplasties at the beginning of this century, numerous techniques have been used for the procedure. This clearly reflects the fact that a single, ideal, "procedure for all seasons" has not been found. Some selected cases still need individual procedures.

REFERENCES

- 1- Goin M. K.: Psychological reaction to surgery of the breast. *Clin. Plast. Surg.*, 9: 347, 1982.
- 2- Strömbeck J.O.: Mammoplasty: Report of a new technique based on two-pedicle procedure. *Br. J. Plast. Surg.*, 13: 79, 1960.
- 3- Pitanguy I.: Surgical treatment of breast hypertrophy. *Br. J. Plast. Surg.*, 20: 78, 1967.
- 4- Roberston D.C.: The technique of inferior flap mammoplasty. *Plast. Reconstr. Surg.*, 40: 372, 1976.
- 5- Robbins T.H.: A reduction mammoplasty with the areola-nipple based on an inferior dermal pedicle. *Plast. Reconstr. Surg.*, 59: 64, 1977.
- 6- Georgiade N.G., Serafin D., Riefkohl R. and Georgiade G.S.: Is there a reduction mammoplasty for "all seasons"? *Plast. Reconstr. Surg.*, 63: 765, 1979.
- 7- Lejour M. and Abboud M.: Vertical mammoplasty without inframammary scar and with breast liposuction. *Perspect. plast. Surg.*, 4: 67-90, 1996.
- 8- Hall-Findally E.J.: Vertical breast reduction with a medially-based pedicle. *Aesth. Surg. J.*, 22: 185-194, 2002.
- 9- Giovanoli P., Simmen C.M., Meyer V.E. and Frey M.: Which technique for which breast? A prospective study of different techniques of reduction mammoplasty. *Br. J. Plast. Surg.*, 52: 52-59, 1999.
- 10- Boschert M.T., Barone C.M. and Puckett C.L.: Outcome analysis of reduction mammoplasty. *Plast. Reconstr. Surg.*, 98: 451-454, 1996.
- 11- Frey M.: A new technique of reduction mammoplasty dermis suspension and elimination of medial scars. *Br. J. Plast. Surg.*, 52: 45-51, 1999.
- 12- McKissock P.K.: Reduction mammoplasty with a vertical dermal flap. *Plast. Reconstr. Surg.*, 49: 245-252, 1972.
- 13- Chiari A.Jr.: The L-short scar mammoplasty: A new approach. *Plast. Reconstr. Surg.*, 90: 233, 1992.
- 14- Hudson D.A. and Skoll P.J.: Repeat reduction mammoplasty. *Plast. Reconstr. Surg.*, 104: 401-408, 1999.
- 15- Schoeller T., Wechselberger G., Bauer T., Otto A. and Piza-Katzer H.: Refinements in reduction mammoplasties from a solely inframammary approach. *Plast. Reconstr. Surg.*, 109: 1100, 2002.

- 16- Di Giuseppe A.: Breast reduction with ultrasound-assisted lipoplasty. *Plast. Reconstr. Surg.*, 112: 71, 2003.
- 17- Davis G.M., Ringler S.L., Short K., Sherrick D. and Bengtson P.B.: Reduction mammoplasty: Long-term efficacy, morbidity and patient satisfaction. *Plast. Reconstr. Surg.*, 96: 1106, 1995.
- 18- Gonzalez F., Walton R.L., Shafer B., Matory Jr.W.E. and Borah G.L.: Reduction mammoplasty improves symptoms of macromastia. *Plast. Reconstr. Surg.*, 91: 1270, 1993.
- 19- Camarena L.C. and Vergara R.: Reduction mammoplasty with superior-lateral dermoglandular pedicle: another alternative. *Plast. Reconstr. Surg.*, 108: 1448, 2001.
- 20- Chalekson C.P., Neumeister M.W., Zook E.G. and Russel R.C.: Outcome analysis of reduction mammoplasty using the modified robertson technique. *Plast. Reconstr. Surg.*, 110: 71-79, discussion 80-1, 2002.
- 21- Miller A.P., Zacher J.B., Berggren R.B., Falcone R.E. and Monk J.: Breast reduction for symptomatic macromastia: can objective predictors for operative success be identified? *Plast. Reconstr. Surg.*, 95: 77, 1995.
- 22- Korchin N.C. and Korchin L.: Vertical versus wise pattern breast reduction: Patient satisfaction, revision rates and complications. *Plast. Reconstr. Surg.*, 112: 1573-8; discussion 1579-81, 2003.
- 23- Marchac D. and Olarte G.: Reduction mammoplasty and correction of ptosis with a short inframammary scar. *Plast. Reconstr. Surg.*, 69: 45, 1982.
- 24- Walton R. and Gonzalez F.: The parenchymal pedicle technique for reduction mammoplasty. In M. Cohen (ed), *Mastery of Surgery: Plast. Surgery*, Boston: Little, Brown, 1993.
- 25- Grant J.H. 3rd and Rand R.P.: The maximally vascularized central pedical breast reduction: evolution of a technique. *Ann. Plast. Surg.*, 46: 584, 2001.
- 26- Erdogan B., Ayhan M., Deren O. and Tuncel A.: Importance of pedicle length inferior pedicle technique and long-term outcome of areola-to -fold distance. *Aesth. Plast. Surg.*, 26: 436, 2002.
- 27- Greuse M., Hamdi M. and De Mey A.: Breast sensitivity after vertical mammoplasty. *Plast. Reconstr. Surg.*, 107: 970, 2001.
- 28- Hamdi M., Greuse M., Nemec E., Deprez C. and De Mey A.: Breast sensation after superior pedicle versus inferior pedicle mammoplasty: anatomical and histological evaluation. *Br. J. Plast. Surg.*, 54: 43, 2001.
- 29- Mc Culley S.J. and Rousseau T.E.: A modified chiari L short-scar mammoplasty-the technique and results. *Br. J. Plast. Surg.*, 52: 112, 1999.
- 30- Terzis J.K.: Functional aspects of reinnervation of free skin grafts. *Plast. Reconstr. Surg.*, 58: 142, 1976.
- 31- Farina M.A., Newby B.G. and Alani H.M.: Innervation of the nipple-areolar complex. *Plast. Reconstr. Surg.*, 66: 497, 1980.
- 32- Tairych G., Worseg A., Kuzbari R., Deutinger M. and Holle J.: A comparison of long-term outcome of six techniques of breast reduction. *Handchir. Mikrochir. Plast. Chir.*, 32: 159, 2000.
- 33- Qiao Q., Sun J., Liu C., Liu Z. and Zhao R.: Reduction mammoplasty and correction of ptosis: dermal bra technique. *Plast. Reconstr. Surg.*, 111: 1122, 2003.
- 34- Blondeel P.N., Hamdi M., Van de Sijpe K.A., Van Landuyt K.H. and Thiesse Monstrey S.J.: The latero-central glandular pedicle technique for breast reduction. *Br. J. Plast. Surg.*, 56: 348, 2003.
- 35- Graf R., Reis de Araujo L.R., Rippel R., Neto L.G., Pace D.T. and Biggs T.: Reduction mammoplasty and mastopexy using the vertical scar and thoracic wall flap technique. *Aesth. Plast. Sur.*, 27: 6, 2003.