

## The Modified External Oblique Musculocutaneous Flap for Reconstruction of Extensive Post-Mastectomy Radio Necrosis: Clinical and Anatomical Study

ABDEL-FATTAH M. ABDALLAH ABDEL-FATTAH, M.D.\*; IMAN LABIB SALEM, M.D.\* and WAGEIH EL-BARANY, M.D.\*\*

*The Plastic & Reconstructive Surgery Unit\* and Anatomy Department\*\*, Faculty of Medicine, Alexandria University.*

### ABSTRACT

Defects resulting from resection of post-mastectomy radio necrosis can be quite large, posing a difficult reconstructive challenge. Pectoralis major, latissimus dorsi, rectus abdominis and omental transposition flaps, with split-thickness skin grafts, have been recommended for closure of chest-wall defects. What is often excluded from the list of reconstructive operation is the external oblique musculocutaneous flap. The anatomical dissection of 25 cadavers showed that the external oblique muscle has 3 sources of blood supply which are the deep circumflex iliac artery, the iliac branch of iliolumbar artery and the lower eight posterior intercostals arteries. In our series of 14 consecutive patients treated at Alexandria Main University Hospital in the period from March 2001 through June 2002, the extended external oblique musculocutaneous flap, with a new modification in operative technique, was utilized in the reconstruction of chest-wall defects and is herein described. The flap is drawn as a V-Y rotation flap on the ipsilateral abdominal wall. The ages of patients ranged between 38 to 69 with a mean of 56.3 years and all of them presented with post-irradiation necrosis of the chest wall. The mean chest-wall defect measured 25X18 cm. The results were satisfactory with only partial flap necrosis in one case. Neither functional disability, from rotating the external oblique muscle, nor any chest complication, as a result of the excision, has been encountered in this series.

### INTRODUCTION

Reconstruction of chest-wall defects following extirpation of large post irradiation necrosis of the site of the mastectomy operation, remains a formidable challenge for reconstructive surgeons. The defects resulting from such resections are often quite large and could involve not only the soft tissues but also ribs and sternum with extensions into the pleural cavity, necessitating rib resection and chest-wall reconstruction with nonautologous material [1].

Simple skin grafting is not usually a viable option because of the poor vascularity of the receiv-

ing bed due to radiation and/or the use of synthetic material sometimes applied for the rigid reconstruction of the chest wall. Traditionally, a number of local and pedicled flaps have been used for coverage of such defects. These include the pectoralis major [2], latissimus dorsi [3], rectus abdominis [4] and omental transposition flaps with split-thickness skin grafts [5]. In patients with large breasts, flaps to cover the chest wall defect can be harvested from the contralateral breast [6]. Free tissue transfer remains the ultimate option when local flaps are unavailable. Small to moderate-sized midline chest-wall defects could be covered with a pectoralis major muscle flap. This is usually done by advancing the muscle or by creating a turnover muscle flap. The latissimus dorsi musculocutaneous flap is often used dependably for defects of the anterolateral thorax. Its usefulness is limited in defects positioned superiorly or inferomedially on the chest wall. Pedicled rectus abdominis flaps are used reliably in a transverse or vertical fashion depending on the coverage needed. Paucity of the donor tissues and the difficulty of positioning of the skin paddle need to be considered carefully in the preoperative evaluation of such patients. An omental flap based on gastroepiploic pedicle could result in adequate coverage of a chest-wall defect. This requires a laparotomy and preoperative assessment of the availability of omental tissue for harvest remains unreliable short of laparoscopy [7].

The external oblique muscle is a large, flat and easily accessible muscle of the anterolateral side of the abdominal wall. It has been considered to have a purely segmental blood supply arising from the intercostals arteries [1]. It is classified as type IV according to Mathes and Nahai [8], its blood

supply is from multiple pedicles of similar size. In view of this vascular supply, a microsurgical transplantation of the muscle as a free flap was considered impractical, since it would have required multiple vascular anastomoses to ensure flap survival [9].

## PATIENTS AND METHODS

### *Anatomical study:*

The vascular and nerve supply of the external oblique muscle were studied in 25 cadavers (seven fresh and eighteen preserved). The external iliac artery was ligated proximal to the origin of the deep circumflex iliac artery, then the femoral artery was ligated below the inguinal ligament. The segment in between the two ligatures was cannulated and injected with red latex mixed with lead oxide. The internal mammary artery was also injected at its origin from the subclavian artery.

The external oblique muscle was dissected and its neurovascular supply was identified. The length of the deep circumflex iliac artery pedicle to the muscle was measured and its diameter was measured, as well, using the Swiss mechanic caliber (accurate measurement till 0.05 mm).

The nerves supplying the external oblique muscle were dissected out carefully in all cadavers and their point of entry into the muscle was marked out on the thoracic and abdominal walls.

### *Clinical study:*

This was carried out on 14 females suffering from post-irradiation necrosis of the chest wall starting from March 2001 through June 2002.

### *Excision of the radio necrosis area:*

The area of radio necrosis is excised completely including the area of ulceration as well as hyperpigmentation. In depth, the excision should reach down to healthy tissues. Any necrotic costal cartilage is removed. Subperiosteal rib resection of any doubtful anterior rib section is carried out. As a matter of fact, excision of up to 2 ribs would not affect the integrity, rigidity or proper functioning of the rib cage [10].

Excision of the soft tissue block should be more or less triangular with the apex tapering towards the axilla.

### *Flap design:*

This flap can be simply described as ipsilateral, V-Y rotation, musculocutaneous, laterally based, external oblique flap which, includes the dynamic territory of the external oblique muscle from the posterior axillary line to the linea alba. The flap territory is drawn as follows (Fig. 1):

a- The upper limit of the flap corresponds to the lower border of the excised radio necrotic area on the anterior chest wall.

b- The medial border of the flap is a direct extension of the medial border of the excised radio necrotic area and is drawn along the midline of the abdomen (linea alba) down to just above the umbilicus.

c- The lateral limit of the flap extends from the apex of the triangulated anterior chest wall excision, in the axilla, along the posterior axillary line to a point just above the iliac crest. The line that joins this point to the lower point of the medial limb of the flap, above the umbilicus, represents the lower limit of the dynamic part of the external oblique muscle and aponeurosis that will be incorporated in the flap (Fig. 2).

d- A V-shaped downward extension of the flap is drawn with the line joining the lower limits of the medial and lateral boundary of the flap, *vide supra*, as its base. The apex of the V is located somewhere on the midclavicular line, midway between the umbilicus and symphysis pubis.

### *Flap raising:*

a- Incise the medial border of the flap down to the anterior rectus sheath.

b- Incise the V-extension down to the external oblique aponeurosis and dissect it upwards in that plane until we reach the base of the V, *vide supra*, where we incise the external oblique transversely across and include it in the flap.

c- Continue dissecting in the plane between the external and internal oblique muscles upwards towards the defect, laterally towards the posterior axillary line and medially to the linea semilunaris.

d- Incise the anterior rectus sheath along the linea alba down to the umbilicus and then across laterally. Elevate the medial edge of the anterior rectus sheath and fix it to the skin of the medial edge of the flap temporarily with few tacking stitches to prevent shearing.

e- Dissect the anterior rectus sheath laterally to the linea semilunaris. Then cut the lateral border of the rectus sheath from below upwards thus including it in the flap in continuity with the external oblique.

f- Sever the origin of the first three digits of the external oblique fleshy muscle from their respective ribs to facilitate smooth rotation of the huge flap into the defect.

g- Meticulous haemostasis should be carried out. The intercostals musculocutaneous perforators will be seen issuing sequentially through the internal oblique somewhere between the anterior and posterior axillary lines and should be preserved (Fig. 3).

h- Replace the missing anterior rectus sheath above the umbilicus by a sheet of polypropylene mesh fixed, with 3-0 prolene stitches, upwards to the origin of the rectus abdominis, below to the remaining portion of the sheath above the umbilicus, medially to the linea alba and laterally to the linea semilunaris, where the posterior leaf of the internal oblique aponeurosis joins that of the transversus abdominis to form the posterior sheath (Fig. 4).

i- The flap is fixed in place, after rotating it into the defect by an inner layer of interrupted 1 vicryl inserted through the deep part of the subcutaneous tissue and so oriented as to fix the flap in its new place and meantime avoid creating tension lines. Then the skin is closed with 2-0 prolene interrupted stitches instituting a fine adjustment that is tension-free.

j- The V-shaped extension is closed in a V-Y fashion in two layers like the rest of the flap.

k- Two negative pressure tube drains are left under the flap; one to drain the area over the chest and the other to drain the lower territory of the flap.

## RESULTS

### *Anatomical results:*

The muscle was found to get arterial supply from three sources:

#### *a- Deep circumflex iliac artery:*

The deep circumflex iliac artery was found to be the largest arterial pedicle to the external oblique muscle in twenty-three of the cadavers dissected

(92%). It had an average diameter of 2 mm (ranging from 1.7 to 2.4 mm).

It arose from the lateral aspect of the external iliac artery. It gave several perforating branches to the abdominal muscles and overlying skin. The largest branch had an average diameter of 0.9 mm (ranging from 0.6 to 1.3 mm) and was found to supply the external oblique muscle in all the cases (100%).

#### *b- The iliac branch of the iliolumbar artery:*

The iliac branch of the iliolumbar artery gave separate branches to the transversus abdominis, internal oblique and the external oblique muscles. The branch to the internal oblique gave a branch that anastomosed with a branch from the deep circumflex iliac artery. From this anastomosis branches arose to pierce the internal oblique to supply the external oblique muscle.

In 2 cases (8%), the deep circumflex iliac artery did not give blood supply to the external oblique muscle. In these cases the iliac branch of the iliolumbar artery gave an anastomosing branch to the deep circumflex iliac artery and then gave branches that took the same course as the corresponding branch of the deep circumflex iliac artery.

#### *c- The posterior intercostal arteries:*

The lower eight posterior intercostal arteries gave segmental pedicles to the external oblique muscle. They entered the undersurface of the muscle mostly between the posterior and anterior axillary lines. These pedicles had an average diameter of 0.9 mm (ranging from 0.5 to 1.6 mm).

#### *Nerve supply:*

It was found that the external oblique muscle was supplied by lateral cutaneous branches of the fifth to the twelfth intercostal nerves. These branches pierced the external intercostals and the external oblique muscles along a curved line that extended from anterior axillary line cranially to the posterior axillary line caudally. It gave an anterior and posterior branches, the anterior branch supplied the external oblique muscle then supplied the skin of the lateral and ventral parts of the abdomen.

The lateral cutaneous branches of the fifth to the twelfth intercostal nerves passed between the internal and transversus abdominis muscles, and then penetrated the former to supply the external oblique muscle.

*Clinical results:*

Our study include 14 female patients. The mean age was 56.3 years. The longest follow-up was 14 months. All patients had external had external beam radiation to the chest wall and 50% of then had received chemotherapy prior to their external oblique myocutaneous flap reconstruction. Five patients had diabetes mellitus.

The mean chest-wall defect covered with an ternal oblique myocutaneous flap measured 25 x 18 cm. The largest defect measured 28 x 22 cm. and the smallest was 20 x 12 cm.

All donor sites were closed primarily, obviating the need for split thickness skin grafts. Average operative time for reconstruction was below 2.5

hours. Drains were removed on postoperative day 5 in most of the patients, and most of the patients were sent home on postoperative day 10.

The results were satisfactory (Figs. 5,6). There were no major flap losses, however, one partial flap loss occurred in a 69-year-old female who was diabetic (Fig. 7). This patient lost about 5 x 5 cm. of distal flap over its random portion, i.e. the V-extension, which was debrided and skin grafted on th 6<sup>th</sup> day postoperatively. There were no abdominal hernias, or hematoma observed. One patient developed mild seroma under the flap which needed evacuation by opening one stitch in the most dependent part of the flap, it took 15 days to disappear completely.

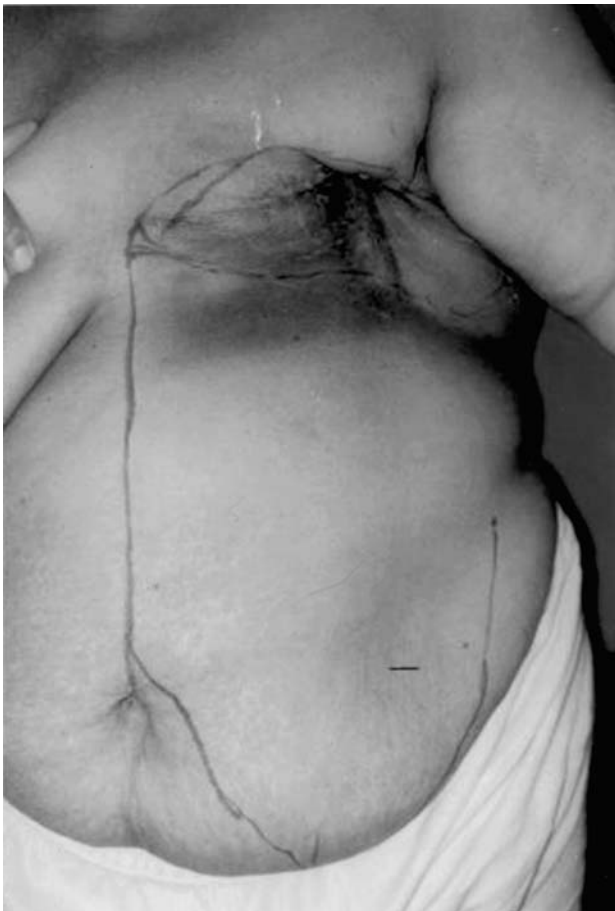

Fig. (1): Pre-operative marking of the extended external oblique flap and the extent of the excision of the radio necrotic tissues.

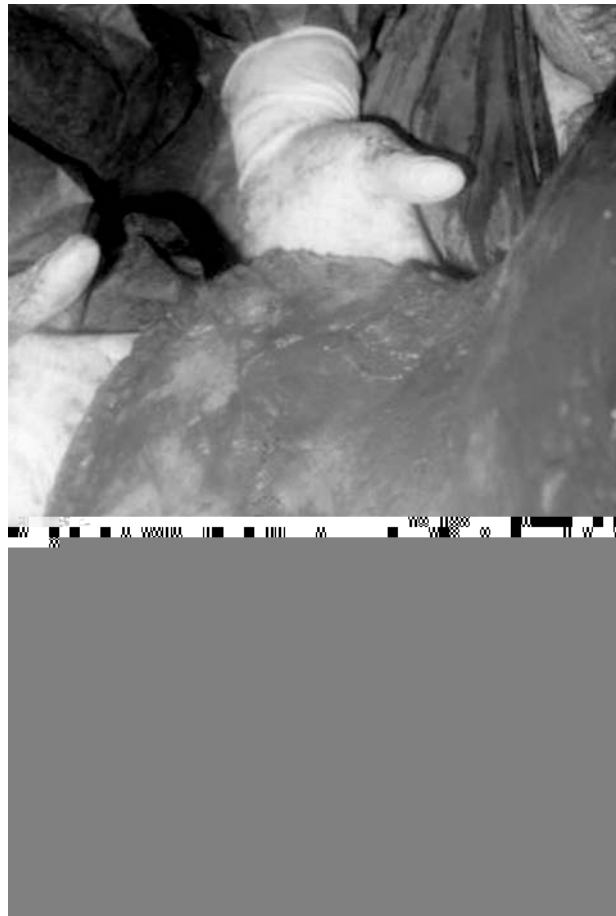


Fig. (2): An operative view showing the lower limit of the dynamic part of the external oblique muscle and aponeurosis (→) and the V-extension of the flap (↔).



Fig. (3): The intercostals musculocutaneous perforators are seen issuing sequentially through the internal oblique somewhere between the anterior and posterior axillary lines.

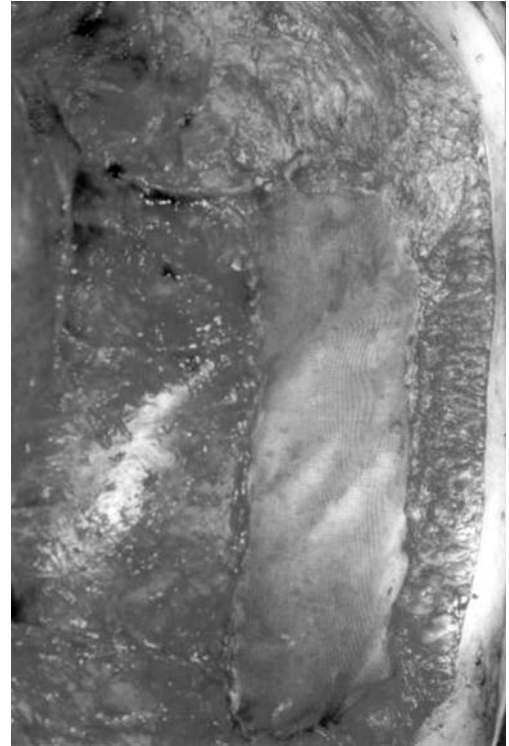
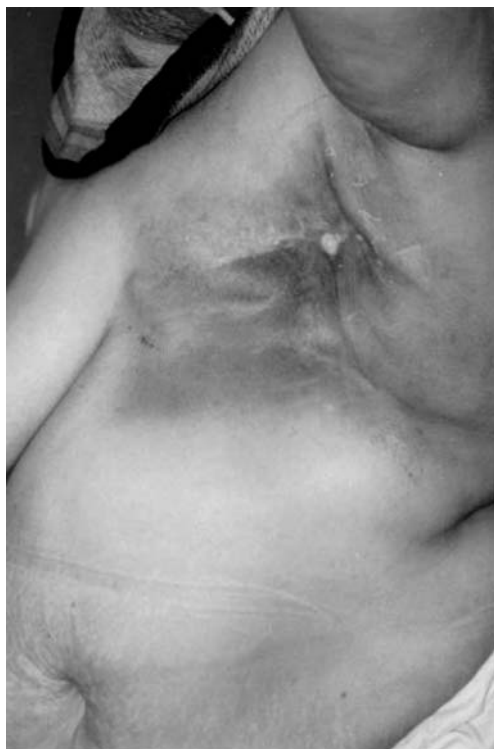
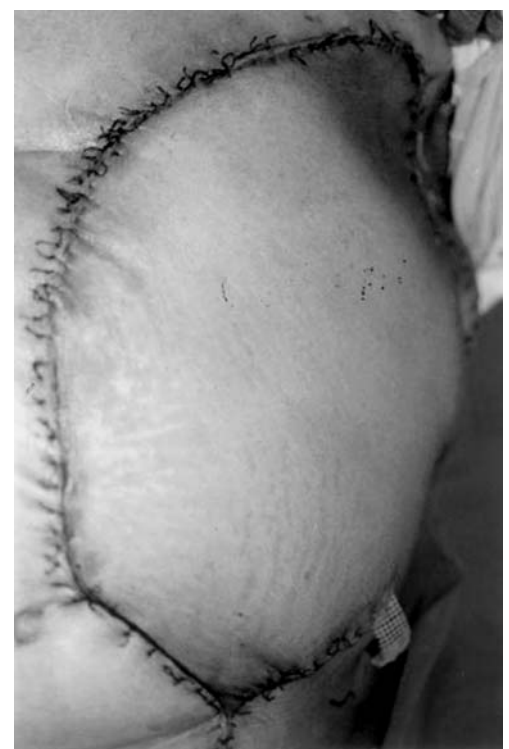
Fig. (4): An intra-operative view showing the polypropylene mesh fixed upwards to the origin of the rectus abdominis, below to the remaining portion of the sheath above the umbilicus, medially to the linea alba and laterally to the linea semilunaris.



(Left)



(Right)

Fig. (5): (Left) pre-operative view showing post-irradiation necrosis of the left side of the chest wall. (Right) 10 days post-operative view of the huge extended external oblique flap with complete coverage of the defect and excellent healing.

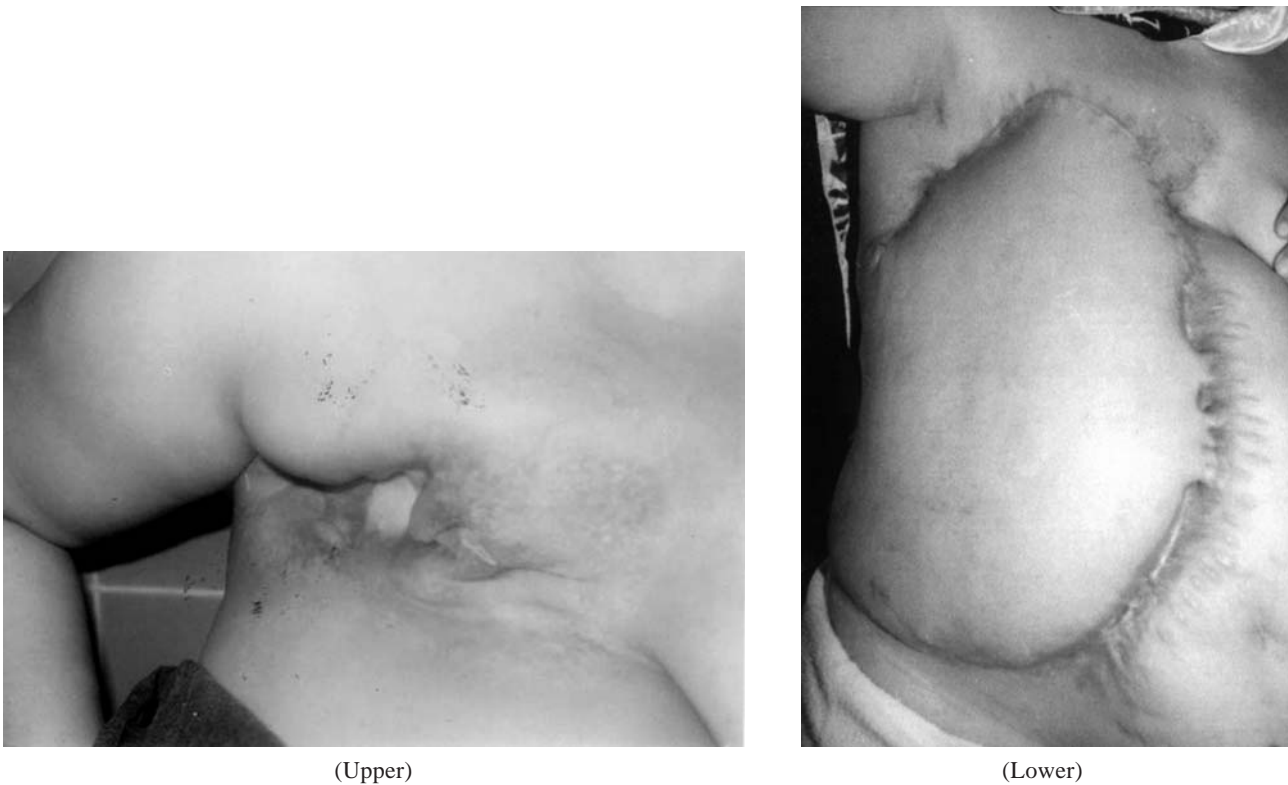


Fig. (6): (Upper) pre-operative view showing severe radio-necrosis of the right chest wall with exposed necrotic 2 ribs. (Lower) late post-operative view showing complete coverage of the defect and excellent healing of the flap.



Fig. (7): Post-operative view showing partial flap loss occurred in a 69-year-old diabetic female.

## DISCUSSION

External oblique musculofascial flaps were first used by Lesnick and Davids [11] for closure of lower abdominal defects in the early 1950s, and has been introduced as a myocutaneous flap in 1964 by Hershey and Butcher [12]. The external oblique

myocutaneous flap has been used successfully for coverage of chest-wall and pelvic defects by other authors [9,13-14]. The extended external oblique myocutaneous flap has been used for reconstruction of large chest wall defects by Moschella and Cordova in 1999 [15]. However, this useful flap remains virtually unknown and underutilized by most reconstructive plastic surgeons reporting their results from major centers [16].

The external oblique muscle is the largest and strongest of all flat abdominal muscles. It originates from the outer surfaces of the lower eight ribs and fans out to be inserted into the xiphoid process, the linea alba, the pubic crest, the pubic tubercle and the anterior half of the iliac crest. The majority of the fibers are inserted by means of a broad aponeurosis [17]. The external oblique muscle has been considered to have a purely segmental blood supply by means of multiple deep perforators from the sixth to the twelfth posterior intercostal arteries. Since these vessels interdigitate throughout the muscle, flap viability is secured if one or more of these perforators are divided inadvertently while raising the flap [1].

Our anatomical study showed that the external oblique muscle gets one or two branches of the deep circumflex iliac artery which contribute significantly to the main blood supply of the muscle. In fact, these branches could be considered the dominant vascular pedicle of the muscle because they are larger than the segmental pedicles.

The success rate with this flap in the present series is extremely gratifying as we have only encountered partial necrosis of the random part (V-extension) in an area of about 5X5 cm in a 69-year-old diabetic female. This is quite acceptable for such an atherosclerotic, irradiated female. It is also comparing favorably with Moschella and Cordova's series [15], who reported a single case of necrosis of the superomedial edge of the flap which required excision and suturing in a series of 13 patients with resection of the chest wall for primary breast carcinoma [8], severe radio dermatitis [4] and neurofibroma [1]. In our series the 14 patients had severe radio necrosis following extirpation of primary breast cancers and post-operative radiotherapy.

The external oblique myocutaneous flap offers a well-perfused composite tissue for reconstruction. It is capable of reaching the third ipsilateral rib space superiorly and up to 5 cm beyond the midline, depending on the laxity of the skin over the anterior abdominal wall. It can cover big areas up to 28X22 cm i.e. 616 cm<sup>2</sup> in our series and up to 500 cm<sup>2</sup> in Moschella and Cordova's series [15].

The extended external oblique musculocutaneous flap has the added advantage of filling in the depth created by excision of radio necrotic area, thus obliterating the dead spaces.

Its robust blood supply can assure primary intention healing in the irradiated patients and old age ones.

Its learning curve is not so steep and can be perfected over a short period of time.

It cuts down the time of the operation when compared to the latissimus dorsi myocutaneous flap because you do not need to change the patient's position on the operating table at different stages of the operation. As well, you do not need any grafts and thus avoid their drawbacks and save the time for fixing them in place of the donor flap.

From the viewpoint of the technique ours differs from that of Moschella and Cordova's [15] in the following:

- We undermine in the plane between the external and internal oblique from below upwards and from lateral to medial side towards the linea semilunaris. Then we lift the anterior rectus sheath and cut the linea semilunaris under vision from below upwards. This saves inadvertent lifting of the internal oblique with anterior leaf of its aponeurosis which forms, together with external oblique aponeurosis, the anterior rectus sheath above the umbilicus. Thus avoiding the feeding intercostals which lie between the internal oblique and the transeversus abdominis.
- We replace the anterior rectus above the umbilicus with polypropylene mesh fixed to the linea alba and linea semilunaris. In the original technique the internal oblique is fixed with non absorbable sutures to the linea alba which is practically rather difficult and imposes great tension on the internal oblique.

## REFERENCES

- 1- Bogossian N., Chaglassian T., Rosenberg P.H. and Moore M.P.: External oblique myocutaneous flap coverage of large chest-wall defects following resection of breast tumors. *Plast. Reconstr. Surg.*, 97: 97, 1996.
- 2- Arnold P.G. and Paroleiro P.C.: Use of pectoralis major muscle flaps to repair defects of anterior chest wall. *Plast. Reconstr. Surg.*, 63: 205, 1979.
- 3- Salmon R.J., Razaboni R. and Soussaline M.: The use of the latissimus dorsi musculo-cutaneous flap following recurrence of cancer in irradiated breasts. *Br. J. Plast. Surg.*, 41: 41, 1988.
- 4- Webster D.J. and Hughes L.E.: The rectus abdominis myocutaneous flap in breast cancer. *Br. J. Surg.*, 70: 71, 1983.
- 5- Petit J.Y., Lacour M.D. and Margull S.A.: Indications and results of omental pedicle grafts in oncology. *Cancer*, 44: 2343, 1979.
- 6- Marshall D.R.: The contra lateral breast flap in reconstruction of the breast and chest wall. *Ann. Plast. Surg.*, 31: 508, 1993.
- 7- Larson D.L. and McMurtrey M.J.: Musculocutaneous flap reconstruction of chest-wall defects: An experience with 50 patients. *Plast. Reconstr. Surg.*, 73: 734, 1984.
- 8- Mathes S.J. and Nahai F.: Classification of the vascular anatomy of muscles: Experimental and clinical correlation. *Plast. Reconstr. Surg.*, 67: 177, 1981.
- 9- Meland N.B., Ivy E.J. and Woods J.E.: Coverage of chest wall and pelvic defects with the external oblique musculofasciocutaneous flap. *Ann. Plast. Surg.*, 21: 297, 1988.
- 10- McCormack P., Bains M.S., Beattie E.J. and Martini N.: New trends in skeletal reconstruction after resection of chest wall tumours. *Ann. Thorac. Surg.*, 31: 45-52, 1981.

- 11- Lesnick G.J. and Davids A.M.: Repair of surgical abdominal wall defect with pedicle musculofascial flap. *Ann. Surg.*, 137: 569, 1953.
- 12- Hershey F.B. and Butcher H.R.Jr: Repair of defects after partial resection of the abdominal wall. *Am. J. Surg.*, 107: 586, 1964.
- 13- Hodgkinson d.J. and Arnold P.G.: Chest wall reconstruction using the external oblique muscle. *Br. J. Plast. Surg.*, 33: 216, 1980.
- 14- Chandrasekhar B., Sloan G.M. and Beatty J.D.: The external oblique myocutaneous flap for extended hemipelvectomy reconstruction. *Cancer*, 62: 1022, 1988.
- 15- Moschella F. and Cordova A.: A new extended external oblique musculocutaneous flap for reconstruction of large chest-wall. *Plast. Reconstr. Surg.*, 103: 1378-85, 1999.
- 16- Samuels L., Granick M.S., Ramasastry S., et al.: Reconstruction of radiation-induced chest wall lesions. *Ann. Plast. Surg.*, 31: 399, 1993.
- 17- Snell R.S.: *Clinical Anatomy for Medical Students*. 2<sup>nd</sup> ed. Boston; Little, Brown and Company, 128, 1981.