

Total Reconstruction of the Auricle in Lobule-Type Microtia

KHALED MAKEEN EL-RIFAIE, M.D.

The Department of Surgery, Faculty of Medicine, Cairo University.

ABSTRACT

Total auricular reconstruction in lobule-type microtia is one of the most challenging problems facing a reconstructive surgeon as it demands precise technique combined with artistic creativity. Ear reconstruction requires a carefully planned procedures of different techniques. In this article we use a good, easy method consists of 2 stages reconstruction. The first stage is construction of the cartilage framework from the ribs and use of a skin pocket. The second stage is 3 months later to elevate the ear and lobule transposition. This method was used in 12 patients with lobule-type microtia. Analysis of the results has shown a high level of satisfaction and good aesthetical balance.

INTRODUCTION

The term microtia indicates a small, abnormally shaped or absent external ear. The occurrence of this abnormality is about once in every 6000-12000 births [1]. It is the most common major congenital anomaly of the external ear. The affected ear usually has conductive hearing loss (about 40-60 dB) secondary to lack of an external auditory canal and to ossicular fixation [2]. Genetic studies have revealed several possible etiologic factors chromosomal aberrations, multifactorial inheritance and autosomal and recessive traits. The most common syndromes associated with microtia are Goldenhar syndrome, hemifacial microsomia and Treacher-collins syndrome.

Microtia is classified on a gradient from less severe (grade 1) to total absence of the external ear (anotia) [3].

Another classification into lobule-type and concha-type is also useful.

The lobule-type, is common among microtic auricular disorders. It is characterized by the presence of a sausage-shaped skin remnant of the ear and ear lobule without a concha, acoustic meatus and tragus.

The other type of microtia is the concha type which is characterized by ear remnant with a lobule, concha, acoustic meatus, tragus and incisura intertragica. It is thought to be milder than the lobule-type.

Lesser deformities are those of hypoplasia of the middle third or superior of the ear, cupear, lopear, cryptotia and cockle shell ear deformities [4].

The origin of microtia repair had its significant beginnings in 1920, when Gillies buried carved homograft rib cartilage under mastoid skin, then separated it from the head with a cervical flap. Pierce (1930) modified this method by lining the new ear's posterior surface with a skin graft and building the helix with a flap of rolled up skin. Young (1944) and Peer (1947) turned to autogenous rib cartilage banked in the abdominal skin and used later but with a poor results. A major break through came in 1959 when Tanzer rekindled using autogenous rib cartilage, which was carved in a solid block. His excellent results have persisted during the years [5]. Cronin introduced silicone ear framework, but suffered like all inorganic implants of high incidence of extrusion [6].

Fukuda [7] stated, in order to achieve all the necessary features for total auricular reconstruction, a one-piece three-dimensional costal cartilage framework consisting of a base frame, a valve like tragus, incisura intertragica, antitragus, anthelix, superior crus, inferior crus and helices were fabricated.

Furthermore in order to cover the fabricated frame various flaps and grafts in multiple stages were necessary before finally arriving at the end results.

Recently, interest in the pre-fabrication concept has been rekindled via modern tissue engineering techniques in which bovine cartilage cells are grown in the laboratory and seeded upon a synthetic ear from which is then implanted beneath the skin of a mouse. The early experimental results are interesting, but, it needs along time of effort and work before it can be applied to humans [8].

In this article, a reliable method of total auricular reconstruction for the severe lobule-type microtia is described. The results will be discussed in view of other techniques.

PATIENTS AND METHODS

Twelve patients with a lobule-type microtia were included in this study. All patients had the following characters of lobule-type microtia, absent pinna except for a vertical sausage-shaped skin remnant without a concha, acoustic meatus and tragus [4]. All the patients had a unilateral anomaly ten patients were males and two were females. The ages ranged from twelve to seven years with an average of eight years. We do not operate before the age of seven years so, as to have sufficient growth of the sound ear and costal cartilage. CT scanning is not needed except for counseling the patient about the candidacy of middle ear surgery.

Surgical protocol:

Preoperative planning:

The successful grafting of a well-sculpted three-dimensional cartilage framework is the foundation for a sound ear repair. A film pattern from the opposite normal ear was taken and reversed to plan the new framework (Fig. 1), then a new pattern several millimeters smaller in all dimensions to allow for the extra thickness which occurs when the cartilaginous framework is inserted under the skin. The ear's location is predetermined in the office by studding the opposite side and making facial measurements that help to achieve symmetry (Fig. 2).

Surgical stages:

Total external ear reconstruction in the lobule-type microtia requires basically two stages. We follow the procedures of Brent [9] and Nagata [4].

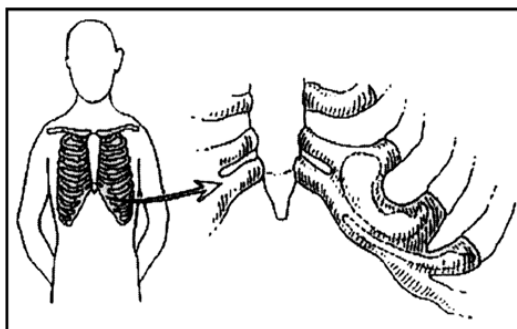


Fig. (1): Site of rib cartilage harvest for ear framework fabrication to take advantage of natural configuration, the cartilage is obtained from side opposite to ear being constructed [9].

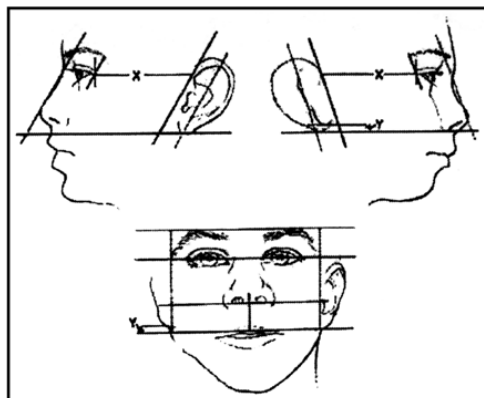


Fig. (2): Preoperative determination of auricular location. The ear's slant is positioned to match the opposite side, roughly parallel to the profile of the nose; the distance is matched from the corner of the eye and the microtic lobe's position is noted (usually displaced upward) when tracing the reverse film pattern, so that the lobe will eventually be positioned correctly when it is transposed into position and "spliced" into the new ear during the second stage of the surgical repair [9].

First stage:

Rib cartilage harvesting and framework insertion: We remove the rib cartilages through an oblique incision made just above the lower rib margin from the side opposite the ear being constructed. The cartilaginous portion of the six, seven and eighth rib is harvested according to the previously measured template. The six and seventh rib cartilages form the base framework and the eighth costal cartilage is used to form the rim or helix (Fig. 3).

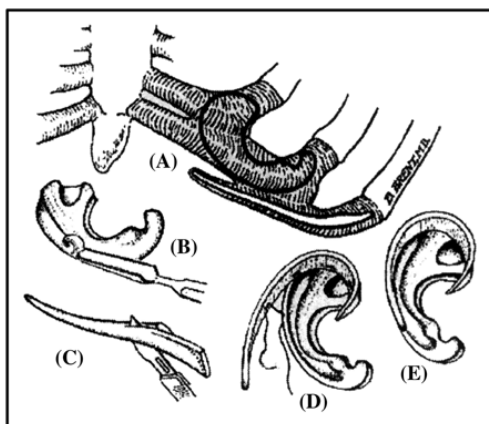


Fig. (3): Donor site: chest on side opposite to ear being repaired. The helical rim is obtained from "floating" rib cartilage, the main pattern from a fused block of two cartilages. (B) Sculpting the main block with chisel. (C) Thinning the "floating" rib cartilage to produce the helical rim. (D) Affixing the rim to the main framework with nylon sutures. Completed framework [9].

Using scalpels and sterilized wood-carving chisels we carve the basic ear from the main cartilage block preserving as much of the covering perichondrial tissue as possible on the outer aspect of the framework to facilitate its adherence to and subsequent nourishment from surrounding tissues, then the helical rim is creating by thinning of the peice from the floating eighth rib on its outer convex surface to cause deliberate wrapping in a favorable direction, then it fastens to the framework body with prolene sutures.

Finally, the living sculpture is completed by carving the rest of its details with chisels.

The skin pocket covering is created using first the film template and preoperatively determined measurements, we mark the ear position and make a small incision a long the ear vestige then dissecting the skin pocket removing the cartilage remnant beneath the skin.

We use the scissor to develop this thin skin "pocket", taking great care not to damage the small blood vessel network that nourishes the skin. To recruit sufficient tension-free skin coverage, the dissection is carried out beyond the marked ear outline.

Following this pocket creation, the three-dimensional framework is inserted in the pocket

with two small suction drains beneath and behind the framework. This creates a continuous suction that not only adheres the nourishing skin flap to the carved cartilage, but also prevents possible disastrous blood clots.

We pack the new ear's convolutions with Vaseline gauze and apply a bulky non-compressive dressing.

Patients are sent home on the average from 1-3 days on pain medication and antibiotics. The ear dressing is changed after 3 days. The drain stays on the average about 5 days and the sutures were removed on the average after seven days.

The next stage was proceeded approximately 3 months later.

Second stage:

After the first stage, the structure has an ear like contour, but still looks two-dimensional without a lobule. In this second stage, the idea of Brent [10] is followed which combines the procedures of ear lobe transposition and lifting the ear with a skin graft in one stage.

An incision is made both in front and behind the skin vestige which is then rotated into place and spliced to the cartilaginous framework and sutured, then a larger incision is made behind the newly constructed ear and the undersurface is undermined. The raw area is then lived by a partial-thickness skin graft from the thigh. The graft is secured in place by sutures and a tie-over dressing followed by ear dressing for seven days.

Follow up of cases was from 6 months up to two years.

RESULTS

The results of the reconstructed auricles were more or less satisfactory as regard the patients and the surgeon.

The complications ranged from small localized skin infection in one case treated with topical and oral antibiotics and healed nicely to catastrophic loss of the skin pocket in another case with exposure of the framework needing its removal and bank it under the arm skin for later reconstruction (Figs. 4,5).

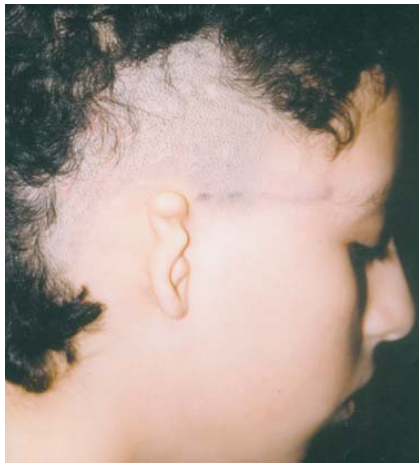

Fig. (4-A): Preoperative picture of lobule-type microtia.

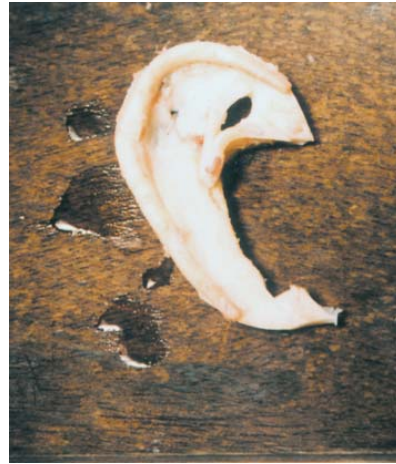

Fig. (4-B): The three-dimensional costal cartilage framework utilized for this case.

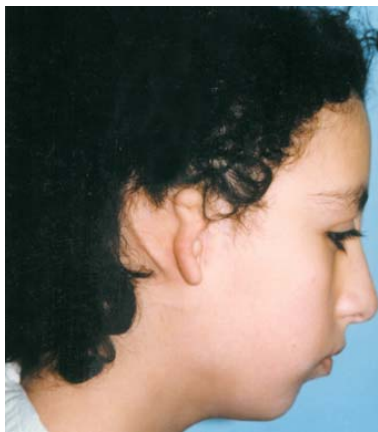

Fig. (4-C): The patient after the first stage with insertion of framework under the skin pocket.

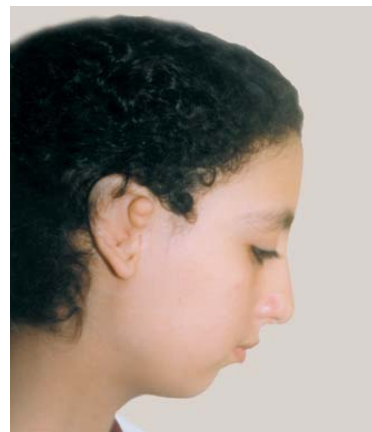

Fig. (4-D): The patient after the second stage with ear elevation and lobule-transposition.

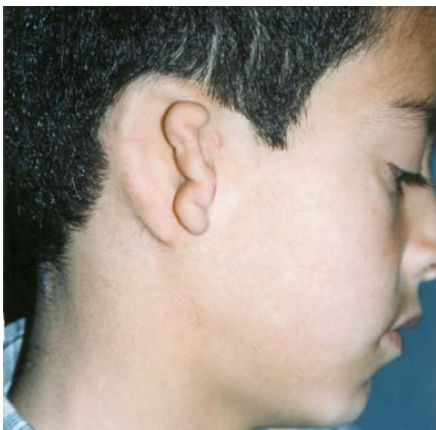

Fig. (5-A): A 9 year-old boy after the first stage with frame insertion.

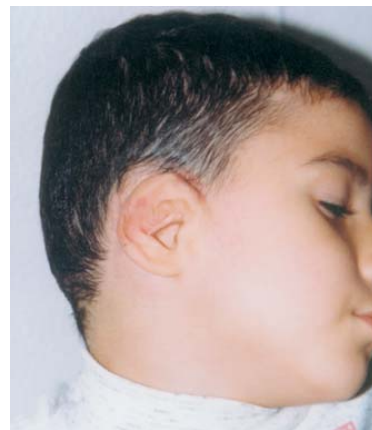

Fig. (5-B): The patient after the second stage with ear elevation and lobule-transposition.

DISCUSSION

Microtia, especially the lobular-type, represent one of the major craniofacial anomalies requiring total ear reconstruction which is a strenuous task for the plastic surgeon who must have technical knowledge, an accurate analysis of the case and a lot of imagination in order to repair the enormous variety of clinical cases [11]. Total auricular reconstruction is a constant challenge to recreate the complex cutaneous and cartilaginous structure that no one could create such perfection.

Microtia has an enormous emotional impact on family members, especially on parents psychological support and care are of great value in the whole treatment. Doctors can not neglect the serious emotional distress caused by the birth of an imperfect child. For the parents it is a great frustration to see their child born with serious physical problem. But, the surgeon should establish the adequate date for the surgery not influenced by family members who want immediate solution.

The ideal time for reconstruction of the ear is after the child is seven years old when the physical development of the ear has already reached a certain size and it will not cause a severe distortion between the reconstructed ear and the normal one. Another important surgical detail is the thickness of the costal cartilage that we use to sculpture the new framework. Before the age of seven this structure is still very fragile and thin, without adequate conditions for the creation of the new auricular framework once this is explained to the parents their anxiety will diminish, thus contributing to the success of the surgery [12].

For acquiring the ideal form and size of the earlobe by reconstruction, the technique used should satisfy some factors as follows:

- Sufficient soft tissue is easily available.
- The symmetrical balance is satisfactory.
- The smooth margin and thin form are maintained.
- The technique is simple and safe.
- The color and texture can be well matched compared with surrounding tissues.

Many technique are available for reconstruc-

tion of the ear in lobule-type microtia, each has advantages and disadvantages [13].

Basically, we need at least two components in total auricular reconstruction: The first is a framework matching the shape and contour of the ear and second is a soft tissue cover which must be thin and adequate. In cases of lobule-type microtia the framework should be large enough to give the adequate ear volume; so, conchal graft from the opposite auricle is not enough. The use of homologous cartilage was tried [14] but always absorbs and failed. The use of alloplastic frameworks was attractive at the beginning and several material were used as silicon rubber and polyethylene [8]. The use of porous polyethylene framework was widely used at a time with two stage procedure: The first stage involves rotating a superficial temporoparietal flap over the framework with skin graft and pocket. The second stage was a lobule trans-

polymer replacement inevitably led to loss of prosthesis shape with time.

Ongoing work with human chondrocytes and biodegradable matrices continues and one day might represent the standard of care in microtia repair. Maintenance of cartilage integrity with time and thus preserving a precise and delicate auricular architecture, remains the most significant hurdle to overcome before this technology is clinically feasible.

To this data, when tissue engineering can provide the ideal cartilage frames, sculpted autogenous rib cartilage remains the material of choice for surgical repair of lobule-type microtia.

Although various donor sites have been used for harvesting the cartilage, only rib cartilage provides a substantial source for fabricating total ear framework. Many authors support this concept as Osomo [11] and Nagata [4]. So, we continue refining and evolving the use of rib cartilage frameworks. The cosmetic outcome and least complication results in our series support this conclusion.

As regard the soft tissue cover of the framework we found the use of a skin pocket carefully dissected without a temporoparietal fascial flap is very useful in the first stage reconstruction, the fascial flaps with a skin graft over it is risky and the aesthetic results are much less as it masks the contour and details of the framework.

Also, in the second stage we elevate the ear with a skin graft only and appears to be satisfactory without a supporting block of cartilage. It was found that it was useful to perform ear lobule transposition in the second stage not at separate stage. Ear reconstruction from autogenous tissues withstand trauma remarkably well [5]. This observation is always found in all of the present cases.

In conclusion, analysis of the patients operated using the described technique, it became evident that the procedure using costal cartilage graft under a skin pocket followed by ear elevation with a skin graft only after 3 months, has demonstrated to be very reliable technique in cases of lobule-type microtia.

REFERENCES

- 1- Naki H.: Reconstruction of microtia with a contour accentuated framework and supplemental coverage. *Plast. Reconstr. Surg.*, 78: 604, 1986.
- 2- Bonilla J.A.: *Microtia Medical Journal*, July 8, Volume 3, Number 7, 2002.
- 3- Brent B.: Auricular repair with autogenous rib cartilage grafts: Two decades of experience with 600 cases. *Plast. Reconstr. Surg.*, 90: 355, 1992.
- 4- Nagata S.: Modification of the stages in total reconstruction of the auricle: Part 1 grafting the three-dimensional costal cartilage framework for lobule-type microtia. *Plast. Reconstr. Surg.*, 93, 2: 221, 1994.
- 5- Brent B.: Microtia repair with rib cartilage grafts: A review of personal experience with 1000 cases. *Clin. Plast. Surg.*, 29: 257, 2002.
- 6- Shanbhag A., Friedman M.I., Augustine J. and van Recum A.F.: Evaluation of porous polyethylene for external ear reconstruction. *Annals of Plastic Surg.* Vol., 24: 32, 1990.
- 7- Fukuder O.: Reconstruction of microtia II. The construction of cartilage framework. *Jap. J. Plast. Rec. Surg.*, 18: 685, 1975.
- 8- Cao Y., Vacanti J.P. and Paige K.T.: Transplantation of chondrocytes utilizing polymer-cell construct to produce tissue-engineered cartilage in the shape of human ear. *Plast. Reconstr. Surg.*, 100: 297, 1997.
- 9- Brent B.: Total auricular construction with sculpted costal cartilage. In Brent B. (Ed), *the artistry of reconstructive Surgery*, St. Louis. The C.V. Mosby Co., 1987.
- 10- Brent B.: Technical advances in ear reconstruction with autogenous rib cartilage graft. *Personal experience with 1200 cases.* *Plast. Reconstr. Surg.*, 104: 319, 1999.
- 11- Osomo G.: Autogenous rib cartilage reconstruction of congenital ear defects: Report of 110 cases with Brent's technique. *Plast. Reconstr. Surg.*, 104: 1951, 1999.
- 12- Brent B.: The pediatrician's role in caring for patients with congenital microtia and atresia. *Pediatr. Ann.*, 28: 374, 1999.
- 13- Yotsuyanag T., Yamashita K. and Sawada Y.: Reconstruction of congenital and acquired earlobe deformity. *Clinics in plast. Surg.*, 29: 249, 2000.
- 14- Steffenson W.H.: Comments on reconstruction of external ear. *Plast. Reconstr. Surg.*, 16: 194, 1955.
- 15- Saadeh P.B., Brent B. and Longacre: Human cartilage engineering: Chondrocyte extraction, proliferation and characterization for construct development. *Ann. Plast. Surg.*, 42: 509, 1999.