

The Reconstructive and Functional Role of Latissimus Dorsi Flap in Complex Upper Extremity Injuries

TAREK MAHBOUB, M.D.*; FOUAD M. GHAREEB, F.R.C.S.**; TAREK A. SAID, M.D.* and
WAEEL S. ABDELNASER, M.D.*

The Departments of Plastic Surgery, Faculties of Medicine, Cairo and El-Menoufiya** Universities.*

ABSTRACT

Severe upper extremity injuries are considered a potential source of significant disability. Appropriate soft tissue restoration is an essential component of any treatment protocol and often requires a vascularized flap to protect the neurovascular and musculo-tendinous structures. The use of latissimus dorsi muscle or myocutaneous flap is considered an ideal solution in such conditions as it provides reliable, well-vascularized soft tissue coverage to an extensive surface area. Also, it could provide a functional unit, as well, to compensate for flexion or extension deficits at the elbow resulting from traumatic loss of the effective muscle power for elbow flexion or extension. Latissimus dorsi pedicled muscle or myocutaneous flap were used for immediate soft tissue coverage in twenty-three patients with complex upper extremity injuries involving the arm and elbow. The muscle flap was used as a functional unit for elbow reanimation in 5 patients. The results were satisfactory with accelerated postoperative recovery and return of functional activity. Limb salvage were achieved in all patients except one with vascular graft occlusion necessitated above elbow amputation. The advantages of immediate coverage of such defects with latissimus dorsi flap were appreciated and it was concluded that this flap could be considered the flap of choice for such defect.

INTRODUCTION

Upper extremity injuries caused by road traffic accidents with massive soft tissue loss and concomitant musculoskeletal and neurovascular structural injuries necessitate urgent soft tissue coverage with a well-vascularized tissue to achieve early stable wound coverage, to protect the vital structures and to facilitate early functional recovery of the injured upper limb. Also, the need for functional reanimation of a deranged group of muscles acting on the elbow as a direct impact of the trauma is a target in the reconstructive plan [1-4].

In this type of injuries, the use of local flaps

including local skin transposition, muscle transposition or vascular axis would be contraindicated in a wide zone of injury (the base of these local flaps are damaged by high energy trauma) or when distal ischaemia is present because of arterial axis sacrifice [5,6,7].

The use of latissimus dorsi muscle or myocutaneous flap is considered an ideal solution in such conditions as it provides reliable, well-vascularized soft tissue coverage to an extensive surface area. Also, it could provide a functional unit, as well, to compensate for flexion or extension deficits at the elbow resulting from traumatic loss of the effective muscle power for elbow flexion or extension [8-12].

The purpose of this work is to evaluate the reliability and versatility of Latissimus dorsi flap in severe upper extremity injuries as well as its role in restoration of elbow function.

PATIENTS AND METHODS

Twenty three patients with complex upper extremity trauma were included in this study. Twenty patients were males and 3 were females, with their ages ranged between 7 to 53 years. All traumas were caused by road traffic accidents with variable expression of the mechanism of injury. Associated insults in the form of orthopedic, neurosurgical, maxillofacial, chest and abdominal injuries were diagnosed in 7 patients and were managed according to priority.

Concerning the local upper extremity injury, all shared a variable degree of soft tissue loss. Brachial artery injury was found in 9 patients. Major nerves injuries (median, ulnar and/or

radial) were found in 12 patients. Humeral fracture was found in 3 patients and smashed elbow was found in 6 patients.

All patients had undergone initial resuscitative measures and an individual treatment plan for the local and associated injuries was developed according to priority.

Local wound management in the form of local control of bleeding and temporary splinting followed by limb evaluation regarding the peripheral circulatory status, nerve dysfunction and orthopedic evaluation including radiological assessment. A multidisciplinary team approach according to the defined clinical and radiological data. Under GA, initial cleaning and debridement of the wound followed by final evaluation of the injured structures. Orthopedic management in the form of internal or external fixation followed by vascular repair in the form of saphenous interposition graft for brachial artery. The severed nerves were identified for later repair. Latissimus dorsi flap was harvested as a pedicled myocutaneous flap in 4 patients, as a muscle flap with overlying split skin graft in 19 patients. Split muscle flap was used in 5 patients with smaller defects. The flap was utilized as a cover only in 18 patients and as a functional unit as well in 5 patients, 3 as elbow extensor and 2 as elbow flexor. In such conditions, the aponeurosis of the latissimus dorsi muscle origin was anchored either to the remnant of the tendinous insertion of elbow flexor or extensor and if not adequate, it was anchored to the forearm bones.

In one patient, part of the muscle was used for nerve wrap around the ulnar nerve to provide a muscle bed separating the nerve from the comminuted bone of smashed elbow to prevent the possible delayed ulnar neuritis (Fig. 5). The donor site was closed primarily in all cases except one case with a large island myocutaneous flap that required application of a split skin graft.

Postoperative flap monitoring and distal limb vasculature with proper limb positioning to avoid muscle stretch especially in functional reconstruction.

Two patients had occlusion of their vascular grafts for which revision of the vascular anastomosis was performed. Unfortunately, one of these patients developed an upper limb ischaemia

that necessitated later above elbow amputation and the latissimus flap, previously harvested, was utilized to cover the stump.

RESULTS

Postoperative follow up of the patients for a variable period that could satisfy the course of each individual patient till regaining complete wound healing and satisfactory function of the upper extremity. Rehabilitation program started as soon as the local condition permit regarding stability of the wound and orthopedic instructions. Further orthopedic management and secondary nerve suture were performed later on at the proper time.

All flaps survived completely except three cases with marginal flap necrosis (13%) that needed no further major interventions, one of them necessitated only regrafting and the other 2 healed satisfactorily with repeated dressings. Partial graft loss over the muscle flaps occurred in 5 patients (21.7%), three of them with a limited surface area that needed no further interventions and the other 2 major loss necessitated regrafting. Local wound infection occurred in 4 patients (17.3%), repeated dressing and antibiotic therapy according to wound culture and antibiotic sensitivity controlled infection in 3 of them, however, one patient (4.3%) developed a persistent discharging sinus that necessitated sequestrectomy of a separate necrotic bone ship as proved to be the cause of the persistent sinus (Fig. 1-6).

Adequate healing of the donor site was achieved in 15 patients (Fig. 1d). Seroma was developed in 4 patients (17.3%) that resolved following repeated aspirations over a variable period of time in three of them. Wound infection was developed in 4 patients (17.3%), one occurred on top of a pre-existing seroma, repeated dressing and proper antibiotic administration achieved full cure of the wound. Partial wound disruption occurred in 2 patients (8.7%), one caused by some tension in a donor wound of a myocutaneous flap and the other as a result of wound infection, one disruption allowed to heal spontaneously and the other more major disruption necessitated secondary sutures. Hypertrophic scar was developed in 3 cases of complicated wound healing (13%), they improved by local steroid injections and other local applications (Table 1).

Functional recovery was satisfactory in functional reconstruction as tested by range of motion and muscle strength. An average of 135 degrees

flexion and short of 10 degrees full extension with an average muscle strength of grade 3 was achieved (Figs. 1 e,f & 2 c,d).

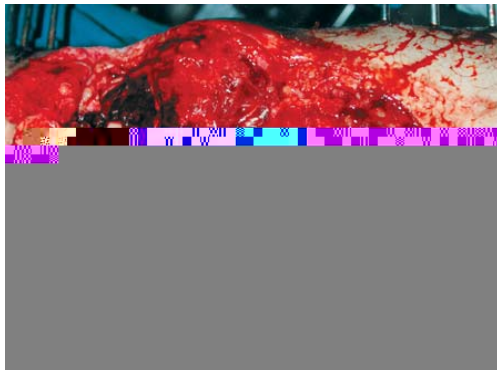


Fig. (1-A): Preoperative view of smashed elbow with deranged elbow extensors.

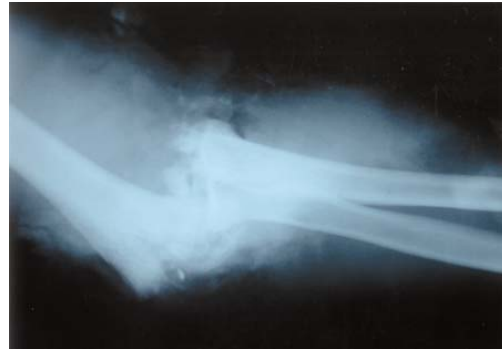

Fig. (1-B): Plain X-ray of the elbow showing the extent of orthopedic injury.

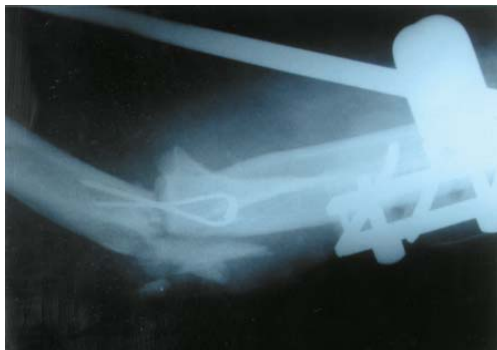

Fig. (1-C): Plain X-ray of the elbow after combined internal and external fixation.

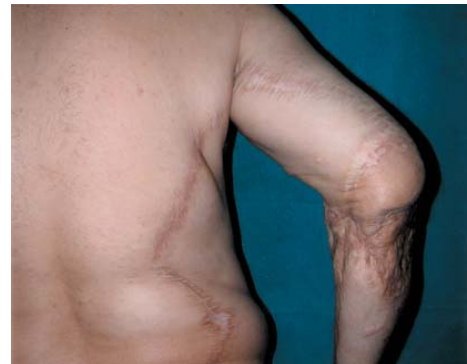

Fig. (1-D): Late postoperative view of both donor and recipient areas.

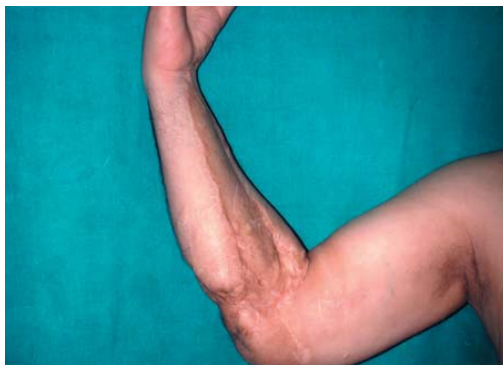

Fig. (1-E): Late postoperative view with the elbow in full flexion.

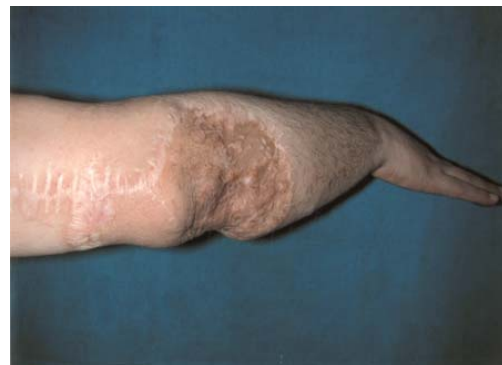

Fig. (1-F): Late postoperative view with the elbow in 10° short of full extension.

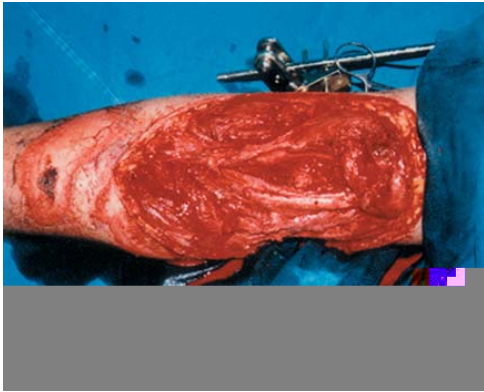


Fig. (2-A): Preoperative view of a complex elbow defect with exposed neurovascular structures, deranged elbow flexors and fracture humerus fixed with external fixator.

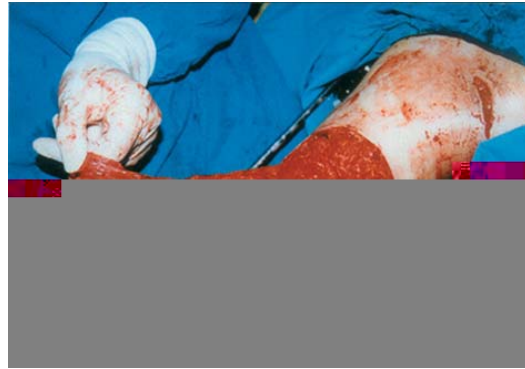

Fig. (2-B): Intra-operative view of the defect with a latissimus dorsi muscle flap harvested for both coverage and elbow flexor-plasty.

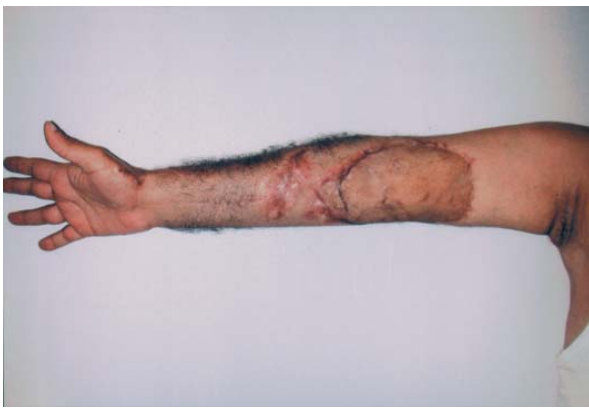

Fig. (2-C): Late postoperative view with the elbow in full extension.

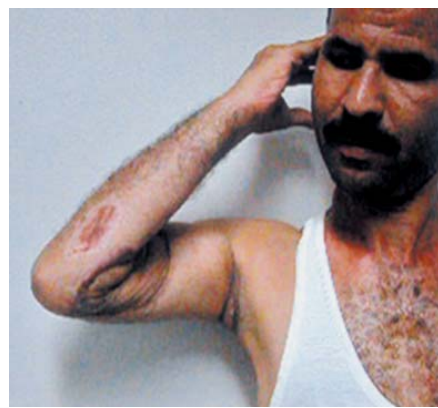

Fig. (2-D): Late postoperative view with the elbow in full flexion.

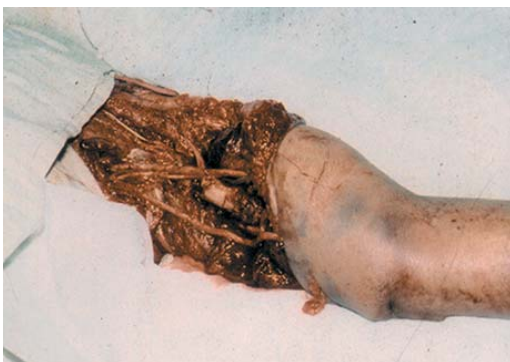

Fig. (3-A): Preoperative view of a distal arm defect with exposed neurovascular structures and severed brachial artery.



Fig. (3-B): Late postoperative view of the defect covered with a latissimus dorsi myocutaneous flap following brachial artery reconstruction with saphenous interposition graft.

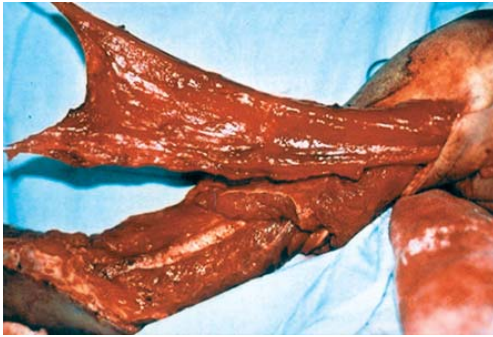

Fig. (4-A): Intra-operative view of an extensive degloving injury of the arm and elbow and exposed humeral shaft, with a harvested latissimus dorsi muscle flap over the defect.

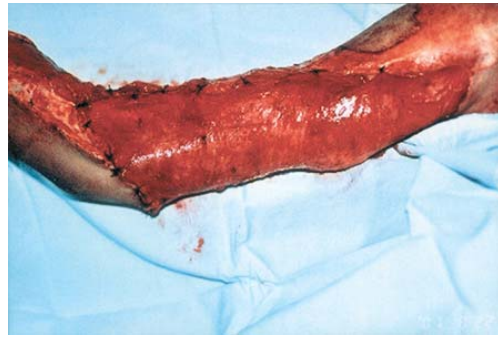

Fig. (4-B): Intra-operative view after completion of defect wrapping with latissimus dorsi muscle flap.

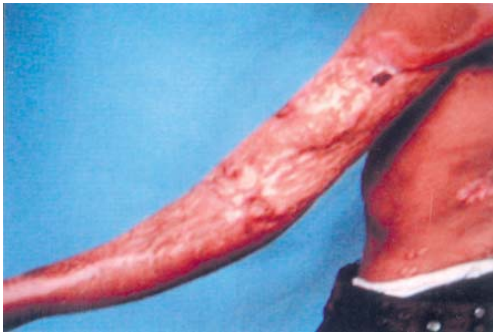

Fig. (4-C): Late postoperative view with adequate healing of the wounds.

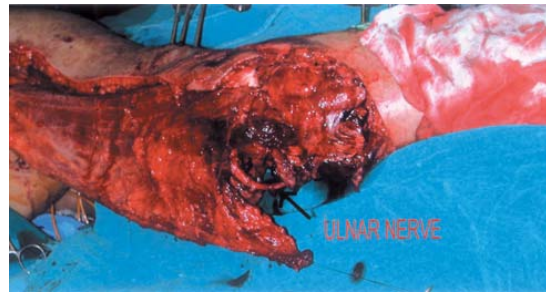


Fig. (5): An operative view of an elbow defect with smashed bony ends of both humerus and ulna and exposed intact ulnar nerve. The latissimus dorsi muscle flap used to cover the defect and wrap the ulnar nerve.



Fig. (6-A): Preoperative view of a dorsal elbow defect with exposed bone and fracture humerus and ulna fixed with external fixator.

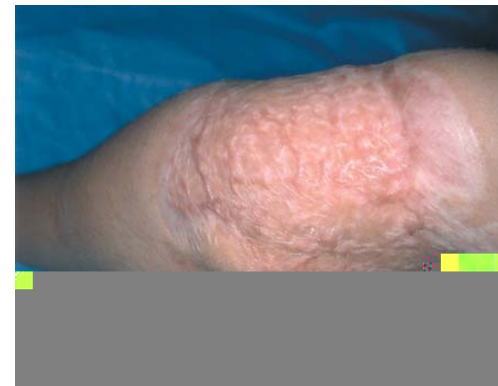

Fig. (6-B): Late postoperative view of the defect covered with latissimus dorsi muscle flap with overlying meshed graft.

Table (1): Recipient and donor site complications.

Complication	Number	%
<i>Recipient site:</i>		
Total flap loss		
Marginal flap necrosis		
Partial graft loss over muscle flap		
Wound infection		
Osteomyelitis		
Vascular graft occlusion		

all patients after adequate cleaning and debridement of the wounds. Although wound infection occurred in 4 patients, it was unlikely to be directed to immediate coverage, as the infection was cleared after a short period of time following the proper use of antibiotic, also the vast majority of patients had a smooth postoperative recovery. Although immediate coverage is mandatory in cases of exposure of neurovascular structures, there is still dilemma regarding the musculoskeletal exposures. The policy of immediate coverage is now accepted by increasing number of reconstructive surgeons provided the wound could be cleaned and debrided properly. Statistical comparison between infection rate in immediate versus delayed reconstruction showed minimal difference in favor of delayed reconstruction. On assumption that adoption of that kind of treatment might increase the risk of infection slightly, if compared to the conventional policy, this should be weighted in face of the major advantages of rapid rehabilitation of patients, minimizing the hospital stay, reducing the finance and returning the patient to his/her activity as early as possible [13].

In such severe form of injuries, possible derangement of a whole group of muscles acting on the elbow, either flexors or extensors, is expected. The extra gain of possible elbow reanimation in conjunction with coverage using a single reconstructive modality is a major advantage. We used the flap for elbow reanimation in 5 patients, 3 extensor-plasty and 2 flexor-plasty with satisfactory functional restoration in both muscle strength and range of motion.

Our results were comparable to that of similar series showing no total loss of any of our flaps, other few minor complications in the recipient as well as the donor areas were met with, most of these complications were managed conservatively and only few of them needed secondary minor surgical interventions with slight increase in postoperative recovery period.

This series of patients revealed the flap to be the most useful armament for reconstruction of complex proximal upper limb and elbow defects. The procedure is safe, reliable, one-staged, with few complications and minimal donor morbidity. This flap could be considered the flap of choice for coverage of such defects.

REFERENCES

- 1- Abu-Jamra F.N., Akel S.R. and Shamma A.R.: Repair of major defect of the upper extremity with a latissimus dorsi myocutaneous flap: a case report. *Br. J. Plast. Surg.*, 34, 2: 121, 1981.
- 2- Stern P.J., Neale H.W., Gregory R.O. and Kreilein J.G.: Latissimus dorsi myocutaneous flap for elbow flexion. *Am. J. Hand Surg.*, 7, 1: 25, 1982.
- 3- Ismail T., Atta A.T. and Refki M.: The versatility of the latissimus dorsi muscle and myocutaneous flaps in upper limb reconstruction. *Egypt. J. Plast. & Reconstr. Surg.*, 13, 1: 49, 1989.
- 4- Rogachefsky R.A., Aly A. and Brearley W.: Latissimus dorsi pedicled flap for upper extremity soft tissue reconstruction. *Orthopedics*, 25, 4: 403, 2002.
- 5- Stevenson T.R., Duus E.C., Greene T.L. and Dingman R.O.: Traumatic upper arm defects treated with latissimus dorsi muscle transposition. *J. Pediatr. Orthop.*, 4, 1: 11, 1984.
- 6- Lai C.S., Tsai C.C., Liao K.B. and Lin S.D.: The reverse lateral arm adipofascial flap for elbow coverage. *Ann. Plast. Surg.*, 39, 2: 196, 1997.
- 7- Hallock G.G.: The utility of both muscle and fascia flaps in severe upper extremity trauma. *J. Trauma*, 53, 1: 63, 2002.
- 8- Stern P.J. and Carey J.P.: The latissimus dorsi flap for reconstruction of the brachium and shoulder. *Am. J. Bone Joint Surg.*, 70, 4: 526, 1988.
- 9- Minami A., Ogino T., Ohnishi N. and Itoga H.: The latissimus dorsi musculocutaneous flap for extremity reconstruction in orthopedic surgery. *Clin. Orthop.*, 260: 201, 1990.
- 10- Chang L.D., Goldberg N.H., Change B. and Spence R.: Elbow defect coverage with a one-staged, tunneled latissimus dorsi transposition flap. *Ann. Plast. Surg.*, 32, 5: 496, 1994.
- 11- Germann G. and Steinau H.U.: Functional soft tissue coverage in skeletonizing injuries of the upper extremity using the ipsilateral latissimus dorsi myocutaneous flap. *Plast. Reconstr. Surg.*, 96, 5: 1130, 1995.
- 12- Al-Qattan M.M.: Severe traumatic soft-tissue loss in the antecubital fossa and proximal forearm. *Ann. Plast. Surg.*, 46, 2: 125, 2001.
- 13- Sadove R.C., Vasconez H.C., Arthur K.R., Draud J.W. and Burgess R.C.: Immediate closure of traumatic upper arm and forearm injuries with the latissimus dorsi island myocutaneous pedicle flap. *Plast. Reconstr. Surg.*, 88, 1: 115, 1991.
- 14- Rowsell A.R., Davies D.M., Eisenberg N. and Taylor G.I.: The anatomy of the subscapular-thoracodorsal arterial system: study of 100 cadaver dissections. *Br. J. Plast. Surg.*, 37: 574, 1984.
- 15- Pierce T.D. and Tomaino M.M.: Use of the pedicled latissimus muscle flap for upper extremity reconstruction. *J. Am. Acad. Orthop. Surg.*, 8, 5: 324, 2000.
- 16- Schusterman M.A., Tobin G.T., Peterson G.H. and Nichols G.: Intramuscular neurovascular anatomy of the latissimus dorsi: the basis for splitting the flap. *Surg. Forum*, 31: 559, 1980.