

## Reliability of Pectoralis Major Myocutaneous Flap in Reconstruction of Cervicofacial Defects Following Ablative Oncological Surgery

AHMED GABER, M.Sc.\*; TAREK ABULEZZ, M.D.\*; SAMIA SAIED, M.D.\*;  
MOHAMED A. ELLABAN, M.D.\*\* and TAREK EL-GAMMAL, M.D.\*\*\*

*The Departments of Plastic Surgery\*, Sohag University Hospital, Faculty of Medicine, Sohag University, Sohag; Plastic & Reconstructive Surgery Unit\*\*, Faculty of Medicine, Suez Canal University, Ismailia and Orthopedics & Hand and Microsurgery Unit, Faculty of Medicine, Assiut University, Assiut, Egypt*

### ABSTRACT

The objective of this study is to assess the reliability of pectoralis major myocutaneous (PMMC) in cases of cervicofacial defects following ablative oncological surgery. We performed a prospective analysis of patients in whom PMMC was used to reconstruct head and neck surgical defects during the period from April 2014 to September 2015. The study was carried out at plastic surgery department of Sohag University Hospital and involved 20 patients. Patients' age ranged from 47 to 78 years, 16 patients were males and 4 patients were females. PMMC was used in 14 cases of defects following cancer larynx surgery and 6 cases of defects following cancer cheek and mandible surgery. No failures were noted in the study; however one patient died two month post-operative due to carotid blow out as a result of over dose of radiotherapy. Despite the current emphasis in tissue replacement has shifted to microvascular free-tissue transfer, the pectoralis major myocutaneous flap is still a versatile and reliable flap with an excellent reach to cervicofacial region especially in patient with poor general condition and with limited expertise and resources required for microvascular free-tissue transfer.

**Key Words:** PMMC – Cervicofacial defects – Oncological surgery.

### INTRODUCTION

Reconstruction with surgical flaps is usually needed for post-ablative head and neck defects because primary closure or mobilization of neighboring tissues is usually insufficient for repair of these defects [1]. Despite the fact that free flaps are now considered the gold standard for head and neck reconstruction, their use may be limited by the need for competent microsurgeon, costly equipments and materials, generally fit patients who tolerate long surgical procedures. Another limiting factor for the use of microsurgical flaps is the need for good quality of recipient vessels for anastomosis [2]. Previously irradiated tissues may have potentially compromised blood vessels that may not be reliable as recipient vessels, so other surgical

options may be needed [3]. The Pectoralis Major flap, which was described by Ariyan in 1979, is the most often employed in this situation due to its reliability and versatility, the distinct advantage of the flap lies in the fact that it is easy to dissect in a short time and has minimal donor site morbidity [4]. The flap can be used as a muscle flap or with a skin paddle as myocutaneous flap. However some individual complications such as wound dehiscence, infection, partial flap loss, fistula and donor site complications can occur [5]. Restricted neck mobility and flap thickness can affect both swallowing and speech functions. Flap bulkiness is sometimes considered a good advantage in some cases like coverage of a reconstruction plate or big vessels [6].

Other pedicled flaps that were used for head and neck reconstruction include pedicled latissimus dorsi myocutaneous flap [7] and cervico pectoral fasciocutaneous flap [8]. In this article, we have described our 2 years' experience using the Pectoralis Major Myo-Cutaneous flap (PMMC) flap in soft tissue reconstruction of defects in the head and neck region. We reported the reliability and versatility of this flap showing its high effectiveness in meeting our surgical needs.

### MATERIAL AND METHODS

This study included 20 patients who had defects in the head and neck regions resulting from ablative oncological surgery. The patients were evaluated in The Plastic Surgery Department at Sohag University Hospital. After discussing the treatment options and deciding the operative plan, an informed written consent was obtained from each patient. The study was approved by Ethical and Research committee in Sohag Faculty of Medicine.

All operative interventions were performed at our department from the period from first of April 2014 to September 2015. Follow-up ranged from 6 months to 1.5 years. The site of the defect reconstructed, the size of the flap harvested and outcome were analyzed in detail.

**RESULTS**

Of the 20 patients, between the age group 47 and 78 years, 16 patients were males while 4 patients were females. PMMC was used to reconstruct defect after cancer larynx surgery in 14 patients while in 6 patients, the flap was used to reconstruct defects resulting after excision of malignant masses in the mandible and check (Table 1). Skin paddle size ranged from 8 to 13cm in length and from 5 to 9cm in width. The secondary defect resulting after flap mobilization was closed primarily in 17 patients and split thickness skin graft needed in 3 cases (Fig. 1). The overall flap survival rate was 100%. However, one patient died after three months by an attack of bleeding of carotid blow-out due to over dose of radiotherapy. The complications of the procedure included wound dehiscence (seen in 40% of cases), skin necrosis and hypopharyngeal fistula (occurred in 3 cases, 15%) and flap dehiscence with orocutaneous fistula was found in only 2 cases (10%). All the complications, except the bleeding blow-out, were successfully managed conservatively Table (2).

*Representative cases:*

Case No. 1:

A 60 years old man, total laryngectomy for cancer larynx and direct closure of the defect were done to him in ENT department. Wound dehiscence occurred one-week later. After debridement of necrotic tissue, pectoralis major myocutaneous flap was used to provide soft tissue coverage of the defect. The donor site was closed directly (Fig. 2).

Case No. 2:

A 60 years old male patient presented with cancer larynx and laryngocutaneous fistula. Total laryngectomy and bilateral selective neck dissection level 1 to 5 were done by ENT team. Pectoralis major myocutaneous flap was used to for reconstruction at the same setting (Fig. 3).

Case No. 3:

A 63 years old female presented with SCC of the right check and oral commissure. Excision with safety margin and ipsilateral neck dissection level

1 to level 5 were done. Reconstruction was done by pectoralis major myocutaneous flap with and the donor site was closed directly. Despite of the bulkiness of the flap, the patient refused to have debulking (Fig. 4).

Case No. 4:

A 52 years old male patient presented with SCC of the mandible infiltrates mucosa of the left check. Left sided hemimadibulectomy was done and pectoralis major myocutaneous flap was harvested and wrapped around reconstruction plate with direct closure of the donor site. Modified radical neck dissection from group 1 to group 5 was also done (Fig. 5).

Table (1): Indications for surgery.

Indication	Frequency	Percent
Defects resulted after Cancer larynx surgery with or without larygeocutaneous fistula	14	70
SCC of mandible infiltrates skin and mucosa of the check	4	20
SCC infiltrates mucosa of the check	1	5
SCC of the check and oral commissure	1	5
<b>Total</b>	<b>20</b>	<b>100</b>

Table (2): Post operative complications.

Complication	Frequency	Percent
Non	7	35
Flap dehiscence and orocutaneous fistula	2	10
Skin necrosis and hypopharyngeal fistula	3	15
Minor wound dehiscence	8	40

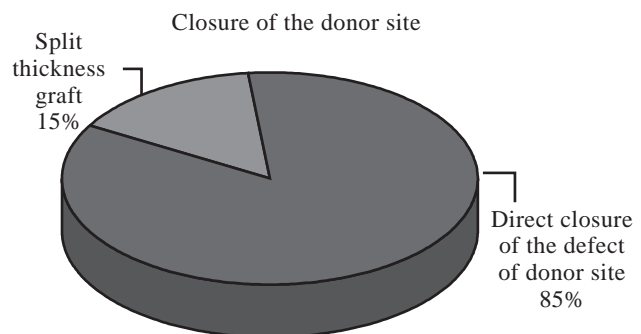


Fig. (1): Methods of closure of the donor site.




Fig. (2): A 60 years old male patient, with total laryngectomy done for cancer larynx and direct closure of the defect was done in ENT department (A). Wound dehiscence occurred one week later (B). After debridement of necrotic tissue, pectoralis major myocutaneous flap was used to provide adequate soft tissue coverage of the defect (C). The donor site was closed directly. The flap in-set after healing of the wound (D).

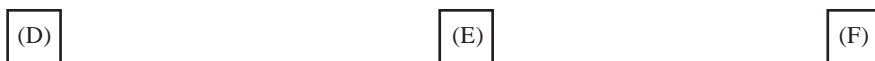


Fig. (3): A 60 years old male patient presented with cancer larynx and laryngocutaneous fistula (A). Total laryngectomy and bilateral selective neck dissection level 1 to level 5 were done by ENT team (B,C). Pectoralis major myocutaneous flap was harvested for reconstruction at the same setting (D). The flap and the donor site are shown after wound healing (E,F).



Fig. (4) : A 63 years old lady presented with SCC of the right cheek and oral commissure (A). Excision with safety margin and ipsilateral neck dissection level 1 to level 5 were done (B). Reconstruction by pectoralis major myocutaneous flap with skin in and out was done (C). The donor site was closed directly and the patient refused debulking (D).




Fig. (5): A 52 years old male patient presented with SCC of the mandible infiltrates mucosa of the left cheek (A,b). Minimal access pectoralis major myocutaneous flap was designed (C). Left sided hemimandibulectomy (D) was done, and the PMMC flap was wrapped around reconstruction plate (E), with modified radical neck dissection from group 1 to group 5 was done. Donor site closed directly (F). Immediate post operative (G) and 2 weeks later (H) photos showing flap inset.

## DISCUSSION

Pectoralis major flap stands as a valuable option in reconstructing post tumor resection defects in the face and neck areas [9]. PMMC flap helps to prevent pharyngocutaneous fistula in case of salvage total laryngectomies after irradiation. In these cases, several authors have proposed to electively reinforce the suture line and pharyngeal wall with the flap [10,11]. In the same way, pectoralis major flap with or without skin paddle can be used to protect the carotid axis after radical neck dissection following radiotherapy failure [12], and in these cases a further adjuvant perioperative radiotherapy can be safely administered. Pharyngeal defects were also reported to be successfully managed by the use of pectoralis major flaps [13].

The age of our study population ranged from 47 to 78 years with a mean of 62.15 ( $\pm 8.67$ ) years. There are noticeable differences in the mean ages of patients who underwent neck reconstruction using the pectoralis flap. Austen and colleagues [14] reported older patients where the age of his patients ranged from 51 to 96 years with a mean of 71 years while Marques et al. [15] showed that the mean age of their patients was 53.7 years with a range from 28 to 72 years, and Sharma et al. [16] reported a more younger patients where the age ranged from 34 to 74 years. This may indicate that the flap can be used with good reliability in different age groups.

70% of our cases suffered from defects after cancer larynx surgery and 30% suffered from squamous cell carcinoma of the mandible and cheeks. The study done by Sharma [16] had laryngeal cancer in only 23% of cases, with nearly 44% of cases had an oral cavity tumors and the rest had tumors in the oropharynx, hypopharynx or ear, while Bussu [17] reported different presentations where mandibular and laryngeal lesions constituted only a minority of total cases (7% and 7.7%; respectively), primary lesions in the oropharynx (31%) or oral cavity (52.2%), with a 1.8% of patients had skin lesions.

The histopathological type of our study cases was squamous cell carcinoma (SCC) in all of our 20 cases (100%). This was similar to the study done by Marques [15] whose cases showed also a 100% SCC histopathological type. Bussu [17] also found SCC in 93% of their cases. Chen et al. [18] reported SCC in only 8 cases (66.7%) of their patients, while 3 cases had sarcoma and one case had basal cell carcinoma (BCC). Austen et al. [14] reported different histopathological type of their

cases where SCC constituted only in 38%, BCC in 38% and melanoma in 24% of their cases.

In all of our cases, we used the flap with its skin paddle as a myocutaneous (PMMC) flap to reconstruct defects resulting after total laryngectomy (55% of cases = 11 cases), total laryngectomy with bilateral selective neck dissection in another 3 cases, hemimandibulectomy in 4 cases (20%) and excision of the cheek tumor with a safety margin in the remaining 2 cases. This is the types of pectoralis major flap used by most head and neck surgeons as reported by Bussu et al. [17] where PMMC flap was performed in 86.5% of patients while PMM flap was done in the remaining 13.5%.

The complications of the procedure included minor wound dehiscence (seen in 40% of cases), hypopharyngeal fistula occurred in 3 cases (15%) and flap dehiscence with oro-cutaneous fistula seen in 2 cases (10%). No complications at all were found in more than one third of our cases (7 cases, 35%). The study done by Marques et al. [15] reported similar results; skin necrosis was seen in 30% of cases, oral fistula in 40% of cases and pneumothorax in 20% of cases. However, due to overlap between complications in their cases, the overall complication rate was 70% and none of these complications occurred in the remaining 30% of cases. Sharma et al. [16] reported an overall complication rate of over 60%, with wound dehiscence seen in 27% of their cases, necrosis in only 3% of cases and wound infection in 23% of cases. Kroll et al., reported [5] analyzed complications in 168 pectoralis major osteomyocutaneous flaps used for head and neck reconstruction the overall rate of complications was 63%. Nagral et al. [19] stated an overall complication rate of over 78% of their cases, with necrosis seen in 32%, dehiscence and/or fistula in 35%, and infection in 21% of their cases. Bussu [17] found skin necrosis in only 3.6% of their cases and wound dehiscence in only 0.3% out of 274 cases operated along 20 years. In our study, accepted wound healing achieved in nearly all cases. This was similar to the results recorded by Austen [14].

Favorable prognosis was noticed in 19 cases out of the 20 cases. One case died 3 months post-operatively due to carotid blow out which led to severe bleeding. Only one of the Bussu's cases (0.3%) died after the operation [17]. Chen [18] reported a death rate of 16.7%, mostly due to recurrence of the original tumor after its excision with or without metastasis, while Austen et al. [14] showed a 100% survival.

### Conclusion:

The current emphasis in tissue replacement has shifted to microvascular free-tissue transfer. However the pectoralis major myocutaneous flap is still a versatile and reliable flap with an excellent reach to cervicofacial region especially in patient with poor general condition. With the high expertise and expensive resources required for microvascular free-tissue transfer, the pectoralis major flap, with or without skin paddle, is still a workhorse flap in head and neck reconstruction.

### REFERENCES

- 1- Pinto F.R., Malena C.R., Vanni C.M., Capelli F.D., de Matos L.L. and Kanda J.L.: Pectoralis major myocutaneous flaps for head and neck reconstruction: factors influencing occurrences of complications and the final outcome. Sao Paulo Med. J., 128 (6): 336-41, 2010.
- 2- Hsing C.Y., Wong Y.K., Wang C.P., et al.: Comparison between free flap and pectoralis major pedicled flap for reconstruction in oral cavity cancer patients a quality of life analysis. Oral Oncol., 47 (6): 522-7, 2011.
- 3- Chiummariello S., Iera M., Domatsoglou A. and Alfano C.: The use of pectoralis major myocutaneous flap as "salvage procedure" following intraoral and oropharyngeal cancer excision. G. Chir., 31 (4): 191-6, 2010.
- 4- Kruse A.L., Luebbbers H.T., Obwegeser J.A., Bredell M. and Gratz K.W.: Evaluation of the pectoralis major flap for reconstructive head and neck surgery. Head Neck Oncol., 27 (3): 12, 2011.
- 5- Kroll S.S., Goepfert H., Jones M., Guillaumondegui O. and Schusterman M.: Analysis of complications in 168 pectoralis major myocutaneous flaps used for head and neck reconstruction. Ann. Plast. Surg., 25 (2): 93-7, 1990.
- 6- Milenovic A., Virag M., Uglesic V. and Aljinovic-Ratkovic N.: The pectoralis major flap in head and neck reconstruction: First 500 patients. J. Craniomaxillofac. Surg., 34 (6): 340-3, 2006.
- 7- Ferbeyre-Binelfa L.: Lattissimusdorsi myocutaneous flap in head and neck surgery. Cir. Cir., 78: 485-491, 2010.
- 8- Copcu Eray, Metin Kubilay, Aktas Alper, Sivrioglu Nazan S. and Oztan Yücel: "Cervicopectoral flap in head and neck cancer surgery." World journal of surgical oncology 1 (1): 29. doi:10.1186/1477-7819-1-29, 2003.
- 9- Schneider D.S., Wu V. and Wax M.K.: Indications for pedicled pectoralis major flap in a free tissue transfer practice. Head Neck, 34 (8): 1106-10, 2012.
- 10- Righini C., Lequeux T. and Cuisnier O.: The pectoralis myofascial flap in pharyngolaryngeal surgery after radiotherapy. Eur. Arch. Otorhinolaryngol., 262: 357-61, 2005.
- 11- Gilbert M.R., Sturm J.J., Gooding W.E., Johnson J.T. and Kim S.: Pectoralis major myofascial onlay and myocutaneous flaps and pharyngocutaneous fistula in salvage laryngectomy. Laryngoscope, 124 (12): 2680-6, 2014.
- 12- McLean J.N., Carlson G.W. and Losken A.: The pectoralis major myocutaneous flap revisited: A reliable technique for head and neck reconstruction. Ann. Plast. Surg., 64 (5): 570-3, 2010.
- 13- Mura F. Bertino G. and Occhini A.: Advanced carcinoma of the hypopharynx: functional results after circumferential pharyngolaryngectomy with flap reconstruction. Acta otorhinolaryngol. Ital, 32: 154-7, 2012.
- 14- Austen W.G., Parrett B.M., Taghinia A., Wolfort S.F. and Upton J.: The Subcutaneous Cervicofacial Flap Revisited. Ann. Plast. Surg., 62 (2): 149-53, 2009.
- 15- Marques A., Abrahao M., Castro M., et al.: Complications of the pectoralis major osteomyocutaneous flap used for head and neck reconstruction. Eur. J. Plast. Surg., 19: 229-33, 1996.
- 16- Sharma S., Murty P.S., Hazarika P., Nayak D.R. and Sharma S.: The Indications and Complications of Pectoralis Major Myocutaneous Flap Reconstruction in Head and Neck Surgery-Our Experience. Indian. J. Otolaryngol. Head Neck Surg., 50 (4): 362-7, 1998.
- 17- Bussu F., Gallus R., Navach V., et al.: Contemporary role of pectoralis major regional flaps in head and neck surgery. Acta. Otorhinolaryngol. Ital, 34 (5): 327-41, 2014.
- 18- Chen W., Zeng S., Li J., Yang Z., Huang Z. and Wang Y.: Reconstruction of full-thickness cheek defects with combined temporalis myofacial and facial-cervico-pectoral flaps. Oral. Surg. Oral. Med. Oral. Pathol. Oral. Radiol. Endod., 103 (1): e10-5, 2007.
- 19- Nagral S., Sankhe M. and Patel C.V.: Experience with the pectoralis major myocutanous flap for head and neck reconstruction in a general surgical unit. J. Postgrad. Med., 38 (3): 119-23, 1992.