

## Our Modified Primary Gingivoperiosteoplasty Technique in the Repair of Alveolar Clefts: Preliminary Results

Wael A. Ghanem, M.D.; Mohammed S. El-Debeiky, M.D., F.R.C.S. and Ahmed B. Radwan, M.D.

The Department of Pediatric Surgery, Faculty of Medicine, Ain Shams University

### ABSTRACT

In case of complete cleft lip and palate, the cleft alveolus results from failure of fusion of the medial nasal and maxillary processes. Maxillary alveolar clefts can prevent normal eruption of the permanent dentition and can therefore inhibit facial growth and symmetry. The repair of alveolar clefts has been and still remains a controversial subject. Gingivoperiosteoplasty (GPP) is a procedure that tends to remove the soft tissue barrier within an alveolar cleft and replacing it with a gingivoperiosteal tunnel that facilitates bone healing through guided tissue regeneration (GTR) without the need for bone grafting and its associated donor site morbidity.

**Material and Methods:** Our study included 30 patients, presenting with complete cleft lip and palate. This study took place over a time range of 4 years from 2011 to 2015. Out of these 30 cleft patients, 15 were left sided, 9 right sided and 6 bilateral. Preoperative assessment included detailed history and photography (frontal, basal & intraoral). No preoperative maxillary orthopedics were performed for any of our cases.

**Results:** Alveolar closure at the time of primary gingivoperiosteoplasty using our modified technique was possible in all cases regardless of the alveolar cleft width and laterality. The cleft gap ranged between 6mm and 15mm, with a mean of 10.4mm and SD of  $\pm 2.94$ mm. In 24 cases (80% of cases), normal arch configuration was restored, while in the remaining 6 cases (20% of cases), there were minor degrees of residual alveolar cleft. Tooth eruption through the repaired cleft was observed in 8 cases (26.6% of cases) during the follow-up period. Occlusion was satisfactory in most of the cases (23 cases) (76.6% of cases).

**Conclusion:** Our modified GPP technique outweighs its drawbacks in terms of being a simple straightforward technique with insignificant complications and it doesn't require any drastic preoperative orthopedics. Since the effects of GPP on facial growth are still controversial, long term follow-up of our cases would still be advised to verify such effects.

**Key Words:** *Gingivoperiosteoplasty – Alveolar clefts.*

### INTRODUCTION

The development of the face is coordinated by complex morphogenetic events and rapid proliferative expansion, and is thus highly susceptible to environmental and genetic factors, explaining the

high incidence of facial malformations. The process of forming facial structures is the result of cell proliferation, differentiation, adhesion, and apoptosis. The processes of the neural crest cells are directed by molecular signals that are controlled by a group of genes that include the transforming growth factor beta (TGF- $\beta$ ) super family, sonic hedgehog (SHH), fibroblast growth factors (FGFs), and bone morphogenic proteins (BMPs). Failures or errors in any of these intracellular mechanisms can disrupt the normal fusion of the medial and lateral nasal processes and maxillary process to cause orofacial clefts [1].

In the complete cleft lip and palate, the cleft alveolus results from failure of fusion of the medial nasal and maxillary processes. As a result, ossification centers in the premaxilla and the maxilla cannot migrate and unite. The normal growth and development in the region of the premaxillary-maxillary suture cannot occur. As for the nasal septum and interincisive suture, they deviate to the non-cleft side due to the unopposed activity of the normally inserted nasolabial muscles. The premaxilla is displaced antero-superiorly with the hemi-premaxilla. These abnormalities tend to encourage and exaggerate forward development in the region of the premaxillary-maxillary suture [2]. Early reconstruction in the region of the premaxillary-maxillary suture encourages a more normal development of the alveolus as recommended by Smith et al. [3].

Maxillary alveolar clefts can prevent normal eruption of the permanent dentition and can therefore inhibit facial growth and symmetry [4].

The reconstruction of the alveolar process in cleft patients is an essential part of cleft treatment as it gives sufficient support to the alar base of the nose; helps in correct eruption of teeth in the cleft

region and subsequently having proper periodontal support [4].

There are three major surgical methods for the closure of the alveolar cleft, they include primary bone grafting, secondary bone grafting, and gingivoperiosteoplasty (GPP). Gingivoperiosteoplasty was first described by Skoog in 1965 as a primary alveolar repair procedure. GPP is a procedure that tends to remove the soft tissue barrier within an alveolar cleft and replaces it with a gingivoperiosteal tunnel that facilitates bone healing through guided tissue regeneration (GTR) without the need for bone grafting and its associated donor site morbidity. The importance of the periosteum in bony healing has been well documented by several investigators. However, Ollier is most often credited with first emphasizing the osteogenic potential of the periosteum. This is especially true for patients at a younger age [2].

Although the osteogenic properties of mucoperiosteum in healing a cleft palate were initially recognized by Langenbeck in the 1800s, it was not until Tord Skoog's descriptions of primary GPP or "boneless bone grafting" in the 1960s that the technique became popularized in cleft care. Successful GTR following a GPP depends on the integrity of the guiding tunnel to restrict fibrous in-growth, the presence of viable periosteum in the created flaps, and the age of the patient [5].

In 1990, Millard [6] advocated a more conservative GPP procedure combined with an invasive Latham device. In 2001, Grayson and Cutting [7] proposed noninvasive presurgical nasoalveolar molding combined with a conservative GPP procedure to repair the cleft alveolus. Many centers (Millard and Latham, 1990 [6]; Wood et al., 1997 [8]; Santiago et al., 1998 [9] and Lee et al., 2004 [10]) recently have used GPP in conjunction with primary lip repair instead of primary bone grafting,

hoping to facilitate orthodontic treatment and reduce the need for secondary bone grafting. Several studies including Ritsila et al., 1972 [11]; Azzolini et al., 1982 [12]; Hellquist et al., 1983 [13] and Smith et al., 1995 [3] have supported the findings of Ollier and Skoog as regards the high osteogenic potential of periosteum-depositing bone without subsequent resorption [2].

According to Millard, the main advantage of GPP is closure of well-aligned segments using periosteal flaps to offer the possibility of bone fill-in of the cleft maxilla. This offers stability to the jaw as a whole and also provides more normal anatomical circumstances for growth of the maxilla. Other benefits of GPP include establishing an intact maxillary dental arch at an early age, facilitating correct eruption path of permanent teeth, early correction of the nose base symmetry, and avoidance of traumatic injury of the donor site during the bone grafting procedure [14].

The repair of alveolar clefts has been and still remains a controversial subject.

## MATERIAL AND METHODS

Our study includes 30 patients, presenting with complete cleft lip and palate. This study was performed over a time range of 4 years from 2011 to 2015. Out of these 30 cleft patients, 15 were left sided (50% of cases), 9 right sided (30% of cases) and 6 bilateral (20% of cases). There were 22 boys (73.3% of cases) and 8 girls (26.6% of cases). The age at the time of the repair ranged between 2 to 6 months of age with a mean of 3.9 months. The surgical procedure took about 120min to 200min with a mean of 165min.

Preoperative assessment included detailed history and photography (frontal, basal & intraoral). No preoperative maxillary orthopedics were performed for any of our cases.

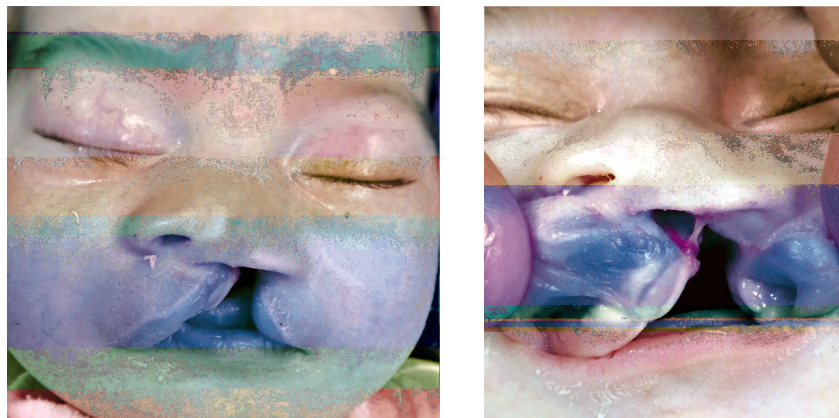


Fig. (1-A,B): A case of 3-month-old male patient with left complete cleft lip.



*Surgical technique:*

Skin markings and incisions for repair of the cleft lip was done using the Tennison triangular flap principle in the repair of unilateral cleft lip cases and Mulliken repair in the bilateral cases. We injected tumescent Epinephrine (1:100000) in all layers of the lip as well as nasal walls, alveolus and anterior palate. Muscles were carefully dissected as a separate layer to release them from their wrong attachments. Then extended incisions were made on both sides of the nasal cavity to facilitate creation of two mucosal flaps to close the nasal floor. Marginal gingivoperiosteal flaps (of width ranging between 5-7mm) based on the palatal side were raised from the anterior surface of the palate and sides of the alveolus by medial and lateral parallel incisions followed by elevation of the

mucoperiosteum. These flaps were transposed medially to form the posterior, inferior and anterior wall of the alveolar box. Closure of both flaps was performed by (4/0) Vicryl simple sutures medially and loose sutures laterally to support the flap alignment in the same concept of palatal repair. Prior to this step we started by closure of the nasal floor using the created mucosal flaps from both nasal walls. We used to fix the created mucoperiosteal flaps anteriorly with the labial mucosa by simple interrupted sutures to add more stability for the new alveolus. Repair of the mucosa, muscle, and lip was then done as usual, meticulously aligning the mucosa with the labial (superior) side of the created alveolus by interrupted (5/0) Vicryl sutures. We performed GPP together with formal lip and nose repair in one stage.

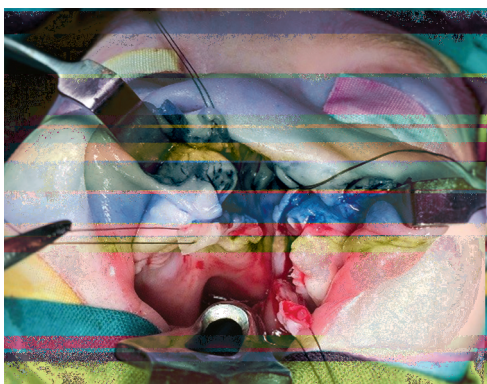


Fig. (2): Creation of the two mucoperiosteal flaps based on the palatal side.

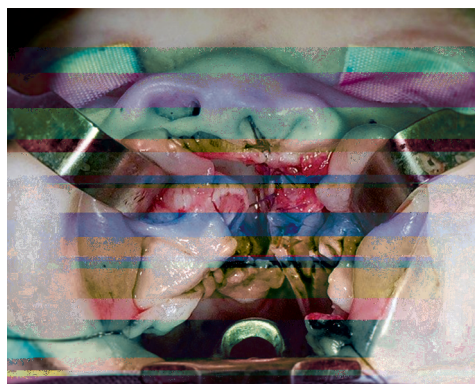

Fig. (3): Starting closure of both mucosal flaps to create the nasal floor.

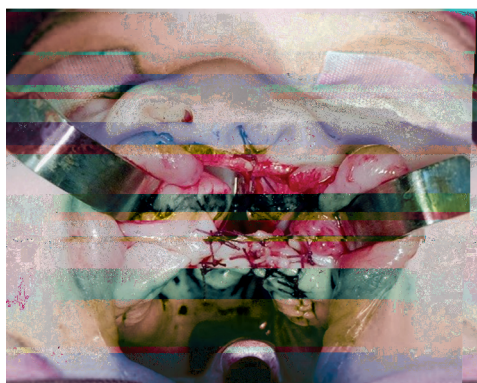


Fig. (4): Alignment of the alveolus with transposition of both mucoperiosteal flaps and closure with interrupted sutures medially and loose interrupted sutures laterally.



Fig. (5): Completion of alveolar repair by closure of the mucosa with the superior surface of the alveolar box and creation of the vestibule.




Fig. (6): Diagram showing: A yellow colored zone representing the mucosal flaps which are elevated to create the nasal floor & a red colored zone representing the posteriorly (palatal) based mucoperiosteal flaps involved in the alveolar repair.

*Follow-up evaluation:*

The follow-up period ranged from 6 to 12 months, starting 2 weeks postoperative, 1 month, 3 months, 6 months then one year. Assessment of the results included clinical examination of facial form, status of eruption of individual teeth at the site of the cleft, alignment of erupted teeth and photography (frontal, basal & intraoral).

## **RESULTS**

Alveolar closure at the time of primary gingivoperiosteoplasty using this technique was possible in all cases regardless of the alveolar cleft width and laterality. The cleft gap ranged between 6mm and 15mm, with a mean of 10.4mm and an SD of  $\pm 2.94$ mm. In 24 cases (80% of cases), normal arch configuration was restored, while in the remaining 6 cases (20% of cases), there were minor degrees of residual alveolar cleft.

Tooth eruption through the repaired cleft was observed in 8 cases (26.6% of cases) during the follow-up period. Occlusion was satisfactory in most of the followed cases (23 cases) (76.6% of cases).

None of the patients developed nasolabial or nasopalatal fistulae. Postoperative complications were confined to 4 patients (13.3% of cases) who developed infection and treated with antibiotics, only 1 case was furtherly complicated by wound dehiscence.

## **DISCUSSION**

There is still debate when it comes to selection of the most appropriate surgical approach for primary reconstruction of alveolar clefts between secondary bone grafting and primary gingivoperiosteoplasty. The benefits of successful secondary alveolar bone grafting have been discussed in many studies. Yet still there are drawbacks including donor site morbidity, the chance for graft infection, and inadequate restoration of the cleft alveolar anatomy, primarily referring to alveolar crest height [15]degy achievrefeeolopln eruption throumonth,

were used to repair the nasal floor constituting the roof of the alveolar box.

Carstens [18] introduced the concept of sliding the adjacent gingiva posterior to the cleft. He called it the "sliding sulcus operation". As for Delaire [19], he implemented the idea of the primary periosteoplasty but suggested postponing it. He applied pre-surgical orthopedics first, then performed the periosteoplasty as an early secondary gingivopalatoplasty at 18 to 24 months of age during hard palate repair. Brusatti and Garattini [20] adopted the same principle of early secondary periosteoplasty performed at 18 to 36 months of age at the time of hard palate repair, but rather relied on the molding effect of the lip and soft palate reconstruction done earlier at 4 to 6 months of age to bring the maxillary stumps into correct alignment.

In 2008, Sato and colleagues [21] documented the positive effect of gingivoperiosteoplasty performed during the initial lip repair on the success of alveolar repair. They avoided the need for secondary alveolar bone grafting in 73% of their patients. In this study, they also compared the outcome of those patients who underwent gingivoperiosteoplasty before secondary alveolar bone grafting with those who did not have gingivoperiosteoplasty performed before secondary alveolar bone grafting revealing a significant increase in the number of patients who obtained satisfactory bony bridging of the alveolus in the former group. They attributed this to three factors: (1) The absence of fistulae with a resultant decreased chances of infection; (2) The presence of periosteum and osteoblasts along the bone bridges in the cleft site from the previously attempted gingivoperiosteoplasty, allowing for a better environment for the integration of the bone graft; (3) The residual alveolar defect becoming reduced in size by the gingivoperiosteoplasty, which would be more successfully grafted than a larger alveolar defect that had no bone bridges.

In a study advocated by Cindy et al., [2] comparing maxillary growth between GPP and Non GPP groups, Results revealed the notion that GPP might affect maxillary growth adversely. The maxillary length was decreased more in the GPP group than in the non-GPP group which could be an indicator of an inhibitory growth effect. Both the SNA (Sella, Nasion, A point) and ANB (A point to B point) angles were decreased more in the GPP group than in the non-GPP group. The reduction in the maxillary basal length and SNA angle revealed that the surgical procedures might cause a disturbance of anterior maxillary dento-alveolar

development. These findings were consistent with those reported by Henkel and Gundlach [22], who demonstrated growth impairment of maxilla in cleft patients treated with GPP when compared with those treated without any grafting procedure.

In some cases with wide alveolar clefts, Naso-alveolar molding (NAM) is needed to reduce the alveolar cleft width as much as possible but it was not performed in any of our cases. Studies as Barry et al. [23], supporting the performance of pre-surgical NAM have noticed minimal tension in the healing lip repair, thereby reducing scar formation. Furthermore, patients with a large initial alveolar cleft width would have a high chance of GPP success if the separated segments were brought into good approximation.

Grayson et al. [24] also claimed that NAM results in minimal tension in the healing lip repair, thereby reducing scar formation. However, as a result of the orthopedic forces used to bring the segments together, it was noted that in some cases, the pre-maxillary position of the greater segment was located posterior to that of the lesser segment. So far there is no clear evidence that the force applied to the dento-alveolar segment can further affect the growth of its underlying basal bone.

As mentioned earlier GPP is also compared to primary and secondary bone grafting techniques to reconstruct the alveolar defect. Reports of maxillary regression following primary bone grafting led the majority of cleft teams to abandon this technique. Secondary bone grafting had been advocated during the mixed dentition period and is becoming appealing procedure, despite the fact that later reports of complications including resorption of the bone graft, mucosal breakdown with loss of bone, root resorption, and failed tooth eruption had been reported. Morbidity related to donor sites was also described [2].

#### *Conclusion:*

Based on our preliminary results, we can say that the benefits of our modified GPP technique outweigh its drawbacks in terms of being a simple straightforward technique with insignificant complications & it doesn't require any drastic preoperative orthopedics. Our cases showed adequate cleft gap closure regardless of gap width and laterality with appropriate alignment and restoration of normal arch configuration in the majority of cases. Although the effects of GPP on facial growth are still controversial, yet in our case long term follow-up would still be advised verify such effects.



## REFERENCES

- 1- Marazita, M.L. and Mooney M.P.: Current concepts in the embryology and genetics of cleft lip and cleft palate. *Clin. Plast. Surg.*, 31: 125-140, 2004.
- 2- Cindy H.H., Ellen W.K., Philip K.C. and Chiung S.H.: The Effect of Gingivoperiosteoplasty on Facial Growth in Patients With Complete Unilateral Cleft Lip and Palate. *Cleft Palate–Craniofacial Journal*, September, 47 (5): 439-446, 2010.
- 3- Smith W.P., Markus A.F. and Delaire J.: Primary closure of the cleft alveolus: A functional approach. *Br. J. Oral Maxillofac. Surg.*, 33: 156-165, 1995.
- 4- Sameh A. Seifeldin: Is alveolar cleft reconstruction still controversial? (Review of literature). *The Saudi Dental J.*, 28 (1): 3-11, 2016.
- 5- Skoog T.: The use of periosteal flaps in the repair of cleft of the primary palate. *Cleft Palate J.*, 2: 332-339, 1965.
- 6- Millard D.R. and Latham R.A.: Improved primary surgical and dental treatment of clefts. *Plast. Reconstr. Surg.*, 86: 856-871, 1990.
- 7- Grayson B.H. and Cutting C.B.: Presurgical nasoalveolar orthopedic molding in primary correction of the nose, lip, and alveolus of infants bone with unilateral and bilateral clefts. *Cleft Palate Craniofac J.*, 38: 193-198, 2001.
- 8- Wood R.J., Grayson B.H. and Cutting C.B.: Gingivoperiosteoplasty and midfacial growth. *Cleft Palate Craniofac. J.*, 34: 17-20, 1997.
- 9- Santiago P.E., Grayson B.H., Cutting C.B., Gianoutsos M.P., Brecht L.E. and Kwon S.M.: Reduced need for alveolar bone grafting by presurgical orthopedics and primary gingivoperiosteoplasty. *Cleft Palate Craniofac. J.*, 35: 77-80, 1998.
- 10- Lee T.H., Grayson B.H., Cutting C.B., Brecht L.E. and Lin W.Y.: Prepubertal midface growth in unilateral cleft lip and palate following alveolar molding and gingivoperiosteoplasty. *Cleft Palate Craniofac. J.*, 41: 375-380, 2004.
- 11- Ritsila V., Alhopuro S. and Rintala A.: Bone formation with free periosteum. *Scand J. Plast. Reconstr. Surg.*, 6: 51-56, 1972.
- 12- Azzolini A., Riberti C., Rosselli D. and Standoli L.: Tibial periosteal graft in repair of cleft lip and palate. *Ann. Plast. Surg.*, 9: 105-112, 1982.
- 13- Hellquist R., Svarstrom K. and Ponten B.: A longitudinal study of delayed periosteoplasty to the cleft alveolus. *Cleft Palate J.*, 20: 277-288, 1983.
- 14- Millard D.R.: *Cleft Craft: The Evolution of Its Surgery. III. Alveolar and Palatal Deformities.* Boston: Little, Brown, 285-287, 1980.
- 15- Hassan A.B., Hazem M.A. and Amir S.E.: Personal Technique for Primary Repair of Alveolar Clefts. *Cranio-maxillofac Trauma Reconstr. Mar.*, 5 (1): 51-58, 2012.
- 16- Meazzini M.C., Tortora C., Morabito A., Garattini G. and Brusati R.: Alveolar bone formation in patients with unilateral and bilateral cleft lip and palate after early secondary gingivoalveoloplasty: Long-term results. *Plast. Reconstr. Surg.*, 119: 1527-1537, 2007.
- 17- Ross R.B.: Treatment variables affecting facial growth in complete unilateral cleft lip and palate. Part 7: An overview of treatment and facial growth. *Cleft Palate J.*, 24: 71-77, 1987.
- 18- Carstens M.H.: Correction of unilateral cleft lip nasal deformity using the sliding sulcus procedure. *J. Craniofac. Surg.*, 10: 346-364, 1999.
- 19- Delaire J.: Premiers re'sultats de la gingivo-pe'riosteoplastieprimaire (avec ou sans osteo-plastie) In: Brunati Sed. *Iltrattamentochirurgico e ortodonticodellalabio-palatoschisi: Laricostruzionedell'equilibriofunzionale* Como, Italy: CesareNani, Lipomo, 1989.
- 20- Brusati R. and Garattini G.: The early secondary gingivoperiosteoplasty. *Oral Maxillofac. Surg. Clin. North Am.*, 12: 443-453, 2000.
- 21- Sato Y., Grayson B.H., Garfinkle J.S., Barillas I., Maki K. and Cutting C.B.: Success rate of gingivoperiosteoplasty with and without secondary bone grafts compared with secondary alveolar bone grafts alone. *Plast. Reconstr. Surg.*, 121: 1356-1369, 2008.
- 22- Henkel K.O. and Gundlach K.K.H.: Analysis of primary gingivoperiosteoplasty in alveolar cleft repair. Part I: facial growth. *J. Craniomaxillofac. Surg.*, 25: 266-269, 1997.
- 23- Barry H. Grayson and Pradip R. Shetye: Presurgical nasoalveolar moulding treatment in cleft lip and palate patients. *Braz. Oral Res.*, 29 (1): 29-42, 2015.
- 24- Grayson B.H., Santiago P.E., Brecht L.E. and Cutting C.B.: Presurgical nasoalveolar molding in infants with cleft lip and palate. *Cleft Palate Craniofac. J.*, 36: 486-498, 1999.