

Post Mastectomy Delayed Breast Reconstruction with DIEP Flap: Experience with 33 Unilateral Cases

YEHIA ZAKARIA, M.D.^{1,2}; QUTAIBAH ALKANDARI, M.D.²; H.I. ELDWENY, M.D.³ and ABD-ELRAHMAN SARHAN, M.D.⁴

The Department of Surgery, Plastic & Reconstructive Surgery Unit, Faculty of Medicine, Zagazig University¹; Al-Babtain Center for Burns & Plastic Surgery, Ministry of Health, Kuwait²; The Surgical Oncology Department, Kuwait Cancer Control Centre, Kuwait³ and National Cancer Institute, Cairo University and Department of Surgery, Faculty of Medicine, Zagazig University⁴, Zagazig

ABSTRACT

Background: This study was conducted in Kuwait Cancer Control Center, Ministry of Health, State of Kuwait, during the period from May 2010 to April 2015.

Aim of Work: To report and summarize the prospectively collected data of 33 free DIEP flaps used for unilateral post-mastectomy delayed breast reconstruction.

Material & Methods: It included 33 patients with post mastectomy scars. Their ages ranged between 24 and 55 years (average 41.6 years). The average operative time was 377.1 minutes. The success rate was 97% with one case of partial flap necrosis. The rate of take-back to the operative theatre for microvascular related problems was 12%.

Results: One patient (3%) developed haematoma underneath the flap, 2 patients (6.1%) developed abdominal seroma and 3 patients developed fat necrosis in an average period of 3.8 (range of 3-5) months after surgery. Two patients (6.1%) had abdominal wound dehiscence. No mortality cases were reported. The average hospital stay was 8.1 days. The average follow-up period was 17.1 months. No reported cases of abdominal bulge or incisional hernia. All patients were satisfied about the abdominal contour postoperatively. Twenty five patients (75.8%) were happy about the cosmetic appearance of the reconstructed breast, 8 patients were satisfied about having a breast mound. Secondary refinement procedures were done to improve symmetry and cosmetic appearance and included; breast reduction, augmentation, mastopexy, NAC reconstruction and scar revisions.

Key Words: Mastectomy – Delayed – Breast reconstruction – DIEP flap.

INTRODUCTION

Breast is an essential symbol of femininity. It influences the woman's self confidence, body image and self esteem. Breast cancer continues to place a significant burden on the health care systems, the incidence of breast cancer in the United States is 1 in every 8 women [1]. In Kuwait, it is the first cancer site. Between January and December 2012, 420 breast cancer cases were collected by Kuwait cancer registry accounting for about 20%

of all cancers and 38% of cancers among females. Breast conservation techniques offer the best treatment for local control of breast cancer, but not all the patients are candidates for such techniques and almost 30% of breast cancer patients will be treated by mastectomy [2].

Breast reconstruction following mastectomy is now considered an essential part in the treatment of those patients because of its positive impact on the patient's psychology and quality of life. The ideal method for breast reconstruction should be safe, reliable and with minimum donor site morbidity [3]. Methods available for breast reconstruction are either prosthesis based or autogenous reconstruction. The autogenous reconstruction has the advantage of being able to create a soft, naturally ptotic, symmetrical breast mound which has the tendency to match with the contralateral native breast both in shape and consistency; also there is no need for periodical revisions as in cases of implant reconstructions [4]. Autogenous breast reconstruction most commonly uses the lower abdominal tissues as proven to be a good source of high quality soft tissue of adequate volume and also because of the hidden scar of the donor site [5,6]. The TRAM (transverse rectus abdominus myocutaneous) flap has been the most popular flap used for breast reconstruction. Many modifications and refinements have been introduced to improve the flap survival such as the bipediced TRAM, supercharged TRAM and the free TRAM flap. Donor site morbidity has been always a major concern in breast reconstruction topic, so trying to minimize it, the technique of pedicled TRAM flap has evolved to MS-TRAM (muscle sparing) flap and then to perforator flaps like the DIEP (deep inferior epigastric artery perforator) flap and the SIEA (superficial inferior epigastric artery

perforator) flap which spare the whole rectus abdominus muscle and rectus sheath [7,8,9].

The aim of this study is to report and summarize the prospectively collected data of 33 free DIEP flaps used for unilateral postmastectomy breast reconstruction in 33 patients, and to evaluate the feasibility, aesthetic outcome and donor site morbidity of the technique.

PATIENTS AND METHODS

This study was carried out in Kuwait Cancer Control Center, Ministry of Health, State of Kuwait during the period from May 2010 till April 2015. It included 33 patients, their ages ranged between 24 and 55 years (average 41.6 years). Table (1) shows patients criteria and preoperative comorbid conditions.

Delayed reconstruction was done in all cases after they completed the adjuvant therapy.

Preoperative preparation:

The management plan was discussed and approved by the tumor board in the hospital involving all specialties concerned in the treatment of cancer patients like surgeons, plastic surgeons, radiotherapists and chemotherapists. Patients on Tamoxifen, a selective estrogen receptor modulator, are advised to stop it 28 days before the operation to reduce its potential risk of increasing microvascular flap complications [10].

A written consent for DIEP flap as the primary reconstructive choice was taken after discussing the procedure and all possible complications, the consent also included the possible chance to change to another flap like MS TRAM if the perforator anatomy was found unfavorable intraoperatively. Pre operative CTA (CT angiography) was done for all patients to map out the perforator anatomy of the abdominal wall and localize the biggest caliber perforator with the least intramuscular course to help save operative time (Fig. 1). If the intraoperative perforator anatomy was less ideal with an absent perforator vein less than 1.5mm in diameter and a palpable arterial pulsation, vein only perforator or extensive intramuscular course of the perforators [11,12], a DIEP flap was converted to a free MS TRAM and was not included in our study.

Marking was done like standard abdominoplasty in the standing position. The contralateral half of the abdomen to the side to be reconstructed was always chosen as it provided better flap inseting. The most relevant perforators identified by the CTA were marked on the skin (Fig. 2).

Surgical technique:

A Two-team approach was always implemented, simultaneously raising the flap and preparing the recipient vessels at the same time. The internal mammary vessels were used as recipient vessels at the level of the 3rd intercostal space in all cases. A portion of the 3rd rib was removed to allow for better exposure of the vessels and easier microvascular anastomoses (Fig. 3).

Flap harvesting started by the lower skin incision, identification of the superficial inferior epigastric vessels and if found of good size, the vein was dissected for few centimeters to be used as a backup for the venous drainage of the flap in case of venous congestion (Fig. 4), but we did not need to use it in this series. The superior skin incision was then made and flap elevation proceeded rapidly from lateral to medial till we approach the site of the marked perforator where dissection was slowed down and continued carefully till we found the perforator. Dissection of the perforator vessels through the rectus muscle then proceeded using low-power bipolar electrocautery, after opening the anterior rectus sheath around the perforator, to the deep inferior epigastric artery and vein (Fig. 5). Care was taken to avoid injury of any of the intercostal nerves innervating the muscle and crossing the pedicle from lateral to medial. Dissection of the pedicle then continues till its origin from the common femoral vessels to gain enough length for comfortable anastomosis. Using the operative microscope, the arterial anastomosis was done using nylon 8-0 and the venous anastomosis was done using nylon 9-0 sutures. The flap is then sutured in place, after discarding zone IV, in layers over a closed suction drain away from the vascular pedicle. All flaps were harvested with no muscle or fascia (Figs. 6,7).

Donor site closure was done at the same time of flap inseting after completion of the microvascular anastomoses. The anterior rectus sheath was repaired in 2 layers; first layer with interrupted figure of 8 polypropylene size 2-0 sutures and second layer with running polyglactin 910 size 0 sutures. No mesh reinforcement of the abdominal wall was needed in any of our cases. Two suction drains were applied in the flap donor site (Figs. 8,9).

Postoperatively the patients spent 1 night in the ICU (intensive care unit) then transferred to the surgical ward.

Routine use of postoperative anticoagulation regimen was not practiced in this study, only prophylactic regimen against DVT (deep venous thrombosis). Full heparinization protocol was

adopted only in cases of revision of the vascular anastomosis.

Chemoprophylaxis using intra-venous Cefuroxime 1.5gm was started at the time of induction of anaesthesia and repeated 8 hourly for 3 doses postoperatively.

Patients were evaluated for flap survival, satisfaction with the reconstructed breast, flap and donor site (abdominal) morbidity.

Patient satisfaction was assessed subjectively during the follow-up visits.

Abdominal morbidity was assessed by means of strength and contour. Abdominal strength is evaluated by the ability to perform sit-ups from supine position. Abdominal contour was assessed by physical examination which included inspection to detect any abdominal bulge and palpation to determine if any fascial defect was present.

RESULTS

In this series, we operated on 33 patients for unilateral breast reconstruction. The operative time ranged between 330 minutes to 400 minutes (average 377.1 minutes). Twenty flaps (60.6%) were vascularised by a single perforator, 8 flaps (24.2%) were vascularised by 2 perforators and 5 flaps (15.2%) were vascularised by three perforators in a row. Thirty two flaps (97%) survived completely and 1 flap (3%) had partial necrosis and required surgical debridement. Four patients (12%) were retaken to the operative theatre for vascular related problems and anastomoses were checked on. In 1 case there was arterial spasm and revision of the anastomosis was done with application of local vasodilators; the flap survived with partial necrosis. We considered it a case of failed reconstruction as the patient required another procedure (pedicled LD myocutaneous flap) to achieve successful breast reconstruction. This patient was a 40 year old, diabetic, with previous chest radiotherapy.

The other 3 patients had flap venous congestion developed on postoperative day 1. In 1 patient, thrombus was found and was evacuated from the vein and the flap survived completely. In the other 2 patients there was no thrombus found and the patients were kept on full heparinization protocol and the flaps survived completely and venous congestion improved gradually afterwards. One patient (3%) developed haematoma underneath the flap and was evacuated in the operative theatre on postoperative day 2. Two patients (6.1%) developed flap donor site seroma and was treated conservatively by repeated aspirations and pressure gar-

ments. Three patients (9.1%) developed fat necrosis of the flap in an average period of 3.8 (range of 3-5) months after surgery. Fat necrosis was detected as any palpable firm nodules more than 1cm, and proved not to be recurrent malignancy, found in the breast 3 months or more after surgery [14]. Table (2) shows the flap complications.

Two cases (6.1%) had wound dehiscence of the flap donor site; they were closed under tension and were treated conservatively by dressing and VAC (vacuum assisted control) therapy. No mortality cases related to the procedure were recorded during the follow-up period.

The hospital stay ranged between 5 and 12 days (average 8.1 days).

The follow-up period ranged between 8 and 23 months (average 17.1 months) postoperatively.

None of our patients developed abdominal bulge in the standing position or hernia during the follow-up period. All patients were able to perform sit-ups from supine position. They were able to do their routine daily activities as before surgery. All our patients were satisfied about the postoperative abdominal contour.

Four patients (12.1%) had hypertrophy of the abdominal scar and were treated conservatively.

Regarding the aesthetic outcome, 25 patients (75.8%) were happy with the cosmetic appearance of the reconstructed breast, however they had concerns about breast asymmetry. The remaining 8 patients (24.2%) were satisfied for having a breast mound, but they were not happy. After performing secondary procedures to improve symmetry, revise scars and reconstruct the NAC (nipple areola complex) they expressed themselves as happy about the procedure. Table (3) shows the contralateral and the reconstructed breast procedures performed for symmetry and to improve the aesthetic outcome.

Table (1): Patients' criteria and preoperative comorbidities.

	N = 33 patients
Mean age, years (range)	41.6 (24-55)
Smoking	2 (6.1%)
Preoperative irradiation	6 (18.2%)
<i>Previous abdominal surgery:</i>	
Lower midline	1 (3%)
CS (Pfannenstiel)	1 (3%)
Liposuction	2 (6.1%)
<i>Medical problems:</i>	
Diabetes	1 (3%)
Hypertension	4 (12.1%)
Cardiac	1 (3%)

CS: Caesarian section.

Table (2): Flap complications.

	N = 33 patients
Flap failure	1 (3%)
Fat necrosis	3 (9.1%)
Average no. of months to fat necrosis	3.8 (3-5)
Infection	0 (0%)
Haematoma	1 (3%)
Seroma	2 (6.1%)
<i>Wound dehiscence:</i>	
Abdominal	2 (6.1%)
Flap	0

Table (3): Procedures performed for symmetry.

	Contralateral breast	Reconstructed breast	Timing
Reduction	15 (45.5%)	0	12-18 months
Augmentation	0	1 (3%)	12-20 months
Mastopexy	8 (24.2%)	0	12-18 months
NAC reconstruction	–	13 (39.4%)	12-23 months
Scar revision	–	6 (18.2%)	10-15 months

NAC: Nipple areola complex.

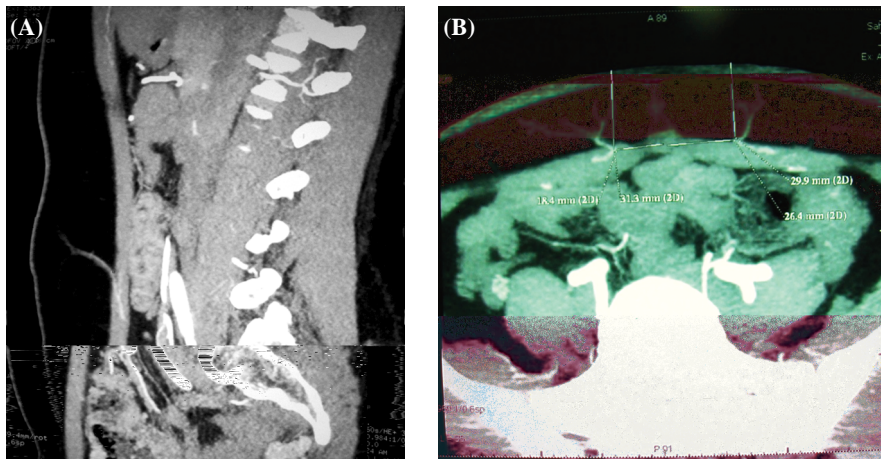


Fig. (1): (A) Sagittal CT angiography image showing the course of the deep inferior epigastric artery perforators through the rectus muscle and fat. (B) Axial CT angiography image showing different perforator sizes.

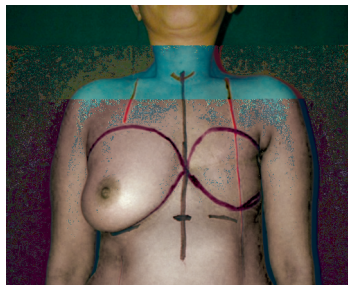


Fig. (2): Preoperative markings with the site of the most reliable perforator marked on the skin.



Fig. (3): Exposure of the internal mammary vessels in the 3rd intercostal space after excision of a portion of the 3rd rib.

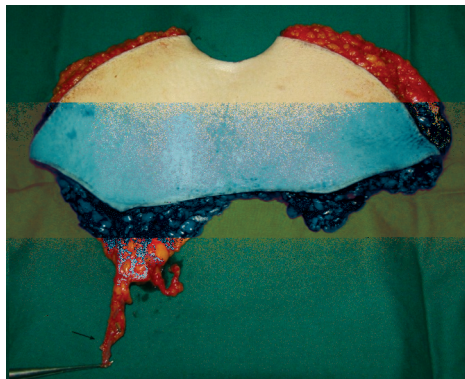

Fig. (4): DIEP flap completely harvested and separated, the arrow shows the superficial inferior epigastric vein (SIEV).




Fig. (5): Complete dissection of the perforator vessels through the rectus muscle and fascia to the deep inferior epigastric vessels.




Fig. (6): DIEP flap harvested as skin and fat flap without any muscle or fascia remnants.

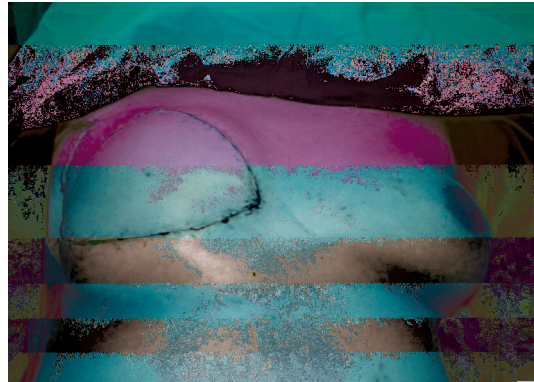

Fig. (7): The flap sutured in place over a closed suction drain away from the vascular pedicle.

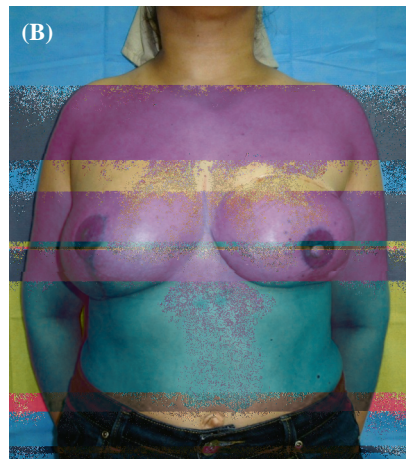
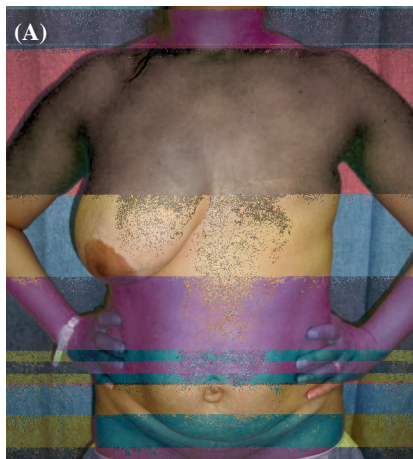

Fig. (8): (A) Preoperative view of a 35 years old patient to undergo left breast reconstruction with DIEP flap. (B) 3 months following second-stage surgery with nipple reconstruction and reduction of the contralateral breast.

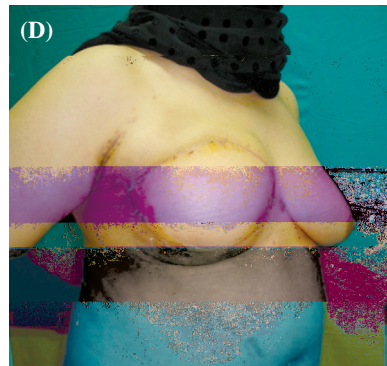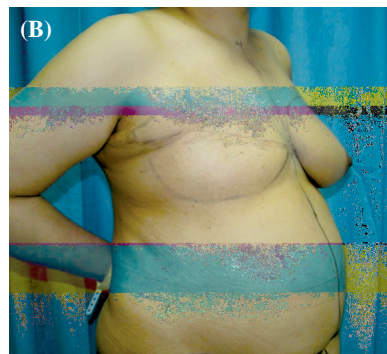

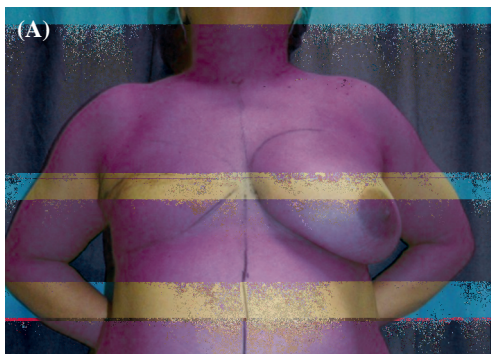
Fig. (9): (A,B) Preoperative views of a 54 years old patient to undergo right breast reconstruction. (C,D) 2 months postoperative views.

DISCUSSION

Perforator flaps represent the most recent advance in the evolution of flap surgery; they allowed the transfer of skin and fat with minimal donor site morbidity as there is no sacrifice of the underlying muscles [14]. Koshima and Soeda [15] reported their success to transfer the skin and fat of the lower abdomen, above the rectus muscle, to reconstruct a defect in the floor of the mouth based on a perforator vessel. Allen and Treece [16] used the same principle and reported the use of the deep inferior epigastric perforator flap for breast reconstruction. Since then, the DIEP flap has been widely used by many plastic surgeons till it become a routine procedure in many centres all over the world [17]. Sereletti [18] stated that the DIEP flap is a technically demanding procedure and perforator dissection is tedious and requires patience. He reported that operative time of 5 or 6 hours is common and acceptable and he agreed that spending more operative time performing this procedure than doing a pedicled TRAM flap is worth the long-term benefits of keeping the integrity of the abdominal wall by preserving the rectus muscle with its fascia and nerve supply. In our study the mean operative time is 337.1 minutes (5.6 hours) which is comparable with other reports [19,20]. We believe our operative time will reduce gradually as our experience increases, especially that we do routine preoperative CTA to map the abdominal perforators and localize the most reliable ones and help save operative time. Many authors recommend using preoperative CTA and reported significant reduction in operative time [21,22]. However, in some cases the intraoperative clinical judgement may lead to changing the preoperative plan based on the CTA. In our study we faced this in two cases where we had to change the plan of reconstruction to MS-TRAM flap but, we did not include them in this series. Zhong et al. [23] made their final decision to use a DIEP flap or free MS-TRAM flap ultimately based on the intraoperative assessment of the perforators. We agree also with Keys et al. [22] that surgeon should be cautious in reliance to CTA mapping and significant perforators should not be sacrificed until the anticipated perforator(s) have been exposed and evaluated clinically. Adopting this, and of course the fact that we are still in the beginning of our learning curve may add to our relatively long operative time.

The rate of flap failure and fat necrosis in our patients is comparable to other reports [17,19,24]. Those reports compared the pedicled TRAM with the DIEP flap breast reconstruction and they attributed the low rate of perfusion-related complications

as fat necrosis and zones III and IV necrosis in the DIEP flap patients to the fact that the anterior abdominal wall is mainly vascularised by the inferior epigastric artery [25,26] which is the pedicle of the DIEP flap. Zhong et al. [23] used propensity score analysis of breast reconstruction related complications and reported that the presence of diabetes is a predictor of major breast complications including flap failure.

Previous abdominal wall surgery was for long considered as a contraindication to abdominal based free tissue transfer; however outcomes of free flaps following previous abdominal wall surgery are increasingly reported in the literature. It was reported that undermining of the lower abdominal apron and division of the superficial epigastric vessels, in most of time, results in ischemic preconditioning of the flap proved by increased diameter of the perforators as shown by imaging studies like CTA and colour Doppler [27,28,29]. In our study we used preoperative CTA for all patients to assess and evaluate the perforators. We had 4 patients with previous abdominal wall surgeries 8 years or more before DIEP breast reconstruction and all of them had successful DIEP flaps.

Blondeel [20] reported an average hospital stay for unilateral breast reconstruction patients to be 7.9 days which is comparable with our results. We agree with Garvey et al. [19] who referred the short hospital stay in their DIEP group of patients (average 4 days), compared to the pedicled TRAM flap group (average 5 days) to the lesser damage done to the abdominal wall in case of the DIEP flap and hence less postoperative pain, faster recovery and earlier return to normal daily activities. They considered the short hospital stay an advantage that again justified the longer operative time compared with other traditional TRAM flap techniques.

We did not report any case of abdominal bulge or incisional hernia in any of our patients during the follow-up period; this is comparable with other authors' data [7,9,30]. Some authors reported cases of DIEP flap complicated by incisional hernia, in comorbid patients especially the obese ones, in a much lower incidence than the free, MS- or pedicled TRAM flap breast reconstruction [31,32]. Abdominal bulge results from damage to 1 or 2 of the intercostal nerves mostly in the form of neuropathic pain from traction on the nerves during harvesting of the DIEP flap. This results in temporary paralysis of the segment of the rectus muscle innervated by that intercostal nerve and it's more likely to recover with time [19,31,33].

DIEP flap potentially offers patients greater postoperative abdominal strength compared to other traditional TRAM flap techniques. In our study, we evaluated the postoperative abdominal strength subjectively by the ability to perform sit-ups from supine position. We did not do objective assessment using isokinetic tests but other studies did and reported that the DIEP groups had significantly higher trunk flexion abilities. When assessing the functional deficit of the abdominal wall muscles postoperatively, DIEP flaps showed return to the baseline for both rectus abdominus and oblique muscles function [8,20,34]. Atisha and Alderman [8] found out that subjective assessment of the abdominal wall function showed similar results between unipedicled TRAM, free TRAM and DIEP flaps with no increased ability to perform sit-ups in the DIEP patients compared with the other groups. We agree with them and with Nahabedian et al. [9] that the ability to perform sit-ups does not accurately reflect the abdominal strength because of the compensation from the other rectus, oblique and iliopsoas muscles and we agree also that most of the patients are satisfied about the postoperative abdominal strength and their ability to perform daily activities as they used to do preoperatively.

The aesthetical outcome in breast reconstruction is very important both to the patient and plastic surgeon. Breast asymmetry is more likely to be observed in cases of unilateral breast reconstruction; the contralateral breast is more frequently bigger and needs reduction. It is rarely reported, especially in young females, that the native breast to be hypoplastic and needs augmentation [35], this is comparable with our results. Many reports in the literature show the high satisfaction of women underwent breast reconstruction by DIEP flap, especially after doing the refinement and touch-up procedures to achieve breast symmetry and improve the cosmetic appearance of the reconstructed breast [36,37].

In Conclusion:

This study indicates that the autogenous breast reconstruction using DIEP flap is a safe, reliable and with high rate of patient satisfaction. It reduces the donor site morbidity by maintaining the integrity of the abdominal wall muscles, postoperative pain is less, recovery is faster and hospital stay is shortened. Other prospective studies with bigger number of patients, in comparable groups, with longer follow-up periods are necessary to compare this technique with other techniques of breast reconstruction.

REFERENCES

- 1- De Angelis R., Tavilla A., Verdecchia A., Scoppa S., Hachey M., Feuer E.J. and Mariotto A.B.: Breast cancer survivors in the united states: Geographic variability and time trends, 2005-2015. *Cancer*, 115: 1954, 2009.
- 2- Lee K., Mun G., Lim S., Pyon J., Oh K. and Bang S.: The impact of immediate breast reconstruction on post-mastectomy lymphedema in patients undergoing modified radical mastectomy. *The Breast*, 22: 53, 2013.
- 3- Tachi M. and Yamada A.: Choice of flaps for breast reconstruction. *Int. J. Clin. Oncol.*, 10: 189, 2005.
- 4- Hidalgo D.A., Borgen P.J., Petrek J.A., Heerd A.H., Cody H.S. and Disa J.J.: Immediate reconstruction after complete skin-sparing mastectomy with autologous tissue. *J. Am. Coll. Surg.*, 187: 17, 1998.
- 5- Coroneos C.J., Heller A.M., Voineskos S.H. and Avram R.: SIEA versus DIEP arterial complications: A cohort study. *Plast. Reconstr. Surg.*, 135: 802e, 2015.
- 6- Wang X., Liu L., Song F. and Wang Q.: Meta-analysis of the safety and factors contributing to complications of MS-TRAM, DIEP, and SIEA flaps for breast reconstruction. *Aesth. Plast. Surg.*, 38: 681, 2014.
- 7- Chang E.I., Chang E.I., Soto-Miranda M.A., Zhang H., Nosrati N., Robb G.L. and Chang D.W.: Comprehensive analysis of donor-site morbidity in abdominal based free flap breast reconstruction. *Plast. Reconstr. Surg.*, 132: 1383, 2013.
- 8- Atisha D. and Alderman A.K.: A systemic review of abdominal wall function following abdominal flaps for postmastectomy breast reconstruction. *Ann. Plast. Surg.*, 63: 222, 2009.
- 9- Nahabedian M.Y., Momen B., Galdino G. and Manson P.N.: Breast reconstruction with the free TRAM or DIEP flap: patient selection, choice of flap, and outcome. *Plast. Reconstr. Surg.*, 110: 466, 2002.
- 10- Kelley B.P., Valero V., Yi M. and Kronowitz S.J.: Tamoxifen increases the risk of microvascular flap complications in patients undergoing microvascular breast reconstruction. *Plast. Reconstr. Surg.*, 129: 305, 2012.
- 11- Keys K.A., Louie O., Said H.K., Neligan P.C. and Mathes D.W.: Clinical utility of ct angiography in DIEP breast reconstruction. *J. Plast. Reconstr. Surg.*, 66: e61, 2013.
- 12- Bajaj A.K., Chevray P.M. and Chang D.W.: Comparison of donor-site complications and functional outcomes in free muscle-sparing TRAM flap breast reconstruction. *Plast. Reconstr. Surg.*, 117: 737, 2006.
- 13- Kroll S.S.: Fat necrosis in free transverse rectus abdominus myocutaneous and deep inferior epigastric perforator flaps. *Plast. Reconstr. Surg.*, 106: 576, 2000.
- 14- Granzow J.W., Levine J.L., Chiu E.S., LoTempio M.M. and Allen R.J.: Breast reconstruction with perforator flaps. *Plast. Reconstr. Surg.*, 120: 1, 2007.
- 15- Koshima I. and Soeda S.: Inferior epigastric artery skin flaps without rectus abdominus muscle. *Br. J. Plast. Surg.*, 42: 645, 1989.
- 16- Allen R.J. and Treece P.: Deep inferior epigastric perforator flap for breast reconstruction. *Ann. Plast. Surg.*, 32: 32, 1994.

- 17- Benditte-Klepetko H.C., Lutgendorff F., Kästenbauer T., Deutinger M. and van der Host C.M.A.M.: Analysis of patient satisfaction and donor-site morbidity after different types of breast reconstruction. *Scand. J. Surg.*, 103: 249, 2014.
- 18- Serletti J.M.: DIEP and pedicled TRAM flaps: A comparison of outcomes. *Plast. Reconstr. Surg.*, 117: 1720, 2006.
- 19- Garvey P.B., Buchel E.W., Pockaj B.A., Casey W.J., Gray R.J., Hernandez J.L. and Samson T.D.: DIEP and pedicled TRAM flaps: A comparison of outcome. *Plast. Reconstr. Surg.*, 117: 1711, 2006.
- 20- Blondeel P.N.: One hundred free DIEP flap breast reconstruction: A personal experience. *Br. J. Plast. Surg.*, 52: 104, 1999.
- 21- Smit J.M., Dmopoulou A., Liss A.G., Zeebregts C.J., Kildal M., Whitaker I.S., Magnusson A. and Acosta R.: Preoperative ct angiography reduces surgery time in perforator flap reconstruction. *J. Plast. Reconstr. Aesthet. Surg.*, 62: 1112, 2009.
- 22- Keys K.A., Louie O., Said H.K., Neligan P.C. and Mathes D.W.: Clinical utility of ct angiography in DIEP breast reconstruction. *J. Plast. Reconstr. Aesthet. Surg.*, 66: e61, 2013.
- 23- Zhong T., Novak C.B., Bagher S., Maass S.W.M.C., Zhang J., Arad U., O'Neill A.C., Metcalfe K.A. and Hofer S.O.P.: Using propensity score to compare major complications between DIEP and free muscle-sparing TRAM flap breast reconstruction. *Plast. Reconstr. Surg.*, 133: 774, 2014.
- 24- Momoh A.O., Colakoglu S., Westvik T.S., Curtis M.S., Yueh J.H., de Blacam C., Tobias A.M. and Lee B.T.: Analysis of complications and patient satisfaction in pedicled transverse rectus abdominus myocutaneous and deep inferior epigastric perforator flap breast reconstruction. *Ann. Plast. Surg.*, 69: 19, 2012.
- 25- Taylor G.I. and Minabe T.: The angiosomes of the mammals and other vertebrates. *Plast. Reconstr. Surg.*, 89: 181, 1992.
- 26- Moon H.K. and Taylor G.I.: The vascular anatomy of the rectus abdominus musculocutaneous flaps based on the deep superior epigastric system. *Plast. Reconstr. Surg.*, 82: 815, 1988.
- 27- Mahajan A.L., Zeltzer A., Claes K.E., Van Landuyt K. and Hamdi M.: Are Pfannenstiel scars a boon or a curse for DIEP flap breast reconstructions? *Plast. Reconstr. Surg.*, 129: 797, 2012.
- 28- Sagarello M., Barone-Adesi L., Cina A. and Farallo E.: The effect of liposuction on inferior epigastric perforator vessels: A prospective study with color Doppler sonography. *Ann. Plast. Surg.*, 55: 346, 2005.
- 29- Farid M., Nicholson S., Kotwal A. and Akali A.: DIEP breast reconstruction following multiple abdominal liposuction procedures. *EPlasty*, 14: e47, 2014.
- 30- Nelson J.A., Guo Y., Sonnad S.S., Low D.W., Kovach S.J. 3rd, Wu L.C. and Serletti J.M.: A comparison between DIEP and muscle-sparing free TRAM flaps in breast reconstruction: A single surgeon's recent experience. *Plast. Reconstr. Surg.*, 126: 1428, 2010.
- 31- Scheer A.S., Novak C.B., Neligan P.C. and Lipa J.E.: Complications associated with breast reconstruction using a perforator flap compared with a free TRAM flap. *Ann. Plast. Surg.*, 56: 355, 2006.
- 32- Takeishi M., Fujimoto M., Ishida K. and Makino Y.: Muscle sparing-2 transverse rectus abdominus musculocutaneous flap for breast reconstruction a comparison with deep inferior epigastric perforator flap. *Microsurgery*, 28: 650, 2008.
- 33- Nahabedian M.Y., Tsangaris T. and Momen B.: Breast reconstruction with the DIEP flap or the muscle-sparing (MS-2) free TRAM flap: Is there a difference? *Plast. Reconstr. Surg.*, 115: 436, 2005.
- 34- Hamdi M., Weiler-Mithoff E.M. and Webster M.H.: Deep inferior epigastric perforator flap in breast reconstruction: Experience with the first 50 flaps. *Plast. Reconstr. Surg.*, 103: 86, 1999.
- 35- Gelati C., Negosanti L., Fabbri E. and Cipirani R.: Aesthetical outcome after breast reconstruction using deep inferior epigastric perforator flap: Personal techniques. *Indian J. Plast. Surg.*, 46: 513, 2013.
- 36- Damen T.H.C., Timman R., Kunst H.H., Gopie J.P., Bresser P.J.C., Seynaeve C., Menke-Pluijmers M.B., Mureau M.A.M., Hofer S.O.P. and Tibben A.: High satisfaction rates in women after DIEP flap breast reconstruction. *J. Plast. Reconstr. Aesthet. Surg.*, 63: 93, 2010.
- 37- Damen T.H.C., Mureau M.A.M., Timman R., Rakhorst H.A. and Hofer S.O.P.: the pleasing end result after DIEP flap breast reconstruction: A review of additional operations. *J. Plast. Reconstr. Aesthet. Surg.*, 62: 71, 2009.