

The Use of Pedicled Ulnar Artery Perforator Flaps in the Coverage of Firearm Injuries in the Forearm and Hand

HUSAM HOSNY, M.D.; HAMED M. KADRY, M.D. and OMAR A. ELSHARKAWY, M.D.

The Department of Plastic Surgery, Faculty of Medicine, Cairo University

ABSTRACT

Background: During recent years the wide availability of firearms has resulted in a sharp increase in the number of gunshot victims presenting with a wide variety of complicated wounds over the extremities. A limited number of local axial flaps can be used to cover these challenging defects. The use of perforator flaps has offered another option for local coverage. This study explored the use of ulnar artery perforator flaps in the coverage of firearm defects over the forearm and hand.

Methods: This study included 6 patients presenting with firearm injuries, presenting with defects over the hand and forearm. Five patients presented with shotgun injuries from a close range, while one patient had a gun shot injury. The locations of ulnar artery perforators were detected by duplex studies and free style perforator flaps were then used to cover the defects.

Results: Successful stable coverage was achieved in all 6 cases. Four cases healed uneventfully while minor complications were encountered in 2 cases in the form of partial loss and infection. Four cases were designed as propeller flaps and rotated 180° while 2 cases had a skin pedicle and were rotated 90°.

Conclusion: Ulnar based perforator flaps offer a reliable method for reconstruction in the forearm and proximal hand. They are suitable in the treatment of cases that have suffered extensive soft tissue loss second to firearm injuries. The flaps are thin, pliable, and robust. The skin is not hirsute. The scar is relatively inconspicuous. It is also a one stage procedure and does not require the sacrifice of a main vessel.

Key Words: *Ulnar artery – Perforators – Shotgun – Firearm – Freestyle flaps – Propeller flaps – Forearm – Hand.*

INTRODUCTION

During recent years the wide availability of firearms has resulted in a sharp increase in the number of gunshot victims in the casualty department of Kasr Al-Ainy hospital. Gunshot wounds in the upper limbs involve both low velocity shot gun pellets and less commonly high velocity bullet

wounds. These firearm injuries represent a very challenging problem, as the zone of injury is most often larger than the entry wound with massive tissue destruction and soft tissue loss resulting in complicated wounds that may involve exposure of vital structures that may themselves be injured such as bone fractures, nerve and tendon injuries [1].

Successful reconstruction of these wounds depends on replacing injured structures with similar tissue to provide stable soft tissue coverage [2]. Traditional flaps that are commonly used to reconstruct forearm and proximal hand defects include local fasciocutaneous flaps for the coverage of smaller defects. Larger defects are commonly covered by local axial flaps like the radial forearm flap or remote flaps as the groin flap.

The radial forearm flap is a time-honored reliable option that is favored by many surgeons for its thinness, pliability, and ease of dissection. It is a versatile option that can be used to cover various defects over the forearm and hand. However it requires the sacrifice of the radial artery which may not be feasible if there is an associated vascular injury, with the hand dependent on a single vessel [3].

The groin flap is an excellent back up flap for forearm and hand reconstruction. It provides a large flap with a concealed donor site. However it requires maintaining the hand in an uncomfortable position for weeks, positioning that may not be compatible with orthopedic external fixators. It is also a 2 stage procedure [4].

The introduction of the perforator flap concept has revolutionized reconstructive surgery. It allows the harvest of reliable flaps based on a perforating branch without the need to sacrifice the main vessel. This concept commonly used in microsurgical free

flap surgery can be applied in pedicled flaps for local reconstruction. By eliminating the microsurgical component, the applications of perforator flaps can be widespread and the potential risk of flap loss diminished [5].

Perforator flap design depends on the detection of the perforating vessels along the course of the main vessels in the vicinity of the region to be reconstructed, and then choosing the most appropriate of these perforators to support the flap. This concept can be applied anywhere along the body [6].

In the forearm perforator flaps can be designed on the radial and ulnar arteries. Many studies have focused on the applications of radial artery perforator flaps. Clusters of clinically significant perforators from the radial artery are found at the distal and proximal ends of the forearm. This allows for the design of distally based perforator flaps to cover the wrist and hand, and proximally based flaps that can cover the elbow. However, distally they are limited in their reach to the lateral aspect of the hand and palm. They cannot comfortably reach the medial aspect of the hand and cannot reach the metacarpophalangeal joints. In addition the scar from the radial artery perforator flap is obtrusive, being on the distal radial exposed (working) surface of the forearm [7].

The goal of this study is to explore the clinical applications of ulnar artery based perforator flaps in the reconstruction of various complicated wounds caused by firearm injuries around the elbow, forearm and hand.

PATIENTS AND METHODS

The study included 6 male patients who presented to the casualty department of the Kasr Al-Ainy hospital between July of 2013 and December of 2014. Five patients were injured by shotgun pellets from a close range, while only one patient had been injured by a gunshot (bullet) injury. The patients were aged 33 to 47 with an average age of 30 years.

The defects included in the study were judged to be in need for stable coverage by flaps due to the complicated nature of the injuries. All of the defects had other associated injuries. All of the patients had muscle laceration or tendon injury while 4 of the patients had associated underlying bone fractures. Two patients had defects over the hand, 2 patients had defects over the distal forearm, one patient had a defect over the middle of the

forearm while one patient had a defect over the proximal forearm. Patients' details regarding age and gender, mechanism of injury, type and location of the defects, associated injuries, flap type and postoperative result are shown in (Table 1).

All the patients were initially admitted to surgery for early debridement and fixation of the bone fractures. This was followed by repeated dressing and in some cases repeated debridement until all the wound edges and floor were cleared of necrotic tissue.

Duplex study was used to detect the site of the ulnar artery perforators nearest to the defect (Fig. 1). In all cases at least one perforator could be located near to the wound margin.

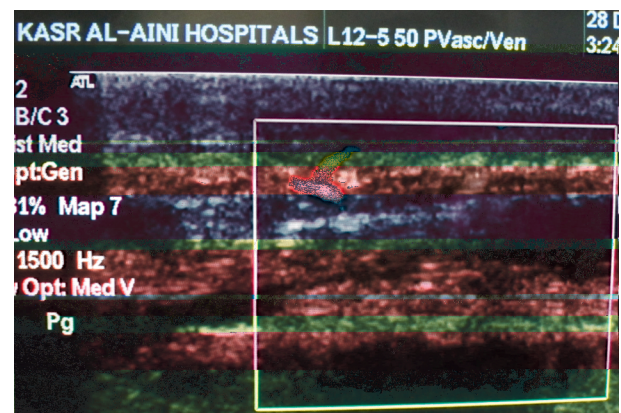


Fig. (1): Duplex study, perforator vessel as it emerges from the ulnar artery.

The principles of free style flaps, first introduced by Wei and Mardini [8] were utilized to tailor flap designs according to; the site of the defect and the site of nearby perforators.

Loupe magnification was used in all cases. All flaps were dissected under tourniquet with minimal exsanguination of blood to be able to identify the perforators during dissection. An exploratory incision is made longitudinally in the forearm, down to the deep fascia, along the axis of the ulnar artery. The marked perforator is identified and once a suitably sized and positioned perforator is identified (caliber, approximately 0.5mm), the site at which the perforator pierces the deep fascia is marked on the skin with a simple suture. The thread of this simple suture is left long and used to measure the distance between the perforator and the distal edge of the defect, then the same length of suture line is used to mark the proximal edge of the flap.

The boundaries of the proposed perforator flap are sketched out on the skin surface, and if necessary the flap design can be readjusted according to the site at which the perforator reaches the skin. The other edges of the flap are then incised and the flap rotated into the defect. Full skeletonization of the pedicle is necessary to ensure comfortable twist without kinking. If the pedicle is compromised, further deeper dissection to obtain the full

length of the perforator down to its origin from the ulnar artery may be necessary.

If a flap rotation of only 90° was needed then the skin pedicle was preserved as this did not hinder rotation. However if a rotation of 180° was needed then a propeller flap design was employed. The donor site was covered by a split thickness skin graft in all cases. All cases were followed-up for a period of 6 months postoperative.

Table (1): Characteristics of the studied cases and complications.

Case No.	Age	Sex	Etiology	Associated injury	Site of defect	Size of defect in cm	Flap size in cm	Degree of rotation	Complications
1	35	M	Shotgun	Flexor tendons of 4 th and 5 th fingers	Medial palm	6 x 4	11 x 5	180°	Infection
2	24	M	Shotgun	Fracture radius	Dorsum of middle forearm	9 x 5	15 x 6	90°	–
3	26	M	Shotgun	Fracture radius, ulna, ulnar nerve injury	Volar distal forearm	12 x 7	14 x 8	180°	–
4	47	M	Shotgun	Fracture radius	Proximal third dorsum forearm	6 x 4	9 x 4	90°	–
5	28	M	Gun shot	Median nerve, flexor tendons, fracture radius	Volar wrist	6 x 5	7 x 8	180°	Partial loss
6	22	M	Shotgun	Fracture metacarpals, exposed tendons	Dorsum of hand	6 x 5	12 x 7	180	–

RESULTS

Successful stable coverage was achieved in all 6 cases. Four cases healed uneventfully while minor complications were encountered in 2 cases in the form of partial loss in one case and infection in another case.

Duplex study was successful in detecting at least one clinically significant perforator of the ulnar artery (size 0.5mm) in the vicinity of the defect.

In one case (Fig. 3) a flap was designed based on the known location of the dorsal branch of the ulnar artery. It was used to cover a defect over the dorsum of the hand. Freestyle perforator flaps were designed in all the other cases according to the site of the ulnar artery perforators that were detected by duplex study preoperatively.

In 2 cases the perforator location allowed a flap design that only needed to be rotated 90° to cover the defect. This allowed the preservation of a skin pedicle. In the other 4 cases the flaps were designed as propeller flaps that were rotated 180°. In 5 cases the flaps were designed around one perforator even when more than one perforator could be found to prevent kinking of the perforator vessels over each other. Only one case had 2 perforators at the base of the flap as the flap only needed to be rotated 90° to reach the defect.

One case suffered from congestion post-operative with partial loss of the epidermal layer. The underlying dermal layer was intact and the case was managed conservatively until full healing was achieved. One case suffered post-operative wound infection that was managed by repeated dressing until complete healing.




Fig. (2): A 24 year old patient presented with a shotgun injury to the forearm with an exposed fractured radius (A). A large flap (15 x 6cm) was design with 2 ulnar artery perforators at its base (B). The flap was rotated 90° over the ulnar border to cover the defect (C). Flap healed completely (D).




Fig. (3): A 22 year old patient presented with a shotgun injury to the dorsum of the hand with exposed fractured 3rd, 4th and 5th metacarpal bones and exposed extensor tendons (A), a propeller flap was designed over the dorsal branch of the ulnar artery and rotated 180° to cover the defect (B).

DISCUSSION

All the patients in the study were males, probably because males were more likely to be involved in violent altercations that involve firearms.

Firearm injuries vary in presentation according to the type of weapon used. Gunshot wounds are characterized by a small inlet wound and a large outlet with severe cavitation effect and massive tissue destruction. Shotgun injuries from a long range have dispersed effect with mild to minimal penetration power, however when fired at a close range they have a devastating effect with massive tissue devitalization and necrosis. Firearm injuries are often heavily contaminated due to the abun-

dance of dead tissue. Early debridement is necessary and is often repeated until the wound is ready for definitive coverage [9].

In our series 5 cases suffered shotgun injuries from a close range resulting in devastating tissue loss, often complicated by underlying bone fractures and exposure of injured nerves and tendons that need reliable coverage. The wounds are surrounded by a zone of injury due to the cavitation and thermal effect of the firearm injury making local random flaps from the vicinity of the wound unreliable and hazardous. Often times the wounds may be complicated by a vascular injury resulting in the distal forearm and hand being supplied by a single vessel. In such cases the use of a flap

based on a main vessel such as the radial artery forearm flap is contraindicated. The use of perforator flaps allows for reliable coverage of large defects while preserving the underlying main vessel [1].

Ulnar artery perforator flaps can be designed anywhere along the course of the forearm as long as a perforator has been detected or identified. Ulnar artery perforators are distributed along the course of the vessel, with clinically significant perforators found in the distal, middle and proximal parts of the forearm [10].

In a study done by Sun et al., [2] they found 2 main clusters of clinically significant perforators emerging from the ulnar artery. These were located at the distal quarter and the proximal third of the forearm. Moreover, other studies done by Yu, et al., [10] and by Mathy, et al., [11] have both found at least 2 to 3 large perforators (size >0.5mm) emerging from the ulnar artery, distributed along its course, with around one perforator found in each of the distal, middle and proximal parts of the forearm. Mathy described an almost constant location of a perforator found within 3cm of the midpoint of the forearm in >94% of their cases [11].

In the distal part of the forearm the dorsal branch of the ulnar artery has an almost fixed location, arising 4 to 6cm from the pisiform bone. This constant location has been previously described by Becker and Gilbert [12] in the design of the Becker flap. Based on this anatomical information, in this study the location of the dorsal branch could be identified intraoperatively through surgical exploration only. However the location of other perforators of the ulnar artery needed to be identified preoperatively by Duplex studies.

The dorsal branch of the ulnar artery was used in the design of one flap. It is a sizeable artery with a large caliber 1-1.5mm [13]. It is a very reliable branch in its location and in the size of the flap that can be raised based on it. In our study a large flap 12 x 7 cm was safely dissected as a propeller flap and it survived completely.

In accordance with the results reported by Mathy it was always possible to find large caliber perforators in the middle of the forearm. In this study 3 flaps were based on the perforators located in the middle of the forearm. The average size of the middle perforator was >1mm which was enough to dissect flaps as large as 14 x 8cm safely.

It is important to identify the location and size of the ulnar artery perforators preoperatively by duplex to make sure that a sizeable perforator is located close to the wound but outside the zone of trauma.

Ulnar artery perforators that were used in flap design in this study varied in size from 0.9 to 1.5mm, with an average of 1.2mm. This allowed the successful design of flaps up to 14 x 8cm in size based on a single perforator. If the design and arc of rotation allowed the inclusion of more than one perforator, this would allow an even larger flap to be successfully carried over to the defect.

In this study the principles of free style flaps were successfully utilized to tailor flap designs according to; the site of the defect and the site of nearby perforators. In all of the cases we were able to find a sizeable perforator of the ulnar artery in the vicinity of the defect whether in the proximal, middle or distal part of the forearm, and a reliable local flap was used to provide adequate wound coverage.

Recommendation:

Ulnar based perforator flaps offer a reliable method for reconstruction in the forearm and proximal hand. They are suitable in the treatment of cases that have suffered extensive soft tissue loss second to firearm injuries. The flaps are thin, pliable, and robust. The skin is not hirsute. The scar is relatively inconspicuous as the ulnar aspect of the forearm is less exposed. It is also a one stage procedure and does not require the sacrifice of a main vessel.

REFERENCES

- 1- Penn-Barwell J.G., Brown K.V. and Fries C.A.: High velocity gunshot injuries to the extremities: Management on and off the battlefield. *Curr. Rev. Musculoskelet Med.* Sep., 8 (3): 312-7, 2015.
- 2- Sun C., Hou Z-D., Wang B. and Ding Z-H.: An Anatomical Study on the Characteristics of Cutaneous Branches-Chain Perforator Flap with Ulnar Artery Pedicle. *Plast. Reconstr. Surg.*, 131, 2013.
- 3- Mateev M.A., Ogawa R., Trunov L., Moldobaeva N. and Hyakusoku H.: Shape-Modified Radial Artery Perforator Flap Method: Analysis of 112 Cases. *Plast. Reconstr. Surg.*, 123: 1533, 2009.
- 4- Kimura N. and Saitoh M.: Free Microdissected Thin Groin Flap Design with an Extended Vascular Pedicle. *Plast. Reconstr. Surg.*, 117: 986, 2006.
- 5- Lee B.T., Lin S.J., Bar-Meir E.D., Borud L.J. and Upton J.: Pedicled Perforator Flaps: A New Principle in Reconstructive Surgery. *Plast. Reconstr. Surg.*, 125: 201, 2010.
- 6- Neligan P.C., Blondeel P.N., Morris S.F. and Hallock G.G.: Perforator Flaps: Overview, Classification, and

- Nomenclature. In: Neligan P.C., Blondeel P.N., Morris S.F., Hallock G.G., editors. *Perforator Flaps: Anatomy, Technique and Clinical Applications*. 1. second ed. St. Louis, Missouri: QMP, p. 53, 2013.
- 7- Saint-Cyr M., Mujadzic M., Wong C., Hatf D., Lajoie A.S. and Rohrich R.J.: The radial artery pedicle perforator flap: Vascular analysis and clinical implications. *Plast. Reconstr. Surg.*, 125: 1469-78, 2010.
- 8- Wei F-C. and Mardini S.: Free-style free flaps. *Plast. Reconstr. Surg.*, 114: 910-6, 2004.
- 9- Aydin H., Okçu O., Dural K. and Sakinci Ü.: Management of community-based shotgun injuries of the extremities: Impact of emergent vascular repair without angiography. *Turkish Journal of Trauma & Emergency Surgery*, 17 (2): 152-8, 2011.
- 10- Yu P., Chang E.I., Selber J.C. and Hanasono M.M.: Perforator Patterns of the Ulnar Artery Perforator Flap. *Plast. Reconstr. Surg.*, 129: 213, 2012.
- 11- Mathy J.A., Moaveni Z. and Tan S.T.: Perforator anatomy of the ulnar forearm fasciocutaneous flap. *J. Plast. Reconstr. Aesthet. Surg.*, 65: 1076-82, 2012.
- 12- Becker C. and Gilbert A.: The ulnar flap-Description and applications. *Eur. J. Plast. Surg.*, 11: 79-82, 1988.
- 13- Vergara-Amador E.: Anatomical Study of the Ulnar Dorsal Artery and Design of a New Retrograde Ulnar Dorsal Flap. *Plast. Reconstr. Surg.*, 121: 1716, 2008.