

## Evaluation of the Role of Lag Screw Technique in Internal Fixation of Mandibular Fractures: A Prospective Study

WESSAM S. WAHDAN, M.D.; HAMED M. KADRY, M.D. and AHMED T. ISMAIL, M.Sc.

*The Department of Plastic Surgery, Faculty of Medicine, Cairo University*

### ABSTRACT

Mandibular fractures are a common presentation in every emergency department. Many techniques of internal fixation have evolved over the years yet the search for the ideal technique is still on. By possessing the virtue of compression lag screw technique has shown a high degree of rigidity, absolute mechanical rest and stability that can withstand the mechanical load of the mandible during the early postoperative period. Lag screw also can help reducing the fracture gap which sets the perfect conditions for callus free primary bone healing.

*Aim of Work:* The aim of this study was to assess the role of lag screw technique in internal fixation of mandibular fractures, its advantages and its limitations.

*Patients and Methods:* A single arm prospective clinical study was conducted in the plastic surgery emergency department in Kasr Al Ainy Hospital over a period of 6 months (February 2015 to September 2015). The study included 20 patients suffering from mandibular fractures who were candidates for open reduction and internal fixation and had at least one fracture that was suitable for lag screw technique application.

*Results:* 24 fractures were fixed using the lag screw technique. Twenty three fractures showed evidence of inter-fragmentary distance reduction.

*Conclusion:* Lag screw technique has shown to be a valuable tool in internal fixation of fractures of mandible. It helped decreasing the fracture gap distance and offers a high degree of rigidity and stability that withstands the masticatory load with minimal hardware needed to complete the osteosynthesis when compared to other modalities for fixation. The high degree of rigidity it offered allowed for obviation of postoperative maxillo-mandibular fixation thus shortened the rehabilitation period.

**Key Words:** Fracture – Mandible – Lag – Screw- Fixation.

### INTRODUCTION

Mandibular fractures are a common presentation in the plastic traumatology department. It accounts for 36% to 59% of all maxillofacial fractures. Road traffic accidents, interpersonal assault, fall from height and sports related injuries are the lead causes

of mandibular fractures, with higher prevalence amongst male patients [1-5].

The primary objectives in management of mandibular fractures should include; union of fractured ends to restore proper function including the ability to masticate and articulation, reestablish pre-injury strength, and prevent infection at fracture site. To reach these outcomes adequate reduction, fixation, and immobilization of fractured segments should be part of the management plan. Different methods of fixation have evolved in maxillofacial surgery; wires, pins, staples, plates and screws. Each one of them offering a different degree of rigidity ranging from non-rigid fixation (e.g. wires), semi rigid fixation (e.g. miniplates), to rigid fixation (e.g. compression plates and lag screw technique) [6].

Lag screw fixation technique for mandibular fractures was first described by Brones and Boering in 1970 [7]. The technique consists of using screws to compress fractured segments without the aid of bone plates. In this form of osteosynthesis absolute interfragmentary stability is generated by screws that transfix the fracture gap. Though it is considered a form of load sharing technique, still it can achieve a high level of rigidity and stability that facilitates primary bone healing. As screws share the load with the bones, it is essential to have two sound bony cortices for optimal implication of the technique and it is unadvisable in cases where there is gross comminution or infection [8]. In 1976 Niederdellmann used lag screw as an essential supplement to osteosynthesis with mental plates [9].

Studies have shown that a properly placed lag screw can achieve between 2000 and 400 N of compressive force when tightening the screw. Meanwhile the compressive force that can be achieved by pre-bent compression plate is in the

order of 600 N [10]. Compression generated by lag screw acts within the fracture and results in even compression along the fracture line. This is in contrast to compression forces generated by pre-bent compression plates which are asymmetric, resulting in high compression adjacent to the plate and decreased compression in the far cortex of the fracture [8].

## PATIENTS AND METHODS

A single arm prospective clinical study was conducted in the plastic surgery emergency department in Kasr Al Ainy Hospital over a period of 6 months (February 2015 to September 2015). The study included 20 patients suffering from mandibular fractures who were candidates for open reduction and internal fixation and had at least one fracture that was suitable for lag screw technique application.

The patient selection was based on fulfillment of the criteria given below.

### *Inclusion criteria:*

- Patients above the age of 12 suffering from mandibular fracture which is indicated for open reduction and internal fixation.
- Displaced unfavorable fractures.
- Multiple fractures.
- Associated condylar fractures and midface fractures.
- When closed reduction (IMF) is not possible.

### *Exclusion criteria:*

- Patients below the age of 12 years.
- Grossly comminuted fractures.
- Presence of evidence of infection.
- Severely lacerated soft tissue risking implant exposure.
- Severely atrophic edentulous mandible.

After completing their trauma surveys and stabilization of their condition patients were further assessed & prepared for surgery in the form of: routine preoperative laboratory, third generation cephalosporin 1gm twice daily and Clindamycin 600mg every 8 hours, restricted oral feeding except for clear fluids and pain control. A signed detailed informed consent was taken and kept in their file.

All candidates underwent panoramic view radiographs and CT scan for facial bones including axial and coronal cuts with 3D reconstruction. Radiographs were repeated immediately postoperative and after 6 weeks.

All patients were operated upon within 3 to 5 days of the initial trauma under general anesthesia with nasal intubation and oral pack.

Maxillo-Mandibular fixation (MMF) was applied to maintain the occlusion during the procedure. An intra oral mandibular vestibular approach was used in all cases.

The first step was disimpacting the fractured segment and removing the fracture hematoma allowing for further proper reduction and clearing the site for adequate compression.

The lag screws used in this study were partially threaded titanium 2.0mm cortical screws. First the near cortex was prepared by drilling the gliding hole in it via a drill that is equal to the thread diameter of the screw (2.0mm). Then a centering guide is inserted in the gliding hole allowing for drilling of the far cortex via a drill bit equivalent to the core diameter of the screw (1.6mm). A depth gauge was inserted to measure the desired length of the screw followed by countersinking of the gliding hole allowing for proper setting of the screw head within the outer cortex. Finally the screw was tightened till the desired amount of compression was achieved. When tightening, the fractured segments were being brought closely to each other till they become impacted and the resistance is felt in the screwdriver. Further tightening by a few screwdriver rotations was done in order to achieve a state of compression and at the same time care was taken not to over tighten to avoid outer cortex microfractures by the screw head.

Two screws were inserted in a lag fashion. Yet in some cases where there was a risk of injury of root of the teeth, a lag screw was inserted on the tension border of the mandible first distributing the compression along the whole fracture line then a monocortical miniplate was used as a tension band. After completion of the osteosynthesis, the maxillo-mandibular fixation is released and double checked for stability and bite but keeping it in the postoperative period without occlusion.

All patients were discharged 24 hours after the operation on oral antimicrobial and mouthwash and pain control. They were instructed to follow a soft diet and avoid excessive chewing or loading on their jaws.

## RESULTS

A total number of 20 patients that suffered from mandibular fractures underwent open reduction & internal fixation. Their age ranged from 15-41 (average 24). All were males with the leading causes

of fractures being road traffic accidents (70%) followed by fall from height (15%), interpersonal assault (10%) & sports related injuries (5%).

The twenty patients that were included in this study had a total of 35 fractures. Out of those 35 fractures 24 fractures were fixed using the lag screw technique. Fractures couldn't be fixed by lag screws either due to technical difficulties in screw application in certain fractures or absence of sufficient amount of bone forming two cortices for technique implication. Table (1).

Table (1): Fractures fixed by lag screw technique.

Fracture Site	Total Number	No Lag screw technique fixation	Percentage of lag screw fixation
Symphseal	5	5	100
Parasymphseal	11	11	100
Anterior Body	3	3	100
Posterior Body	1	1	100
Angle	7	2	28.6
Ramus	2	1	50
Condyle	5	0	0
Lamellar	1	1	100
<b>Total</b>	<b>35</b>	<b>24</b>	<b>68.6</b>

As a rule all patients in this study were not subjected to maxillo-mandibular fixation (MMF) in the postoperative period due to the high degree of rigidity that the technique offers. In certain situations patients had to be put in MMF postoperatively. Three cases had associated subcondylar fracture that was treated conservatively, so MMF was not released after surgery. One case the MMF was left due to doubt in the occlusion adjustment and it was released in the first operative visit (8 days).

During the immediate postoperative radiographs assessment (panoramic view radiographs & CT

scans axial and coronal cuts), the interfragmentary distance between fractured segments across the fracture line was compared to the preoperative images. In our study the majority of cases fixed by lag screw (23 out 24 fractures, 95.83%) showed evidence of interfragmentary distance reduction and adequate compression except one case (4.17%). CT scans of that case revealed the complexity of the fracture didn't allow for proper compression along the inner cortex, though the outer cortex was properly reduced and approximated by the lag screws.

The 6<sup>th</sup> week post operative radiographs were compared to the immediate postoperative ones as regards bone healing. The shrinkage of the fracture line was taken as an evidence of bone healing and the presence or absence of callus was used to distinguish between primary and secondary bone healing. In the current study all patients showed evidence of callus free bone healing.

Complications encountered during the study were subdivided into 2 groups, complications related to the lag screw technique and general complications. In the first group only one complication was noticed in the first postoperative visit in the form of slight degree of malocclusion. Fortunately the arch bar was not removed and he was managed conservatively by putting the patient back in occlusion with the aid of guiding traction elastics. In the other group, the following general complications were face, lost tooth (1 case), wound dehiscence without hardware exposure as the dehisced segment was over the intra-osseous portion of the screw (1 case), wound infection treated by aspiration and antibiotic according to culture and sensitivity (1 case) and 2 cases of inferior alveolar nerve affection, one of them was avulsed during traction as the fracture involved the mental foramen and the other recovered completely after 6 weeks.

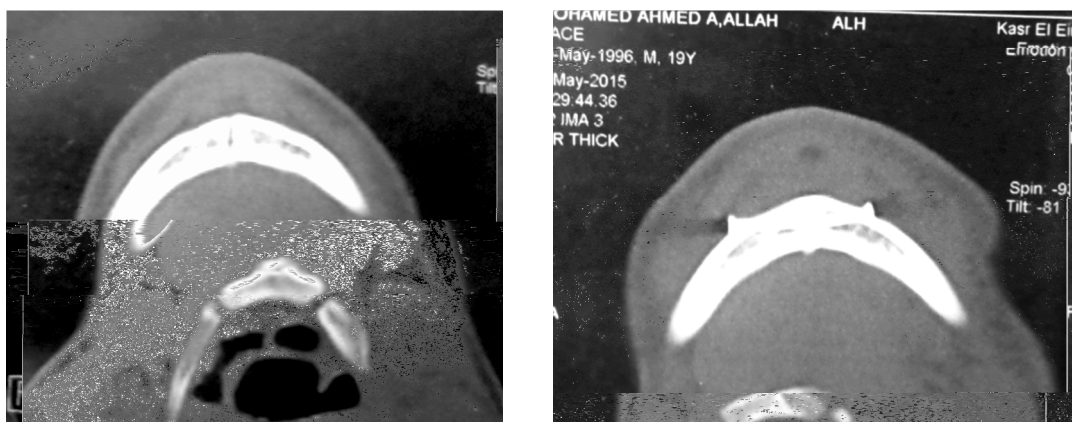


Fig. (1): Pre & Post-operative axial CT cuts of symphyseal fracture. Note the intimate contacts of fracture segments, and the perfectly placed perpendicularly lying lag screw.



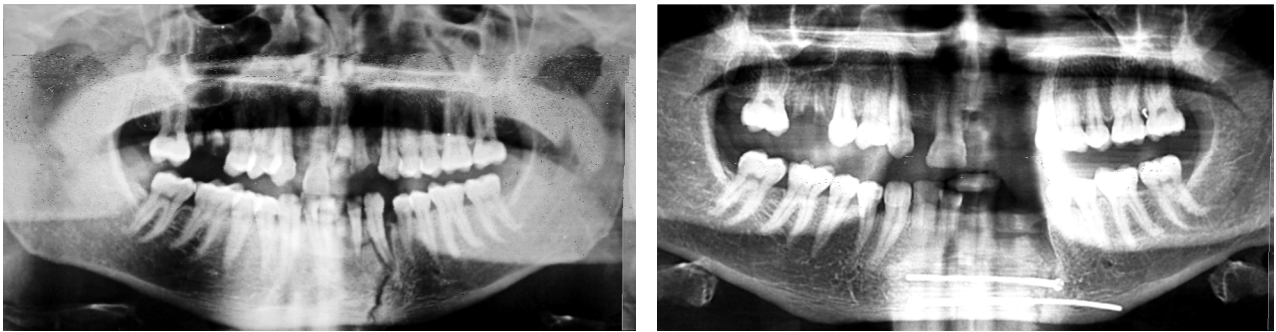


Fig. (2): Pre & Post-operative panoramic view of parasymphseal fracture.

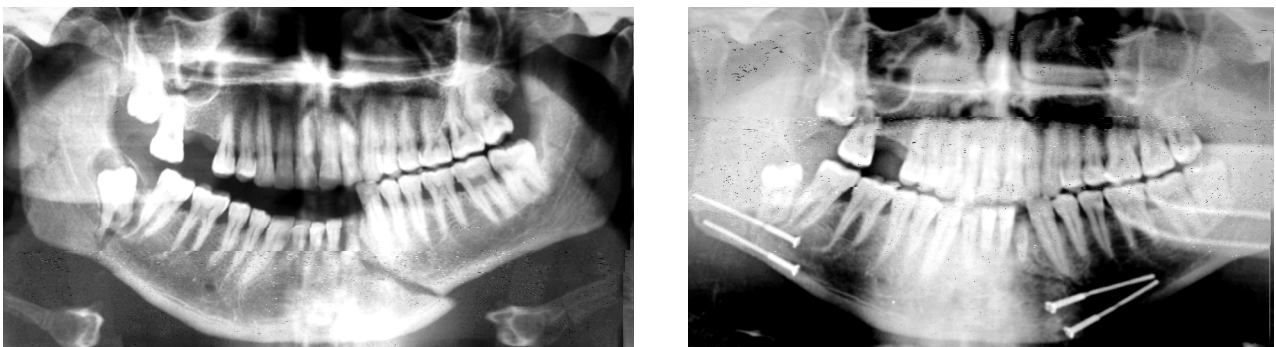


Fig. (3): Pre & Post-operative panoramic view of left parasymphseal fracture and right posterior body.

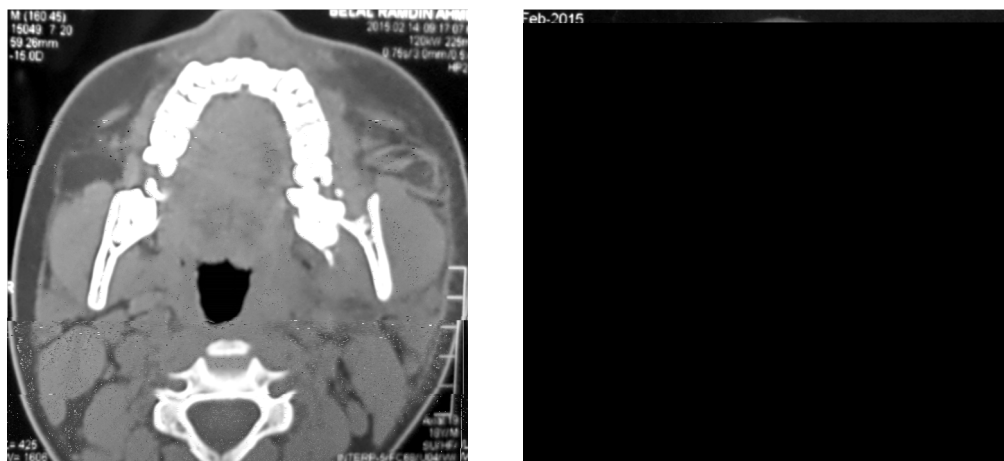

Fig. (4): Pre & Post operative axial CT cuts of fracture angle.

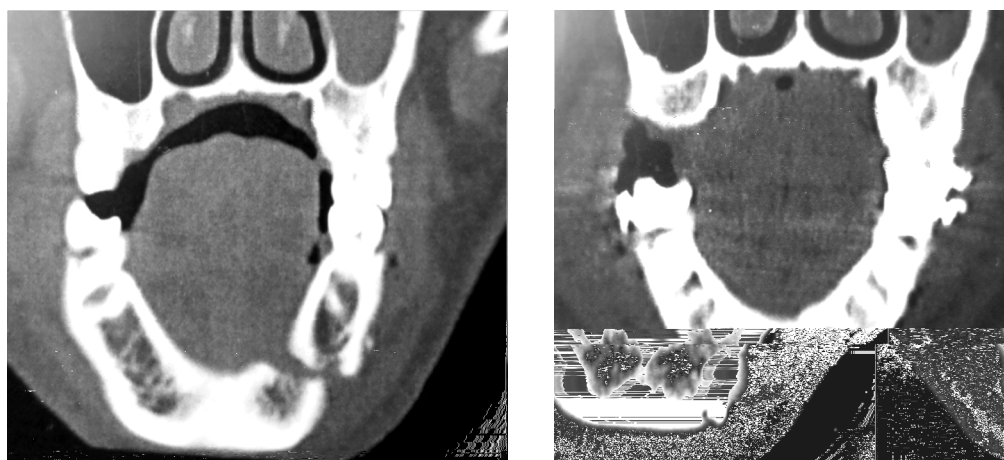

Fig. (5): Pre & Post-operative Coronal CT cuts of parasymphseal fracture.

## DISCUSSION

Mandibular fractures account for approximately two thirds of all facial fractures with a 70% incidence [11]. Adequate management of mandibular fracture is a must for safe rehabilitation and early return to daily activities without any limitations to the patient's life style or special masticatory habits [12].

The first attempts of open reduction of mandibular fracture dates to 1869. The development of plates and screw system in orthopedic surgery presented a promising tool for internal fixation of mandibular fractures [6]. In 1970, Brons and Boering utilized the concept of lag screw from orthopedic surgery and applied it to the mandible and relied on it as a stable form of internal fixation [7].

In the current study a total of 20 cases with mandibular fractures were managed at Kasr Al Ainy Plastic Surgery Emergency department. Out of a total of 35 fractures, 24 fractures at different sites of the mandible were successfully managed by the lag screw technique. With every fracture, the operators became more accustomed with the technical difficulties and challenges, gaining more knowledge and experience that helped venturing in more complex fractures.

One of the pearls of lag screws was the ability of the technique to reduce the fracture gap allowing for primary bone healing to take places which was put into test by multiple studies. Goyal et al., in 2012, compared the effect of lag screws (15 patients) on the fracture gap as compared to miniplate osteosynthesis fixation by 2.0 miniplates (15 patients) on anterior fractures. The results showed the mean post-operative radiographic distance between all measuring points were considerably more in cases of miniplate group [13].

In 2011 Schaaf et al., compared fracture gap in angle fracture when managed by lag screw against 1 miniplate and 2 miniplates. The study concluded that miniplate fixation resulted in a wider fracture gap especially in the region of the lower margin of mandible while lag screw fixation demonstrated a smaller fracture gap [14].

In the current study, 23 fractures showed decrease in their gap distance. While one fracture that wasn't obvious in the panoramic view images, yet the CT scans showed intimate contact of the outer cortices and the problem was in the inner cortex that maybe needed an additional lag screw in the perpendicular axis.

Another advantage of lag screw technique over other methods of fixation is the high degree of rigidity that it attains. A vitro study in 2011 focused on the mechanical behaviors of different fixation techniques including lag screw. In that study, single miniplate fixation showed the lowest peak load score while lag screw showed a higher resistance than 2 miniplates for all displacements [15]. In the current study, the high level of rigidity allowed that patients were not put in MMF in the postoperative period. The technique delivered adequate fixation that was rigid enough to withstand the masticatory stresses and patient's jaw mobility in 20 fractures when they were followed over a period of six weeks.

Anterior mandibular fractures (symphseal & parasymphseal) occupied the greater portion of this study (67%), fixed by the lag screw technique. The high proportion returned to several fractures. Firstly, the anterior location of the site made it easier for intraoral approach. Also the amount of bone present in the anterior region between the two mental foramina, gave enough freedom for drilling and designing a perfectly fitting holes in both cortices that allowed the screw application in lag fashion. The dense bone in that region also was sufficient enough to give good buttressing effect when the screw head compressed the segments against each others. On the other hand the dense bone in the region caused early fatigue of the drill bits and made them more prone to breakage. The other difficulty was when applying the lower screw and compressing it, this lead to widening of the fracture gap above in the tooth bearing region with disturbance of the bite. In order to overcome this issue, a special sequence was followed during fixation. First an interdental wire that encircled the fracture with teeth on both its sides (bridal wire) was applied then a modified towel bone holding forceps held the segments together at the level of the mental foramen. Now the lower lag screw can be inserted and tightening safely without fear of gapping above. Then the wire was tightened again and the bone forceps was released and the second lag screw was applied and tightened ensuring compression at the tooth bearing area.

Many studies were also performed evaluating the lag screw technique in the anterior mandible with similar results [9,13,16]. Most of failures or complications were results of operator judgment or technique [16]. Another study showed that the lag screw group showed faster improvement in term of biting efficiency as compared to miniplate

group which showed a tendency to masticate only medium hard food items by 24 weeks [13].

The other site that needs special attention is the angle region. Seven cases with fractures at the angle region were encountered in the current study. Lag screw was successfully applied in 2 out of the seven cases. The low proportion of lag screw application returns to the high technical demand needed to achieve perfectly inserted screw in lag fashion in the angle region without injury to the important structures underlying the bone in that region (inferior alveolar nerve in its canal and dental roots of the third molar). The tight space between these structures didn't allow for multiple attempts of drilling, so if any damage happened to the prepared hole (over drilling) lag screw application was aborted and another fixation alternative was used. In this study, angle fractures were managed with a solitary lag screw with a small incision extending posterior to the fracture over the anterior border of the ramus till the first molar. This technique was sufficient for exposure and gave enough space for lag screw application.

Those challenges were faced in other studies and multiple techniques and approaches were suggested to over them. Pavan et al., proposed a new technique that relies on a small limited external incision 2cm below the inferior border of the mandible from which fracture was managed. By the aid of a Kirshner wire, the fracture was reduced under X-ray image then used the K wire to determine the path of the screw. A cannulated 2.7mm lag screw was inserted and then removed the K wire [17]. Schaaf et al., used an intraoral access, like the one used in the current study, but added a 4mm extra oral stab incision at the inferior border of the mandible to aid in cortices preparation for screw insertion [18]. A solitary lag screw in the angle region proved to withstand the the functional loading of the mandible in that region [19]. Both patients in the current study showed good primary stability with a single screw in the angle region and significant reduction in the in the fracture gap distance.

Four fractures of mandibular body were successfully managed using the lag screw technique (3 in anterior body region and 1 in posterior region). In those fractures it wasn't the dense bone in the region as in symphyseal fractures or the difficulty in exposure and manipulation as in angle fracture that presented a challenge but rather the structure of the body of the mandible itself. The horizontally lying body from the mental foramen till the angle in a straight manner made it difficult for proper

screw placement. It was impossible to insert a perfectly placed screw in lag fashion that was perpendicular to the fracture line when the fracture lies completely in the coronal plane. The only way to manipulate such fractures by lag screws was when the fractures were angulated towards the sagittal plane. If the application of the lag screw was intended and the fracture's ends didn't allow for proper placement, overriding of the fractured segments was inevitable when the screw was tightened as it would approach two non corresponding points across the fracture line. This was in harmony with the study that concluded that fixation of mandibular body fracture with lag screw technique was reliable when there was sufficient obliquity of the fracture [20].

During the course of the study several advantages of the technique that weren't measured in the outcomes were noticed. One of those advantages was the minimal exposure the technique implementation required for adequate fixation. In the beginning, long incisions (similar to the ones used in miniplates) were used then it was realized that there is no need for such long incisions and shorter ones were used. Another parameter noted was the time of procedures. The time of the procedures was not taken into account within the measured outcome yet it was noted when the lag screw technique was used the procedure took less than expected. The minimal amount of hardware needed to stabilize the fracture was another advantage.

The limitations and drawbacks of lag screw technique application that were encountered during this study all returned to the difficulty and high technical demand needed to complete the osteosynthesis. The technique is very sensitive and deviation from the principles may lead to undesirable outcomes. Comprehensive understanding of different zones of the mandible regarding their different bone densities and underlying important structures adds to the amount of experience and knowledge essential for successful application.

## REFERENCES

- 1- Brook I.M. and Wood N.: Aetiology and incidence of facial fractures in adults. *Int. J. Oral Surg.*, 12 (5): 293-8, 1983.
- 2- Eliss E. 3<sup>rd</sup>, Moos K.F. and El-Attar A.: Ten years of mandibular fractures:an analysis of 2137 cases. *Oral Surg. Oral Med. Oral Pathol.*, 59 (2): 120-9, 1985.
- 3- Van Hoof R.F., Merckx C.A. and Stekelenburg E.C.: The different patterns of fractures of the facial skeleton in four European countries. *Int. J. Oral Surg.*, 6 (1): 3-11, 1977.



- 4- Alexander J. Sojat, Tina Meisami, George K.B. and Sandor Cameron M.L. Clokie: The Epidemiology of Mandibular Fractures Treated at the Toronto General Hospital: A Review of 246 cases. *Journal of the Canadian Dental Association*, 67 (11): 640-644, 2001.
- 5- Hassouna M.W., Nor ELdin A.A., Kenawy A.M. and Abo Rady AF.: Cranio-maxillofacial trauma patients in Cairo University Hospital: A 6 months review. Kasr Al Ainy Faculty of Medicine thesis for Master degree, 2013.
- 6- Miloro, Michael and Larry J. Peterson: Peterson's principles of oral and maxillofacial surgery. Shelton, CT: People's Medical Pub. House-USA, 2012. Print.
- 7- Brons R. and Boering G.: Fractures of mandibular body treated by stable internal fixation-a preliminary report. *J. Oral Maxillofac. Surg.*, 28: 407-415, 1970.
- 8- Muller, Maurice E., et al.: Manual of internal fixation techniques recommended by the AO-ASIF Group. Berlin, Heidelberg: Springer Berlin Heidelberg, 1991.
- 9- Niederdelmann H., Schili W., Duker J., et al.: Osteosynthesis of mandibular fracture using lag screws. *Int. J. Oral Surg.*, 5: 117-121, 1976.
- 10- Brennwald J., Mutter P., Von Arx C., Cordey J. and Perren S.M.: Preoperative measurement of the torque at the bone-screw. *Unfallmed Berufsher*, 3: 123-126, 1975.
- 11- Malik Neelima A.: Text book of oral and maxillofacial surgery. New Delhi: Jaypee, 2008.
- 12- Haribhakti V.V.: The dentate adult human mandible: An anatomic basis for surgical decision making: *Plast. Reconstr. Surg.* Mar., 97 (3): 536-41, Discussion 542-3, 1996.
- 13- Goyal M., Jhamb A., Chawla S., Marya K., Duas J.S. and Yadav S.: A comparative evaluation of fixation techniques in anterior mandibular fractures using 2.0mm monocortical Titanium miniplates versus 2.4mm cortical Titanium lag screw. *J. Maxillofac. Oral Surg.*, 442-50, 2012.
- 14- Schaaf H., Kaubruegge S., Streckbein P., Willbrand J.F., Kerkmann H. and Howaldt H.P.: Comparison of miniplate versus lag-screw osteosynthesis for fractures of the mandibular angle. *Oral Surg. Oral Med. Oral Pathol. Oral Radiol.*, Jan., 111 (1): 34-40, 2011.
- 15- Vieira eOliveira T.R. and Passeri L.A.: Mechanical evaluation of different techniques for symphysis fracture fixation – an in vitro polyurethane mandible study, *J. Oral Maxillofac. Surg.* Jun., 69 (6): 141-6, 2011.
- 16- Tiwana P.S., Kushner G.M. and Alpert B.: Lag screw fixation of anterior mandibular fractures: A retrospective analysis of intraoperative and postoperative complications. *Oral Surg. Oral Med. Oral Pathol. Oral Radiol.* June, 65 (6): 1180-1185, 2007.
- 17- Pavan K., Nisheet A., Asawari M., Sunil ,Shrikant S., Percutaneous Approach for Mandibular Angle fracture using Lag Screw, *WIMJOURNAL*, 48-53, 2014.
- 18- Sasikala B., Kurmaravelu C., Elavenil P. and Kirshnakumar VB.: Solitary lag screw fixation for mandibular angle fracture: Prospective study, *SRM Journal*, 5 (3): 180-185, 2014.
- 19- Chrcanovic B.R.: Fixation of mandibular angle fractures: In vitro biomechanical assessments and computer based studies, *Oral Maxillofac. Surg.* Dec., 17 (4): 251-68, 2013.
- 20- Ellis 3<sup>rd</sup>: Use of lag screws for fractures of mandibular body. *J. Oral Maxillofac. Surg.* Nov., 54 (11): 1314-6, 1996.