

Submandibular Duct Rerouting as a Lay Way for Saliva Control

YASSER EL-SHEIKH, M.D.*; SHERIF ELKASHTY, M.D.* and
ABDELMEGID HELMY ELFAKHARANY, M.D.**

The Department of Plastic & Reconstructive Surgery, Faculty of Medicine, Menoufia University* and
the Department of Oral Surgery, Faculty of Dentistry, Al-Azhar University***

ABSTRACT

Background: Saliva problems may arise even with normal saliva production either due to obstruction of salivary gland ducts or failure to swallow saliva after its production, which is known as sialorrhea. Sialorrhea is the unintentional loss of saliva from the mouth. Sialorrhea has negative social and physical impact on the affected patients. There are many surgical options for treatment of sialorrhea. Bilateral submandibular duct rerouting into the oropharynx with sublingual glands excision presents an effective and safe technique for management of this problem. Submandibular duct relocation into the posterior floor of mouth is an effective and safe solution for pathologic or iatrogenic obstruction of the submandibular ducts.

Purpose: The objective of this article is to evaluate the effectiveness and safety of submandibular duct manipulation either by rerouting or relocation in management of sialorrhea or pathologic/iatrogenic obstruction of the submandibular ducts.

Patients and Methods: Seven patients were included in this study in the period from February 2011 to September 2013. There were four patients suffering from sialorrhea due to neuromuscular incoordination and three patients suffering from pathologic and iatrogenic obstruction of the submandibular ducts. Submandibular duct rerouting into the oropharynx with sublingual glands excision was done to control sialorrhea, and submandibular duct relocation into the posterior floor of mouth was done primarily for pathologic and secondarily for iatrogenic obstruction to alleviate duct obstruction. The patients were followed-up for 18 months.

Results: The seven patients were evaluated as regards the subjective improvement in their symptoms and the occurrence of complications. The sialorrhea level markedly improved after the submandibular duct rerouting into the oropharynx. The three patients with obstructive symptoms as pain, swelling and recurrent sialadenitis had their symptoms relieved after the obstructed duct was relocated into the posterior floor of mouth. There were no complications as ranula formation, lingual nerve injury, submandibular sialadenitis or respiratory complications.

Conclusion: The surgical manipulation of the submandibular duct either by duct rerouting into the oropharynx or duct relocation into the posterior floor of mouth is considered effective and safe lay way for saliva control.

INTRODUCTION

In the normal state, approximately 1.5 to 2 L of saliva is produced in a 24-hour period, with the submandibular and sublingual glands possessing a higher resting flow rate than the parotid glands. Even with normal saliva production, salivary problems may however arise from either blockage of the gland duct or failure of swallowing saliva after its production which is known as sialorrhea. Surgical manipulation of the submandibular duct can be deployed safely and effectively to control these saliva problems.

Sialorrhea is the unintentional loss of saliva from the mouth. The condition is not due to excessive production of saliva, but rather is secondary to poor swallowing function resulting from neurological control of the oropharyngeal muscles. Sialorrhea is seen most commonly in patients with cerebral palsy but can affect any number of patients with conditions affecting the neurologic or muscular systems. Chronic drooling has a negative impact on the patients' social relations and adds to the burden of patient care [1,2].

Anticholinergic drugs such as atropine can control drooling but are not appropriate for long-term use because the high doses needed cause unacceptable side effects such as urine retention and constipation. Surgical options for treatment of sialorrhea include parotid duct ligation or rerouting, submandibular gland excision, submandibular duct rerouting or ligation, sublingual gland excision, and division of parasympathetic nerve supply to the glands. Each surgical procedure has its proponents based primarily on subjective impressions of surgical outcome [3-8].

Because most spilled saliva is produced by the submandibular glands, many surgical options for

controlling sialorrhea involve disruption or rerouting of the submandibular gland output. Approximately 1.5 to 2 L of saliva per day is produced in the oral cavity and oropharynx. In the non stimulated state, nearly 80% of salivary flow is produced by the submandibular and sublingual glands, 10% to 15% is produced by the parotid glands, and the remaining 5% to 10% is produced by the minor salivary glands. The amount of saliva, the constant nature of its production, and the location of duct orifices all make the submandibular glands the most critical to address surgically when attempting to control sialorrhea [9,10].

Pathologic obstruction or iatrogenic obstruction of one or both submandibular ducts following surgery of the anterior floor of mouth can lead to obstructive sialadenitis, with glandular swelling and degeneration. Stimson and Leban overcame this problem by surgical translocation of the duct orifice into the posterior mouth floor away from the previous surgical intervention [11].

The purpose of this study is to evaluate the effectiveness and safety of surgical manipulation of the submandibular duct by either rerouting into the oropharynx or relocation into the posterior floor of mouth in management of sialorrhea and duct obstruction respectively.

PATIENTS AND METHODS

This study was done at The Department of Plastic and Reconstructive Surgery, Menoufia University Hospitals. It was done in the period from February 2011 to September 2013, with a follow-up period of an average of 18 months. Surgical manipulation of the submandibular duct was done in the form of either rerouting or relocation to manage two groups of patients with saliva problems. The first group included four patients who had sialorrhea due to neuromuscular incoordination and the second group included three patients who had pathologic/iatrogenic obstruction to the submandibular duct.

Patient characteristics of both groups were shown in Tables (1,2).

Table (1): Characteristics of patients with sialorrhea.

Patient No	Gender	Age	Severity of sialorrhea	Cerebral palsy	Mental retardation
1	M	25 y	Mild	No	No
2	M	17 y	Moderate	No	No
3	M	48 y	Sever	No	No
4	F	27 y	Moderate	No	No

Table (2): Characteristics of patients with pathologic/iatrogenic obstruction of the submandibular duct.

Management	Aetiology	Age	Gender	Patient No
Excision of lesion with primary relocation of the duct opposite 1 st molar	Pathologic / sarcoidosis of Lt duct orifice	35 y	F	1
Secondary relocation of both ducts opposite 1 st premolar	Iatrogenic/after excision of Torus Mandibularis /both ducts	29 y	F	2
Secondary relocation of Lt duct opposite 2 nd premolar	Iatrogenic/after submental intubation/ Lt duct	22 y	M	3

The level of sialorrhea was gauged as mild, moderate, or sever based on the patient description of the number of small towels wetted per day (1-2 towels was mild, 3-4 was moderate, and more than 5 towels was sever) and how often the patient required his mouth to be wiped to stay dry.

Preoperative Dental preparation was done by doing the following:

- Removal of subgingival calculus.
- Treatment of periodontal infections.
- Treatment of soft dental decay.

Surgical Technique of duct rerouting:

The operation was done under general anesthesia administered through nasotracheal tube. Preoperative antibiotics were given prophylactically to cover oral flora and continued for 7 days after surgery. Patients were placed supine and sterily draped. The oral cavity was sterilized and a throat pack was placed. The tongue was retracted out of the field of dissection by a tongue retractor.

The orifices of the submandibular ducts were identified. The mucosa surrounding the duct orifices was infiltrated with 1 to 2mL of 1:200,000 epinephrine for the purpose of hemostasis. An island (cuff) of mucosa about 2 to 3mm was incised surrounding each duct orifice. The ducts were identified and skeletonized off their surrounding tissue by sharp dissection without cannulation. The ductules of the sublingual glands entering the submandibular ducts were transected and the sublingual glands were excised (Fig. 1). The lingual nerve was identified, protected, and preserved. The submandibular ducts were dissected for approximately 3 to 4cm until the submandibular gland was identified (Fig. 2).

A submucosal tunnel was developed by blunt dissection using a hemostat starting at the most posterolateral aspect of the mucosal incision, directed posteriorly toward the anterior tonsillar pillar. The exit site of the tunnel was created at the posterior aspect of the anterior tonsillar pillar (Fig. 3). The submandibular duct was then passed through the tunnel (without acute angulation between the duct and the gland to avoid kinking and obstruction) with a 4-0 silk suture secured to the mucosal island. The mucosal island was secured to the anterior tonsillar pillar by one or two 4-0 vicryle stitches. The donor site of the mucosal island was left to heal by secondary intention.

Surgical technique of duct relocation:

Basically this technique was used to relocate the submandibular duct either primarily in the patient with sarcodosis of duct orifice (Fig. 4) or secondarily in the patients with iatrogenic duct obstruction. The preparatory steps were basically the same as in the above technique. The affected duct orifice(s) was/were excised in an oblique fashion (about 45 degrees to widen the cross sectional area) and the remaining duct(s) was/were dissected posteriorly for a suitable length (Figs. 5,6) and reimplanted into a more posterior position into a newly created opening in the floor of the mouth opposite the premolars or the molars according to the duct remaining length (Fig. 7). The duct orifice was secured by vicryle 4-0 four stitches to the new mucosal opening.

RESULTS

Patients were seen after surgery at 4 weeks, 8 weeks, and then every 3 months during the follow-up period. The postoperative results were evaluated as regards the subjective improvement of sialorrhea in the first group and the subjective improvement

of obstructive symptoms in the second group and the occurrence of complications in both groups.

Subjectively, the drooling was evaluated at rest and at mealtimes. In each situation, control of drooling was classified as excellent, good, fair, and or poor (Table 3).

The results of the four patients with sialorrhea were summarized in (Table 4).

Subjectively, the patients of the pathologic/iatrogenic obstruction of the submandibular ducts became totally free of the pain, swelling and recurrent sialadenitis after relief of obstruction by relocation of the submandibular duct(s).

In terms of complications, no ranulae had occurred postoperatively. There was transient mild swelling in the floor of the mouth that resolved spontaneously in 2 to 5 days. There were no postoperative infections of the submandibular glands. There was no injury to the lingual nerve. No patients had an increased incidence of respiratory complications during the follow-up period.

Table (3): Classification of surgical outcome.

Classification	Description
Excellent	Normal salivary control
Good	Occasional salivary control
Fair	Improved but still drooling
Poor	Failure of salivary control

Table (4): Results of subjective evaluation in each case.

Patients	Control of drooling	
	Resting	Mealtimes
1	Excellent	Excellent
2	Excellent	Excellent
3	Excellent	Good
4	Excellent	Excellent




Fig. (1): Bilateral excision of sublingual glands to both decrease saliva production and avoid development of postoperative ranulae.



Fig. (2): The duct with surrounding mucosal cuff was completely dissected down to its junction with gland.

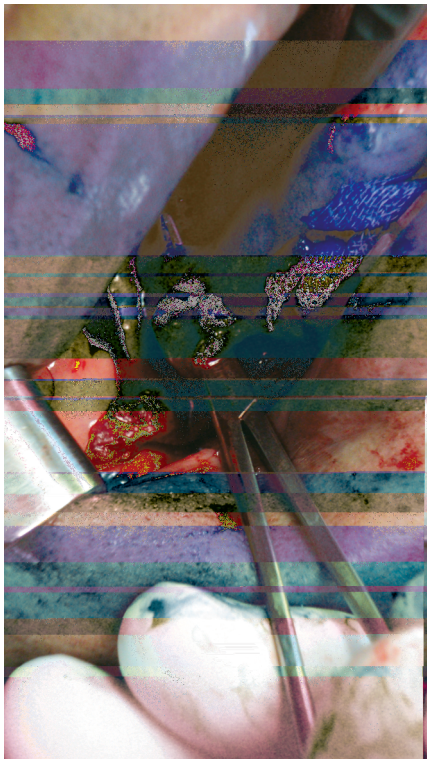


Fig. (3): Tunneling by a hemostate into the anterior tonsillar pillar behind platoglossus muscle.




Fig. (4): Preoperative photo showing a mass obstructing Lt duct which was dilated.

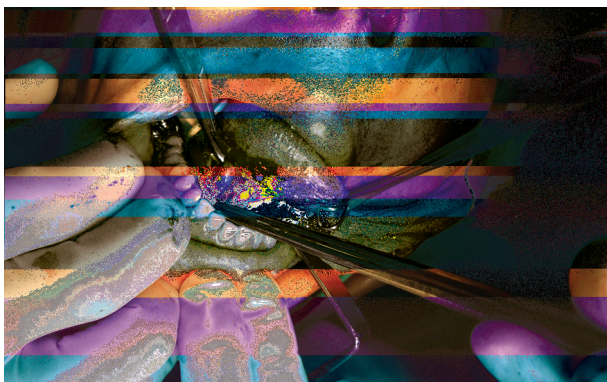


Fig. (5): Dilated obstructed Rt duct was sharply dissected off surrounding tissue in case of tarsus mandibularis.



Fig. (6): Lt duct dissected with tumor like mass (sarcoidosis) encircling the duct orifice.

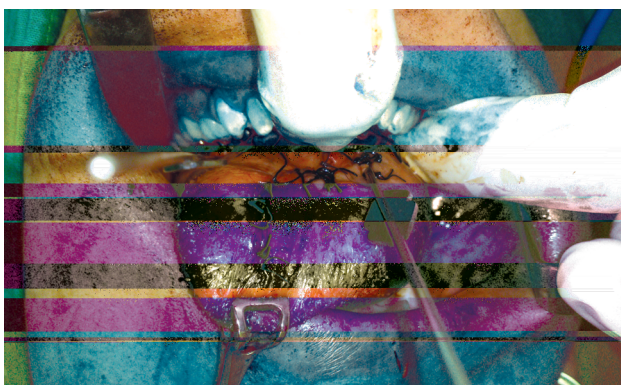


Fig. (7): Both duct orifices were relocated in the posterior floor of mouth opposite 1st molars with z plasty of tongue frenulum in tarsus mandibularis.

DISCUSSION

The salivary glands produce about 1.5 to 2 L saliva per day. Even with normal saliva production, saliva problems may arise from blockage of the gland ducts or failure of swallowing of saliva after its production which is known as sialorrhea.

Many different surgical options exist for the treatment of sialorrhea. By virtue of the difficulty in standardizing preoperative and postoperative levels of sialorrhea, surgical outcome data can be difficult to compare from one surgical procedure to another. However, most authors report their outcomes after performing a single procedure on all patients with sialorrhea.

Submandibular gland excision with rerouting of the parotid ducts, the Wilkie procedure, has a reported excellent to good control of sialorrhea in approximately 89% of patients [5].

Submandibular gland excision and parotid duct ligation has an excellent surgical outcome of nearly 100% good response [3]. However, this surgical option carries an increased risk of xerostomia and entails external incisions [12].

Relative to the risks, submandibular duct rerouting remains an excellent choice of therapy with the advantages of technical ease, shorter operative time, lack of external operative scars, and relatively uncommon significant risks. The most common complication of the submandibular duct rerouting surgery is ranula formation from the transected ductules of the sublingual gland. We avoided this complication by excising the sublingual glands in our sialorrhea patients.

The increased risk of lingual nerve injury due to its proximity in the surgical field is avoided by nerve identification, guarding, and protection throughout the procedure. Theoretically, the increased salivary flow to oropharynx may cause salivary contamination of the respiratory tree, however in practice, no patients in our study noticed an increase in the number of pulmonary infections after the rerouting.

Submandibular duct rerouting alone was reported by Cotton and Richardson in 1981 to had a 96% success rate in 25 patients [13]. Similarly, we had a high success rate in our four sialorrhea patients.

In the second group of patients with pathologic/iatrogenic submandibular duct obstruction, there were secondary pain and swelling with recurrent sialadenitis. To effectively alleviate these obstructive symptoms, the dilated duct(s) was (were) dissected, with excision of the obstructed fibrosed orifice in a diagonal manner (about 45 degrees) and re-implanting the new wide orifice in the posterior floor of mouth mostly opposite the 1st premolar or 1st molar, away from the previous surgical field. Doing so, this limited the circumferential scarring of the new orifice and avoided recurrence of the duct stenosis with relief of the obstructive symptoms.

In conclusion, submandibular duct manipulation either by duct rerouting into the oropharynx for management of sialorrhea or duct relocation into the posterior floor of mouth for management of pathologic/iatrogenic duct obstruction is safe, effective and versatile lay way for saliva control.

REFERENCES

- 1- Blasco P.A. and Allaire J.H.: Drooling in the developmentally disabled: Management practices and recommendations. *Dev. Med. Child Neurol.*, 34: 849, 1992.
- 2- Harris S.R. and Purdy A.H.: Drooling and its management in cerebral palsy. *Dev. Med. Child Neurol.*, 29: 807, 1987.
- 3- Glass L.W., Nobel G.L. and Vecchione T.R.: Treatment of uncontrolled drooling by bilateral excision of submaxillary glands and parotid duct ligations. *Plast. Reconstr. Surg.*, 62: 523, 1978.
- 4- Crysdale W.S. and White A.: Submandibular duct relocation for drooling: A 10-year experience with 194 patients. *Otolaryngol. Head Neck Surg.*, 101: 87, 1989.
- 5- Wilkie T.F. and Brody G.S.: The surgical treatment of drooling, a ten-year review. *Plast. Reconstr. Surg.*, 59: 791, 1977.
- 6- Arnold H.G. and Gross C.W.: Transtympanic neuroectomy: a solution to drooling problems. *Dev. Med. Child. Neurol.*, 19: 509, 1977.
- 7- Frederick F.J. and Stewart I.F.: Effectiveness of transtympanic neuroectomy in management of sialorrhea occurring in mentally retarded patients. *J. Otolaryngol.*, 11: 289, 1982.
- 8- Mullins W.M., Gross C.W. and Moore J.M.: Long-term follow-up of transtympanic for sialorrhea. *Laryngoscope*, 89: 1219, 1979.
- 9- Stuchell R.N. and Mandel I.D.: Salivary gland dysfunction and swallowing disorders. *Otolaryngol. Clin. North. Am.*, 21: 649, 1988.
- 10- Bailey C.M. and Wadsworth P.V.: Treatment of the drooling child by submandibular duct transposition. *J. Laryngol. Otol.*, 99: 111, 1985.
- 11- Stimson C.W. and Leban S.G.: Transplantation of the submandibular duct associated with resection for carcinoma. *Oral. Surg. Oral. Med. Oral. Pathol.*, 56: 136, 1983.
- 12- Shott S.R., Myer C.M. and Cotton R.T.: Surgical management of sialorrhea. *Otolaryngol. Head Neck Surg.*, 101: 47, 1989.
- 13- Cotton R.T. and Richardson M.A.: The effect of submandibular duct rerouting in the treatment of sialorrhea in children. *Otolaryngol. Head Neck Surg.*, 89: 535, 1981.