

Functional and Aesthetic Evaluation of Abbe-Sabattini Cross Lip Flap for Reconstruction of Lower Lip Defects after Squamous Cell Carcinoma Excision

WALEED S. ALDABAANY, M.D.; AMR ELNAGARY, M.D. and SHREIF MAHER, M.D.

The Department of Plastic Surgery, Faculty of Medicine, Fayoum University, Fayoum, Egypt

ABSTRACT

Background: Defects larger than one half of the lip cannot be closed primarily; therefore, tissue transfer is necessary. The recommended surgical techniques for these defects are Cross lip flaps which include Abbe-Sabatini and Estlander flaps.

Patients and Methods: Ten patients with squamous cell carcinoma at lower lip not reaching angle of mouth excised with safety margin ranging from 0.5cm to 1cm in each side and the excision not including angle of mouth. The size of the defects in all patients after excision of the tumour was ranging from 1/2 to 2/3 the size of the lower lip. Reconstruction was done in all patients using Abbe-Sabatini cross lip flap and separation of the flap was done after three weeks.

Results: The mean age of the patients was 56.5 years (ranging from 47-70 years). Seven patients were males and three patients were females. In all patients the flaps were survived completely. We evaluate the Abbe-Sabatini cross lip flap regarding the functional and aesthetic aspects. Abbe-Sabatini cross lip flap had a good functional outcome regarding Oral continence to food, fluids, and air and Oral mobility and adequate oral access. In seven patients the sensations were gained completely within six months, but in the remaining three patients there were slight hypoesthesia after one year. We found also that Abbe-Sabatini cross lip flap had a good aesthetic outcome.

Conclusion: Abbe-Sabatini cross lip flap is an ideal versatile flap to reconstruct the defects of lower lip ranging from 1/2 to 2/3 of the size of the lower lip not including angle of the mouth with very good functional and aesthetic outcome.

INTRODUCTION

Defects larger than one half of the lip cannot be closed primarily without undue wound tension. Strategies for closure involve borrowing tissue either from the opposite lip or from the cheek. Tissue borrowing from the opposing lip was first described by Sabattini in 1838, and is commonly known as the Abbe cross lip flap (Fig. 1).

The flap width should be approximately one half of the width of the excised tissue. This width

will reduce the size of both upper and lower lip by the same amount.

Two centimeters is the maximum recommended width size of the flap, which is pedicled on the labial artery. The pedicle is divided 10 to 21 days later [1].

The Estlander flap is similar to the Abbe flap, but involves rotating the upper lip tissue around the lateral edge of the mouth (Fig. 2). It is best used in situations where the defect involves the oral commissure, so that the flap not only repairs the lower lip defect, but is the first step in commissure reconstruction [2].

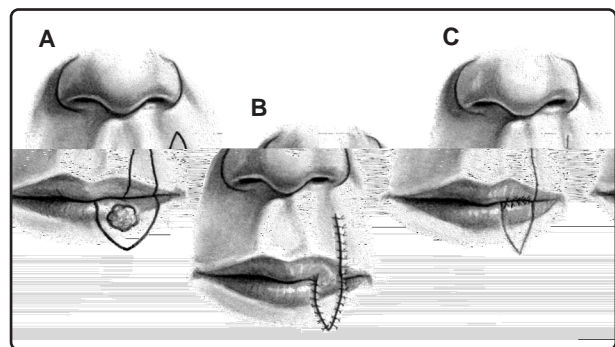


Fig. (1): Abbe-Sabatini cross lip flap [3].

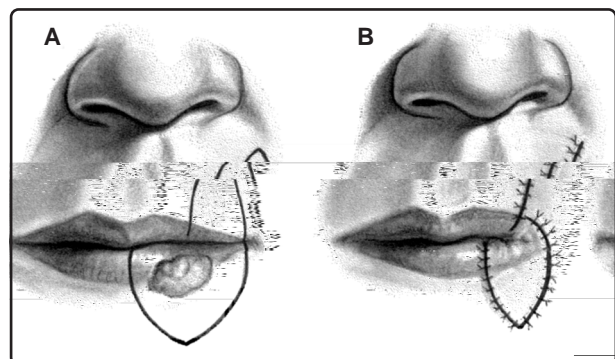


Fig. (2): Estlander flap [3].

PATIENTS AND METHODS

Ten patients with squamous cell carcinoma at lower lip not reaching angle of mouth excised with safety margin ranging from 0.5cm to 1cm in each side and the excision not including angle of mouth.

Lip shaving was added in addition in one patient with superficial S.C.C. at the rest of the vermillion.

Supraomohyoid block neck dissection was done in six patients.

The size of the defects in all patients after excision of the tumour was ranging from 1/2 to 2/3 the size of the lower lip.

Reconstruction was done in all patients using Abbe-Sabattini cross lip flap and separation of the flap was done after three weeks.

In all patients preoperative incisional biopsy was done to prove the diagnosis. C.T. scan neck, chest and abdomen were done to exclude metastasis.

Surgical technique:

V shaped excision of the ulcer with safety margin ranging from 0.5cm to 1cm in each side.

Marking of the Abbe-Sabattini cross lip flap (V shaped with the base of the triangle extending medially from angle of mouth to be equal the half of the width of the defect).

The lateral border of the triangle was incised first including skin, muscles, and mucosa with determination of the level of the superior labial artery just below the mucosa of the vermillion.

The medial border of the triangle was then incised including skin, muscles, and mucosa to the level of the superior labial artery just below the mucosa of the vermillion.

The flap was then rotated based on superior labial artery to be sutured into the defect in layers.

The donor site was closed also in layers.

The flap pedicle was divided after 3 weeks.

Follow-up of patients for at least one year postoperative.

RESULTS

The mean age of the patients was 56.5 years (ranging from 47-70 years). Seven patients were males and three patients were females.

The size of the defects in all patients was ranging from 1/2 to 2/3 the size of the lower lip.

In all patients the flaps were survived completely.

We evaluate the Abbe-Sabattini cross lip flap regarding the functional and aesthetic aspects.

A- Functional considerations:

- Oral continence to food, fluids, and air:

Good in all patients.

- Oral mobility (evaluated by sounds formations and facial expressions):

Good in all patients.

- Adequate oral access (evaluated by size of mouth):

In all patients there were no microstomia with an adequate oral access.

- Preservation of sensation:

In seven patients the sensations were gained completely within six months, but in the remaining three patients there were slight hyposthesia after one year.

B- Aesthetic considerations:

- Symmetry and normal anatomic proportions:

In all patients the angles of the mouth were symmetrical with preservation of the normal anatomic proportions of the lip.

- Normal shape and position of philtrum:

Good in all patients.

- Establishment of a vermillion-cutaneous white border:

The vermillion-cutaneous white border were reconstructed and established in all patients.

DISCUSSION

The lips have important functional and aesthetic roles in daily living. They are the focal point of the lower face, with several aesthetic units intricately controlled by a complex series of muscles. Several key factors make reconstruction of the lip especially challenging [4].

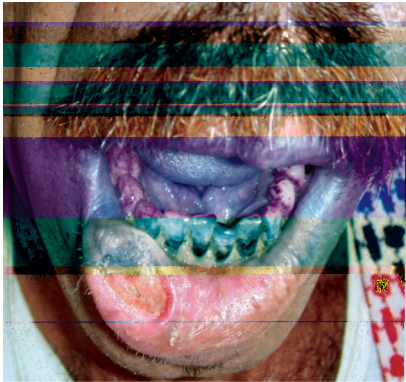

Fig. (3-A): Preoperative picture of SCC of lower lip.

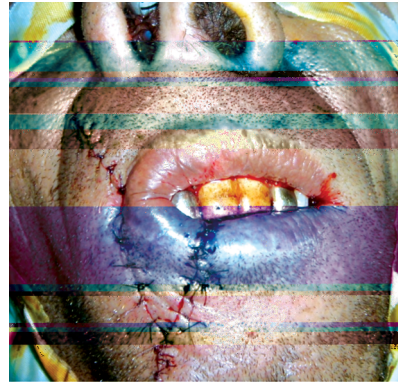


Fig. (3-B): Intraoperative picture of Abbe-Sabatini flap.

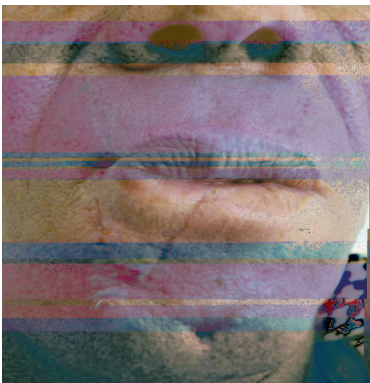

Fig. (3-C): Postoperative picture of Abbe-Sabatini flap before separation.

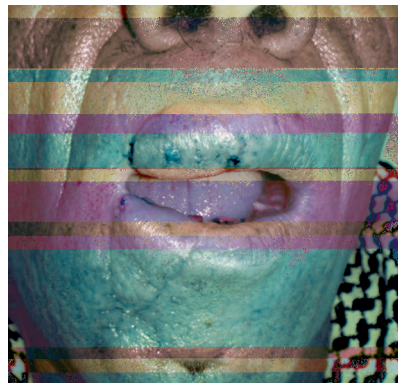

Fig. (3-D): Postoperative picture of Abbe-Sabatini flap after separation.

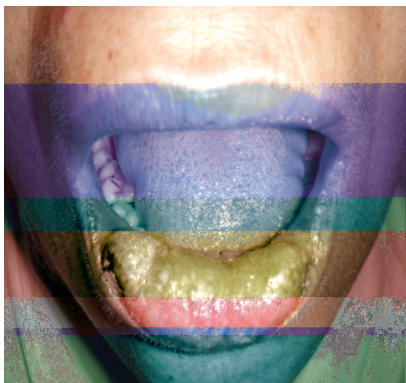

Fig. (4-A): Preoperative picture of SCC of lower lip.

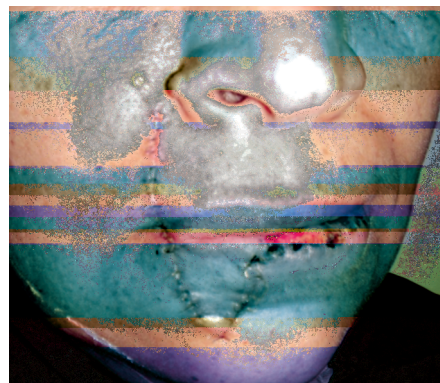

Fig. (4-B): Postoperative picture of Abbe-Sabatini flap and lip shaving before separation.



Fig. (4-C): Postoperative picture of Abbe-Sabatini flap after separation.



Fig. (4-D): Postoperative picture of Abbe-Sabatini flap after separation.

Lip reconstruction is driven by restoration or preservation of function and aesthetics.

Functional considerations include oral continence, mobility that allows for sound formation and facial expression, and adequate oral access.

Furthermore, preservation of sensation is preferred, as insensate lips are more prone to repeat injury [5].

Aesthetic considerations include appropriate symmetry and normal anatomic proportions, presence of a philtrum, normal oral commissures, and establishment of a vermilion-cutaneous white border [6].

Full thickness defects larger than one half of lip cannot be reconstructed by advancement of the remaining lip tissue; therefore, tissue transfer is necessary. The recommended surgical techniques for these defects are: Cross lip flaps (Abbe-Sabatini, Estlander); fan flap (Gillies fan Flap); and circumoral advancement-rotation flap (Karapandzic flap) [7].

Cross lip flaps are designed by forming a full-thickness flap from the other lip.

Cross lip flaps are technically divided into two as Abbe-Sabatini and Estlander flaps.

The Abbe-Sabatini flap is a two-staged procedure, especially preferred for defects that do not involve commissure and the pedicle is generally separated 2-3 weeks late.

The Estlander flap is similar to the Abbe flap, but involves rotating the upper lip tissue around the lateral edge of the mouth. It is best used in situations where the defect involves the oral commissure.

It is a single stage flap that does not only repair the lower lip defect, but is the first step in commissure reconstruction but it results in a blunted rounded angle of mouth so a commissureplasty is performed at 3 months [8].

The most important advantages of these flaps are the reconstruction of the defect by rather similar tissue and the provision of the continuity of muscle fibers [9].

Though denervation of the orbicularis oris may occur, the orbicularis muscle reinnervates with

adequate functioning with one-year postoperative electromyography. The disadvantage of this technique is that it reduces the oral circumference; microstomia which becomes an important issue with increasingly large defects [10].

In our study we reconstructed ten lower lip defects not reaching angle of mouth ranging from 1/2 to 2/3 of the lower lip using Abbe-Sabatini cross lip flap.

We found that Abbe-Sabatini cross lip flap had a good functional outcome regarding Oral continence to food, fluids, and air and Oral mobility which was evaluated by sounds formations and facial expressions and adequate oral access which was evaluated by size of mouth and there were no microstomia if the defects did not exceed more than 2/3 of the size of the lower lip.

In seven patients the sensations were gained completely within six months, but in the remaining three patients there were slight hypoesthesia after one year.

We found also that Abbe-Sabatini cross lip flap had a good aesthetic outcome regarding symmetry and normal anatomic proportions, presence of a philtrum, normal oral commissures, and establishment of a vermilion-cutaneous white border.

The only disadvantage of this flap is that it requires a second stage for separation.

Conclusion:

Abbe-Sabatini cross lip flap is an ideal versatile flap to reconstruct the defects of lower lip ranging from 1/2 to 2/3 of the size of the lower lip not including angle of the mouth with very good functional and aesthetic outcome.

REFERENCES

- 1- Sabattini P.: *Cenno Storico Dell'origine e Progressi Della Rhinoplastica e Chelioplastica* . Bologna, Belle Arti, 1838
- 2- Wilson J.S.P. and Walker E.P.: Reconstruction of the lower lip. *Head Neck Surg.*, 4: 29-44, 1981.
- 3- Craig L. Cupp, Cdr, McUsnr, Wayne F. and Larrabee Jr.: *Operative techniques in otolaryngology-Head and Neck Surgery*, Vol. 4, No. 1, p 46053, 1993.
- 4- Neligan P.C.: Strategies in lip reconstruction. *Clin. Plast. Surg. Jul.*, 36 (3): 477-85, 2009.
- 5- Kronic A.L., Weitzul S. and Taylor R.S.: Advanced reconstructive techniques for the lip and perioral area. *Dermatol. Clin. Jan.*, 23 (1): 43-53, 2005.

- 6- Odell M.J. and Varvares M.A.: Microvascular reconstruction of major lip defects. *Facial Plast. Surg. Clin. North Am.* May, 17 (2): 203-9, 2009.
- 7- Coppit G.L., Lin D.T. and Burkey B.B.: Current concepts in lip reconstruction. *Curr. Opin. Otolaryngol. Head Neck Surg.*, 12: 281-7, 2004.
- 8- Converse J.M. and Wood-Smith D.: Techniques for the repair of defects of the lips and cheeks, in Converse J.M. (ed): *Reconstructive Plastic Surgery* (ed 2). Philadelphia, PA, Saunders, p 1574, 1977.
- 9- McCarn K.E. and Park S.S.: Lip reconstruction. *Otolaryngol. Clin. North Am.*, 40: 361-80, 2007.
- 10- Ishii L.E. and Byrne P.J.: Lip reconstruction. *Facial Plast. Surg. Clin. North Am.* Aug., 17 (3): 445-53, 2009.