

Fleur-De-Lis Approach in Treatment of Abdominal Laxity after Massive Weight Loss

YASSER EL HAWARY, M.D.

The Department of Plastic and Reconstructive Surgery, Faculty of Medicine, Tanta University

ABSTRACT

Background: Bariatric surgeries are becoming increasingly common in the treatment of morbidly obese patients. The enormous weight loss resulting from these procedures causes excessive skin and subcutaneous tissue throughout the body, especially in the abdominal region. The objective of this study was to present the technique of vertical abdominoplasty as an alternative for resection of excess skin in ex-obese patients.

Methods: Evaluation of 20 patients who underwent vertical abdominoplasty between 2011 and 2014. A full abdominoplasty pattern was marked, and the inferior incision was lowered along the midline to adjust for mons pubis ptosis as necessary. The vertical component of the abdominoplasty was marked as an inverted "V" or triangle to decrease the abdominal girth, and the cephalic portion was "rounded off" to create an inverted "U". It was important to lower the final incision of the superior margin of the original abdominal pannus resection approximately 2 to 3cm to allow for minimal tension at the lower abdominal midline closure.

Results: Twenty patients whose average weight loss was 53kg after gastric bypass and gastric sleeve surgery underwent abdominal contour surgery incorporating a fleur-de-lis pattern. Four men and sixteen women with ages ranging from 18 to 48 years (average, 34 years) were treated. Twenty-five percent of the patients had minor complications (2 seromas, 2 minor dehiscences, and one hypertrophic scars), which were all treated on an outpatient basis.

Conclusions: Use of a fleur-de-lis pattern in abdominal body contouring is a safe and effective technique for properly selected massive weight-loss patients. It is particularly appropriate for those patients with either significant upper midline abdominal fullness or midline scar of previous operation.

Key Words: Obesity – Bariatric surgery – Weight loss – Abdomen/surgery.

INTRODUCTION

Standard abdominoplasty technique enables excision of excess tissue in one plane only through a single transverse incision. The single incision may be inadequate in addressing excessive tissue [1].

The Fleur-de-lis (FDL) technique removes supra-umbilical horizontal excess via a vertical excision, in addition to the transverse incision. The operation derived its name from the first stitch bringing the flaps together, giving the appearance of a fleur-de-lis pattern.

A similar operative technique was described as early as 1967 by Castanares and Goethel [2] but the FDL technique was only later popularised by Dellon in 1985 [3]. Dellon used this technique in patients who had marked weight loss, abdominal panniculus with obesity or supra umbilical dermatochalasis [4]. It is therefore an ideal technique for massive weight loss patients.

However, in the face of current increasing obesity globally, accompanied with an increase in bariatric surgeries, this subset of patient population present different surgical challenges compared to cosmetic driven abdominoplasty [5]. They may have excessive skin in both horizontal and vertical components. In this patient group, a standard abdominoplasty technique may not be the most appropriate surgical approach. The FDL technique is ideal for the massive weight loss patient and should be the surgical approach of choice.

PATIENTS AND METHODS

Twenty patients with a history of bariatric surgery undergoing vertical abdominoplasty between 2011 and 2014 in the Hospital of the Faculty of Medicine, Tanta University, was carried out. The variables analyzed were age, time between bariatric surgery and abdominoplasty, body mass index (BMI) after bariatric surgery, use of drains, length of stay, and postoperative complications.

Preoperative markings:

Patients were marked in a standing position. The markings were used as a reference point for

the excision during the surgical procedure, and adjustments were made during surgery to provide the desired result.

Initially, a full abdominoplasty pattern was marked; this area included the tissue from the superior border of the umbilicus to the lowest abdominal crease. The inferior incision was lowered along the midline to adjust for mons pubis ptosis as necessary. This was marked in accordance with Baroudi's description, leaving a (5-7) cm length from the vulvar commissure to the top of the mons pubis for women.

The vertical component of the abdominoplasty was marked as an inverted "V" or triangle to decrease the abdominal girth. The widest portion at the base of the triangle was determined by using a "pinch test," (Fig. 1).

Rounding off the cephalic portion of the inverted "V" to be more like an inverted "U" increased the amount of tissue resected from the cephalic portion. It was also important to lower the final incision of the superior margin of the original abdominal pannus resection approximately 2 to 3 cm to allow for minimal tension at the lower abdominal midline closure (Fig. 2).

Technique description:

All patients wore sequential compression devices on the lower extremities. A Foley catheter was inserted and prophylactic antibiotics were administered. Anticoagulation medications were not used. With the patient under general anesthesia, en bloc resection of the skin was performed following the preoperative marking, without additional detachments. The pre-aponeurotic plane was the deepest limit of the resection.

The navel was separated from the surgical specimen before its resection and maintained by abdominal aponeurosis. In all patients, abdominal aponeurosis plication in 2 planes with non-absorbable suture was then carried out. This enabled not only correction of diastasis of the rectus abdominis muscles, which is always, present in these patients, but also allowed reduction of the tension on the surface planes of the sutures.

In the most caudal position of the scar, some wrinkling of the tissue was normal. In severe cases, compensation was accomplished with a small horizontal component.

Closure was performed in 3 layers by using absorbable thread. The navel was repositioned into the anatomical position, as determined by the projection of its position deep in the skin flaps. All patients were instructed to use compression in the abdominal region from the immediate postoperative period up to 2 months after surgery.

RESULTS

The mean age at the time of abdominoplasty was 34 years (range, 18 to 48 years). Most patients were women (16 women and 4 men). On average, the procedure was performed 2.8 years (range, 1 to 4 years) after bariatric surgery.

All patients underwent significant weight loss after bariatric surgery, with an average loss of 39% of their initial weight (range, 25 to 48%). Mean BMI at the time of abdominoplasty was 27.4kg/m² (range, 22 to 32kg/m²). The mean hospital stay was 2 days (range, 1 to 4 days), the weight of the specimen was 2.9kg (range, 1.2 to 6.5kg), the time of drain removal was 4 days (range, 3 to 9 days), and there were no serious complications such as thrombosis, systemic disorders, or death.

Minor complications were noted in 5 (25%) patients, and included 2 cases of seroma, 2 cases of minor dehiscence, and a case of hypertrophic scarring. The 2 seromas occurred in patients who had their surgical sites drained. Patients with minor dehiscence were treated as outpatients with simple dressings until their wounds had healed by secondary intention.

Table (1): Results of the study.

Result	Mean	Range
BMI at the time of the operation	27.4	(22-32) kg/m ²
Hospital stay	2 days	(1-4) days
Time of drain removal	4 days	(3-9) days
Weight of the specimen	2.9 kg	(1.2-6.5) kg

Table (2): Complications of the study.

Complications	Number	Percent
Seroma	2 cases	10
Minor dehiscence	2 cases	10
Hypertrophic scarring	One case	5
Total	5 cases	25



Fig. (1): Pinch test is used to determine the widest portion at the base of the triangle.

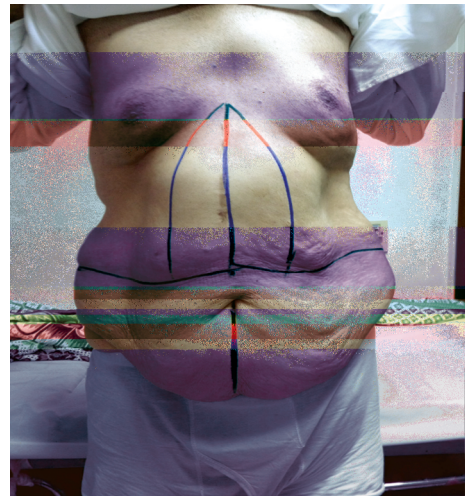


Fig. (2): The vertical component of the abdominoplasty was marked as an inverted "V" or triangle to decrease the abdominal girth.




Fig. (3): The abdomen after excision of the excess skin and fat and plication of the midline.



Fig. (4): The excised part of the abdomen shows the shape of fleur-de-lis.

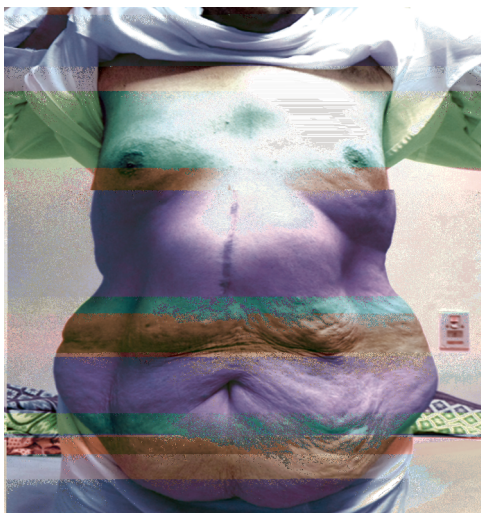

Fig. (5): Preoperative photo of a 29 year-old man requesting vertical abdominoplasty after massive weight loss (ventral view).



Fig. (6): Postoperative photo 2 months later.



Fig. (7): Preoperative photo of the same patient (lateral view).

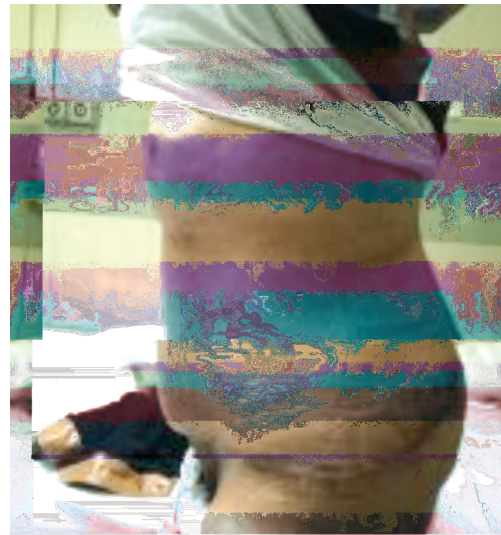


Fig. (8): Post-operative photo of the same patient (lateral view).

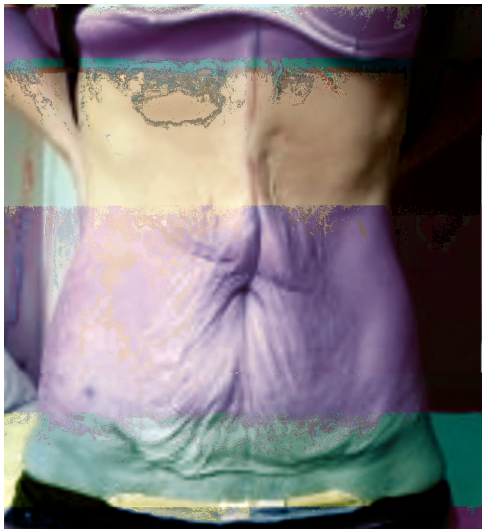

Fig. (9): Preoperative photo of a 40 year-old women requesting vertical abdominoplasty after massive weight loss (ventral view).

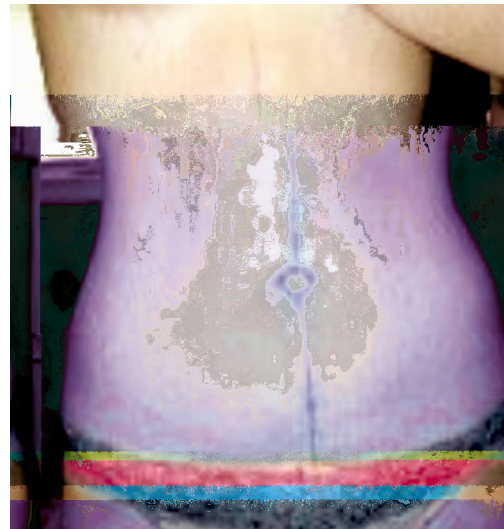

Fig. (10): Post-operative photo after 3 months.

DISCUSSION

Traditionally, tummy tucks are performed via low transverse incisions in order to hide the resulting scars in the patient's underwear or swimwear, leading to better esthetic acceptance by patients. After major weight loss, especially in patients undergoing bariatric surgery, there is a lot of excess skin all over the body, particularly in the abdominal region, which is accompanied by pronounced sagging of the skin.

This excess tissue is visible in both the cranio-caudal direction and the lateral-lateral direction, preventing its compensation with a single horizontal scar. Thus, anchor or fleur-de-lis incisions, with their associated vertical and horizontal incisions,

have become extremely popular for abdominoplasty in patients with excess abdominal skin after major weight loss. However, these incisions are subject to complications, primarily in the region of confluence of the scars, which is known as the T area [6].

This technique results in both vertical and transverse scars, which are less esthetically acceptable and more noticeable as compared to the transverse scar resulting from removal of excess skin in the abdominal region after drastic loss of weight. Although most bariatric surgeries are currently performed laparoscopically, many patients already had a vertical scar in the upper abdomen resulting from open bariatric surgery [7].

Abdominal wall scarring is a risk factor that has to be reconciled for each patient. Many scars, such as those resulting from a previous McBurney's incision for appendectomy, lower transverse abdominal incisions, Pfannenstiel's incisions, and umbilical hernia incisions, can be incorporated into the design of the resected abdominal tissue. In fact, many Kocher subcostal incisions from an open cholecystectomy and midline vertical laparotomy scars can also be incorporated into the design of the fleur-de-lis procedure without jeopardizing the viability of the flaps [8].

A literature review showed complication rates vary widely for the FDL series (12%-62%). Dellon's case series (1985) of 16 patients revealed an overall complication rate of 50% [4].

Ramsey-Stewart's case series on 45 patients showed an overall complication rate of 13.3%, describing partial wound healing and seroma as main complications in their study [5].

The complications encountered in this series were 25% all minor and required outpatient treatment only. The seromas observed in some cases suggest that the use of drains in these patients was not effective. In fact, as there is no additional undermining and subcutaneous tissue at the edges of the wound is closed in multiple planes, the dead space resulting from the procedure is reduced and small collections in localized regions of the wound will form localized cysts, which will not be effectively drained if the drain is placed in another plane.

Conclusions:

Fleur-De-Lis pattern for abdominal contour surgery is an option for treating properly selected post-bariatric surgery patients. It is especially appropriate for those patients who have significant upper midline abdominal excess that contributes to the overall girth.

Recommendations: To reduce complications.

- 1- Pinch and reduce by an inch on either side' of maximal width of vertical ellipse during pre-operative marking.

- 2- Ligating and/or coagulating perforators before division, thereby preventing ends of perforators from retracting and subsequent potential bleeding points post-operatively.
- 3- No undermining of flaps of the abdomen - facilitated by reducing the width to the vertical ellipse.
- 4- Wash and second look for potential bleeding points before closure and appropriate haemostasis.
- 5- No 'breaking of table' before closure of transverse incision.
- 6- The placement of two drains - one under the vertical ellipse excision and one under the transverse abdomen excision.

REFERENCES

- 1- Van der Beek E.S., Te Riele W., Specken T.F., Boerma D. and Van Ramshorst B.: The impact of reconstructive procedures following bariatric surgery on patient well-being and quality of life. *Obes. Surg.*, 20 (1): 36-41, 2010.
- 2- Orpheu S.C., Coltro P.S., Scopel G.P., Saito F.L. and Ferreira M.C.: Body contour surgery in the massive weight loss patient: Three year-experience in a secondary public hospital. *Rev. Assoc. Med. Bras.*, 55 (4): 427-33, 2009.
- 3- Persichetti P., Simone P. and Scuderi N.: Anchor-line abdominoplasty: A comprehensive approach to abdominal wall reconstruction and body contouring. *Plast. Reconstr. Surg.*, 116 (1): 289-94, 2005.
- 4- Dellon A.L.: Fleur-de-lis abdominoplasty. *Aesthetic Plast. Surg.*, 9 (1): 27-32, 1985.
- 5- Ramsey-Stewart G.: Radical "Fleur-de-Lis" Abdominal after Bariatric Surgery. *Obes. Surg.*, 3: 410-414, 1993.
- 6- Agha-Mohammadi S. and Hurwitz D.J.: Management of upper abdominal laxity after massive weight loss: Reverse abdominoplasty and in-framammary fold reconstruction. *Aesthetic Plast. Surg.*, 34 (2): 226-31, 2010.
- 7- Costa L.F., Manta A.M., França A.S., Cavalcante H.A. and Nahon M.: Abdomi-noplastia vertical modificada em pacientes ex-obesos. *Rev. Soc. Bras. Cir. Plást.*, 18 (3): 71-4, 2003.
- 8- Sugarbaker P.H.: Vertical abdominoplasty. *J. Surg. Oncol.*, 78 (3): 217-9, 2001.
- 9- Salles A.G., Ferreira M.C., Remigio A.F.N. and Gemperli R.: Evaluation of aesthetic abdominal surgery using a new clinical scale. *Aesthetic Plast. Surg.*, 36 (1): 49-53, 2012.