

Modifying Waist Contour in Abdominoplasty by Refinement in the External Oblique Advancement Technique

KARIM KHALIL EL-LAMIE, M.D.

The Department of Plastic Surgery, Faculty of Medicine, Ain Shams University

ABSTRACT

A narrow waist is the dominant factor for the hourglass figure which is considered the main determinant of the female body attractiveness. Despite this, many surgeons when performing an abdominoplasty still rely on flanks liposuction and rectus plication to decrease the waist circumference. In many situations these maneuvers are not sufficient in creating the defined waist line. The author advocates the use of external oblique muscle advancement in patients with mild divarication of the recti to enhance waist line definition without any compromise in the abdominal contour.

INTRODUCTION

Abdominoplasty is usually regarded as a straightforward procedure. Apart from the introduction of the superficial fascial system by Lockwood few contributions has been made to enhance the overall outcome [1]. The classic abdominoplasty consisting of removal of excess skin and fat from the lower abdomen, vertical plication of the rectus sheath and umbilical transposition, does little to improve the waist line [2]. Even if combined with liposuction, usually the abdominal contour is slightly improved yet without noticeable waist narrowing. Works dedicated for waist line enhancement ranged from mere vertical plication of the linea semilunaris, transverse plication of external oblique fascia, advancement of the rectus or external oblique muscle up to removal of the floating ribs [2-7]. The external oblique muscle advancement technique was introduced by Nahas in 2001 as a method to modify the abdominal musculoaponeurotic layer in a certain group of patients [4]. In this article, the author discusses the surgical technique, the indication and outcome of this method.

PATIENTS AND METHODS

From April of 2012 to May 2014, 9 female patients underwent abdominoplasty with external oblique advancement, mean age 41. All patients included in the study were presenting with mild to moderate divarication of the recti after history

of one or multiple pregnancies. Patient with severe divarication or paraumbilical hernia were excluded as well any female with history of any obstructive airway disease. The waist to hip ratio (WHR) was taken for all patients preoperatively and remeasured 3 months postoperatively. WHR was used for the evaluation because it is considered as the main determinant of femininity and attractiveness and can be used as a precise tool to calculate the overall changes in the female body contour after the procedure [8]. The waist line was measured at a horizontal level just above the umbilicus i.e. with the lower border of the tape just touching the upper border of the navel. The hip circumference likewise was measured at its widest part at the level of the greater trochanter.

Surgical technique:

After raising the abdominal flap with preservation of the umbilical stalk, the divarication of the recti is corrected with 2 layers of polypropylene 1 sutures from just below the xiphisternum to the pubic bone. The first layer is interrupted figure of eight sutures followed by a reinforcing continuous second layer. The divarication never surpassed 5cm in any case in its widest part. Then an incision is made along one linea semilunaris 2cm medial to the edge of external oblique muscle. Vertically the fascial cut extended from the level of anterior superior iliac spine below up to 5cm above the umbilical level. The plane between the external oblique and internal oblique is entered first with sharp dissection then bluntly with finger dissection till just behind the level of anterior axillary line. Care not to injure the innervation and blood supply of the muscle coming deep from the internal oblique at the level of posterior axillary line. Using 4 or 5 artery clamps, the external oblique fascia is now grasped and advanced medially to overlap 2cm from the rectus sheath. Each clamp is replaced with polypropylene n° 1 sutures applied in a figure of eight fashion sequentially from above downward.

These sutures are reinforced by another running layer all along the overlapped edges. The same technique is applied to the other linea semilunaris resulting in an advancement of 6-8cm on both sides. Liposuction of the abdominal flap above the umbilicus as well as the flanks is performed before excision of the lower abdominal skin and advancement of the flap. Transposition of the umbilicus, suturing the SFS with polydioxanone 0 and Closure of the skin in layers conclude the operation (Fig. 1). Two drains are inserted exiting below the scar in the pubic region and are left from 5-7 days. An abdominal binder is worn immediately after the operation and continuously for the first 6 weeks.

RESULTS

The postoperative course was uneventful apart from 2 patients who suffered from seroma collec-

tion and both were surgically drained 2 weeks postoperatively without any compromise of the final outcome. Normal activity was encouraged after 3 weeks and patients were informed not to strain or attempt to perform sit-ups or vigorous activity for the first 2 months. After this period and during the follow-up the patients were observed during flexion of the trunk. There were no complains whatsoever from the patient during the movement and the contour of the abdomen showed no bulge or deformity during performance of the activity. The waist measurement was serially evaluated at 2 weeks interval and the final measurement was taken after 3 months postoperatively (Fig. 2). The overall abdominal girth was decreased especially just above the level of the umbilicus (waist line) with some patients showing improvement up to 14cm (Table 1).




Fig. (1): A 44-year-old female patient with mild divarication of the recti. (Left) Preoperative markings with the patient on the operating table. (Right) Intraoperative view: The abdominal flap is raised with midline plication of the recti and advancement of the external oblique muscles. The hemostat is pointing to the edge of the right external oblique muscle which is about 5cm from the umbilical stalk. (Below) Immediate postoperative result after completion of the procedure with better waist definition.

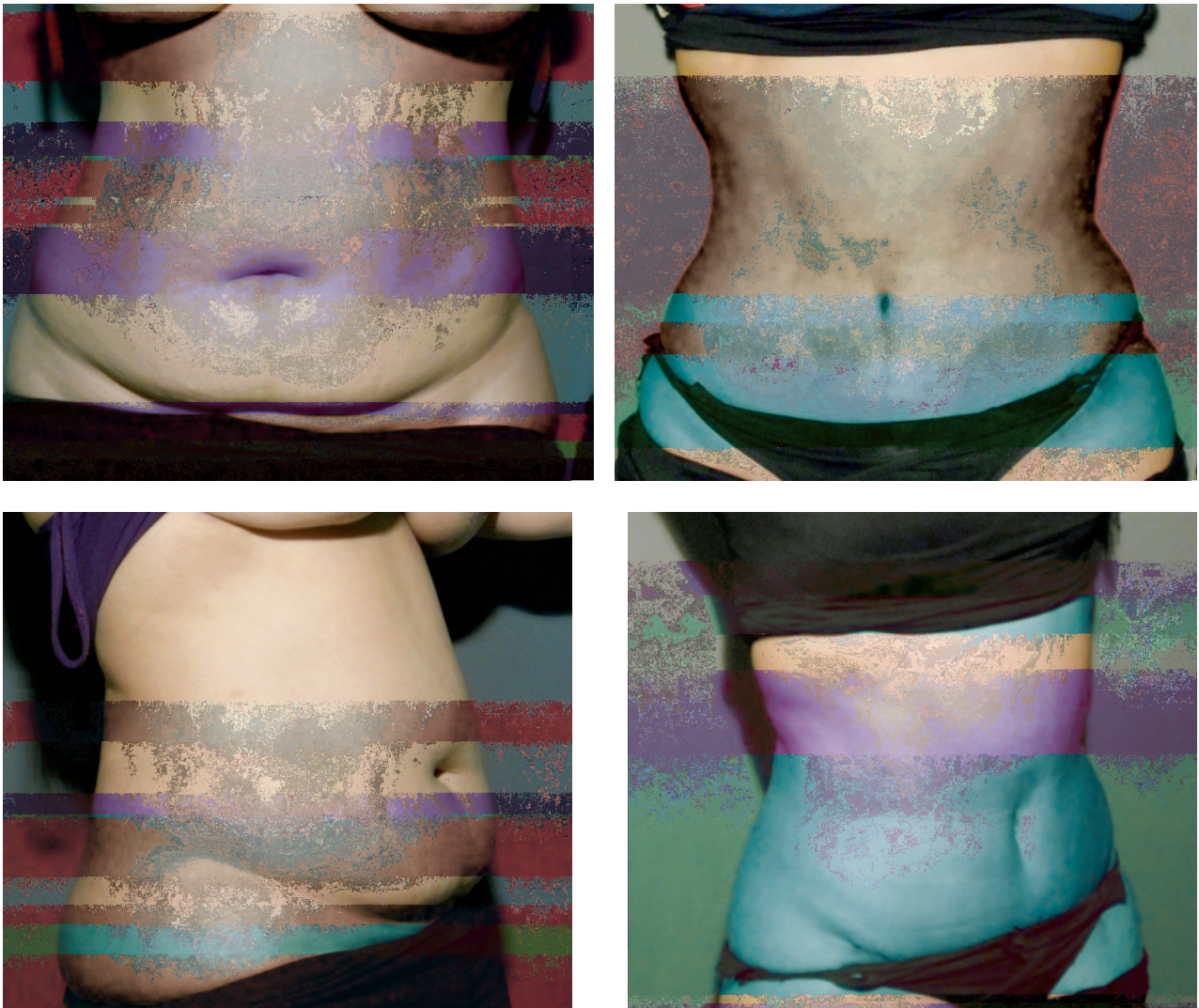


Fig. (2): A 29-year-old female patient after undergoing abdominoplasty with liposuction and external oblique advancement. (Left) Preoperative and (Right) 3 months postoperative. Notice the marked decrease in waist circumference (12cm) and the overall improvement in the abdominal contour.



Fig (3): Abdominoplasty with the myofascial release performed in a male patient with marked divarication of the recti and a paraumbilical hernia. (Left) While the patient is lying flat or coughing there is normal abdominal contour. (Right) on just starting a sit-up a slight longitudinal bulge is observed along the midline representing the two flipping edges of the recti muscles.

Table (1): Patient details.

Patient number	Age	Preoperative waist measurement in cm	Postoperative waist measurement in cm	Preop. WHR*	Postop. WHR*
1	33	85	77	0.87	0.78
2	47	98	87	0.9	0.82
3	51	83	75	0.8	0.73
4	39	96	85	0.89	0.8
5	29	89	78	0.84	0.75
6	37	94	85	0.91	0.82
7	44	97	83	0.98	0.82
8	35	93	82	0.92	0.84
9	54	84	75	0.82	0.74

* WHR = Waist to hip ratio.

DISCUSSION

In the past 2 decades, plastic surgeons started to modify the surgical concept of abdominoplasty in order to achieve an ideal contour of the female silhouette. Lockwood introduced the concept of high lateral tension technique aiming to rejuvenate the shape of the abdomen hip, pubic and upper thigh regions as well [1]. Other authors were concerned with scar location or umbilical modification [9,10]. With the growing interests about the waist to hip ratio and its impact on the overall shape of the body, many works emerged addressing this issue [11]. Conventional vertical plication of the rectus sheath although decreasing the abdominal girth in case of marked divarication of the recti muscle does not lead to a better waist definition [12-14]. Actually, if done aggressively vertical plication can lead to increase intra-abdominal pressure causing slight lateral bulge and obliteration of the hourglass figure [5,15]. Different techniques of plication were then introduced like transverse plication at the level of umbilicus, L shape plication of the external oblique aponeurosis and vertical plication of the linea semilunaris [2,3]. Ramirez introduced rectus myofascial release and repair which is stemmed from component separation used to repair midline abdominal wall defects. The myofascial release relies on incising the anterior rectus sheath at the junction of the inner one third with the middle third of the rectus muscle width. These incisions meet just below the level of the xyphoid process superiorly and the pubis inferiorly. Suturing first the medial borders and then lateral borders of these incisions in the midline allows better pull of the external oblique muscle which in turn will be more effective in decreasing the waistline measurements. Ramirez noted average width advancement at the level of the navel of

10.5cm. In the author opinion his technique is mainly suited for patients with significant midline laxity however when performed in patient with mild divarication of the recti, this maneuver has limited advantage. Moreover, if attempts are made to increase the advancement by incising more laterally along the rectus sheath, this resulted in flipping of the recti with noticeable bulge when performing sit-ups (Fig. 3).

External oblique advancement was introduced by Nahas as an alternative to waist narrowing. Based on a cadaveric study, there was significant statistical improvement of waist measurements after external oblique advancement performed on top of rectus sheath plication [4]. Nahas later on introduced this method clinically as a solution to a group of people whom he classified as having a "poor waistline definition" without describing what are their criteria [6]. In the author opinion this method is suitable for patients who have laxity of the abdominal wall muscles without significant diastasis of the recti and midline bulge. This can be tested by asking the patient to cough or do a sit-up while palpating the edges of the 2 recti muscles. An estimated divarication of up to 5cm around the umbilicus is considered favorable for this technique as there will still be a room for significant external oblique advancement after midline plication without producing undue tension on the abdominal musculature. Moreover, in this group of patients with small divarication the over-aggressive flipping of the recti muscle is avoided and hence no postoperative bulge is produced. However, if a significant divarication exists, the surgeon should attempt a myofascial release from the start and rely on the midline advancement of the recti to enhance the waistline.

REFERENCES

- 1- Lockwood T.: High-lateral-tension abdominoplasty with superficial fascial system suspension. *Plast. Reconstr. Surg.*, 96 (3): 603-15, 1995.
- 2- Yousif N.J., Lifchez S.D. and Nguyen H.H.: Transverse rectus sheath plication in abdominoplasty. *Plast. Reconstr. Surg.*, 1; 114 (3): 778-84, 2004.
- 3- Psillakis J.M.: Plastic surgery of the abdomen with improvement of body contour: Physiology and treatment of the aponeurotic musculature. *Clin. Plast. Surg.*, 11 (3): 465-77, 1984.
- 4- Nahas F.X.: Advancement of the external oblique muscle flap to improve the waistline: A study in cadavers. *Plast. Reconstr. Surg.*, 108 (2): 550-5, 2001.
- 5- Abdominoplasty and Abdominal Wall Rehabilitation: A Comprehensive approach. Ramirez OM. *Plast. Reconstr. Surg.*, 105 (1): 425-35, 2000.
- 6- Nahas F.X.: An aesthetic classification of the abdomen based on the myoaponeurotic layer. *Plast. Reconstr. Surg.*, 108 (6): 1787-95, 2001.
- 7- Davison S.T., Clifton M.S., Futrell E.F., Priore R. and Manders E.K.: Aesthetic Considerations in Secondary Procedures for Gender Reassignment. *Aesthet. Surg. J.*, 20 (6): 477-481, 2000.
- 8- Singh D.: Universal allure of the hourglass figure: An evolutionary theory of female physical attractiveness. *Clin. Plast. Surg. Jul.*, 33 (3): 359-70, 2006.
- 9- Le Louarn C. and Pascal J.F.: The high-superior-tension technique: Evolution of lipoabdominoplasty. *Aesthetic Plast. Surg.*, 34 (6): 773-81, 2010.
- 10- Baroudi R. and Ferreira C.A.: Contouring the hip and the abdomen. *Clin. Plast. Surg.*, 23 (44): 561-72, 1996.
- 11- Fisher M.L. and Voracek M.: The shape of beauty: Determinants of female physical attractiveness. *J. Cosmet. Dermatol.*, 5 (2): 190-4, 2006.
- 12- Oneal R.M.1, Mulka J.P., Shapiro P., Hing D. and Cavaliere C.: Wide abdominal rectus plication abdominoplasty for the treatment of chronic intractable low back pain. *Plast. Reconstr. Surg.*, 127 (1): 225-31, 2011.
- 13- Van Uchelen J.H., Kon M. and Werker P.M.: The long-term durability of plication of the anterior rectus sheath assessed by ultrasonography. *Plast. Reconstr. Surg.*, 107 (6): 1578-84, 2001.
- 14- Nahas F.X., Ferreira L.M., Augusto S.M. and Ghelfond C.: Long-term follow-up of correction of rectus diastasis. *Plast. Reconstr. Surg.*, 115 (6): 1736-41. Discussion, 1742-3, 2005.
- 15- Matarasso A.: The male abdominoplasty. *Clin. Plast. Surg.* 31 (4): 555-569, 2004.