

Comparison between Percutaneous Reduction and Closed Reduction for Treatment of Non-comminuted Isolated Zygomatic Arch Fractures

MAAMOUN ISMAIL, M.D.*; AMR IBRAHIM FOUAD, M.D.* and MOHAMED S. M HASSAN, M.D.**

The Departments of Plastic Surgery and General Surgery**, Faculty of Medicine, Cairo* & Fayoum**, Univeristies*

ABSTRACT

Zygomatic arch fractures are common injuries, occurring in isolation in 5% of all patients with facial fractures and in 10% of patients with any fracture to the zygomaticomaxillary complex. Isolated non-comminuted zygomatic arch fractures are easily treated with the minimally invasive approaches, which most often provide long-term stability. This study used an objective analysis for evaluation of various minimally invasive options available for reduction of non-comminuted isolated fracture of zygomatic arch namely percutaneous, transcutaneous, Gillies, and Keen approaches. The study included 100 patients randomly divided into 2 groups, group A treated by percutaneous and transcutaneous methods and group B treated by closed reduction. Objective analysis was performed using malar height and vertical dystopia measurements; subjective analysis was done based on clinical analysis and a questionnaire answered by the patients. It was concluded that there is no statistically significant difference in regards the outcome among both groups and both methods can be done safely to reach an anatomic successful reduction.

INTRODUCTION

The zygoma is a major portion of the midfacial contour. When a deformity occurs in this area, a reduction should be conducted to correct it [1]. The zygomatic arch, contradistinction to the zygoma is a relatively weak part of the facial bone [2]. Zygomatic arch fractures are common injuries, occurring in isolation in 5% of all patients with facial fractures [3], and among all facial fractures, the zygomatic arch occurs the most frequently [4]. The incidence and etiology varies from developed and under-developed countries, but in general it is more commonly found in young males and the most common cause was found to be direct trauma as in road traffic accidents followed by violence [5]. Fracture zygomatic arch can be clinically diagnosed by observation, the region of pain and tenderness, restricted mouth opening caused by impingement of the coronoid process, trismus caused by trauma and irritation to the temporalis muscle, flattening of the midface and asymmetry in the malar region [6]. Skeletal healing of bone fragments

after insufficient fracture reduction and fixation results in an inadequate projection of the zygomatic arch and thus facial asymmetry. Therefore, from both cosmetic and functional aspects, it is mandatory that zygomatic arch fracture is properly diagnosed and adequately managed [7]. Radiological assessment can be done by submentovertex radiograph and computed tomography both axial cuts and 3-D [8]. Recently, Ultrasonography proved to be a very rapid, cost-effective, and radiation free imaging technique for detection of superficially situated bone fracture such as zygomatic arch [9,10].

Nevertheless, there is no approved classification for the zygomatic arch fracture, which has a physiognomically important influence to provide guidance for treatment. Because of these reasons, new classification systems are improved. According to the computed tomographic findings, the classification according to dislocation of fractures can be summarized as below [4]:

Type I: No displacement.

Type II: Displacement with bone contact at all fractures lines.

Type III: Displacement without bone contact at one fracture line.

Type IV: Displacement without bone contact at two fracture lines.

Type V: Comminution or displacement without bone contact at three or more fracture lines.

Yamamoto et al., [11] reported that in type I fracture; reduction is not necessary. In type II, III and IV, reduction by closed methods is possible. In type V, open reduction is needed to reduce the comminuted fragments together with fixation and stabilization to maintain their alignment.

Closed reduction through extraoral, intraoral, or percutaneous approach is used for most cases

of zygomatic arch fractures [12]. Endoscopic-assisted approach to achieve reposition and osteosynthesis for isolated arch fracture is now an integral part of management of zygomatic arch fracture assuming the development of specialized training programs and improvements in endoscopes [13].

The objective of this study was to compare between the percutaneous, transcutaneous reduction and closed reduction methods for treatment of isolated fracture zygoma type II, type III and type IV analyzing the outcome both objectively and subjectively.

PATIENTS AND METHODS

100 patients were randomly divided equally into two groups. In group A, 50 patients were treated by percutaneous or transcutaneous reduction for isolated zygomatic arch fracture whether by hook traction or percutaneous stitches traction and in group B, 50 patients were treated by closed methods of reduction by either intra-oral (Keen's) or temporal (Gillie's) approach. They were evaluated objectively for their outcome, complications during and after reduction with evaluation of their advantages and disadvantages and the difference between the two groups was observed. It aimed for the better clinical results and fewer complications for each procedure, consequently contributing towards the greater goals of a better treatment option and in due process benefit the concerned patient. The study was conducted over a period of more than 4 years from November 2010 – May 2014 in Kasr Al Aini Hospital (Cairo University Hospitals, Governmental Hospitals, and private health sector). It included patients between 14 and 60 years with isolated non-comminuted zygomatic arch fractures. Other inclusion criteria were patients presented by non-comminuted isolated zygomatic arch fracture within one week of fracture onset (type II, III, and IV) willing to receive treatment. Exclusion criteria were medically unfit patients, cases with comminuted fracture of zygomatic arch, (type V), and patients with associated maxillofacial fractures or multiple trauma patients.

Preoperatively; all the patients were ensured to be vitally stable, received pain killer and parenteral antibiotics were administrated. Radiological imaging included plain X-ray (Waters' view, Caldwell's posterior-anterior view) and computed tomography (axial and 3-D). Malar height was measured from vertex view of the patient comparing fractured site with normal site and measuring with a Vernier caliper. For measurement of malar height a single reference point (intersection

point of midsagittal line with the intercanthal line) was taken and second point was taken at the maximum height of malar region as viewed from vertex view of patient and distance was measured between these two points pre and post operatively. Informed consent was taken in all cases, preoperative photos were taken, and antibiotic was administrated. Surgery was done in all cases within 7 days of the trauma. For the percutaneous reduction, it was performed under local anesthesia and sedation, while in cases included in the closed reduction group; it was done under local anesthesia and intravenous sedation or general anesthesia. In case of hook traction, via a lateral eyebrow incision and by a trans-cutaneously insertion hook reduction was done. In cases of the percutaneous stitch traction, a polypropylene "1" two stitches was used to pass from skin to beneath (posterior to) the zygomatic arch, then back from skin, stitches were placed on both medial and lateral sides, then traction was done in a superior-anterolateral direction. Gillie's temporal approach; 2.5cm incision, inclined at an angle of 45° to the zygomatic arch, in the temporal region in the hair bearing area of the scalp, or at the hair line. The Rowe zygoma elevator inserted between the fascia and temporalis muscle and fracture is reduced. Keen's approach uses a 1cm incision in the mucobuccal fold just beneath the zygomatic buttress of the maxilla. Elevators are passed upwards behind the fractured bone maintaining close contact with the bone in order to avoid entering the fat pad in the temporal bone. Reduction is achieved by elevating the bone upward and outward; a snapping sound may be heard when the bone is replaced.

Postoperatively, continuation of antibiotic and anti-inflammatory pain killers was continued for one week, computed tomography (axial and 3D) was done, with postoperative questioner answered by the patients and postoperative photos on regular visits. Further assessment was done by analysis of malar height and vertical dystopia at first, 3rd, 6th weeks after reduction. At the 6th week, malar height and vertical dystopia were confirmed as by that time, the malar height can be assessed without presence of any edema. Randomization was done using computer based software "EpiCalc2000". The software was used to generate serial numbers 1-100 into two groups randomly and those who fulfilled the inclusion criteria were allocated serial numbers according to the date and sequence of admission to hospital. The person who was responsible for conducting the measurements at the time of assessment of variables was blindfolded regarding the type of procedure that was conducted. Data

were analyzed by SPSS version 14.0, a computer based software. Quantitative variable, age, malar height, vertical dystopia has been presented as Mean \pm Standard Deviation (SD); *t*-test was used for comparison between the two groups. The $p \leq 0.05$ was taken as significant.

RESULTS

In this study, 100 patients were randomly divided into two study groups. In group A, patients were treated by transcutaneous or percutaneous reduction methods and in group B; patients were treated by closed reduction methods. In all cases, etiology was traumatic; road traffic accidents represented 52%, violence 35% accidental fall 9%, while sport injuries were 4%. The average age of patients in group A was 31.60 \pm 12.35 years with age range 51 (68-17) years while in group B the average was 30.34 \pm 11.69 years with age range 55 (60-15) years. In both study groups, there was no statistical difference in the average age of the patients, i.e. p -value (0.601 $>$ 0.05). According to the gender there were 85 male patients, 44 were treated by percutaneous or transcutaneous reduction while the rest of 41 were treated by closed reduction. There were only 15 female patients in this study, in which 6 were treated by percutaneous or transcutaneous reduction and 9 were treated by closed reduction. The male to female ratio was 5.67:1. Objective analysis included Malar height and vertical dystopia measurement. Malar height in group A after 6 weeks was 67.02 \pm 3.52mm with range 16 (75-59) mm, while in group B the average malar height was 68.38 \pm 3.62 with range of 13 (74-

61) mm. That is statistically the same (insignificant), i.e. p -value (0.06 $>$ 0.05). In group A, vertical dystopia was 1.84 \pm 0.68mm with range of 2 (3-1) mm and in group B the average vertical dystopia was 1.86 \pm 0.77 with range of 3 (3-0) mm. The average vertical dystopia was statistically insignificant, i.e. p -value (0.897 $>$ 0.05). Clinically, there was mild postoperative edema and bruises in all cases that resolved spontaneously within the period for maximum 6 weeks of follow up. Postoperative pain was mild; with pain score ≤ 2 in all cases. Functional outcome in regards to adequate reduction was achieved in all cases as assessed by postoperative computed tomography, no transient trismus, and full mouth opening was achieved in all cases. Cosmetic appearance was accepted in all cases based on the questionnaire answered by the patients.

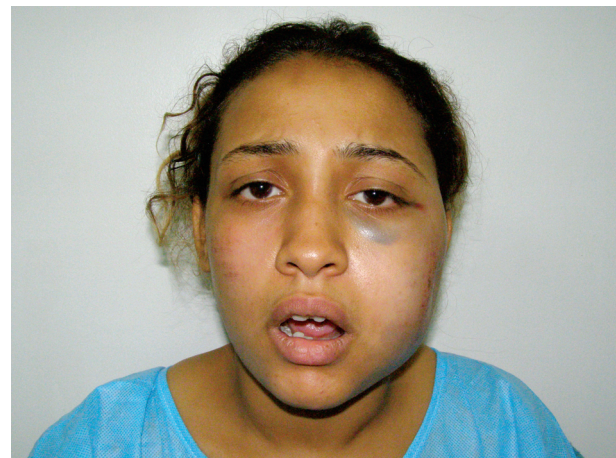

Fig. (1): Preoperative photo of 24 years old female with left zygomatic arch fracture with limited mouth opening.

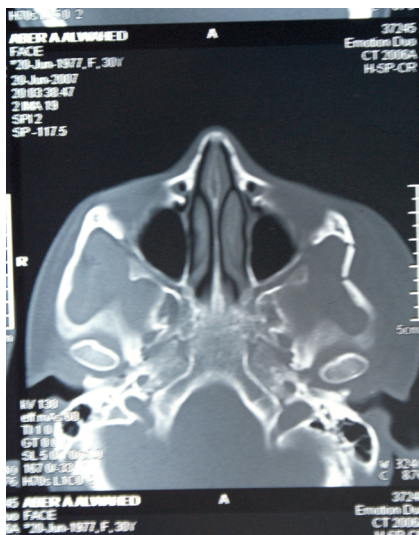

Fig. (2): CT scan (axial cuts) showing left zygomatic arch fracture for same patient.

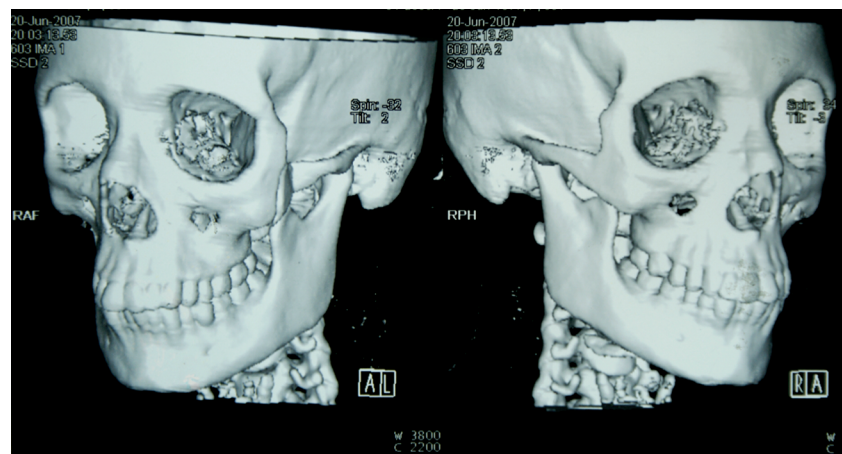


Fig. (3): 3-D CT scan for same patient-left zygomatic arch fracture.

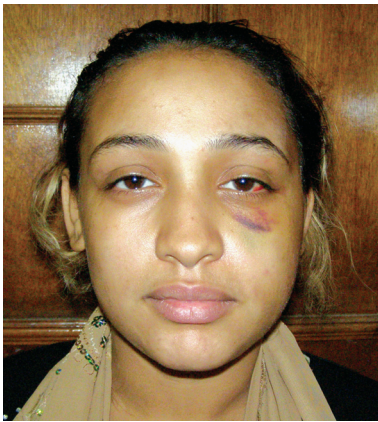

Fig. (4): Postoperative photo for same patients (2 weeks postoperative after closed reduction by Gillie's approach).

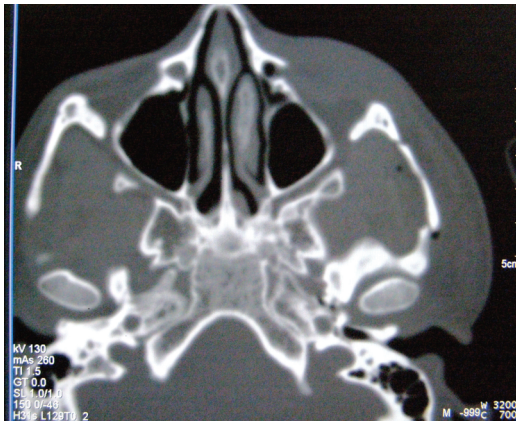


Fig. (5): Postoperative axial CT scan shows adequate reduction.

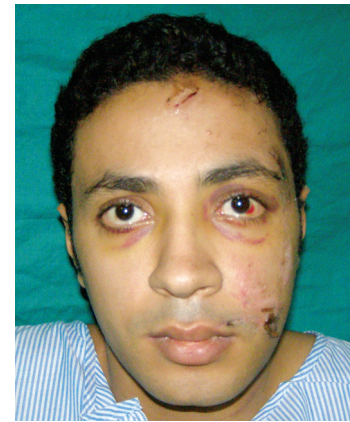

Fig. (6): Preoperative photo for 22 years old patient with left zygomatic arch fracture.

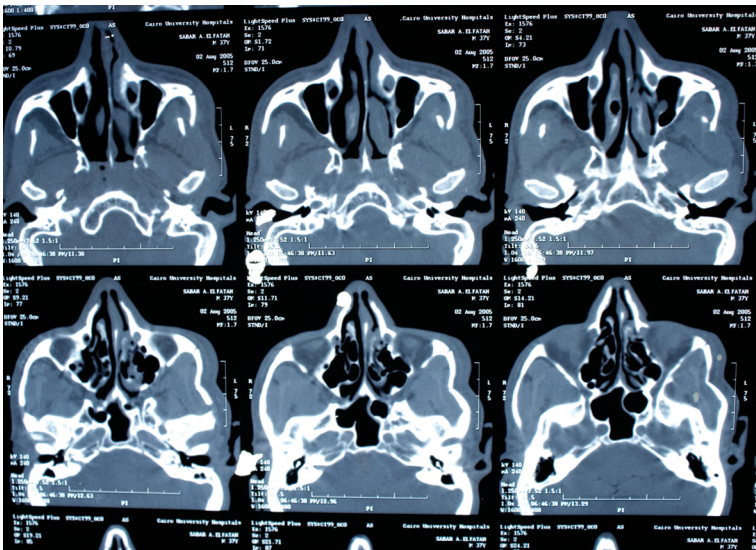


Fig. (7): CT-scan axial cuts showing left zygomatic arch fracture.

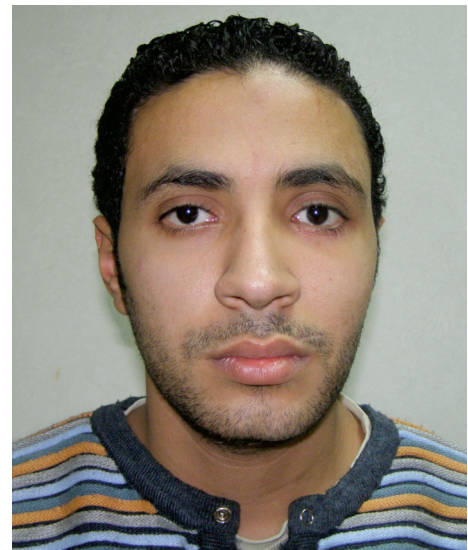

Fig. (8): Postoperative photo for the same patient after 8 weeks after percutaneous reduction using polypropylene stitches.

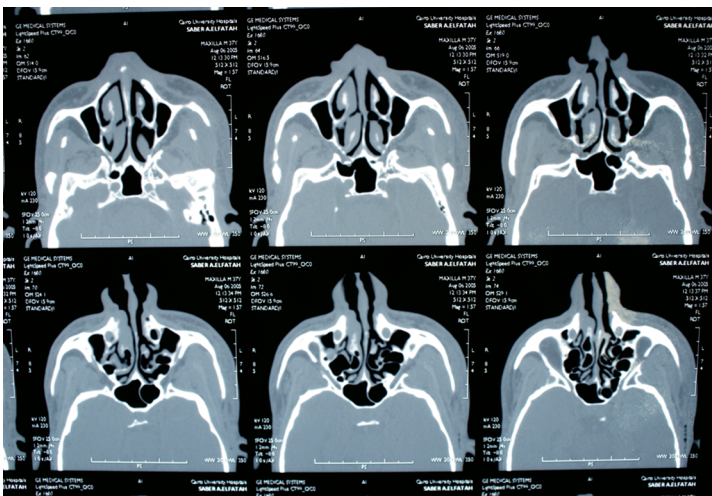


Fig. (9): Postoperative CT scan axial cuts showing the successful reduction of left zygomatic arch fracture.

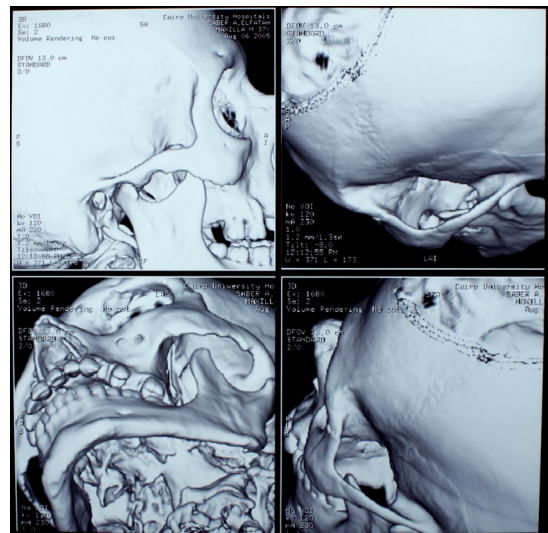


Fig. (10): 3-D CT Scan for the same patient.

Table (1): Demography of the patients included in the study.

Etiology	Sex	Age	Patients
RTA 52%	85% Males	14-16 years	100 cases
Violence 35%	15% Females		
Accidental falls 9%			
Sport injuries 4%			

Table (2): Distribution of cases according to the surgery-reduction method-done.

	Gillies	Keen	Trans-cutaneous	Per-cutaneous stitch
Male	23	18	25	19
Female	4	5	3	3
Total	27	23	28	22

DISCUSSION

Zygomatic arch has a thin structure and is affected easily by trauma. Therefore, among facial fractures zygomatic arch fractures are rather frequent. Some of the zygomatic arch fractures may be in the form of component of the mid-face fracture. Isolated fractures of zygomatic arch only results from localized force landing on the face laterally and having a relatively less impact. Isolated fracture of zygomatic arch comprises about 10% of all zygomatic fractures [4]. If it is not treated properly, the arch fracture may lead not only to various cosmetic deformities related to skeletal structure of the face but also to functional disorders resulting from the pressure on the coronoid process. There are many studies, which related to demographic distribution of isolated zygomatic arch fracture in the literature. In these studies, it is reported that fractures were more common in males than females, and that road traffic accidents and falls represents [11]. In our study, males represented 85% of the patients included in the study, road traffic accidents represented the commonest etiology, but the percent of violence as an etiology was higher in our study than mentioned in the literature. The left side was more frequently involved than the right side, and the etiology is unknown [11] and that matched to the results in our study. Our theoretical explanation to the higher incidence of higher incidence of left zygomatic arch fracture due to violence may be related that most populations are right handed, making the direction of direct trauma mostly towards the left side of the face of the victim. Classification of the fractures greatly facilitates the surgeon choice of treatment. However, until recently there has been no classification of the generally encountered isolated zygomatic arch

fractures in various shapes, it does not exist in the literature, and to form an algorithm for treatment was an attracted attention. Yamamoto et al., [11] therefore classified the fractures into five types according to the degree of displacement and loss of bone contact. We found that his classification is useful to determine the treatment method, in which type I does not need reduction and types III and IV needs closed reduction, while open reduction or fixation is needed for type V fractures [14]. We followed that classification in our study, it was found to be helpful and it clearly defined our inclusion and exclusion criteria. Based on that type I that needs no reduction was not included in the study, and type V that needs open reduction and fixation was one of the exclusion criteria. In spite of that, still some authors find that there is no well-established classification and treatment guideline for zygomatic arch fracture and reduction [15]. Fractures of the zygomatic arch are usually treated by blind methods, as the fracture line cannot be visualized directly in closed or percutaneous reduction, it depends on digital exploration, crepitus, clicks, or conventional radiography and these can be used as guides to reposition of fragments. That is why some authors mentioned that successful closed reduction is often difficult. Postoperative radiographs are often the only way to assess the adequacy of the reduction. The correct alignment of the zygomatic arch is very important in achieving adequate repositioning. The correct alignment indicates the proper position of the zygomatic bone and ensures adequate prominence of the lateral midfacial aspect [16]. These were the clinical guides that we followed in our study, but we did not face any significant difficulty as mention by Gulicher et al., [16], we depended on assessing the success of reduction mainly by post-reduction imaging (axial computed tomography) to assess the success of reduction. Portable fluoroscopy and C-arm may have the advantage of evaluation of the reduction status intraoperatively [17]. Recently, intraoperative high frequency ultrasound guidance was introduced for intraoperative zygomatic arch reduction, and it was concluded that it is rapid, easy, and recommended as an intraoperative visualizing tool [18]. We did not use any of these intraoperative imaging tools in our study, and as per the success of reduction in our study, and in spite of these methods being helpful valuable tools, we did not find that it is essential to use any of them. There are several methods for treatment of the displaced isolated zygomatic arch fracture such as percutaneous approach, intraoral (Keen) approach, temporal (Gillie's), and open reduction. Lately, most closed reduction is more favored by most authors [19].

From these, some authors reported that the Gillie' approach is the most frequently used modality [20]. Closed reduction has the advantages of easy reduction under local anesthesia, little possibility of facial nerve injury, can be done via hairline incision, and its results are satisfactory [11]. Keen intraoral approach has the advantages of that it leaves no visible scars and can obtain complete anatomic reduction, and it is of choice for several authors [14]. Percutaneous methods by hook reduction can be done via a lateral eyebrow incision and by a transcutaneous inserted hook is easy, can be done under local anesthesia, and avoid lacerations of buccal skin [11] and with successful reduction [21]. Using a percutaneous two stitches, and passing it underneath the zygomatic arch and performing an upward and lateral traction on the arch, can be done under local anesthesia, safe, easy, avoid any incisions and hence no scars, but it needs experience to reach an easy successful anatomical reduction. In this study, it was found that there was no statistical difference between the closed reduction methods in comparison to the percutaneous or transcutaneous methods, and both can lead to a successful anatomical reduction based on objective analysis using malar height and vertical dystopia measurements. Recently endoscopic reduction has been used for zygomatic arch fractures, and found to be helpful to perform reduction and fixation, if needed, via small incision and without sustaining the drawbacks of extensive access incisions [17].

Conclusion:

Fracture of the zygomatic arch is more common in adult males who are more exposed to external environment as compared to females. Road traffic accidents are the commonest cause for zygomatic arch fracture, but its ratio to violence differs between developed and underdeveloped countries (the incidence of violence is higher in underdeveloped countries). Objective assessment of post-reduction variables, i.e. malar height and vertical dystopia does not show a statistically significant difference between both the percutaneous and transcutaneous simple measures and the closed reduction methods. It is still recommended to have a protocol for management of zygomatic arch fracture based on a well-established classification. It was found that no statistical advantages for closed reduction over percutaneous reduction methods, in addition to both are simple, safe, minimally invasive, with very minimal morbidity. Percutaneous reduction has the advantages of that it can be done under local anesthesia only and surgical incisions can be avoided totally with the percutaneous stitch method for reduction. Endoscopic

assisted management of fracture zygomatic arch with all its types has a significant role.

REFERENCES

- 1- Cheon J., Seo B., Yang J. and Son K.: Clinical follow-up on sagittal fracture at the temporal root of the zygomatic arch: Does it need open reduction? Archives of Plastic Surgery, 40 (5): 546-552, 2013.
- 2- Fonesca R.: Oral maxillofacial surgery, chapter 6, Volume 3, 1st edition, Fonesca R. (editor), Page 198, W.B. Saunders Company, 2000.
- 3- Swanson E., Vercler C., Yaremchuk M.J. and Gordon C.: Modified gillies approach for zygomatic arch fracture reduction in the setting of bicoronal exposure, The Journal of Craniofacial Surgery, 23 (2): 859-62, 2012.
- 4- Ozyazgan I., Gunay G.K., Eskitascioglu T., Ozkose M., and Coruh A.: A new proposal of classification of zygomatic arch fractures, J. Oral. Maxillofac. Surg. Mar., 65 (3): 462-9, 2007.
- 5- Cheema S.A.: Zygomatic bone fractures, J. Coll. Physicians Surg. Pak., 12: 815-821, 2004.
- 6- Nayyar M.S.: Management of zygomatic complex fracture, J. Coll. Physicians Surg. Pak., 12: 700-705, 2002.
- 7- Rohrich R.J. and Watumull D.: Comparison of rigid plate versus wire fixation in the management of zygoma fractures: A long-term follow-up clinical study, Plast. Reconstr. Surg., 96 (3): 570-575, 1995.
- 8- Michael P., Dolas R., Managutti A. and Deepashri K.: A modified temporal incision: An alternative approach to the zygomatic arch, J. Maxillofac. Oral. Surg., 9 (4): 428-433, 2010.
- 9- Singh K. and Jayachandran S.: A comparative study on the diagnostic utility of ultrasonography with conventional radiography and computed tomography scan in detection of zygomatic arch and mandibular fractures, Contemporary Clinical Dentistry, Volume 5 (Issue 2): 166-169, 2014.
- 10- Adeyemo W. and Akadiri O.: A systematic review of the diagnostic role of ultrasonography in maxillofacial fractures, Int. J. Oral. Maxillofac. Surg., 40: 655-61, 2011.
- 11- Yamamoto K., Murakami K., Sugiura T., Fujimoto M., Inoue M., Kawakami M., Ohgi K. and Kirita T.: Clinical analysis of isolated zygomatic arch fractures, J. Oral. Maxillofac. Surg. Mar., 65 (3): 457-61, 2007.
- 12- Werner J., Frenkler J., Lippert B., et al.: Isolated zygomatic arch fracture: Report on a modified surgical technique, Plast. Reconstr. Surg., 109 (3): 1085-9, 2002.
- 13- Xie L., Shao Y., Hu Y., Li H., Gao L. and Hu H.: Modifications of surgical technique in isolated zygomatic arch fracture repair: Seven case studies, Int. J. Oral. Maxillofac. Surg., 38 (10): 1096-100, 2009.
- 14- Guner R., Yilmaz U., Yaman F. and Cetin C.: Isolated arcus zygoma fractures (9 cases report), Journal of International Dental and Medical Research, Accept Date 09 November, ISSN 1309-100X, 2009.
- 15- Kim J., Kim S., Chung A. and Chung Y.: Zygomatic arch fracture: A new classification and treatment algorithm with epidemiologic analysis, J. Craniofac S., DOI: 10.1097/SCS.0000000000000864, 2014.

- 16- Gulicher D., Krimmel M. and Reinert S.: The role of intraoperative ultrasonography in zygomatic complex fracture repair, *Int. J. Oral. MAXillofac. SURG.*, 35: 224-230, 2006.
- 17- Badjate S.J. and Cariappa K.M.: C-Arm for accurate reduction of zygomatic arch-a case report, *Br. Dent. J.*, 10: 275-7, 2005.
- 18- Kiwanuka E., Smith S., Frates M. and Caterson E.: Use of high-frequency ultrasound guidance or intraoperative zygomatic arch fracture reduction, *J. Craniofacial S.*, 24 (6): 2036-8, 11/2013.
- 19- Niessen F., Egmond V., Specken T. and Alting C.: The Gillies procedure in the treatment of zygomatic fractures and dislocations, *Eur. J. Plast. Surg.*, 19: 300-306, 1996.
- 20- Lee P.K., Lee J.H. and Choi Y.S.: Single transconjunctival incision and wo-point fixation for the treatment of non-comminuted zygomatic complex fracture, *J. Korean Med. Sci.*, 21: 1080-1085, 2006.
- 21- Kruger E.: *Oral and maxillofacial traumatology*, Schilli W., Chapter 10, Volume 2, page 172-173, Quintessence Publishing Co., Inc. Chicago, Illionis, 1986.