

## Repairing the Capsular Defect after Dorsal Wrist Ganglionectomy: Long-Term Effect on Recurrence

AHMED M. ABOULWABA, M.D. and SHERIF S. EMARA, M.R.C.S.

The Department of Plastic Surgery, Faculty of Medicine, Ain Shams University, Cairo, Egypt

### ABSTRACT

*Background:* Dorsal wrist ganglion is the commonest benign tumor of the hand. We have been encountered with many cases of recurrence after usual surgical excision. There is a widespread disagreement regarding is it essential to repair the capsular defect or not? We supposed that closure of this defect after excision will prevent or decrease the recurrence rate according to the pathophysiological data of the ganglion cyst formation.

*Material and Method:* 171 adult patients were prospectively involved in this study. All have been operated using the same technique of excision of the stalk and part of the adjacent capsule followed by closure of the resultant capsular defect.

*Results:* With long term postoperative follow-up, we have no recurrence and all patients regained full range of motion of the wrist joint within two months.

*Conclusion:* Closure of wrist capsule after dorsal wrist ganglionectomy will prevent recurrence with no affection on the range of motion or overall hand functions.

### INTRODUCTION

Dorsal wrist ganglia have been shown to originate from the portion of the joint capsule that attaches to the scapho-lunate (SL) ligament [1]. In 1928, Carp and Stout [2] theorizing that ganglion cysts resulted from mucinous degeneration of connective tissue because of chronic damage. They felt that communication of the ganglion cyst with the joint capsule was the result of later degeneration of the capsule. Soren [3] in 1966 reinforced this theory and postulated that a constitutional factor may contribute to the development of ganglion cysts because some patients display multiple cysts on their wrists and ankles.

Extensive studies by Psaila and Mansel [4] by using scanning electron microscopy showed that the walls of ganglion cysts consist mainly of sheets

of collagen fibers arranged in multidirectional strata. The walls show sparse, flattened cells appear to be fully functional fibroblasts or mesenchymal cells, but an epithelial or synovial lining is distinctly absent [4,5]. Most cysts contain a clear, highly viscous, jelly-like fluid, significantly thicker than synovial fluid. This fluid is different biochemically and is much thicker than intra-articular synovial fluid [6].

The treatments range from simple observation [7], aspiration with [7-11] or without injection of various agents [12-14] to arthroscopic resection [15-18] and open excision [17,19,20] Surgical excision remains the gold standard for treatment of ganglion cysts. Prior to the work of Angelides, postoperative recurrence rates were as high as 40%, results that were parallel to the conservative management. Since the adoption of surgical techniques that include excision of the entire ganglion complex, including cyst, pedicle, and a cuff of the adjacent joint capsule, recurrence rates have improved significantly.

Recurrence rates have been documented widely, varying from 1% reported by Angelides and Wallace in 1976 [1] to 42% [21] for open excision. Arthroscopic resection of dorsal and more recently volar ganglia show a recurrence rate up to 7% [22]. Angelides and Wallace [1] reported that macroscopic studies indicated the presence of a tortuous duct communicating with the SL joint. They proposed an excision of the tissue removing the involved segment of the joint capsule and the deep attachments to the SL ligament. According to them and Razemon, [23] the recurrence rate was very low (1-2%).

Some surgeons consider the resection of a part of the articular capsule around the point of the

input of ganglion's stalk (average 1-2cm diameter) to be very important with excellent results. However, a literature search revealed widespread disagreement regarding it is essential to repair the capsular defect. This study was designed to examine the results of surgical removal of the ganglion, part of the capsule and part of the SL ligament followed by closure of the capsular defect. This is to evaluate the importance of capsular repair on the recurrence and overall hand functions.

## PATIENTS AND METHODS

This study prospectively enrolled 171 adults admitted with dorsal wrist ganglia with no underlying pathology of the wrist joint. It was conducted in Ain-Shams University Hospitals, Cairo, Egypt and Al-Hada Military Hospitals, Taif, Kingdom of Saudi Arabia. The study period was six years (from January 2006 till January 2012) with a regular follow-up of the patients postoperatively. The demographic and clinical characteristics of the patients involved in this study are shown in Table (1).

Careful history taking was done with special consideration on the main complaint, duration and if it is primary or recurrent ganglion. In most cases, patients related the etiology to be minor trauma or excessive strain over the SL ligament. A standard complete hand and wrist examination, including a range-of-motion (ROM) assessment using the Goniometer, a grip strength assessment using Jamar® Hydraulic Hand Dynamometer, key pinch strength using Jamar® Hydraulic Pinch Gauge (Fig. 1) and neurologic function testing including both motor and sensory components, were performed preoperatively. The diagnosis was done chiefly on clinical bases. A standard plain X-rays views were performed routinely to roll out any wrist pathology or SL dissociation. Patients with history of wrist diseases or any limitation in either the ROM or handgrip strength were exempted from the study. The accepted ROM was 50° in either flexion or extension and 20° in the ulnar/radial deviation axis. Power strength of the wrist was accepted according to the owner's manual provided with the dynamometer (Table 2). The patients were followed-up in the postoperative period regularly. In each visit the following data were checked; pain, recurrence, hand grip strength, key pinch power and ROM of the wrist joint using the same instruments which had been used preoperatively (Fig. 2). The time lapse between each visit was fixed for all patients. Every week in the first month, every month for the following three

months, then every six months in the remaining follow-up period.

### *Surgical technique:*

Under general anesthesia and pneumatic tourniquet to ensure a bloodless field. Loupe magnification of 3X power is used to identify the pedicle and its attachment to underlying ligaments.

The ganglion cyst is approached through a transverse incision centered directly over the cyst. In recurrent cases the approach was through the old scar after its excision (Fig. 3). Typically, a dorsal ganglion appears between the extensor pollicis longus and extensor digitorum communis tendons, which are retracted radially and ulnarly, respectively. The main cyst and its pedicle are mobilized from the surrounding tissues down to the underlying joint capsule. Careful dissection is used to avoid rupturing the cyst because this makes identification and full excision of the pedicle and capsular attachments more difficult. A curvilinear incision is made through the capsule adjacent to the cyst, along the proximal pole of the scaphoid. The capsule is elevated and retracted distally to expose the capsular attachments to the SL ligament. At this point, smaller intra-articular cysts and mucin filled duct are often seen attached to the SL ligament (Fig. 4B). The capsular incision is then continued around the stalk of the ganglion in the form of an ellipse, but all capsular attachments to the stalk are left intact. The ganglion, its pedicle and capsular attachments with the mucin duct are then tangentially excised off the SL ligament. Maintaining the integrity of the SL ligament is very important to eliminate the possibility of iatrogenic SL instability. The excised portion of the joint capsule usually measures approximately (0.5-1.0x1.5cm). Repair of the capsular defect is done transversely using absorbable 3/0 suture. The tourniquet is then released and hemostasis achieved, and then the wound is closed in layers to minimize scar formation and a bulky dressing extending from the proximal forearm to the MP joints is applied (Fig. 5). Splinting the wrist in 10-20 degrees in extension was done. The hand to be elevated and early finger motion is encouraged.

### *Postoperative care:*

The splint, dressing and sutures are removed between 7 and 10 days postoperatively. Wrist motion is initiated and encouraged, especially volar flexion, in the second week. Hand physiotherapy is continued from the third week until a full range of motion has been obtained.

## RESULTS

On analysis of the patients enrolled in this study (Table 1), it was found that dorsal wrist ganglia are more prevalent in females (70.2%) rather than males. The mean age of presentation was 28 years old. Dorsal wrist ganglia are more common in the right (most dominant) hand with a percentage of 84.2. One hundred and two patients (59.6%) presented with pain, 60 patients (35.1%) with cosmetic disfigurement and nine patients (5.3%) for fear of malignancy. Exceptionally pleasant result we obtained from analysis of the studied group is that twenty seven patients were complaining from recurrent ganglia which represented about 15.8% of all patients. This clearly reflects the magnitude of recurrence as a problem in the management of dorsal wrist ganglia.

The patients were followed-up regularly; with a mean follow-up of 23 months (3-36 months). In most patients who presented with pain preoperatively, it was disappeared. Sixty two percent of the cases suffered from pain during the active and passive ROM in the first month. This pain was significantly decreasing gradually till it was completely resolved within the following month. The remaining 38% of patients experienced the regular postoperative pain and disappeared within two weeks.

Power strength was excellent even in the first visits after removal of the splint with exact results as documented preoperatively. The same dynamometer and key pinch gauge were used to measure the postoperative values. The mean preoperative flexion was 55°, two weeks postoperative was limited to 30° and after four weeks it was raised to 45°. All patients had regained full flexion as stated preoperatively within two months (Fig. 6). Most patients resumed their work after three weeks on a light-work-basis and all of them were able to perform their complete job within six weeks.

Regarding the recurrence rate there was no even a single case of recurrence during this five-years study period. We have followed-up a large number of cases for more than two years. According to our behaviour in this study.

On macroscopic examination of the excised ganglion cysts it was noticed that most of them were multicystic rather than unilocular cyst (Fig. 7). Figs. (8-11) show some of the cases enrolled in this series.

Table (1): Demographic and clinical characteristics of the studied patients

	No.	%
Total number of involved cases	171	100
Age (in years)	16-51	Mean: 28
<i>Sex:</i>		
Male	51	29.8
Female	120	70.2
<i>Complaint:</i>		
Pain	102	59.6
Cosmetic	60	35.1
Fear of malignancy	9	5.3
<i>Type of lesion:</i>		
Primary	144	84.2
Recurrent	27	15.8
<i>Site:</i>		
Right	150	87.7
Left	21	12.3
<i>Wrist ROM and handgrip:</i>		
Intact	171	100
Limited	0	0

Table (2): Adult Data for Jamar Model SKU: 12-0600 Dynamometer, Averages of Grip Strength in kg. for Adult.

Age in years	Male, dominant hand	Male, non dominant hand	Female, dominant hand	Female, non dominant hand
20	36kg	35kg	21.5kg	19kg
25	39kg	36kg	22kg	20kg
30	40.25kg	36kg	21kg	19kg
23	39kg	35.5kg	19.5kg	18.75kg
40	37.5kg	34kg	18.5kg	17.75kg
45	35.75kg	32.5kg	17.5kg	16.75kg
50	33kg	30.25kg	17.5kg	16.5kg

Fig. (1): The instruments used in this study. From left to right: Key pinch gauge, goniometer and dynamometer.

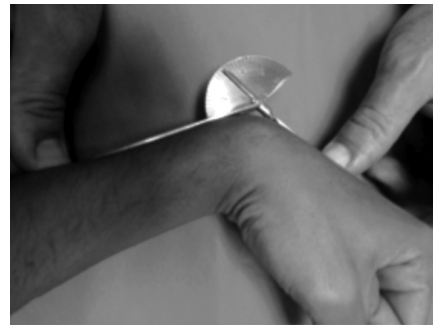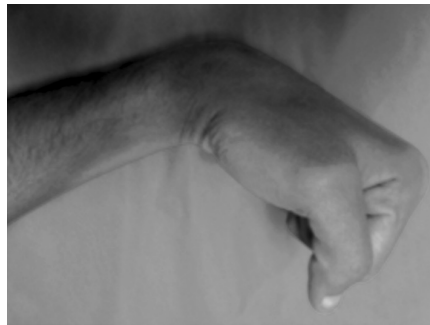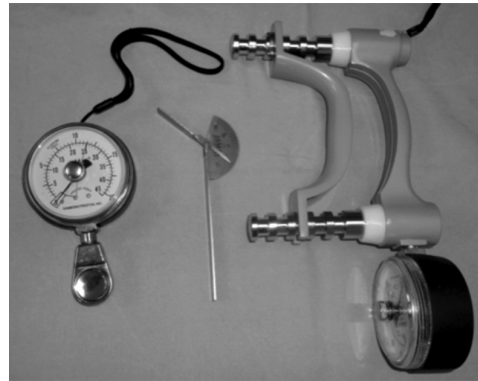


Fig. (2): Postoperative measurement of flexion degree during the postoperative visits. The recorded flexion degree (6 months postoperatively) is above 60°.

Fig. (3): A- Preoperative photo for recurrent ganglion (within 6 months of open surgical excision). B- The completely excised cyst with its stalk. C- Closing the capsular defect. D- Immediate postoperative photo.

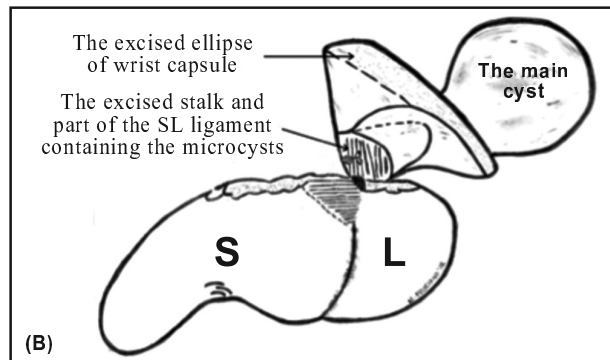
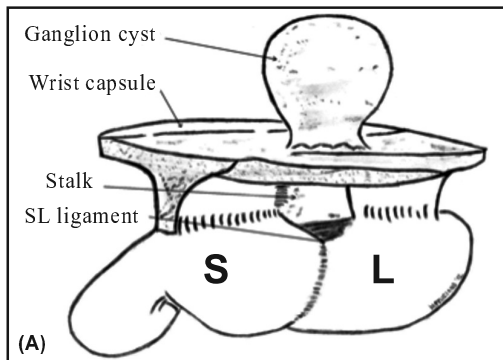
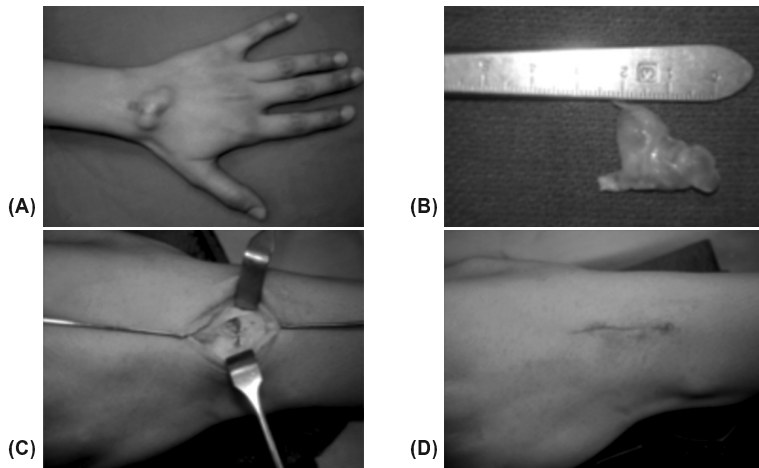


Fig. (4): A- Diagrammatic representation of the common anatomy of dorsal wrist ganglion. B- Schematic drawing of the surgical technique is illustrated.

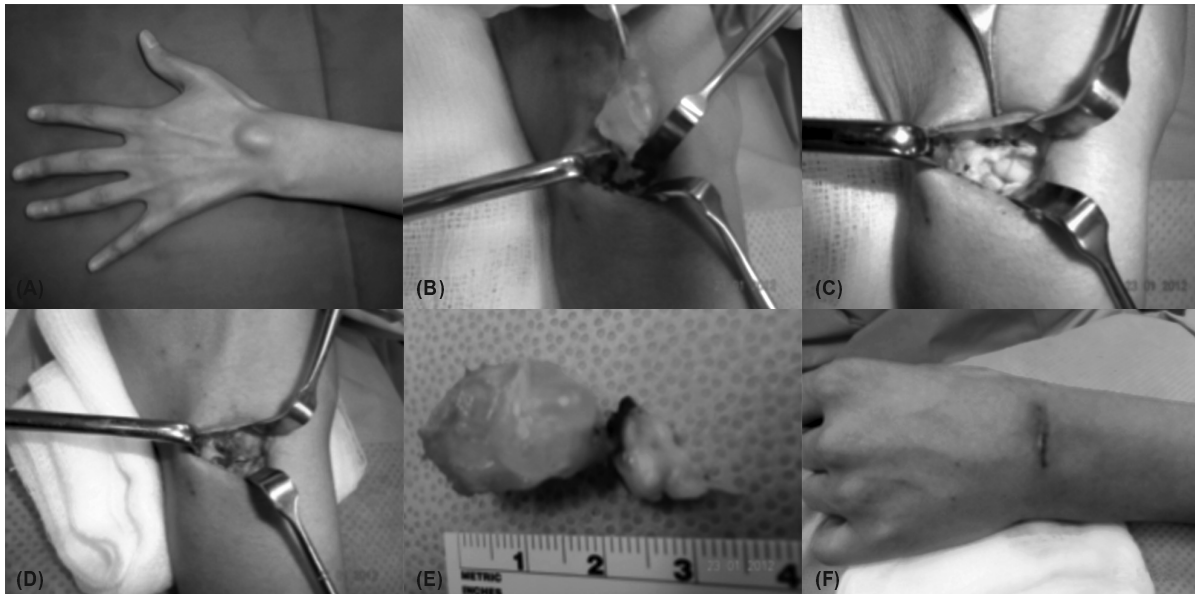


Fig. (5): Steps of surgical technique. A- A preoperative photo of dorsal wrist ganglion. B- The cyst dissected with its stalk attached to the wrist capsule, an ellipse of 0.5x1.5cm is marked around the stalk. C- The resultant capsular defect after excision, the SL joint is seen. D- Closure of capsular defect using absorbable 3/0 suture. E- The cyst is completely excised measuring almost 3cm, the ellipse of wrist capsule and attached part of SL ligament is attached to the main cyst by the stalk. F- Skin closure in two layers.

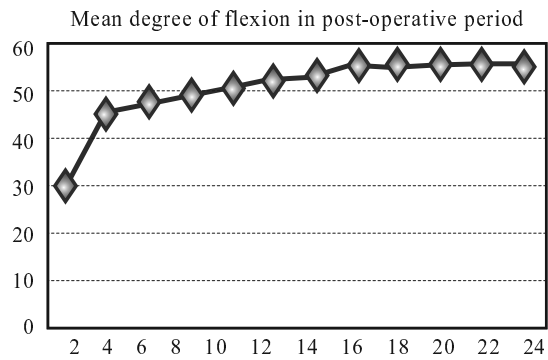


Fig. (6): Mean of flexion degrees in the post-operative course. Vertical axis represents the flexion angle degree while horizontal one is the weeks.

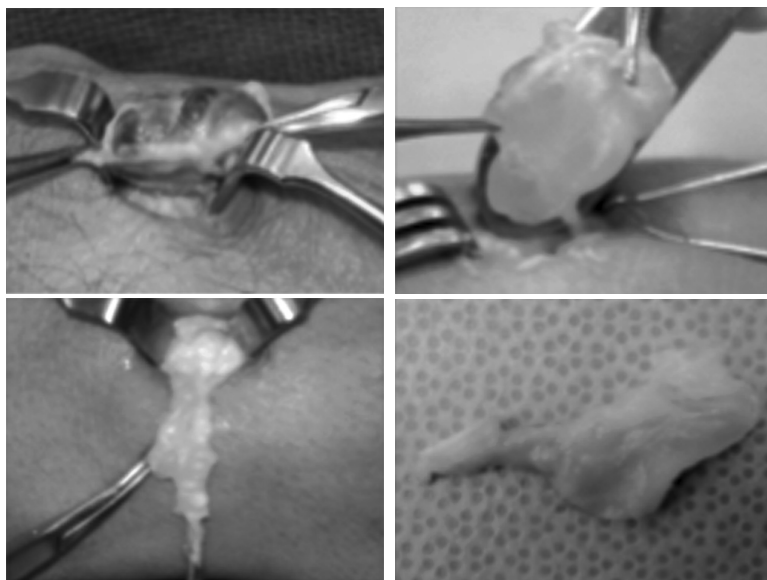


Fig. (7): Intraoperative macroscopic photos of ganglia with evident multicystic appearance.

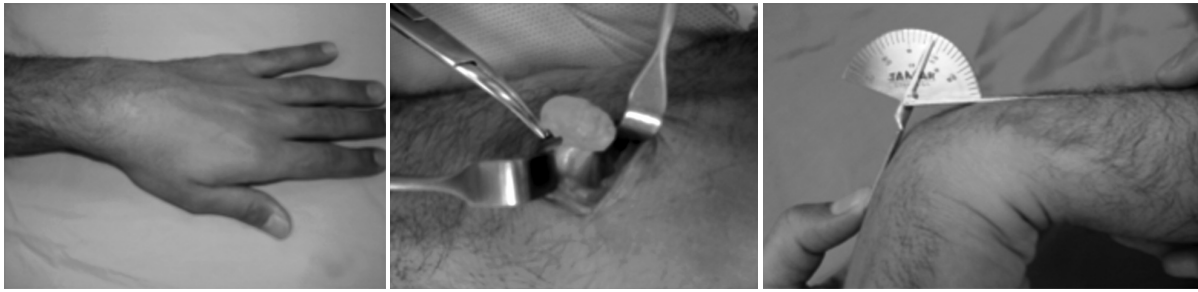


Fig. (8): A 28 year old male patient with recurrent ganglion of left wrist. Left: Preoperative. Middle: Intraoperative. Right: 2-years post operative photos showing wrist flexion more than 60°.

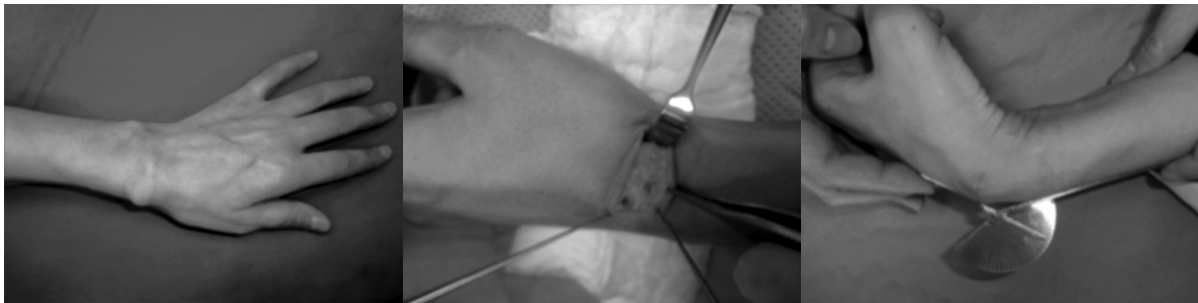

Fig. (9): Atypical serpigenous ganglion of a 37 year old lady. The main cyst is located on the radial side of the wrist whereas its stalk is passing superficial to EPL tendon and originates from SL ligament. Left: Preoperative. Middle: Intraoperative. Right: One month postoperative photos showing wrist flexion of 45°.

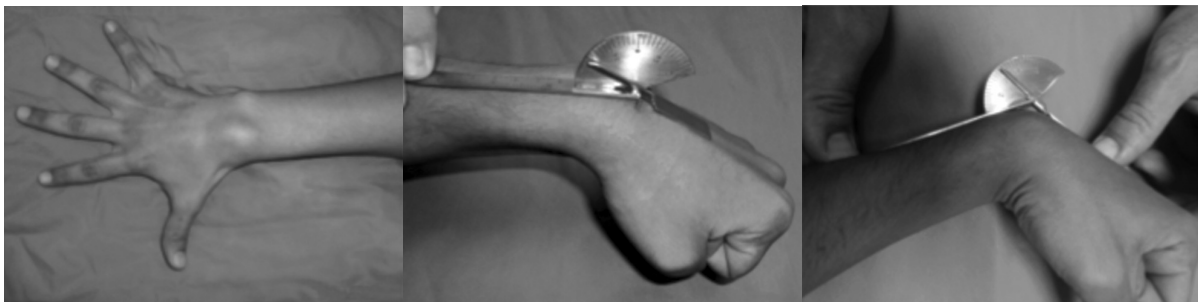

Fig. (10): A 21 year old gentleman with right wrist ganglion. Left: Preoperative photo. Middle: Two weeks postoperative photo with 30° flexion. Right: Six months postoperative photo showing wrist flexion >60°.

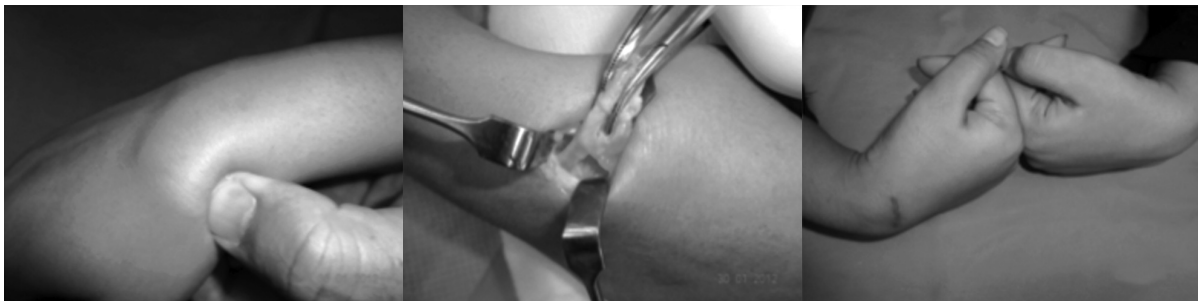

Fig. (11): A 32 year old lady with right wrist serpigenous ganglion. Left: Preoperative photo with the main cyst situated on the radial side. Middle: Intraoperative photo shows the long stalk passing over the EPL tendon. Right: Seven weeks postoperative photo shows full flexion comparable to the sound side.

## DISCUSSION

Surgical excision remains the gold standard for treatment of ganglion cysts. It improves the rate of ganglion resolution and generally provides good to excellent results, but is not an universal remedy, and thus, the development and continued use of numerous nonsurgical techniques. Prior to the work of Angelides, postoperative recurrence rates were as high as 40%, results that were rivaled by expectant management.

Since the adoption of surgical techniques recommended by Angelides and Wallace that include excision of the entire ganglion complex, with all its capsular attachments to the SL ligament including cyst, pedicle, and a cuff of the adjacent joint capsule, recurrence rates have been improved significantly. Angelides and Wallace [1] reporting a 1% recurrence rate following 346 dorsal wrist ganglion excisions. Clay and Clement [24] had a similar low recurrence rate of 3% following 62 dorsal ganglion excisions. However, there have also been many series reporting much higher recurrence rates: McEvedy [7] reported 40% recurrence following the excision of both dorsal and volar ganglia, Jacobs and Govaers [25] reported a rate of 28%. More recently Dias et al., [19] have reported a 39% recurrence rate in a six year prospective study of dorsal ganglion excision. The variability shown in the literature with regards to recurrence rates demonstrates that ganglion surgery is challenging.

Cadaveric studies [26] showed that moderate rotatory subluxation of the scaphoid was produced when the dorsal radiocarpal ligament over the SL joint and the SL interosseous ligament were excised. It is also reported the presence of rotatory subluxation of the scaphoid, years after excising the ganglion. In view of this finding, we examined the effect of closure of the wrist capsule after excision of the dorsal wrist ganglion on the recurrence rate, as by this technique the normal anatomy and physiology of the wrist joint have been restored.

One of the reasons that make most of the surgeons don't close the wrist capsule after ganglionectomy is the avoidance of stiffness of the wrist joint in extension. The powerful flexor action concomitant with the early-started postoperative physiotherapy will guard against this stiffness. This is shown in our results that all patients regained full range of motion within two months.

One hundred and seventy one consecutive adult patients were operated by the same surgeon

(senior author). Although done in two different well-equipped institutes, the same technique and instruments were used. We thought about this study after noticing no recurrence with this technique in our regular practice. So we started to document the patients with meticulous assessment of other factors preoperatively and postoperatively in a well-designed fashion.

The demographics and clinical characteristics of patients included in this study were found comparable with the other preceding studies. This is regarding the sex distribution, females were found to be more affected than males, and that the average age of the patient group was almost 28 years. In this study the mean follow up was 23 months and this was comparable to most studies, where the mean follow-up duration was 24-36 months [16,17].

In this study, we found that the main reason for doing the surgery was pain in about 59.6% of patients. In previous series, pain was present in a wide range starting from 25% up to 67% of cases [8,9] with the exception of one series reported by Clay and Clement [29] where most of their patients were suffering from pain in 87%.

There is no persistence of pain or weakness of hand grip after surgery in all our patients. Angelides and Wallace [1] reported also no persistent symptoms in any of their 346 patients and Clay and Clement [24] showed that nine patients of their fifty had a weaker grip. Dermon et al., [27] did 124 wrist ganglionectomy without repairing the dorsal defect, the improvement was noted in 92.3% of their cases but they reported 3% and 7.8% of the patients suffered from a weaker grip and a limitation of dorsiflexion, respectively.

Recently Dermon et al., [27] in 2011 had been encountered seven cases of recurrence, which is accounts for 10.6% in their study patients; this reflects that there is still significant recurrence rate with non-closure of the capsular defect. Although Carp and Staut [2] reported an excision of the cyst, less extensive capsulectomy (0.5cm<sup>2</sup>) and closure of the capsule with an absorbable suture they had encountered with a recurrence rate of 5%. On macroscopic examination of the excised recurrent cysts, we found that most of them are multicystic (Fig. 7). Probably, limited capsulectomy may leave some small capsular microcysts that were present around the stalk (Fig. 4B). This may explain their 5% recurrence found in that series. For that reason, it is recommended to do wider capsulectomy not less than 0.5-1.0x1.5cm as stated in our operative technique.

According to our finding, we had operated on 27 cases of recurrent dorsal wrist ganglia (15.8% of the study group). None of them had their wrist capsules repaired on reviewing their previous operative reports in their files. The recurrence rate was 0% even in those cases done with recurrent ganglia.

In conclusion, meticulous dissection of the cyst with its stalk, adequate elliptical excision of wrist capsule around the stalk, limited excision of part of SL ligament directly attached to the capsule followed by closure of the capsular defect will guard against recurrence and ensure intact full hand functions.

### REFERENCES

- 1- Angelides A.C. and Wallace P.F.: The dorsal ganglion of the wrist: Its pathogenesis, gross and microscopic anatomy, and surgical treatment. *J. Hand Surg.*, 1: 228-35, 1976.
- 2- Carp L. and Stout A.P.: A study of ganglion, with special reference to treatment. *Surg. Gynecol. Obstet.*, 47: 460-8, 1928.
- 3- Soren A.: Pathogenesis and treatment of ganglion. *Clin. Orthop.*, 48: 173-179, 1966.
- 4- Psalia J.V. and Mansel R.E.: The surface ultrastructure of ganglia. *J. Bone Joint. Surg. Br.*, 60B (2): 228-33, 1978.
- 5- Loder R.T., Robinson J.H., Jackson W.T. and Allen D.J.: A surface ultrastructure study of ganglia and digital mucous cysts. *J. Hand Surg.*, 13 (5): 758-62, 1988.
- 6- Gude W. and Morelli V.: Ganglion cysts of the wrist: Pathophysiology, clinical picture, and management. *Curr. Rev. Musculoskelet Med.*, 1: 205-11, 2008.
- 7- McEvedy B.V.: The simple ganglion: a review of modes of treatment and an explanation of the frequent failures of surgery. *Lancet*, 266: 135-6, 1954.
- 8- Nelson C.L., Sawmiller S. and Phalen G.S.: Ganglions of the wrist and hand. *J. Bone Joint. Surg. Am.*, 5: 1459-64, 1972.
- 9- Holm P.C.A. and Pandsey S.D.: Treatment of ganglia of the hand and wrist with aspiration and injection of hydrocortisone. *The Hand*, 5: 63-8, 1972.
- 10- Derbyshire R.C.: Observation on the treatment of ganglia. With a report on hydrocortisone. *Am. J. Surg.*, 112: 635-6, 1973.
- 11- Varley G.W., Needoff M., Davis T.R. and Clay N.R.: Conservative management of wrist ganglia. Aspiration versus steroid infiltration. *J. Hand Surg. [Br.]*, 22: 636-7, 1997.
- 12- Richman J.A., Gelberman R.H., Engber W.D., Salamon P.B. and Bean D.J.: Ganglions of the wrist and digits: Results of treatment by aspiration and cyst wall puncture. *J. Hand Surg. [Am.]*, 12: 1041-3, 1987.
- 13- Nield D.V. and Evans D.M.: Aspiration of ganglia. *J. Hand Surgery. J. Hand Surg. [Br.]*, 11: 264, 1986.
- 14- Zubowicz V.N. and Ishii C.H.: Management of ganglion cysts of the hand by simple aspiration and cyst wall puncture. *J. Hand Surg.*, 12A: 618-20, 1987.
- 15- Ho P.C., Lo W.N. and Hung L.K.: Arthroscopic resection of volar ganglion of the wrist. A new technique. *Arthroscopy*, 19: 218-21, 2003.
- 16- Mathoulin C., Hoyos A. and Pelaez J.: Arthroscopic resection of wrist ganglia. *Hand Surg.*, 9: 159-64, 2004.
- 17- Rocchi L., Canal A., Fanfani F. and Catalano F.: Articular ganglia of the volar aspect of the wrist: Arthroscopic resection compared with open excision. A prospective randomised study. *Scan. J. Plast. Reconstr. Surg. and Hand Surg.*, 42: 253-9, 2008.
- 18- Luchetti R., Badia A., Alfarano M., et al.: Arthroscopic resection of dorsal wrist ganglia and treatment of recurrences. *J. Hand Surg.*, 25B: 38-40, 2000.
- 19- Dias J.J., Dhukaram V. and Kumar P.: The natural history of untreated dorsal wrist ganglia and patient reported outcome 6 years after intervention. *J. Hand Surg. Eur. Vol.*, 32: 502-8, 2007.
- 20- Faithfull D.K. and Seeto B.G.: The simple wrist ganglion- more than a minor surgical procedure? *Hand Surg.*, 5: 139-43, 2000.
- 21- Dias J. and Buch K.: Palmar wrist ganglion: Does intervention improve outcome? A prospective study of natural history and patient reported treatment outcomes. *J. Hand Surg. [Br.]*, 28: 172-6, 2003.
- 22- Pederzini L., Ghinelli L. and Soragni O.: Arthroscopic treatment of dorsal arthrogenic cysts of the wrist. *J. Sports Traumatol and Related Res.*, 17: 210-15, 1995.
- 23- Razemon J.P.: Surgical treatment of ganglions of the wrist by partial excision of the joint capsule: Report on 303 cases. *Ann. Chir. Main.*, 2 (3): 230-43, 1983.
- 24- Clay N.R. and Clement D.A.: The treatment of dorsal wrist ganglia by radical excision. *J. Hand Surg.*, 13 (2): 187-91, 1988.
- 25- Jacobs L.G. and Govaers K.J.: The volar wrist ganglion: Just a simple cyst? *J. Hand Surg. [Br.]*, 15: 342-6, 1990.
- 26- Ruby L.K., An K.N., Linscheid R.L., Cooney W.P. 3<sup>rd</sup> and Chao E.Y.: The effect of scapholunate ligament section on scapholunate motion. *J. Hand Surg. Am.*, 12 (5 Pt 1): 767-71, 1987.
- 27- Dermon A., Kapetanakis S., Fiska A., Alpantaki K. and Kazakos K.: Ganglionectomy without Repairing the Bursal Defect: Long-term Results in a Series of 124 Wrist Ganglia. *Clinics in Orthopedic Surgery*, 3: 152-6, 2011.