

## Mammoplasty in MWL Patients Biological Implant Versus Synthetic Implant

SAMEH EL NOAMANI, M.D.\*; ASHRAF A. KHALIL, M.D.\*; HAMED M. KADRY, M.D.\* and MOHAMAD FAROUK, M.D.\*\*

*The Department of Plastic Surgery, Faculty of Medicine, Cairo\* and Beni-Suef\*\* Universities*

### ABSTRACT

Breast auto-augmentation uses a woman's own breast tissue to optimize breast shape and projection. Additionally, it incorporates mastopexy techniques to correct any sagging in the breasts and remove excess skin. In many patients, mastopexy alone improves the shape of the breast but does not necessarily achieve the degree of upper breast fill the patient desires. It is therefore, advisable to use a breast implant to improve the shape of the ptotic breast following massive weight loss (MWL) and to provide more youthful upper pole fullness. This solution, however, introduces the possible concerns, objections, and complications associated with breast implants. Our study aims at comparing results of augmentation mastopexy in massive weight loss patients either by rearrangement of local breast tissues or by further introducing an implant. During our study, clinical analysis and algorithmic approach was introduced for proper dealing with cases of breast ptosis following massive weight loss.

*Patients and Methods:* We started our retrospective study in August 2012 reviewing 50 patients done at Kasr Elainy University Hospitals, and some private practice of the authors from December 2008 to January 2012 with history of massive weight loss (MWL). Patients were divided into 2 groups (Groups A and B). Group A patients who are grade 2 (atrophic ptotic breasts) were scheduled for breast implant augmentation with mastopexy, while Group B patients who are grade 3 (apparently adequate volume with ptotic breasts) were divided randomly into two groups that scheduled for breast implant augmentation with mastopexy and the other group were scheduled for autoaugmentation procedure.

*Results:* In this series, complications were observed more frequently in patients who underwent a mastopexy with implant augmentation. An average of one third of patients who were scheduled for vertical mastopexy with implant augmentation suffered some form of postoperative complication. Patients who underwent breast autoaugmentation suffered much less complication rates. Thus, breast reshaping with mastopexy and augmentation with autologous tissues have significant advantages in terms of safety with less complications. However, number of patients who underwent implant augmentation mastopexy was almost double the number of those underwent autoaugmentation though their number was nearly equal.

*Conclusion:* Implant mastopexy, though more risky, it is more cosmetic, with long lasting results. Auto-augmentations

carries the lowest risk, though it is not long lasting procedure, may turn out to bottoming and pseudo-ptotic breasts. We believe that a multidisciplinary approach is best. Centres of excellence are clearly the future for this sub-specialty within plastic surgery, as facilities, trained staff and time are needed to maximise efficiency, safety and improved outcomes. Large volume work will allow research and expertise to develop with time. In the future, the birth and the rise of new mammary implant concepts and technologies could completely change the concept of breast autoaugmentation of the massive weight loss breast.

### INTRODUCTION

Breast surgery in massive weight loss (MWL) patients is an artistic endeavor, an exercise in right-brain creativity. Clarification of patient expectations and knowledge of individual anatomic characteristics are critical to the surgical plan, but ultimately it is an internalized vision of what is normal and aesthetically pleasing that guides the procedure [1].

Although the breast represents only one aspect of the massive weight loss patient, the deformity is often complex, blending into the upper abdomen, lateral chest, and arm. The long, deflated, ptotic breast following massive weight loss is still poorly understood, and although we are familiar with intricacies related to breast ptosis as the result of age, pregnancy, and gravity, those following massive weight loss pose additional challenges [2].

Surgeons' tools are tissue, muscle, and skin, and every incision or transfer of tissue results in scars and changes that cannot be erased. Furthermore, each patient heals in a unique manner. Surgeons must understand how each procedure affects healing and the result as it "ages". After breast implant surgery, the tissue ages differently than after autologous flap procedures. Unilateral procedures, particularly with implants, also produce longitudinal aging disparities [3].

Breast auto-augmentation uses a woman's own breast tissue to optimize breast shape and projection. Additionally, it incorporates mastopexy techniques to correct any sagging in the breasts and remove excess skin. The procedures are also referred to as breast lift with autoaugmentation or breast autoaugmentation-mastopexy because it augments and lifts the breasts [4].

In many patients, mastopexy alone improves the shape of the breast but does not necessarily achieve the degree of upper breast fill the patient desires. It is therefore, advisable to use a breast implant to improve the shape of the ptotic breast following massive weight loss (MWL) and to provide more youthful upper pole fullness, and add an element of permanence to the correction while minimizing the length of the mastopexy scars [5].

This solution, however, introduces the possible concerns, objections, and complications associated with breast implants [6].

Our study aims at comparing results of augmentation mastopexy in massive weight loss patients either by rearrangement of local breast tissues or by further introducing an implant. During our study, clinical analysis and algorithmic approach was introduced for proper dealing with cases of breast ptosis following massive weight loss.

## PATIENTS AND METHODS

We started our retrospective study in August 2012 reviewing 50 patients done at Kasr Elainy University Hospitals, and some private practice of the authors, period from December 2008 to January 2012 with history of massive weight loss.

All patients included in this study were seeking for body contour improvements after massive weight loss, and they were weight stable for at least 6 months.

All the patients underwent a general medical examination. None of these patients had any major medical condition that might be a contraindication for a longer surgical procedure (all patients were at least New York Heart Association classification II).

We excluded all smokers and those whose general conditions didn't allow for such procedures, as well as, patients with BMI less than 30kg/m<sup>2</sup>.

Finally we were left with 43 patients whose deformities were ideal for breast reconstructive

procedures with breast lift associated with either auto-augmentation or implant augmentation.

*Physical examination of the breast:* Included the breast and axilla for masses, tenderness, and induration.

*Evaluation of body-contour deformities of the breasts consisted of determining two factors:*

- Degree and quality of skin excess or deficiency, and
- Degree of content (fat and glandular tissue in breast) excess or deficiency.

*The following measurements were recorded:*

- Sternal notch and/or mid-clavicle to nipples.
- Nipples to midline.
- *Extent of ptosis:* Either the degree and/or measurement from nipple to inframammary fold and inframammary fold to lowest point of the breast.
- Determination whether the native breast parenchyma and lateral roll together will provide adequate volume for breast reshaping procedure, either subjectively or objectively.
- Pinch testing of the breast substance.

Patients' demographics included age, body mass index at the time of mammoplasty, weight loss, risk factors, nipple to notch measurements, and degree of ptosis.

All 43 patients presented with breast ptosis and volume loss Pittsburgh Scale Grade 2 or 3, and requested both larger and uplifted breasts, necessitating a combined mastopexy/breast augmentation.

Patients were divided into 2 groups (Groups A and B). Group A patients who are grade 2 (atrophic ptotic breasts) were scheduled for breast implant augmentation with mastopexy, while Group B patients who are grade 3 (apparently adequate volume with ptotic breasts) were divided randomly into two groups that scheduled for breast implant augmentation with mastopexy and the other group were scheduled for autoaugmentation procedure.

Among each group, patients were re-assessed for the degree of breast ptosis, the size of the native breast parenchyma, and pinching test for breast thickness.

Photographs were taken from several views as part of the physical examination.

All patients consented to a standardised clinical and photographic work-up. An extensive informed

consent took place, with particular attention to outlining realistic outcomes expectations.

The operative data points included skin takeout pattern, weight of tissue resected, and the type of pedicle used.

While selecting the technique, patients are divided into two groups:

*In Group A patients, patients were further subdivided according to our clinical analysis to three groups:*

Group I: Whom ptosis is lower than 2cm that underwent two management lines:

- A- Who underwent dual plane augmentation mammoplasty (when pinching test is less than 3cm).
- B- Who underwent crescent augmentation mastopexy (when pinching test is greater than 3cm).

Group II: Whom ptosis degree from 2 to 4cm who underwent circumareolar augmentation mastopexy.

Group III: Whom ptosis degree is greater than 4 cm who underwent circumvertical augmentation mastopexy.

*In Group B patients, that were randomly divided into two groups:*

Group I: Whom underwent auto-augmentation mammoplasty (biological implant).

Group II: Whom underwent implant augmentation mastopexy following the same algorithm like Group A patients putting in mind the Addition Subtraction Concept.

*Breast auto-augmentation techniques:*

- Dermal suspension/parenchymal reshaping and selective autoaugmentation.
- Superior or superomedial flap technique with keeping the inferior portion for augmentation.
- Circumvertical superiorly based flap mastopexy with implant augmentation.
- Estimation of the volume of the implant.

To estimate the patient's current breast size, measurements were taken with the patient wearing a soft, non-padded bra. The following measurements were required:

- 1- Chest circumference at the IMC (in inches).
- 2- Chest circumference at nipple level (in inches).

*To estimate the cup size, we used measurements 1 and 2 as follows:*

- The strap size is determined by adding 5 in to

the chest circumference at the IMC; i.e., if the measurement is 29 inches, the strap size would be  $29+5=34$ .

- The cup size is the difference between the chest measurement at the nipple level and the IMC, with a difference of 5 in equal to an A cup and each additional inch another cup. A difference of 4 inches would be a AA cup, and a difference of 3 inches a AAA cup. If the IMC measurement is 29 inches and the nipple level circumference is 36 inches, this would be  $36-29=7$ , or a C cup. When less than 5 inches, divide the A cup by 2 for a AA cup (100 grams) or by 3 for a AAA cup (80 grams).

In the average case, every cup size for a bras-siere was an increment of 200ml of implant or grams of breast tissue, so an A cup would be 200g, a B cup 400g, a C cup 600g, and so on.

We used these measurements to plan the size and base diameter of the implant as simple addition. We also tried to estimate the amount of breast tissue to be removed as this will, of course, affect the final breast volume. We guessed within a half cup size (100 grams) and added this to the implant size.

*Implant placement:*

We made a decision to use a totally submuscular pocket for implant placement in all cases undergoing vertical mastopexy-augmentation in an attempt to minimize the "bottom out" of the implant over time.

To minimize the descent of the breast over the muscle, we maximized the breast tissue removed so that the remaining breast (without an implant) would be reduced to 200-300g (A/B cup). Therefore, our submuscular implants were never larger than 350ml.

In cases undergoing Wise mastopexy-augmentation, we decided to choose the submuscular implants because postbariatric patients present a special dilemma. Their severe evolution favors submuscular implant position as a consequence of poor soft tissue.

The placement of the implant in other techniques depend on the pinching test of the breast fold.

*Implant type, shape and texture:*

All implants used in our thesis were silicon filled, high profile, cohesive gel, and rounded

*Postoperative evaluation:**Early postoperative:*

Recording the operative complications either major or minor.

*Late postoperative:*

An objective and subjective comparisons were done between the implant using technique versus the biological implant technique:

*Subjectively:* With help of a direct patient questionnaire, patients in whom the procedure had been performed more than six months previously were asked to informally evaluate their aesthetic result, based on a series of parameters including volume, symmetry, shape of the breast mound, and symmetry of the nipple-areola complex, as follows:

- Five = Excellent.
- Four = Good.
- Three = Fair.
- Two = Mediocre.
- One = Poor.

*Objectively:* A panel formed of three consultants of plastic surgery was held to compare both techniques evaluating: Symmetry, NAC position, axis, and size, NAC to IMF distance, IMF position, Ratio between the supra areolar to infra areolar areas, breast contouring and size, breast consistency and scarring problems.

## RESULTS

A total of 50 post-bariatric surgery massive weight loss patients were counselled initially to choose 43 MWL patients with the following characteristics:

- Suitable breast deformities (breast ptosis and volume loss Pittsburgh Scale Grade 2 or 3).
- Have major concerns about their current breast shape, and
- Consider breast reshaping as their top priority following massive weight loss.

Patients were divided into 2 groups (Groups I and II). Group I patients were scheduled for breast implant augmentation with mastopexy, while Group II were randomly divided into two groups either patients were scheduled for an auto-augmentation procedure or implant augmentation with mastopexy, among each group, patients were re-assessed for the degree of breast ptosis and the size of the native breast parenchyma (Table 1).

We made our decision to use a submuscular pocket versus subglandular pocket according to pinching testing.

Group A and Group B patients were evaluated individually and both techniques in each group were compared in terms of cosmetic appearance, incidence of complications, and patient's satisfaction.

The outcome data were collected together with complications and the need for revisional surgery.

*Subjective assessment of postoperative results:*

23 patients got 5/5, 7 patients got 4/5, 6 patients got 3/5, 5 patients got 2/5, while 20 patients got 1/5.

The 23 patients who were excellent were: 15 patients who inserted implants while the remaining 8 patients underwent mastopexy alone.

The 20 patients who were criticized by patients by a way or another (15 patients without implants and 5 patients with implants).

*Objective assessment of postoperative results:*

18 patients got 5/5, 12 patients got 4/5, 8 patients got 3/5, while 5 patients got 2/5.

Table (1): Surgical procedures in both groups.

Group A (Implant technique)		Group B (Autoaugmentation procedures)	
Technique	No. of Patients	Technique	No. of Patients
Crescent mastopexy	3	Dermal suspension with parenchymal reshaping	5
Dual plane augmentation mammoplasty	5	Superior pedicle with inferior augmenting one	10
Circumareolar aug- mentation mastopexy	5	Circumvertical mastopexy	5
Circumvertical aug- mentation mastopexy	10		

Table (2): Postoperative complications in both groups.

Postoperative complications	
Implant technique	Non implant technique
NAC partial loss: 2 patients	NAC partial loss: 2 patients
Implant extrusion: 1 patient	Mild infection: 17 patients
Capsular contracture: 4 patients	
Mild wound infection: 10 patients	

Table (3): Subjective assessment of postoperative results in both groups.

Group A		Group B	
Points of dissatisfaction	No. of Patients	Points of dissatisfaction	No. of Patients
Asymmetry	2	Asymmetry	1
Volume dissatisfaction	5	Contour dissatisfaction	1
Contour dissatisfaction	4	Asymmetrical NAC	2
Asymmetrical NAC	1	> one factor	1
> one factor	3		

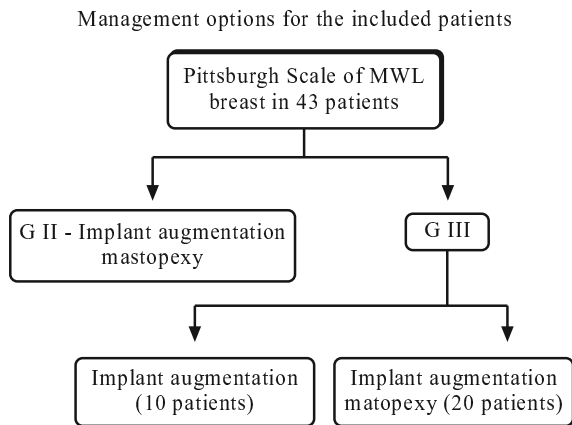


Fig. (1): Management options.

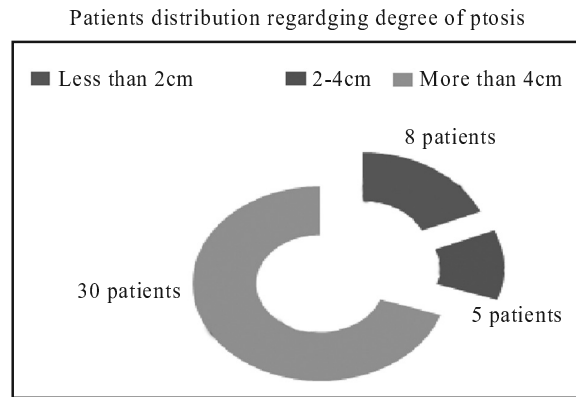


Fig. (2): Patient distribution regarding ptosis degree.

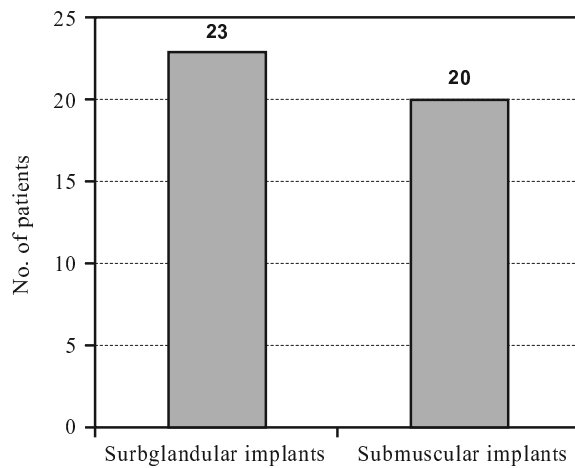


Fig. (3): Plane of implant insertion.

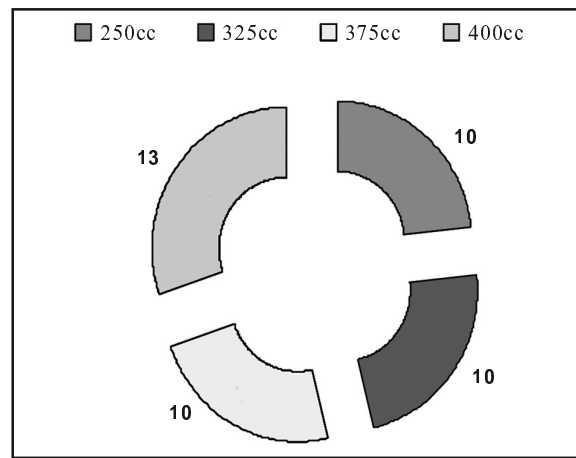
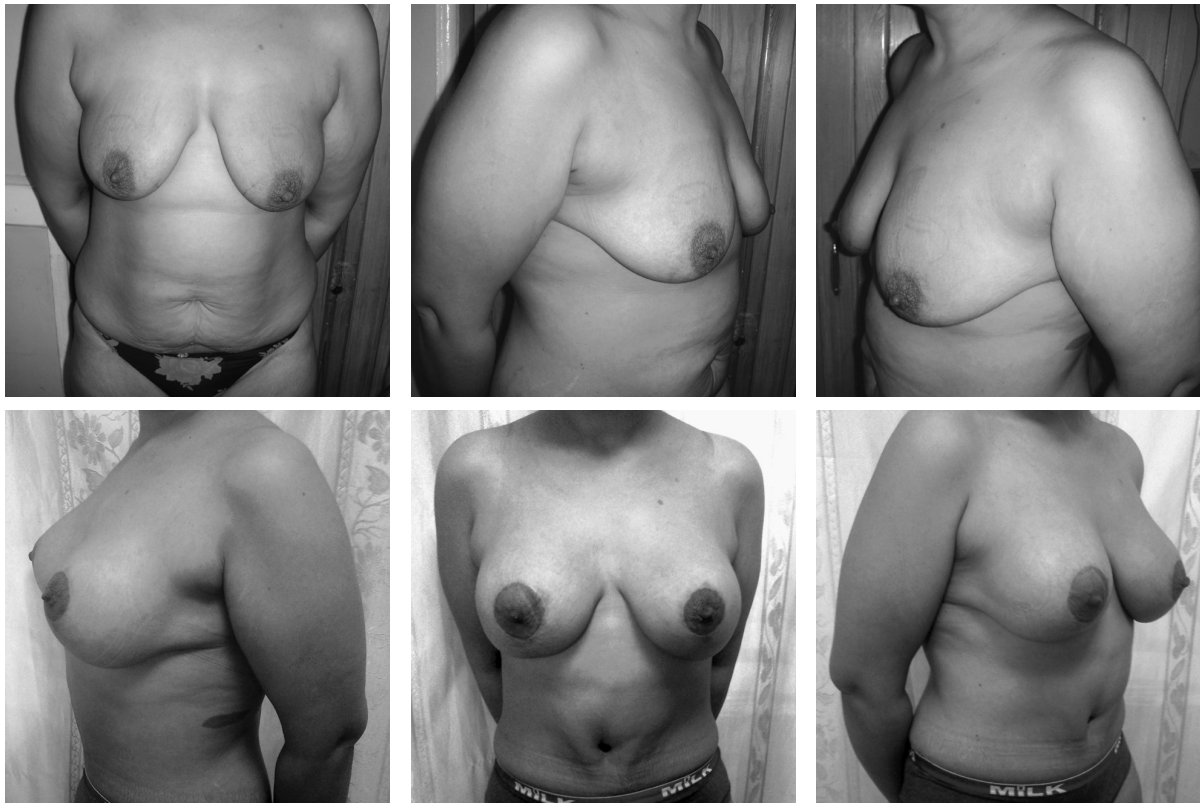
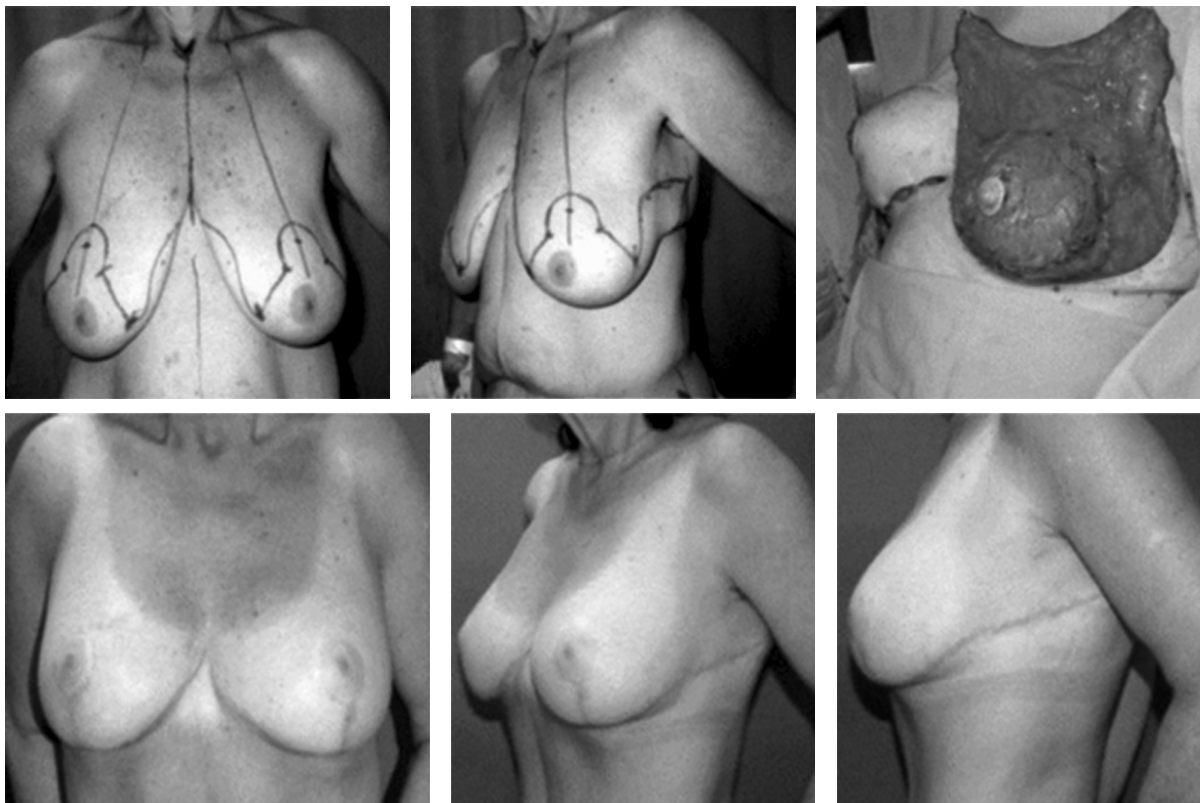


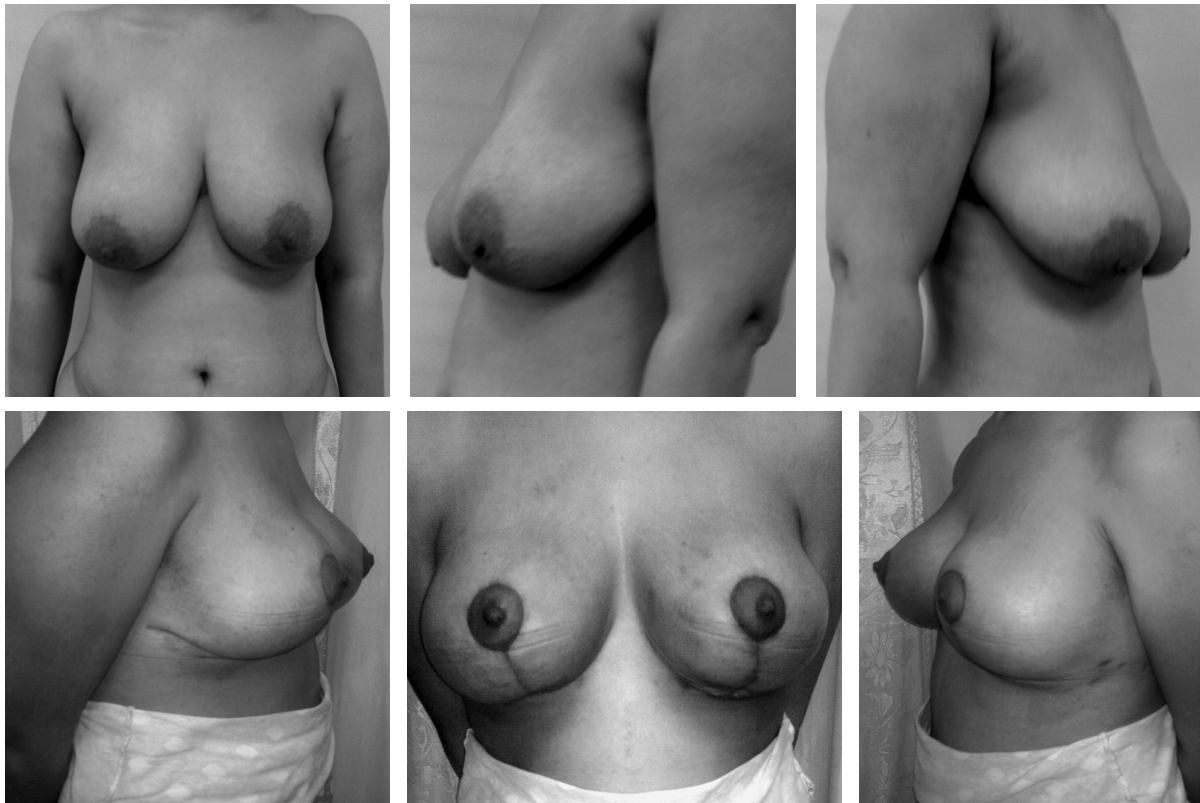
Fig. (4): Implants sizes used in the study.



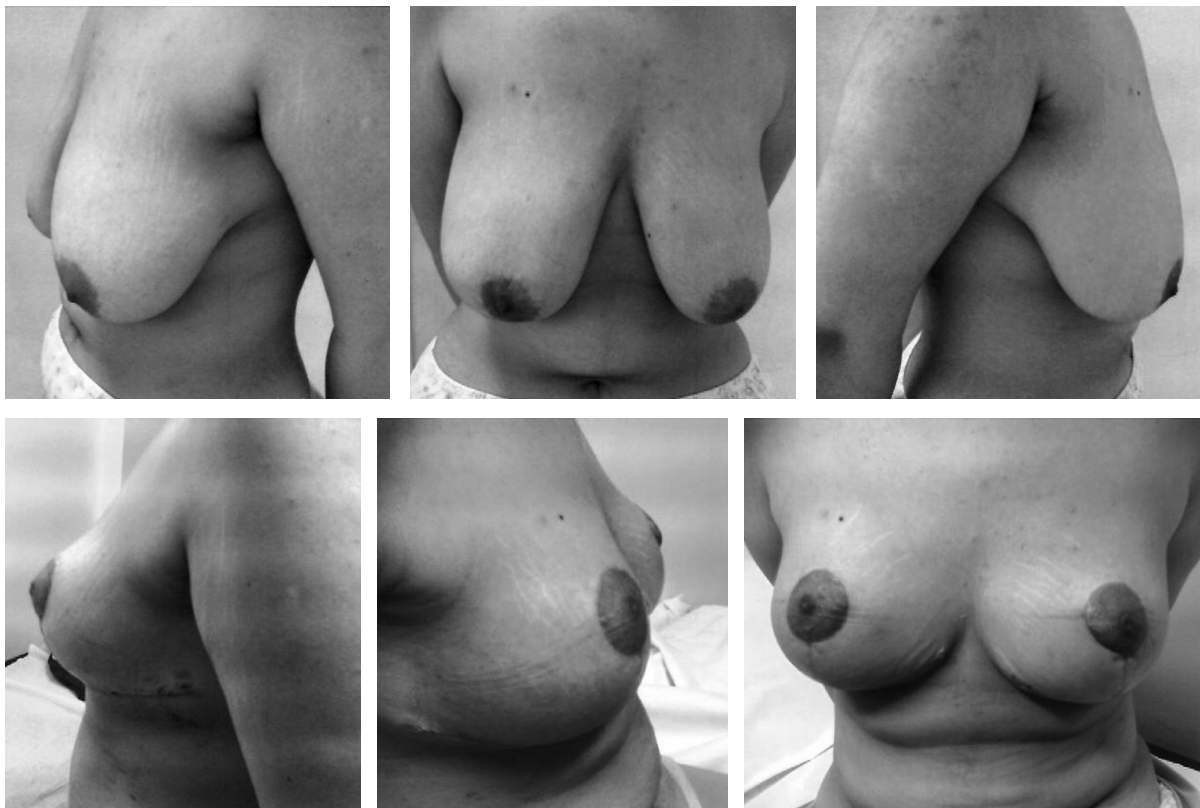
Case (1): Circumvertical augmentation mastopexy pre- and postoperative photos.



Case (2): Rubin's autoaugmentation pre- and postoperative photos.



Case (3): Circumvertical mastopexy pre- and postoperative photos.



Case (4): Superior pedicle and inferior portion auto augmentation pre- and postoperative photos.

## DISCUSSION

Breast and body contouring following massive weight loss is on the rise. Although the breast represents only one aspect of the massive weight loss patient, the deformity is often complex, blending into the upper abdomen, lateral chest, and arm [2].

The typical "cosmetic surgery" patient without a history of substantial weight loss has areas of moderate fat excess with minimal skin excess, and is adequately treated with minimally invasive procedures, such as liposuction, allowing the elastic properties of skin to resolve the residual minor skin excess.

In contrast, areas of major skin excess, such as those seen in the MWL patient, do not contract adequately to achieve a reasonable cosmetic result with minimally invasive methods, necessitating excisional procedures.

Massive weight loss following bariatric surgery frequently results in body contour deformities such as ptotic with or without hypoplastic breasts. In addition, redundant skin and subcutaneous tissue often develops in the lateral thoracic and axillary regions of such patients. This excess tissue can be useful for autogenous breast augmentation in patients after massive weight loss. However, the implant usage may be of importance as an adding volume factor [7].

The types of breast deformities seen following massive weight loss are relatively new, and to best manage these patients and assess outcomes, it is important that we understand the defect.

Classification systems exist for breast ptosis; however, these are based mainly on nipple position. The degree of ptosis following massive weight loss has both a glandular component and a true ptosis component, stressing the importance of evaluating not only the nipple position but the gland and skin envelope as well [8].

The Pittsburgh Rating Scale has recently been developed to measure contour deformities following massive weight loss, with potential applications in preoperative planning and evaluating results. However, assessing the breast deformities and evaluating long-term results remains a challenge and will always have a certain degree of subjectivity.

The goals of both reconstructive and aesthetic breast surgery are to meet size and shape expecta-

tions, preserve function, achieve symmetry, and minimize scars [9].

The surgical reshaping of these breasts often requires dramatic skin resection, coupled with parenchymal shaping, incorporating suture plication and suspension techniques to achieve attractive long-term results.

The maintenance of shape over time might best be demonstrated by longitudinal evaluation of results of three-dimensional images of the breast and comprehensive yet easy-to-use rating scales. [10].

Reports of procedures for breast lifts appeared as early as the 1950s; however, no reliable method of breast augmentation was available until Cronin and Gerow, with the help of Dow Corning Corporation, brought the Silicone gel breast implant to the medical marketplace in 1963 [11].

Spear and others have written of complications encountered due to combining the two procedures of breast augmentation and mastopexy; these include nipple-areolar necrosis, implant malposition, contour deformities, poor scarring, and implant infections [12].

Many plastic surgeons have advised against performing these two procedures simultaneously. However, when they are done as a single procedure, excellent results can be obtained, and this practice is preferred by patients as being less expensive and less inconvenient than staged procedures [13].

Mastopexy with implant augmentation in the MWL patient is an operation of temporal value meant to restore a youthful, uplifted appearance to the MWL breast that have sagged and lost its shape. The improvement effect is usually not a lasting one. Time and gravitational forces eventually reverse some of the tightening and elevation produced by surgery [14].

In our study we performed mastopexy with implant augmentation in 23 patients and depending on the degree of breast ptosis, we used the crescent mastopexy, dual plane mastopexy, circumareolar mastopexy or vertical mastopexy-augmentation following the criteria of pittsburgh scale, however dual plane mastopexy as a useful technique for mild cases with severely atrophic breast is considered in our thesis.

The decision regarding implant placement, submuscular versus subglandular, also must be made. In a very thin woman with small atrophic and ptotic breasts, submuscular placement is



favoured, and in a woman with ptotic B cup, the subglandular route could be more appropriate.

However, it is preferable to use a totally submuscular pocket because if the musculofascial attachments are maintained, the implant will not “bottom out” over time [15].

To minimize the descent of the breast over the muscle, one should maximize the breast tissue removed so that the remaining breast (without the implant) would be reduced to 200-300g [16]. In our thesis, this fact was used to introduce the implant concept in even grade 3 pittsburgh scale system depending on the technique of addition subtraction.

When the augmentation is intended to correct breast ptosis, the implant is best positioned in the subglandular plane, providing upper pole fullness and definition to the inframammary crease. If the implant is placed in a submuscular position without associated skin resection, a tight lower subpectoral pocket can restrict proper descent of the implant and the breast parenchyma may rotate over it, creating a double-bubble deformity [17].

We made a decision to use a totally submuscular pocket for implant placement in all cases undergoing vertical mastopexy-augmentation in an attempt to minimize the “bottom out” of the implant over time giving a more durable effect.

To minimize the descent of the breast over the muscle, we maximized the breast tissue removed so that the remaining breast (without an implant) would be reduced to 200-300g (A/B cup). Therefore, our submuscular implants were never larger than 350ml.

Often the use of an implant in a mastopexy or reduction will do as much to improve the shape as to increase the size. In fact, with proper planning, the implant can add longevity to the early result. Choosing the proper technique can be daunting to the novice.

Patients with breast ptosis subsequent to massive weight loss, who are subjected to mastopexy and augmentation with implants, experience a high incidence of complications. In addition, in some cases, precise implant positioning to produce an aesthetically pleasing long-term result can be very challenging because of the skin excess of the ptotic breast as well as the unsatisfactory volume of covering tissues [18].

In this series, complications were observed more frequently in patients who underwent a mas-

topexy with implant augmentation. An average of one third of patients who were scheduled for vertical mastopexy with implant augmentation suffered some form of postoperative complication.

Patients who underwent breast auto-augmentation using either dermal suspension/total parenchymal reshaping, superiorly based flaps together with inferior portion auto-augmentation or vertical mastopexy techniques suffered much less complication rates.

Thus, breast reshaping with mastopexy and augmentation with autologous tissues have significant advantages in terms of safety with less complications.

In our study, we excluded all patients with ongoing weight loss but still obese, history of tobacco smoking, active skin infection, as well as, any medical condition that might endanger the outcome of the procedure.

According to Rubin, the technique of dermal suspension and parenchymal reshaping has proved to be very safe and reliable [19]. Although, in our study, this technique was only confined to cases with massive fibroadenosis that might hinder folding of a superiorly based flap.

The superomedial flap rotation-advancement technique has been used to reshape the ptotic deflated breast following massive weight loss.

This technique has been inspired by necessity and applied to the massive weight loss patient based on many of the basic concepts and principles as discussed by Lejour and Hall-Findlay [20].

According to Losken 2007, the superomedial technique has proven to be a reliable and versatile technique, with the benefits for various aspects of the massive weight loss breast deformity being numerous [9].

The ability to use the vascularised extension of the superomedial pedicle to autoaugment the upper pole provides fullness to an area that is often devoid of volume and otherwise difficult to full without implants. The rotation of this extended superomedial pedicle provides a parenchymal defect in the inferior pole that is then amenable to parenchymal plication and lateral breast advancement [9].

The importance of this is especially magnified in the massive weight loss patient where any reliance on the inelastic skin envelope for breast reshaping will invariably contribute to recurrence

of breast ptosis. The skin envelope is very relaxed, with the skin being thin and atrophic.

These principles are not new, as Lejour recognized the importance of such glandular suturing [21].

Although this technique is applicable through the vertical pattern in patients with lesser deformities and relatively good skin quality, the majority will require a Wise pattern skin takeout to address the lateral chest wall deformity.

Additionally, transfer of tissue from the lateral thoracic region on large dermal pedicles has been described without identification or dissection of axial blood vessels (Rubin; 2006).

The introduction of the perforator concept in flap surgery has resulted in significant progress in the field of reconstructive surgery during the last decade; however, our area of expertise in breast reconstruction following massive weight loss at Kasr Alainy Hospitals does not include these types of reconstructive procedures.

#### *Conclusion:*

Implant mastopexy, though more risky, it is more cosmetic, with long lasting results. Auto-augmentations carries the lowest risk, though it is not long lasting procedure, may turn out to a bot-toming and pseudo-ptotic breasts.

We believe that a multidisciplinary approach is best. Centres of excellence are clearly the future for this sub-specialty within plastic surgery, as facilities, trained staff and time are needed to maximise efficiency, safety and improved outcomes.

Large volume work will allow research and expertise to develop with time. In the future, the birth and the rise of new mammary implant concepts and technologies could completely change the concept of breast autoaugmentation of the massive weight loss breast.

#### REFERENCES

- 1- Wallace A.F.: The surgery of beauty. Trans. Med. Soc. Lond., 98 (17): 1981-1982.
- 2- O'Connell J.B.: Bariplastic surgery. Plast. Reconstr. Surg., 113: 1530, 2004.
- 3- Westreich M.: Anthropomorphic breast measurement: Protocol and results in 50 women with aesthetically perfect breasts and clinical application. Plast. Reconstr. Surg., 100: 468, 1997.
- 4- Rubin J.P. and Khachi G.: Mastopexy after massive weight loss: Dermal suspension and selective auto-augmentation. Clin. Plast. Surg., 35: 123, 2008.
- 5- Elliot L.F.: Circumareolar mastopexy with augmentation. Clin. Plast. Surg., 29 (3): 337-347, 2002.
- 6- Persoff M.M.: Use of the adjustable Spectrum implant in aesthetic breast surgery. In: Innovations in Plastic Surgery, 1 (1): 64, QMP Clinical Series, 2005.
- 7- Hamdi M., Landuyt K., Ulens S., et al.: Clinical applications of the superior epigastric artery perforator (SEAP) flap: Anatomical studies and preoperative perforator mapping with multidetector CT. J. Plast. Reconstr. Aesthet. Surg., 62: 1127-34, 2009.
- 8- Brink R.: Management of true ptosis of the breast. Plast. Reconstr. Surg., 91: 657, 1993.
- 9- Losken A. and Daniel J. Holtz: Versatility of the Superomedial Pedicle in Managing the Massive Weight Loss Breast: The Rotation Advancement Technique. Plast. Reconstr. Surg., 120: 1060, 2007.
- 10- Losken A., Seify H., Denson D.D., Paredes A.A. and Carlson G.W.: Validating three-dimensional imaging of the breast. Ann. Plast. Surg., 54: 471, 2005.
- 11- Cronin T.D. and Gerow F.: Augmentation mammoplasty-a new "natural feel" prosthesis. In: Transactions of the 3rd International Congress of Plastic Surgeons. Amsterdam, Excerpta Medica, 1964.
- 12- Spear S.L., Boehmler JH.IV. and Clemens M.W.: Augmentation/Mastopexy: A 3-year review of a single surgeon's practice. Plast. Reconstr. Surg., 118 (7 suppl.), 136S-147S, 2006.
- 13- Spear S.L.: Augmentation/mastopexy: "Surgeon, beware". Plast. Reconstr. Surg., 112 (3): 905-906, 2003.
- 14- Song A.Y., Jean R.D., Hurwitz D.J., et al.: A classification of contour deformities after bariatric weight loss: The Pittsburgh Rating Scale. Plast. Reconstr. Surg., 116: 1535. Discussion 1545, 2005.
- 15- Rohrich R.J., Gosman A.A., Brown S.A. and Reish J.: Mastopexy preferences: A survey of board-certified plastic surgeons. Plast. Reconstr. Surg., 118 (7): 1631-1638, 2006.
- 16- Spear S.L. and Venturi M.L.: Augmentation with periareolar mastopexy. In: Spear S.L., (ed). Surgery of the Breast: Principles and Art, Vol. 2, 2<sup>nd</sup> edn. Philadelphia, Lippincott Williams and Wilkins, pp. 1391-1402, 2006.
- 17- Cardenas-Camarena L. and Ramirez-Macias R.: International Confederation for plastic reconstructive and aesthetic surgery, Augmentation/mastopexy: How to select and perform the proper technique. Aesthetic Plast. Surg., 30: 21, 2006.
- 18- Migliori F.C., Gabrielli A., Rizzo R., et al.: Breast contouring in postbariatric patients: A technique selection algorithm. Obes. Surg., 20: 651-6, 2010.
- 19- Rubin J.P., Agha-Mohammadi S. and O'Toole J.P.: Breast reshaping after massive weight loss. In: Aly A, editor. Body Contouring After Massive Weight Loss. St. Louis: Quality Medical Publishing, p. 361-78, 2006.
- 20- Hall-Findlay E.J.: A simplified vertical reduction mammoplasty: Shortening the learning curve. Plast. Reconstr. Surg., 1004: 748, 1999.
- 21- Lejour M.: Vertical mammoplasty and liposuction of the breast. Plast. Reconstr. Surg., 94: 100-114, 1994.