

Lateral Forehead Defect Reconstruction: Rotational Forehead Flap vs. Temporoparietal Fascia Flap

AYMAN FIKRY, M.D.; MOHAMMAD NASR, M.D. and YEHIA ZAKARIA, M.D.

The Departments of Plastic and Reconstructive Surgery & General Surgery, Zagazig University Hospitals

ABSTRACT

Introduction: The lateral forehead defect reconstruction resulting after tumor resection or trauma is a challenging problem, it is done by flap repair when there is excessive soft tissue loss or simple approximation of wound edges is not feasible.

Aim of the Work: The repair must keep symmetry between both sides of face, minimal disturbance to the surrounding structures, with acceptable residual donor side morbidity.

Patients and Methods: 20 patients admitted to plastic surgery unit of Zagazig University Hospitals during the period starting from April 2010 to December 2011. All patients were suffering from lateral forehead defect, the included patients were allocated randomly in one of two groups: Group A: 10 patients were repaired with the use contralateral Rotational Forehead Flap (RFF) and Group B: 10 patients were repaired with the use of ipsilateral Temporoparietal Fascia flap (TPFF).

Results: The flap survival rate was 100% in both groups, the early post operative complications were nearly same in both groups, the main complications in group A were eye brow elevation and low set hair line, while in group B were linear scar alopecia and temple parathesia. Patient in group B had more satisfactory cosmetic results than group A.

Conclusion: Although the TPFF harvesting is more challenging than RFF and has to be covered with skin graft, The TPFF is a reliable and versatile regional flap in the forehead reconstruction, The TPFF has more acceptable cosmetic result and less residual morbidity than RFF.

INTRODUCTION

The face is one of the most commonly affected sites by skin tumors, and trauma [1]. The forehead is a major facial unit, it has one central and two lateral subunits [2]. The lateral subunit is extending from the midbrow to the juncture with the temple [3].

The forehead is covered by tight, smooth skin of uniform quality [2]; it has a poor elasticity and slightly convex surface [4]. Forehead defects arise most often from oncologic resection or traumatic loss [5].

The need for a flap for the closure of a defect emerges when tissue is missing or simple approx-

imation of wound edges is impossible [6]. Facial defects, when repaired with skin grafts often tend to develop depressions, irregularities and contractures [7].

Along with defect closure, other goals of repair, it must be performed with minimal disturbance to surrounding structures, Care must be taken to maintain symmetry between sides [8], align scars along the hairline or eyebrows, maintain the normal height of the hairline [4], and finally with minimal donor site morbidity [9], also a well-hidden scar is desirable [1].

This article addresses two options for the reconstruction of lateral forehead defects; either contralateral Rotational forehead flap (RFF) or Temporoparietal fascia flap (TPFF), the choice between these two flaps was compared by taking into consideration, the size of the tissue defect, maintaining symmetry, resulting postoperative complications, and residual morbidity.

Surgical anatomy of RFF:

The entire forehead is available as an arterialized flap [2]. It is based on the superficial temporal artery (STA) [10]. Its anterior (facial) branch anastomoses with the supraorbital and supratrochlear arteries from the ophthalmic artery [9].

This flap allows the rotation of an adjacent forehead skin along a semicircular arc, shifted from the opposite hemiforehead and scalp to cover the defect in the large hemi forehead defects [2,6].

The main idea of this flap is to convert the defect into an isosceles triangle, then a line projecting along the base of that triangle extending at least 1.5 times longer than the base of the triangular defect, the pivot point of the semicircular arc is the midpoint of that line [10]. The superior border of the flap (perimeter) is an arc which is developed in the hair bearing scalp and traverses the frontal

scalp to the opposite preauricular crease [10]. A relaxing incision, or “back cut,” might be required to allow proper rotation of tissue [6].

Surgical anatomy of TPF:

The TPF is an inferiorly based axial fascial flap containing the (STA) and vein [11]. The (STA) emerges from the parotid at the level of the tragus, accompanied by two concomitant veins [12]. The STA then divides into anterior and posterior branches 2 to 3cm above the root of the helix [9]. The fascia is 2-3mm thick [12]. It is the most superficial layer beneath the subcutaneous fat of the temporal region [13]. The temporalis muscle and fascia lie deep to the TPF and are separated from it by a layer of loose areolar tissue, the flap is based axially on the posterior of the STA and not the anterior branch [9,14].

PATIENTS AND METHODS

This study was carried out on 20 patients admitted to Plastic Surgery Unit of Zagazig University Hospitals during the period starting from April 2010 to December 2011. All patients were suffering from lateral forehead defect following trauma or tumor excision. (Patients with Prior surgery, trauma or radiation in the temporoparietal area were excluded from this study). The included patients were allocated randomly in one of two groups (Table 1).

Group A: 10 patients were repaired with the use of contralateral Rotational Forehead Flap (RFF).

Group B: 10 patients were repaired with the use of ipsilateral Temporoparietal Fascia flap (TPFF).

Table (1): Patient demographic data.

Patient demographic data	Group A	Group B
Age range	19-60y	13-55y
Sex:		
• Male	7	6
• Female	3	4
Cause of defect:		
• Post traumatic	4	5
• Post tumor excision	6	5

The average dimensions of the defect was ranging from 80mm X60mm. Tumor resection was done with good safety margins and examined with frozen section examination. Defect coverage with skin grafts was abandoned in this series to avoid depressions and irregular contour and also with cases which had exposed bone after tumor resection

or trauma. The traumatic cases in both groups were managed immediately after wound debridement. All patients received perioperative antibiotics.

Surgical technique:

Group A:

Under general anaesthesia, Preoperative hair shaving is limited to the operative field, preoperative marking is done, and then scalp incision is done beveled at an angle parallel to hair shafts, and ensures good hemostasis.

Elevation of the flap is accomplished down toward the supraorbital rim in the subaponeurotic layer, once the flap has been rotated to the desired position; the hair line on the distal margin of the flap is aligned with the temporal hairline on the lateral margin of the defect.

The defect is closed without tension, attempting to orient the suture line transversely to minimize the exposed portion of the scar. The frontal scalp is closed by relaxation and advancement of the scalp posterior to the defect, a suction drain is left in the wound (Figs. 1-3).

Group B:

Under general anaesthesia, Preoperative hair shaving is limited to the operative field, the STA is traced by handle Doppler (transcutaneous flow Doppler) and marked, local anesthesia with 1% lidocaine with 1/100,000 of epinephrine is injected intradermally, a preauricular skin crease incision is made just anterior to the spine of the helix, the incision is made over the course of STA curve into a hemicronal incision about 5 to 10cm behind the hairline.

Dissection of flaps is performed just deep to the cutaneous follicles to avoid damage to the STA and more superficially located STV, to the way to the vertex of the skull, where the galea aponeurotica blends with the TPF. Then TPF can be divided distally, the downward elevation of the flap is performed by freeing the deep surface that is facilitated by the loose areolar plane between the TPF and deep temporal fascia down to zygomatic arch (Fig. 4).

The flap is then transposed via a subcutaneous tunneling to the defect, Care must be taken to prevent kinking or twisting of the flap within the tunnel, after flap inseting, it can be covered with an immediate or delayed split-thickness skin graft, a suction drain is left in the wound (Fig. 5).

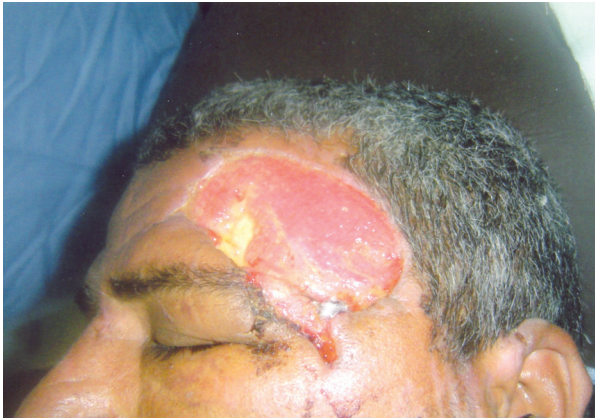

Fig. (1 A): Traumatic defect with exposed bone.

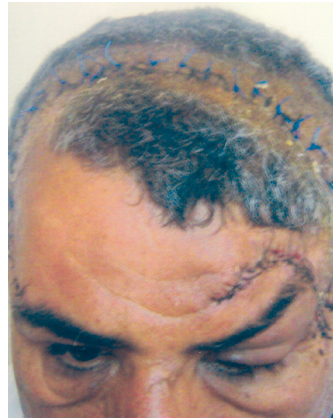

Fig. (1 B): Coronal incision in scalp.

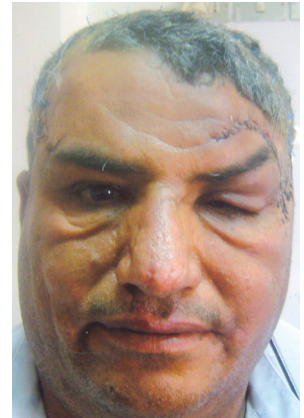

Fig. (1 C): Postoperative elevated eye brow.

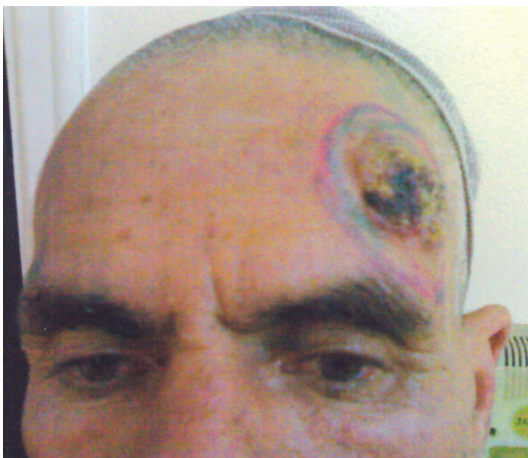

Fig. (2 A): Basal cell carcinoma.

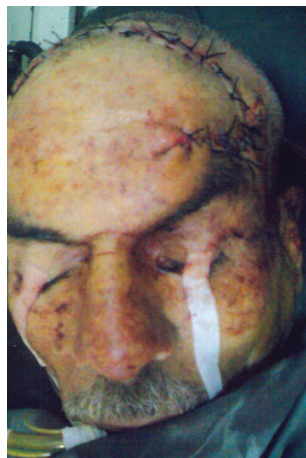

Fig. (2 B): Intra operative view.

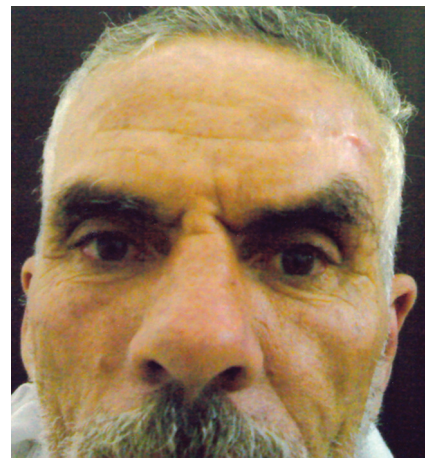


Fig. (2 C): 6 months postoperative.

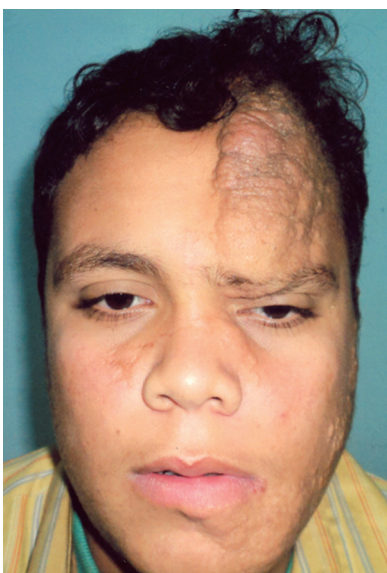

Fig. (3 A): Pilosebaceous hamartoma.

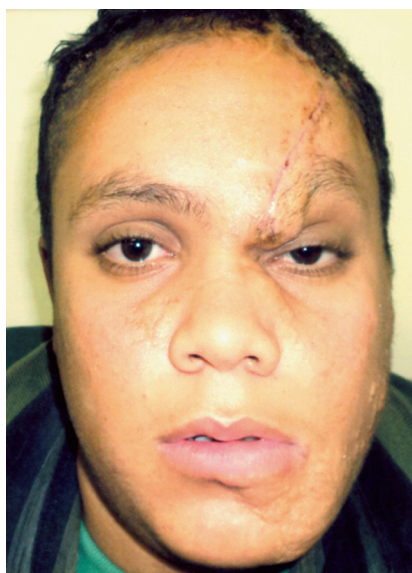

Fig. (3 B): Early post operative.

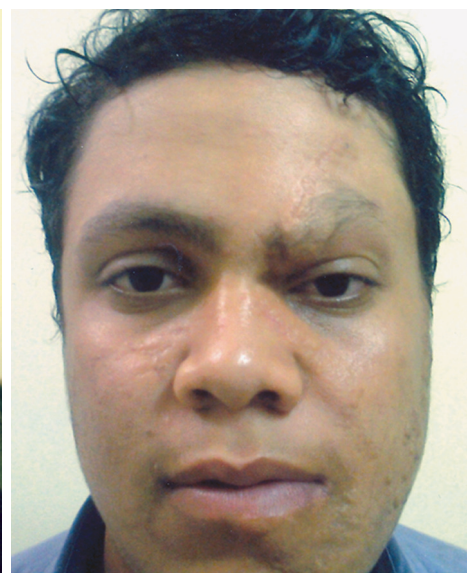

Fig. (3 C): 1.5 years post operative.

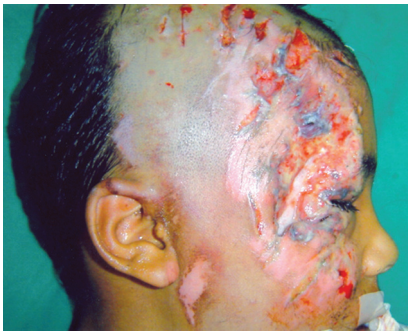

Fig. (4 A): Traumatic defect with exposed bone.

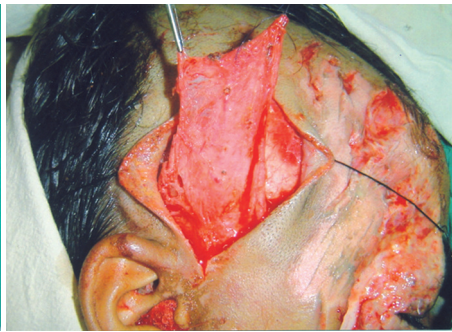


Fig. (4 B): Intraoperative elevated TPF.

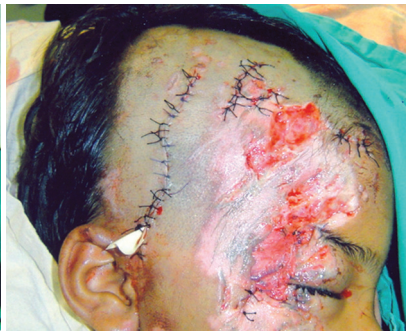

Fig. (4 C): Insetting of the flap.

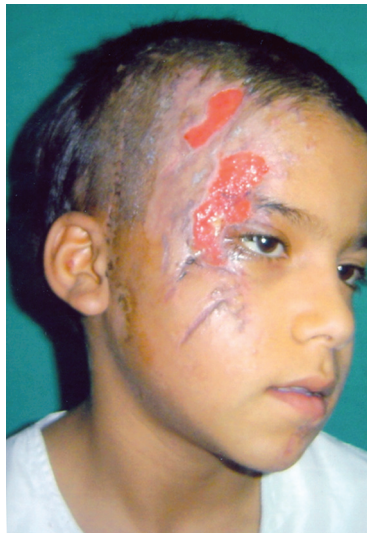

Fig. (4 D): One week post operative.

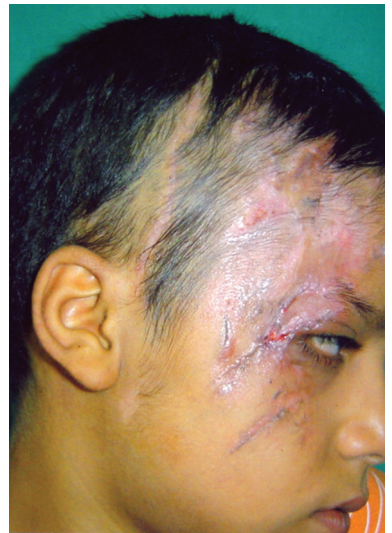

Fig. (4 E): One month later.

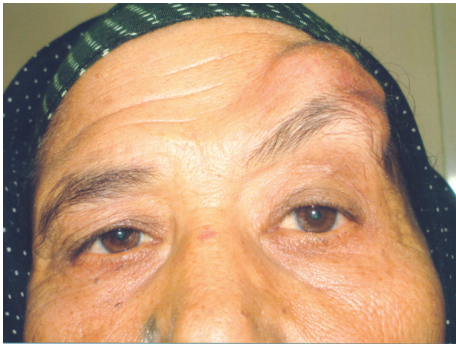


Fig. (5 A): Recurrent leiomyosarcoma.

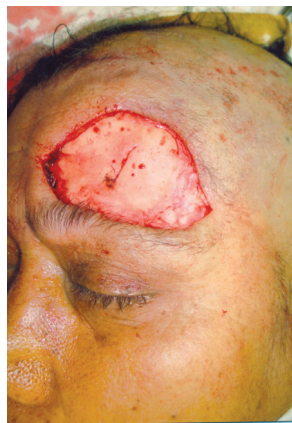

Fig. (5 B): Tumor excision with exposed bone.

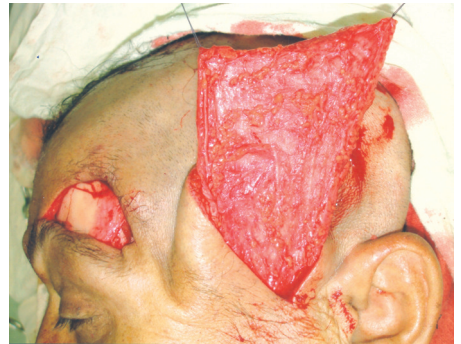

Fig. (5 C): Intraoperative elevated TPF.

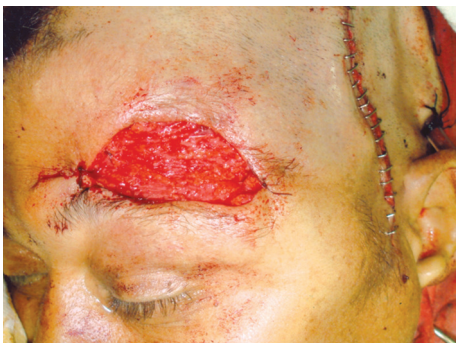

Fig. (5 D): Insetting of the flap.

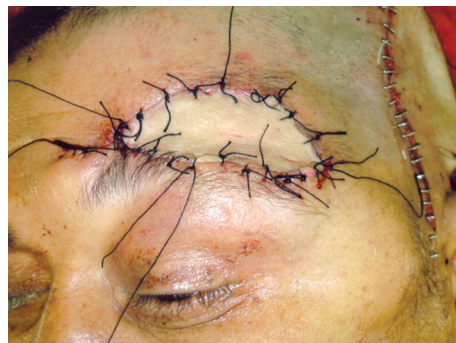

Fig. (5 E): Immediate skin grafting.

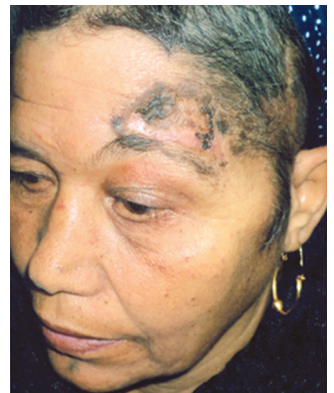

Fig. (5 F): One month later.

RESULTS

During the study period, the number of patients were 20 patients (n=20) divided in two groups, the results were evaluated objectively and by preoperative and postoperative photography during the follow-up period which was ranging from 1 month to 18 months with mean 6.5 months. The flap survival rate was 100% in both groups, and pathological findings in post tumor excision cases is illustrated in (Table 2).

The early postoperative complications were nearly the same in both groups except one case in group B with hematoma in the donor site which evacuated with no skin edge compromise. As regard the late postoperative complications, the main complications in group A were eye brow elevation and low set hair line, while in group B were linear scar alopecia and temple parathesia. Patient in group (B) had satisfactory cosmetic results more than group (A), comparison of the results in (Table 3) and (Fig. 6).

Table (2): Pathological findings in tumor cases.

Pathological diagnosis	Group A	Group B
Basal cell carcinoma	3	2
Squamous cell carcinoma	2	1
Basosquamous cell carcinoma	–	1
Recurrent leiomyosarcoma	–	1
Pilosebaceous hamartoma	1	–

Table (3): Postoperative complications.

	Group A	Group B
Flap survival rate	10/10 100%	10/10 100%
<i>Operative time (Mean)</i>	2:16.6	3:20.5
<i>Skin graft:</i>		
• Primary grafting	No	8 80%
• Secondary grafting	No	2 20%
<i>Early post operative complications:</i>		
• Edema (periorbital)	4 40%	5 50%
• Infection	1 10%	1 10%
• Hematoma	No	1 10%
<i>Late Post operative complications</i>		
<i>-Donor site morbidity:</i>		
• Alopecia (liner scar)	2 20%	5 50%
• Temple parathesia	No	10 100%
<i>-Symmetry:</i>		
• eye brow elevation	8 80%	No
• low set hair line	8 80%	No
<i>Patient's satisfaction:</i>		
• Good	4 40%	7 70%
• Fair	3 30%	3 30%
• Poor	3 30%	0 0%

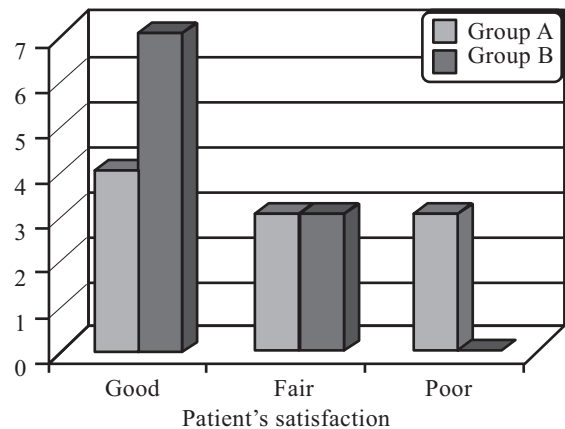


Fig. (6): Comparison of patient satisfaction between the two groups.

DISCUSSION

The ideal facial reconstruction should provide a good color and texture, preserves harmony and does not distort facial symmetry [1].

Both of flaps can cover large forehead defects, The RFF can reconstruct moderate-to-large forehead defects [2], involving up to 40% of the forehead surface area [10]. The larger the flap, the easier the primary closure of both the recipient and donor sites [2]. Also the TPF is a long-reaching pedicled flap; when full extent of the flap is harvested, its dimensions are up to a 17-cm-long by 14-cm-wide segment [9,12,14].

The major advantage of RFF that, it allows primary closure of both recipient and donor sites, by appropriate tension distribution over a wide and liner area [2,6,10], without skin grafting of donor defect [15]. Also, the great vascularity of RFF makes the infection and flap necrosis rarely occurred [10].

Several literatures had described The TPF as a unique flap; it is a thin, pliable and supple flap for reconstruction [9,14,16]. It convolutes into surface defects [17], and It can be fashioned easily to conform to any contour of traumatic contour defects [16].

TPF is a well-vascularized flap with reliable blood supply [9,14]. It supplies blood flow in poor healing situations such as in chemoradiated field or infected field [14], it revascularizes saucerized bone, and allows perfusion of infected surfaces with antibacterial agents [17]. It provides a vascularized substrate for an immediate split thickness or full-thickness skin graft [11,18].

As regard the results of the current study, the flap survival rate was 100% in both groups, which

means that both flaps had showed good vascularity that allows control of infection and flap survival. This agreed with the reported results of other series, Bridger et al. [9] had reported no perioperative flap failures in twenty-one patients treated with pedicled TPF for facial defect reconstructions, also Lai and Chenny [16] had successful transfer of pedicled TPF without flap compromise in nine patients (100%) with orbital cavity defects.

As regard operative time; in the current study, the mean operative time of TPF harvesting was longer time than RFF, as the dissection of the TPF harvesting is tedious [19], and great care had taken in separating the subcutaneous tissue from the underlying axial vascular supply.

As regard texture and color matching, the RFF has the same texture and color matching as it containing all layers of the forehead and scalp [2]. While with TPF, the fascial flap has to be covered with partial thickness skin graft.

All TPF were covered with partial thickness skin graft (the 1st two cases were done with secondary skin grafting while the other eight cases with immediate grafting), skin graft take was excellent in all cases, this is agreed with Lai and Chenny [16], They reported that, Split-thickness skin grafted onto a pedicled TPF showed 100% survival, and Goode et al. [11] mentioned that, the TPF is as a good carrier of a skin graft. It remained stable despite postoperative irradiation [18]. In the current series, during the follow-up period the skin grafted TPF remained stable (in two cases received radiotherapy) and color matching was accepted on the long run.

In the current study, the most commonly reported late post operative complication with RFF was elevated eye brow and low set hair line, several authors had reported the same resulting deformity such as Angelos & Downs [8] had reported, post-operative moderate brow distortion, Worthen [10] had mentioned that asymmetry of the forehead furrows occurred particularly when these are deep and prominent, and Menick [2] said that the RFF lowers the forehead hairline. Linear alopecia was reported in only two cases in group A as we adopted to do beveled incision in the scalp, as recommended by Granzow and Brian Boyd [6] to avoid linear hairless scar, also the low set hair line was not a problem in 2 male cases of this series as they had male pattern boldness.

On the other hand in our study, the most commonly reported donor site complication after TPF is liner scar alopecia, this agreed with Lai and

Chenny [16]. Perhaps, the superficial plane of dissection might damage hair follicles, which may result in alopecia and, possibly, skin loss [9], and care should be taken to stay deep to the hair follicles to avoid alopecia [14], more ever the scalp hair could camouflage the resulting scars or asymmetries [20].

The auriculotemporal nerve travels with STA and STV, and therefore is usually cut in the dissection, leading to expected temporal numbness [14], this is also reported in our cases but it was not a troublesome condition.

Although, the donor site of TPF is from the undersurface of the scalp in the temporo-parietal regions [9], it does not leave a scalp depression that might require further aesthetic surgery to correct [21], and that soft tissue depression was quickly hidden by hair [9].

Finally, The TPF, as regards flap characteristics, is unparalleled when compared with other regional flaps such as rotational forehead or scalp flaps [16]. It can be harvested with minimal donor site morbidity [9]. The ideal use of TPF lies in the reconstruction of head defects requiring minimal bulk [16].

Conclusion:

Although the TPF harvesting is more challenging than RFF and has to be covered with skin graft, The TPF is a reliable and versatile regional flap in the head reconstruction, TPF is a highly vascular flap resists infection, pliable, it shows good take of the skin graft which remained stable despite post op. radiation, it does not distort facial symmetry. And finally, The TPF has more acceptable cosmetic result and less residual morbidity than RFF.

REFERENCES

- 1- Tan O.: An algorithmic approach to restoration of the fronto-naso-periorbital skin defects using the forehead flaps. *Journal of Cranio-Maxillofacial Surgery*, 38: 11-18, 2010
- 2- Menick F.J.: Principles of subunit reconstruction of the forehead, operative techniques in Plastic and Reconstructive Surgery Vol. 5, No. 1 (February), PP 12-17, 1998.
- 3- Seline P.C. and Siegle R.J.: Advanced Surgical Reconstructive Techniques Forehead reconstruction, *Dermatologic Clinics* Vol. 23, Issue 1, January, p. 1-11, 2005.
- 4- Rodriguez-Bruno K.M. and Byrne P.J.: Philosophy on the closing of facial defects: Choosing the right procedure *Operative Techniques in Otolaryngology*, p. 22, 2-12, 2011.
- 5- Ducic Y.: *Facial Plastic Surgery Clinics of North America*, Volume 17, Issue 2, May, p. 177-187, 2009.

- 6- Granzow J.W. and Brian Boyd J.: Grafts, local and regional flaps, M.Z. Siemionow and m. Eisenmann-Klein (eds.), Plastic and Reconstructive Surgery, springer specialist surgery series, © springer-verlag london limited, 2010.
- 7- Pinho C., Choupina M., Silva P., Ferreira P., Guimaraes I., and Amarante J.: A new retroauricular flap for facial reconstruction, The British Association of Plastic Surgeons, 56: 599-602, 2003.
- 8- Angelos P.C. and Downs B.W.: Facial Plastic Surgery Clinics of North America, Volume 17, Issue 3, August, p. 379-393, 2009.
- 9-Bridger A.G., Walpoe M. and Costantino P.D.: The Pedicled Temporoparietal Fascial Flap For Complex Midfacial Reconstruction, operative techniques in Otolaryngology-Head and Neck Surgery, Vol. 11, No. 3 (Sept),: pp 198-200, 2000.
- 10- Worthen E.: Scalp flaps and the rotational forehead flap, grabb's encyclopedia of flaps, (editors) Berish strauch, luis o. vasconez, Elizabeth J. Hall-Findlay, Bernard T. lee, 3rd edition, Vol 1: pp 3, 2009.
- 11- Goode R.L., Reynolds B. and Long C.: The temporoparietal fascia flap, Operative techniques in Otolaryngology-Head and Neck Surgery, Vol. 4, No. 1 (Mar.), pp 18-23, 1993.
- 12- Nayak V.K. and Deschler DG.: Pedicled temporoparietal fascial flap reconstruction of select intraoral defects. Laryngoscope, 114: 1545-1548, 2004.
- 13- Tolhurst DE., Carstens MH., Greco RJ., et al.: The surgical anatomy of the scalp. Plast Reconstr. Surg., 87: 603-626, 1991.
- 14- Allegretti J.P. and Panje W.R.: The temporoparietal fascial flap in head and neck reconstruction: The Workhorse from above Operative Techniques In Otolaryngology-Head and Neck Surgery, Vol. 11, No. 2 (Jun), pp. 143-146, 2000.
- 15- Ahuja R.B.: Local flap template: Present perfect tense or flap tense? British Association of Plastic, Reconstructive and Aesthetic Surgeons. doi: 10.1016/j.bjps. 03.005, 2008.
- 16- Lai A. and Cheney M.L.: Temporoparietal Fascial Flap in Orbital Reconstruction Arch. Facial Plast Surg., 2 (3): p: 196-201. 2000.
- 17- Rose E.H. and Norris M.S.: The versatile temporoparietal fascial flap: Adaptability to a variety of composite defects. Plast Reconstr. Surg., 85: 224-232, 1990.
- 18- Cheney M.L., Vavares M.A. and Nadol J.B.: The temporoparietal fascial flap in head and neck reconstruction. Arch. Otol. Head Neck Surg., 119: 618-623, 1993.
- 19- Temporoparietal Fascia Flap- Iowa Head And Neck Protocols-ITS Wiki Service, [https:// wiki.uniowa.edu/display/protocols/temporoparietal+fascia+flap](https://wiki.uniowa.edu/display/protocols/temporoparietal+fascia+flap) # Temporoparietal Fascia Flap-for clinicians. Last edited by Douglas Hentstrom on Feb. 16, 2012.
- 20- Earnest L.M. and Byrne P.J.: Facial Plastic Surgery Clinics of North America, Volume 13, Issue 2, May, P.345-353, 2005.
- 21- Clauser L., Curioni C. and Spanio S.: The use of the temporalis muscle flap in facial and craniofacial reconstructive surgery: A review of 182 cases. J. Craniomaxillofac. Surg., 23: 203-214, 1995.