

## Inferior Gluteus Maximus Myocutaneous Flap for Reconstruction of Ischial Bed Sores

WALID MOSTAFA, M.D.

The Department of General Surgery, Plastic and Reconstructive Surgery Unit, Faculty of Medicine, Tanta University

### ABSTRACT

**Background:** The skin overlying the ischium is the most common location for pressure sores and is one of the most difficult areas to treat. There are various alternatives for the closure of ischial pressure sores. The inferior portion of the gluteus maximus muscle along with an island of overlying skin seems to be the best choice for initial coverage of an ischial pressure sore.

**Methods:** Debridement including bursectomy and radical excision of all non viable, fibrous and infected tissues was done. The ischial tuberosity was reduced and rasped to a smooth contour. The inferior gluteus maximus myocutaneous flap was elevated and transected at a point where a mass adequate to fill the deep portions of the wound had been included. The flap was rotated so that the tip was drawn into the defect. Suction drain was inserted and the wound was closed in layers. The flap donor site was closed without a skin graft.

**Results:** Twenty patients (17 males and 3 females) underwent inferior gluteus maximus myocutaneous flap reconstruction for grade 4 ischial pressure sores. Partial dehiscence of the wound occurred in 2 cases. One of them healed spontaneously; while secondary revision of the wound was done for the other. Two cases showed recurrence, after 5 and 6 months. Both cases were reoperated successfully with the same technique then followed-up again for 6 months with no recurrence.

**Conclusions:** The inferior gluteus maximus myocutaneous flap should be considered as one of the first choices in the treatment of ischial pressure sores. It is easily elevated vascularized bulky flap with low recurrence rates. Rotational and advancement in case of recurrence can be done successfully. It also spares the vascular pedicles of adjacent flaps for future use.

### INTRODUCTION

The term "pressure sore" has been used since early Egyptian times [1]. It is an area of localized damage to the skin and underlying tissue caused by pressure, shear, friction, and/or a combination of these [2]. Pressure sores or ulcers usually occur over weight-bearing bony prominences such as the sacrum, ischial tuberosities, greater trochanters and the calcaneum [3]. Three groups of patients are at high risk: Paraplegics, the aged, and those

who are hospitalized [4]. The number of these patients is rising; this is due to an increase in spinal injury caused by traffic accidents and to the increase in life expectancy [5].

Pressure ulcers represent a challenge for the medical and nursing staff because they are averse to healing, difficult to close by surgery, have a tendency to recur and are extremely costly to treat [6].

The European Pressure Ulcer Advisory Panel in (2010) classified pressure ulcer severity according to the degree of tissue loss [4] (Table 1).

Table (1): European pressure ulcer advisory panel grading system for pressure ulcer classification.

Intact skin with non-blanchable redness.	Grade I
Partial thickness loss of dermis presenting as a shallow open ulcer with a red pink wound bed, without slough. May also present as an intact or open/ruptured serum-filled or sero-sanguinous filled blister.	Grade II
Full thickness tissue loss. Subcutaneous fat may be visible but bone, tendon or muscles are not exposed. May include undermining and tunneling.	Grade III
Full thickness tissue loss with exposed bone, tendon or muscle.	Grade IV

Prevention remains the mainstay in the management of pressure ulcers. Once developed, avoidance of further progression or deterioration of the ulcer is essential. Simple conservative treatment of grade I and II pressure ulcers consists of eliminating any predisposing risk factors and addressing them appropriately. In some patients, however, continued progression and deterioration of the ulcer is inevitable. In such patients, early active management and intervention are essential. In pressure ulcers which are grade II or above, surgical

debridement of necrotic tissue from the wound bed may be necessary to promote healing of the ulcer [7]. Surgical intervention, including reconstructive surgery is frequently indicated in non-healing chronic grade III and IV pressure ulcers, because conservative non-surgical treatment is protracted and frequently culminates in either a non-healing wound or early recurrence [8].

The skin overlying the ischium is the most common location for pressure sores, especially in paraplegic patients who are confined to wheelchairs [7,9,10]. Ischial pressure ulcers are characterized by small skin defects but with a large penetrating cavity underneath [7]. It is one of the most difficult areas to treat, because the ischial area is very mobile and vulnerable to pressure in the sitting position. Also, unlike in the sacral area or greater trochanter of the femur, in the ischium, the position changes of flexion and extension of the lower extremities influence the tension and size of the pressure sore [11]. The treatment of ischial pressure ulcer includes excision of undermined skin, abrasion or resection of the ischial tuberosity, removal of infected bursae and the closure of the defect by a flap [12].

There are various alternatives for the closure of ischial pressure sores such as the gluteus maximus musculocutaneous flap, inferior gluteal thigh flap, hamstring muscle flap, biceps femoris muscle flap, tensor fascia lata flap, and gracilis muscle flap [11].

Recurrence often develops due to the continuous pressure on the ischial area during the patients' daily activities. For this reason, patients with ischial pressure sores may require several flap surgeries during their lifetime; however, the number of surgeries is limited because there are not many vascular pedicles in the gluteal region for the flap surgery. To treat these patients, it is important to adopt a surgical strategy in which the vascular pedicles and muscles for future flaps are not injured during the initial flap procedure [13].

Rationale for flap selection include the preservation of future flap options, sufficient soft tissue supply to cover the ischial bony prominence, and flaps based on the trunk or pelvis which have minimal changes in tension with different leg/pelvis positions. Due to the significant changes in the tension exerted across the ischial area with different lower limb positions, flaps based on the immobile trunk or pelvis have better outcome than those based on the more mobile lower extremity [11,14].

In fact, there are two frequently used flaps for ischial sores, which may be thought of as based in

the pelvis: The inferior gluteus maximus myocutaneous flap and the inferior gluteal thigh fasciocutaneous flap. The inferior gluteus maximus flap is based entirely in the pelvic area. The inferior gluteal thigh flap can be considered pelvic-based since its pedicle, the descending branch of the inferior gluteal vessels, originates in the pelvis and the connections of the inferior gluteal thigh flap to the leg are completely severed during inferior gluteal thigh island flap elevation [11].

The inferior portion of the gluteus maximus muscle along with an island of overlying skin seems to be the best choice for initial coverage of an ischial pressure sore [11]. This flap can provide a large area of soft tissue for transposition, the reported donor site morbidity is low [15], and contrary to a common misperception, the descending branch of the inferior gluteal artery, the major blood supply to our flap of second choice (the inferior gluteal thigh flap), is routinely preserved. Even after division of this vessel, however, the inferior gluteal thigh flap remains reliably vascularized, presumably due to the collateral vessels from the thigh [16].

We present our series of 23 ischial pressure ulcers that were managed by the inferior gluteus maximus myocutaneous flap.

## MATERIAL AND METHODS

Between March 2008 and March 2011, 20 patients (17 males and 3 females) underwent inferior gluteus maximus myocutaneous flap reconstruction for grade 4 ischial pressure sores at Plastic Surgery Unit, Tanta University Hospitals. All patients were evaluated for surgical treatment preoperatively. Concurrent diseases were dealt with, the patient's ability to cooperate and to tolerate operation and the postoperative regimes were evaluated. The patient and relatives were thoroughly educated for adjusting the patient's daily living activities with postoperative pressure relief and general care.

The patient is positioned in the prone position, with hips flexed, and the outline of the flap is marked (Fig. 1a,b,c). Debridement was complete and necessitated bursectomy and radical excision of all non viable, fibrous and infected tissues. This usually involved the excision of bone which is often affected by osteomyelitis, the ischial tuberosity is reduced and rasped to a smooth contour. Removal of bony prominences removed the initiating pressure point and also shifted pressure elsewhere. Undermined areas were exposed to ensure adequate debridement.

To elevate the inferior gluteus maximus myo-

cutaneous flap, an incision was made along the crease between the buttock and the thigh along the lower border of the ischial ulcer. The incision was planned so that the flap was as large as possible and would not encroach on the pressure points. It involved the skin and subcutaneous tissue to the muscle fascia, which is quite thin. The dissection then bared the muscle surface for few centimeters distal to the skin incision. The inferior part of the muscle was transected at a point where a mass adequate to fill the deep portions of the wound had been included (Fig. 2).

The inferior part of the muscle was elevated from its lower border which usually formed a part of the wall of the ulcer. Elevation proceeded by dissection in the areolar plane deep to the muscle and superficial to the sciatic nerve. Blood vessels were protected by being closely attached to the deep surface of the muscle except near the piriformis muscle origin where they emerge from the pelvis.

The tip of the flap was drawn into the defect by suturing the excess muscle into the depth of the wound (Fig. 3). Sometimes it was necessary to back cut parallel to the muscle fibers to achieve adequate mobility. Suction drain was inserted and the wound was closed in layers. The flap donor site was closed without a skin graft (Fig. 4).

After operation a low-residual diet was given for 2 weeks and meticulous perineal hygiene was maintained. The patients were maintained entirely non-weight bearing on the ischial area for 5 weeks on air-flotation beds, with frequent change of position and total body care. After this period, a sitting protocol with gradual increase in pressure on the operation site was introduced. In cases with wound complications, a sitting protocol was delayed until the wound healed.

## RESULTS

Twenty patients (17 males and 3 females) underwent inferior gluteus maximus myocutaneous flap reconstruction for grade 4 ischial pressure sores at Plastic Surgery Unit, Tanta University Hospitals. The patients ranged in age between 22 and 60 years. Only one patient was ambulatory while the rest were paraplegic cases. Five of these cases were presented with recurrence after bursectomy and primary closure (Figs. 1a,8a).

Flap success and primary healing were defined as a healed wound within one month postoperatively, usually corresponding to the time of wound suture removal. Reconstructive failure was defined as a case resulting in a non-healed wound. All our

patients were followed-up after the operation for at least one year.

Immediate complications occurred in 2 patients (10%), with partial dehiscence of the wound due to an underlying seroma collection, related to the early withdrawal of suction drains. One of them healed spontaneously; while in the second case, secondary revision of the wound was done in order to accelerate healing. The introduction of a sitting protocol in these two cases was delayed for further 3 weeks. All patients achieved complete healing at the time of hospital discharge. The mean hospitalization period after surgical closure of the wound was 25 days (Figs. 5a-b,6a-b,7a-b,8a-b).

Two of our cases showed recurrence (10%), one after 5 months and the other after 6 months. Adequate history taken from both cases revealed prolonged weight bearing on the ischial areas with lack of proper medical and nursing care for early signs of recurrence. Both cases were considered as grade 3 pressure sores and were reoperated successfully with the same technique then followed-up again for 6 months with no recurrence (Figs. 8a-b,9a-b).

## DISCUSSION

There are various alternatives for the closure of ischial pressure sores such as the gluteus maximus musculocutaneous flap, inferior gluteal thigh flap, hamstring muscle flap, biceps femoris muscle flap, tensor fascia lata flap, and gracilis muscle flap [11].

Recurrence of ischial ulceration often develops despite successful flap closure because of the continuous pressure on the ischial region in the course of the patients' daily activities. Patients may require several flaps during their lifetime for the closure of ischial pressure sores. It is important to adopt a surgical strategy in which vascular pedicles to future flaps are not injured when the initial procedure is performed [17].

An ideal flap for the coverage of an ischial pressure sore should be well vascularized, with sufficient bulk to obliterate any "dead" space and be easy to work with. It should also allow the sparing of potential vascular pedicles for other flaps which may be required in future reconstructions [18]. In the ischium, the position changes of flexion and extension of the lower extremities influence the tension and size of the pressure sore. To minimize the tension after a pressure sore operation, it is important to select a non-mobile flap from the pelvis area rather than one from the lower extremities.



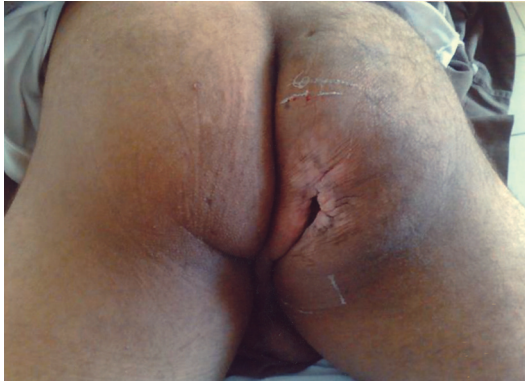

Fig. (1-A): The patient is positioned in the prone position, with hips flexed.

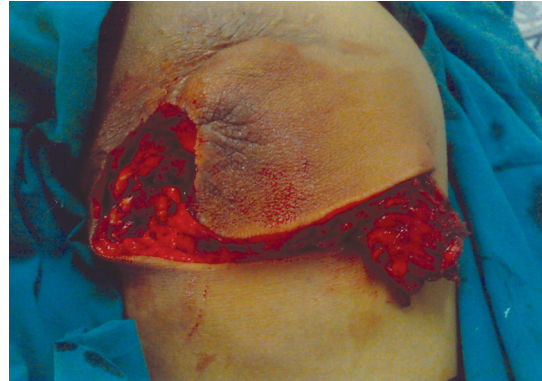

Fig. (2): Elevation of the inferior gluteus maximus myocutaneous flap involving excess few centimeters of the muscle distal to the skin crease incision.

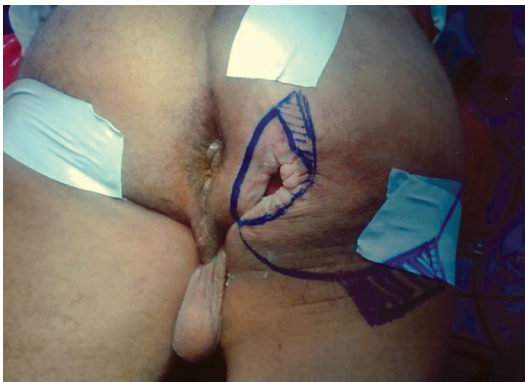

Fig. (1-B): The outline of the flap is marked.

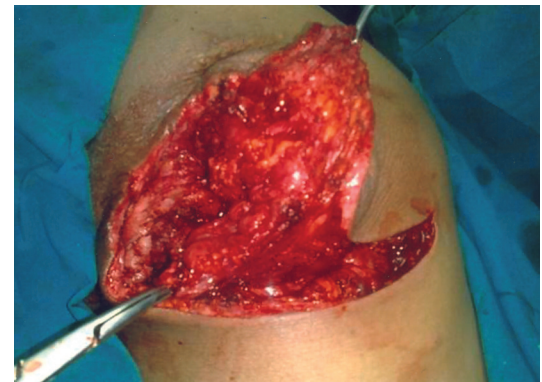


Fig. (3): Suturing the excess muscle into the depth of the wound.

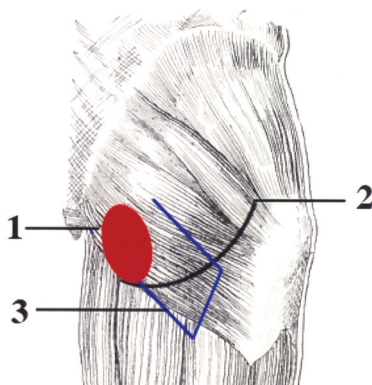


Fig. (1-C): Diagram of the flap, 1: The ischial bed sore 2: Skin incision at the gluteal fold 3: The included inferior part of the gluteus maximus muscle.

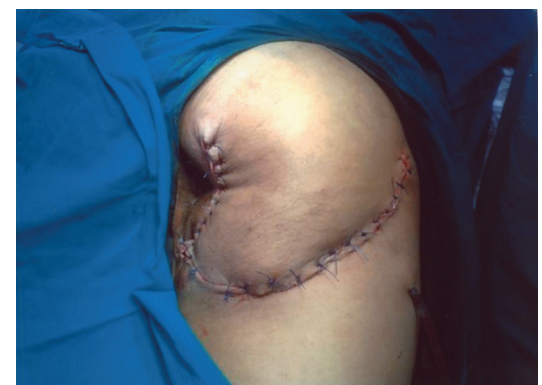

Fig. (4): The wound was closed in layers. The flap donor site was closed without a skin graft.

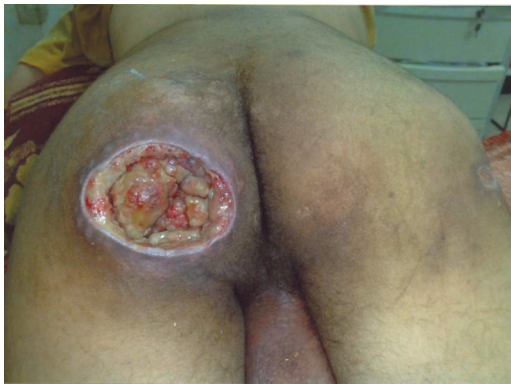

Fig. (5-A): Right extensive ischial bed sore.

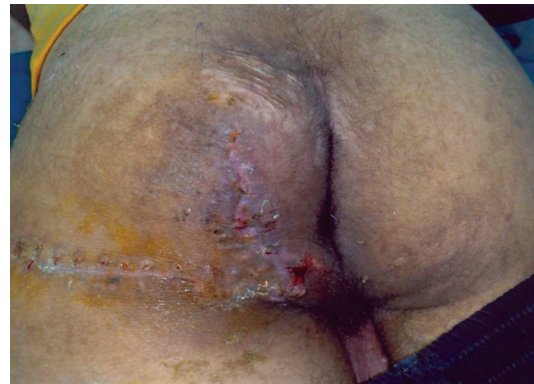

Fig. (5-B): Postoperative results after 25 days.

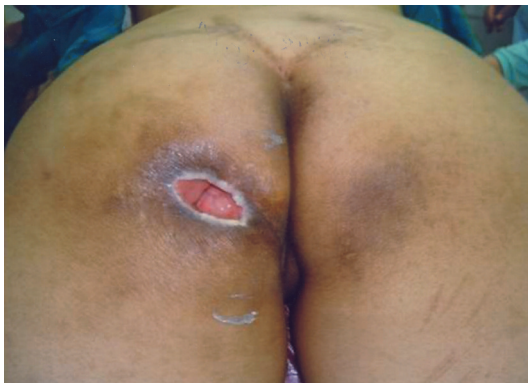

Fig. (6-A): Right ischial bed sore.

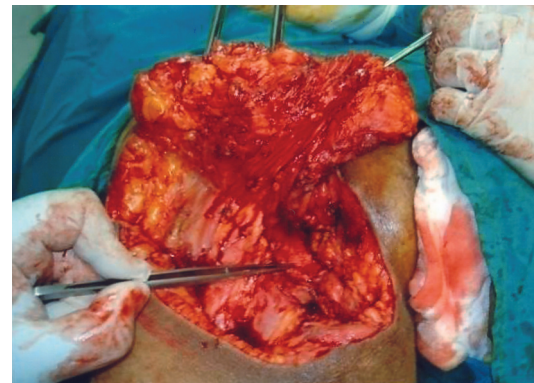


Fig. (6-B): Debridement. Burssectomy and excision of bone. The ischial tuberosity is reduced and rasped to a smooth contour.

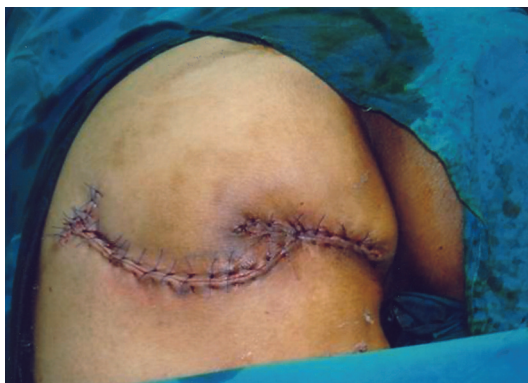

Fig. (6-C): Immediate postoperative results.

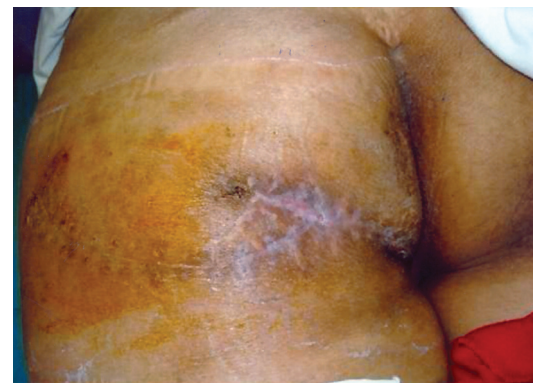

Fig. (6-D): Postoperative results after two months.

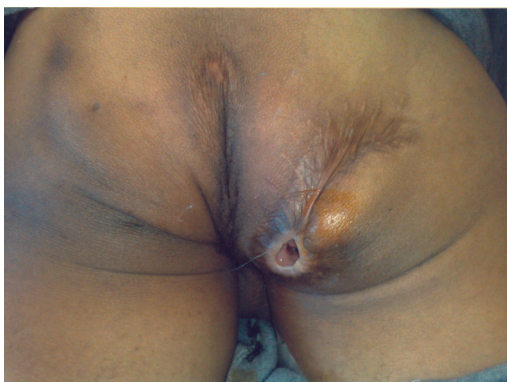

Fig. (7-A): Left ischial bed sore after failed trials for direct repair.

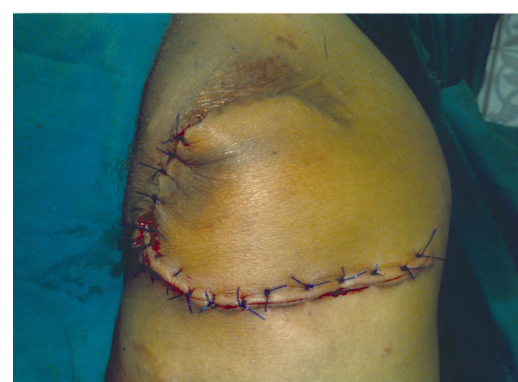

Fig. (7-B): Immediate postoperative results.



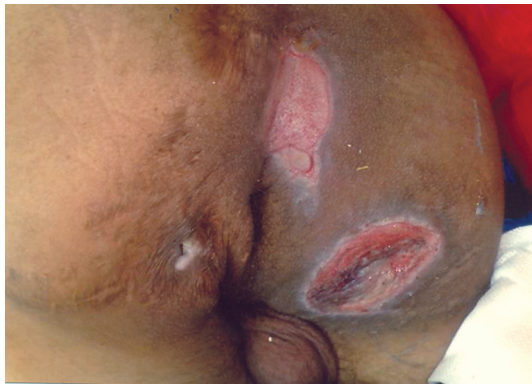

Fig. (8-A): Right recurrent ischial bed sore.

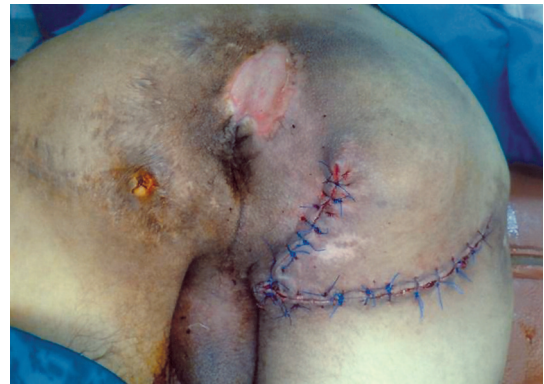

Fig. (8-B): Immediate postoperative results.

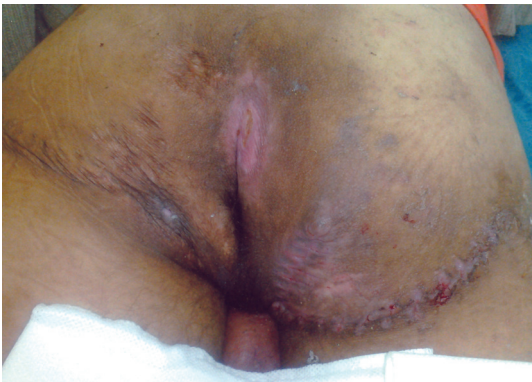

Fig. (8-C): Postoperative results one month after rerotation and advancement of the same flap.

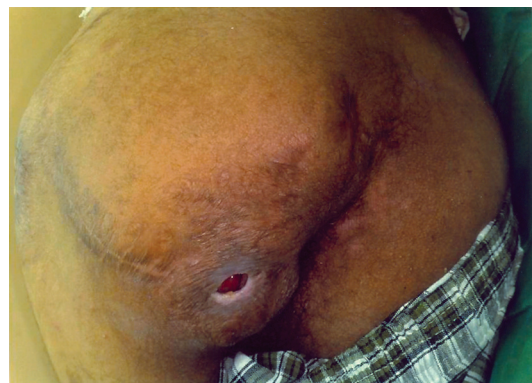

Fig. (9-A): Left recurrent ischial bed sore.

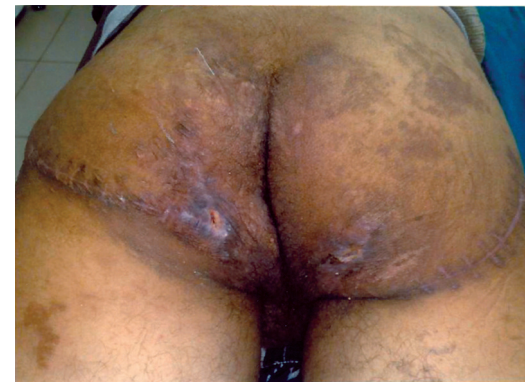

Fig. (9-B): Postoperative results one month after rerotation and advancement of the same flap.

One of the most commonly used flaps for ischial sores are the inferior gluteus maximus myocutaneous flap [11]. It was first reported in 1979 by Mathes and Nahai [19] and later in 1981 by Schefflan et al. [20] who used the inferior part of the gluteus maximus with the island of the overlying skin without disrupting the inferior gluteal artery. This flap originates from the pelvic area with sufficient soft tissue and muscle and it has the merits of low donor site morbidity and preservation of the pedicle of the inferior gluteal thigh fasciocutaneous flap for a second operation. Other flaps may not provide sufficient volume and the mobile characteristics of the lower extremities may result in increased tension [11,21].

Reis et al. [5], in their series of 82 ischial pressure sores, compared between biceps femoris myocutaneous flap, the inferior gluteus maximus myocutaneous flap, Gracilis myocutaneous flap, tensor fascia lata, other local transposition flaps and direct closure. They advocated the inferior gluteus maximus myocutaneous flap as it does not interfere with the future use of other flaps from adjacent areas, should this be necessary. They found that it does not interfere with the patient's ability to walk in ambulant patient. In their study, direct closure, local transposition flaps, and gluteal random rotation skin flaps, had a significantly higher recurrence rate than myocutaneous flaps, which was also noted by others [18,22].

In 1986 Stevenson et al. [23] made a modification of this flap by forming a true island flap and tunneling it beneath the bridge of normal skin to cover the defect. Higgins et al. [24] in 2002 followed by others [9,25,26] reported ischial pressure sore reconstruction by inferior gluteal artery perforator flap. They stated that preserving the perforators adds more resistance to pressure induced ischemia for the fasciocutaneous gluteal flaps and conserves the adjacent muscle for subsequent selection of

flaps in cases of recurrence. Although they reported insufficient supply of subcutaneous tissue and the creation of dead space that resulted in reoperation later with a muscle flap or myocutaneous flap. In addition, meticulous dissection was time consuming, required hand held Doppler assessment, loupe magnification and a long learning curve to avoid injury to the perforators.

Among our twenty cases, early partial dehiscence of the wound occurred in two cases (10%) due to an underlying seroma collection, one of them healed spontaneously; while in the second case, secondary revision of the wound was done. Recurrence occurred in two cases (10%) within 6 months due to prolonged weight bearing on the ischial areas with lack of proper medical and nursing care, they were operated again successfully using the rerotated and advanced inferior gluteus maximus myocutaneous flap, with no recurrence after further 6 months follow-up.

The direct cause for pressure sore development is still present, which explained the recurrence. This illustrates that health care personnel involved with any patient who is prone to pressure sore development must be well informed and strongly motivated for the preventive measures.

In the study of Rajacic et al. [18] on 26 patients using the same flap, they had six cases of early partial dehiscence (23%), three of them healed spontaneously and two cases needed secondary wound revision while in one case a local cutaneous flap was used. Three cases of recurrence in their study (11%) between 6 and 13 months required another flap for closure (posterior thigh flap).

In the study of Kim et al. [9] on 23 patients using the inferior gluteal artery perforator flap, six cases (23%) developed early partial wound dehiscence, two of them healed conservatively while debridement and primary repair was done for the other four. The sore recurred in five cases (21%) after 6 months postoperatively that were treated with muscle transposition flap to fill the dead space. This was sufficient as the overlying skin was redundant.

We believe that including the inferior part of the gluteus maximus muscle as a myocutaneous flap in the repair of ischial pressure sores adds bulk to eliminate dead space, a carrier for reliable blood supply to overlying soft tissue, a mass of cushioning tissue over a pressure-bearing area that will distribute the pressure, and successful rerotation and advancement in case of recurrence.

### Conclusion:

The inferior gluteus maximus myocutaneous flap should be considered as one of the first choices in the treatment of ischial pressure sores. It is easily elevated vascularized bulky flap with low recurrence. Rerotation and advancement in case of recurrence can be done successfully. It also spares the vascular pedicles of adjacent flaps for future use.

### REFERENCES

- 1- Rowling J.T.: Pathological changes in mummies. *Proc. R. Soc. Med.*, 54 (5): 409-412, 1961.
- 2- European Pressure Ulcer Advisory Panel (EPUAP) (2008) [www.epuap.org](http://www.epuap.org)
- 3- Hunter I.A. and Sarker R.: Managing pressure sores. *Surgery (Oxford)*, 29 (10): 518-522, 2011.
- 4- Barbenel J.C., Jordan M.M., Nicol S.M. and Clark M.O.: Incidence of pressure sores in Greater Glasgow Health Board area. *Lancet*, 310 (8037): 548-550, 1977.
- 5- Reis J., Amarante J., Costa-Ferreira A., Silva A. and Malheiro E.: Surgical treatment of pressure sores. *Eur. J. Plast. Surg.*, 22 (7): 318-321, 1999.
- 6- Thoroddsen A.: Pressure sore prevalence: A National survey. *J. Clin. Nurs.*, 8 (2): 170-179, 1999.
- 7- Lefemine V., Enoch S. and Boyce D.E.: Surgical and reconstructive management of pressure ulcers. *Eur. J. Plast. Surg.*, 32 (2): 63-75, 2009.
- 8- Janis J.E. and Kenkel J.M.: Pressure sores. *Selected Readings Plast. Surg.*, 9 (49): 1-42, 2003.
- 9- Kim Y.S., Lew D.H., Roh T.S., Yoo W.M., Lee W.J. and Tark K.C.: Inferior gluteal artery perforator flap: A viable alternative for ischial pressure sores. *J. Plast. Reconstr. Aesth. Surg.*, 62 (10): 1347-1354, 2009.
- 10- Colen S.R.: Pressure sores. In: McCarthy J.G. ed. *Plastic surgery*. Vol. 6. The trunk and lower extremity. Philadelphia: Saunders, 3797-838, 1990.
- 11- Foster R.D., Anthony J.P., Mathes S.L. and Hoffman W.Y.: Ischial pressure sore coverage: A rationale for flap selection. *Br. J. Plast. Surg.*, 50 (5): 374-379, 1997.
- 12- Vasconez L.O., Schneider W.J. and Jurkiewicz M.J.: Pressure sores. *Curr. Prob. Surg.*, 14 (4): 1-62, 1977.
- 13- Foster R.D.: Pressure sores. In: Mathes S.J. editor. *Plastic surgery*. 2<sup>nd</sup> ed., Vol 6. Philadelphia: Saunders/Elsevier, p. 1321, 2006.
- 14- Ichioka S., Okabe K., Tsuji S., Ohura N. and Nakatsuka T.: Triple coverage of ischial ulcers with adipofascial turnover and fasciocutaneous flaps. *Plast. Reconstr. Surg.*, 114 (4): 901-905, 2004.
- 15- Riou J.A., Cohen J.R. and Johnson H.Jr.: Factors influencing wound dehiscence. *Am. J. Surg.*, 163 (3): 324-330, 1992.
- 16- Rubin J.A., Whetzel T.P. and Stevenson T.R.: The posterior thigh fasciocutaneous flap: Vascular anatomy and clinical application. *Plast. Reconstr. Surg.*, 95 (7): 1228-1239, 1995.
- 17- Colen S.R.: Pressure sores. In McCarthy J.G. (Ed): *Plastic*

- Surgery, Vol. 6. Philadelphia: WB Saunders Company, 1990.
- 18- Rajacic N., Gang R.K., Dashti H. and Behbehani A.: Treatment of ischial pressure sores with an inferior gluteus maximus musculocutaneous island flap: An analysis of 31 flaps. *Br. J. Plast. Surg.*, 47 (6): 431-434, 1994.
  - 19- Mathes S.J. and Nahai E.: Clinical atlas of muscle and musculocutaneous flaps. St Louis: Mosby, 91-104, 1979.
  - 20- Schefflan M., Nahai F. and Bostwick J.: Gluteus maximus island musculocutaneous flap for closure of sacral and ischial ulcers. *Plast. Reconstr. Surg.*, 68 (4): 533-538, 1981.
  - 21- Stevenson T.R., Pollock R.A., Rohrich R.J. and VanderKolk C.A.: The gluteus maximus musculocutaneous island flap: refinements in design and application. *Plast. Reconstr. Surg.*, 79 (5): 761-768, 1987.
  - 22- Yamamoto Y., Ohura T., Shintomi Y., Sugihara T., Nohira K. and Igawa H.: Superiority of the fasciocutaneous flap in reconstruction of sacral pressure sores. *Ann. Plast. Surg.*, 30 (2): 116-121, 1993.
  - 23- Stevenson T.R., Pollock R.A., Rohrich R.J. and Craig A.V.: The gluteus maximus musculocutaneous island flap: refinements in design and application. *Plast. Reconstr. Surg.*, 79 (5): 761-768, 1987.
  - 24- Higgins J.P., Orlando G.S. and Blondeel P.N.: Ischial pressure sore reconstruction using an inferior gluteal artery perforator (IGAP) flap. *Br. J. Plast. Surg.*, 55 (1): 83-85, 2002.
  - 25- Ismail H.E.A.: Versatility of perforator sparing buttock rotation flap in repair of pressure sores. *Eur. J. Plast. Surg.*, 35: 89-95, 2012.
  - 26- Wong C., Tan B. and Song C.: The perforator-sparing buttock rotation flap for coverage of pressure sores. *Plast. Reconstr. Surg.*, 119 (4): 1259-1266, 2007.