

## Bat Ear Correction: A New Step to Mark Your Steps and Cover Your Sutures

HISHAM M. EL MINAWI, M.D.; AHMED M. SOBHI, M.D. and ASHRAF A. KHALIL, M.D.

*The Department of Plastic Surgery, Faculty of Medicine, Cairo University*

### ABSTRACT

A transcutaneous suture is placed to mark the suturing of the ear instead of using ink and needles.

*Patients and Methods:* 10 patients with prominent ears were operated upon. 7 females and 3 males. Skin excision was done, then flaps were dissected medially till the periostum of the mastoid removing all fibromuscular tissue and laterally till the helix. The perichondrium is then dissected as a flap based laterally on the helix posteriorly, Creation of the antihelix was done by bending the cartilage posteriorly, and then temporary anterior transcutaneous mattress sutures were applied. After the desired correction is properly achieved, transverse mattress sutures are taken posteriorly just at the edges of the cartilage created by the anterior temporary sutures, Giving you the exact proper correction you have already achieved.

*Results:* The results were satisfactory to the patients, only one patient suffered from a haematoma, another from a hypertrophic scar, and one had to do a redo.

**Key Words:** *Bat ears – Sutures – Ink – Perichondrial flap.*

### INTRODUCTION

The ears contribute to the overall look of the face, and although their contribution is less than those of the eyes and nose, the ears can attract attention [1].

The prominent ear is the most common congenital external ear deformity [2].

A prominent ear, also called a protruding or “lop” ear, is characterised by an increase in the cephaloauricular angle, which arises from a lack of development or underdevelopment of the antihelical fold; an oversized concha; or abnormal attachment of the auricle to the side of the head, alone or in combination [1].

The first description of an operation to correct prominent ears is credited to Dieffenbach in 1845 [2]. Many methods have been described to correct

prominent ears, but no single operation is currently capable of resolving all cases [1].

Improper marking of the cartilage leads to improper folding, which leads to faulty correction, overcorrection, undercorrection or postoperative recurrence of prominence.

Here we propose a simple way to mark the folding of antihelix, by which we have got a nice contour and consistent results.

### PATIENTS AND METHODS

10 patients with prominent ears seeking surgical correction were subjected to our modification over a period of 2 years, in Cairo University Hospital. 7 were females and 3 were males. Age ranges between 9 and 28 (mean age 14). 6 patients had unilateral and 4 had bilateral deformity.

Complete pre-operative assessment was done including history and examination. Analysis of the deformity and proposed surgical correction was discussed with the patient. Together with type of anesthesia, the possible complications and the follow-up. Photos were taken in antero-posterior, lateral and postero-anterior views.

#### *Surgical technique:*

Posteriorly a dumbbell-shaped skin ellipse was marked. All patients were done under local anesthesia. Adrenaline 1/200.000 was injected subcutaneously.

Skin excision was done, then flaps were dissected medially till the periostum of the mastoid removing all fibromuscular tissue and laterally till the helix.

The perichondrium is then dissected as a flap based laterally on the helix posteriorly, Creation of the antihelix was done by bending the cartilage

posteriorly, and then temporary anterior transcutaneous mattress sutures were applied. After the desired correction is properly achieved, now transverse mattress sutures are taken posteriorly just at the edges of the cartilage created by the anterior temporary sutures, giving you the exact proper correction you have already achieved.

The anterior temporary sutures avoids the use of many small needles or the ink for marking.

Prolene 4/0 on a round needle was used (Fig. 2).

Then the perichondrial flap is fashioned and sutured with vicryle 5/0 back to the edge of the remnant cartilage (Figs. 4 & 5).

Dissection of the perichondrium weakens the cartilage and facilitates correction, and suturing it back augments the correction and buries the sutures.

Two or three Concho mastoid sutures are then taken using 3/0 PDS sutures on a round needle.

Skin is then fashioned and closed using 4/0 monocryl.

*Dressing:* Steristrips were applied over the wound edges then vaslinated gauze is stuffed behind the ear and pluffy dressing on the anterior surface which is then wrapped with light elastic bandage (Fig. 1).

## RESULTS

14 auricles in ten patients were corrected with the mentioned technique, they were followed-up every 3 months in the first year, and every 6 months in the second year.

One of the patients developed haematoma, necrosis, extrusion or granuloma of a suture, or infection.

Hypertrophic scarring was encountered in one dark skin patient, and was managed by local steroid injection.

The aesthetic results were quite good, no major deformity or asymmetry encountered. Patient satisfaction was excellent (Fig. 3).

## DISCUSSION

Many techniques were published in literature to correct bat ears, each describing a way to mark the suture points and ways to weaken the cartilage to fix it in place. Gibson and Davis [3] proposed a

method of weakening the anterior surface by abrading the perichondrium to exploit the elasticity of the cartilaginous tissue on the intact side.

Other techniques of weakening the cartilage as with scoring or shaving of the cartilage but may cause over weakening and sharp edges in some cases. With the proposed perichondrial flap undermining, we weaken the cartilage and at the same time we bury our fixation sutures which are sometimes visible from the posterior surface or may cause stitch sinuses. Also refashioning and trimming of the posterior perichondrial flap and later suturing to the cartilage provides a more solid fixation and adds strength to the cartilage suturing and folding.

Although Tolhurst [4] proposed that as a rule it was not necessary to place any sutures into the cartilage after anterior scoring with the implication that if the appearance of the cartilage is not satisfactory, more anterior scoring should at first be tried before resorting to sutures, but yet we think that sutures are very important for fixation and long term stability together with the weakening caused by undermining the posterior perichondrial flap and its fixation after trimming to the cartilage.

Suture extrusion incidence varies from 0%-3.1% in the literature [5,6] with the exception of 6 studies with a high incidence between 11.9%-22.2% [7]. All studies with high incidence reported the presence of suture extrusion as a complication employed a type of non absorbable synthetic suture with sizes from 3/0-5/0 strand diameter, such as gortex, prolene, nylon and polyester.

We had a suture extrusion incidence of 0% although we were using non absorbable prolene, which we believe was due to the coverage with the posterior perichondrial flap, but due to our small patient population, we can't confirm that and further studies with bigger patient population should be done.

The transfixing insulin needles is cumbersome, and leads to inaccurate results, so as the ink method, with the temporary anterior sutures what you see is exactly what you get.

Table (1): Complications in the studied cases.

Complication	Total	%
Infection	0	0
Haematoma	1	7.1
Skin necrosis	0	0
Hypertrophic scarring	1	7.1
Reoperation for recurrence	1	7.1
Stitch sinus	0	0

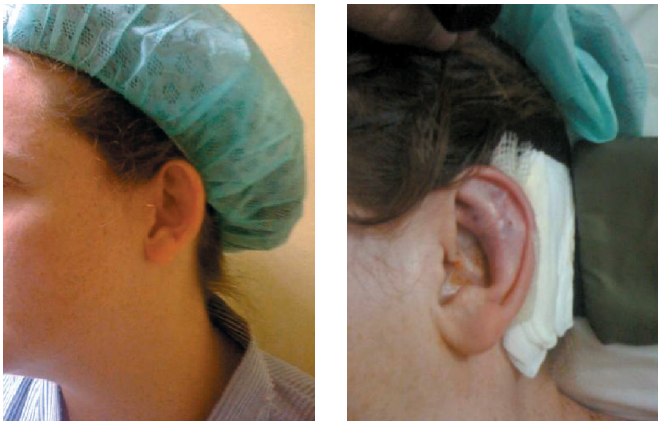

Fig. (1): Before and intraoperative.

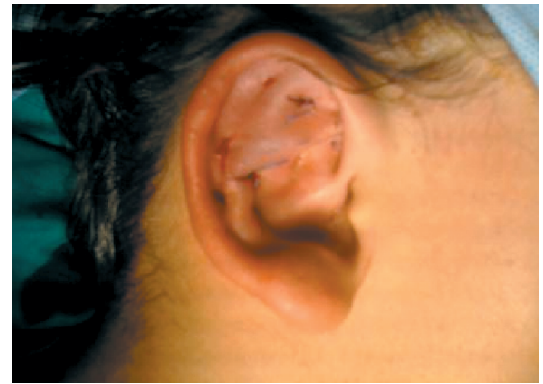

Fig. (2): Transcutaneous sutures.

Fig. (3A,B): Pre and 6 months post operative photos.

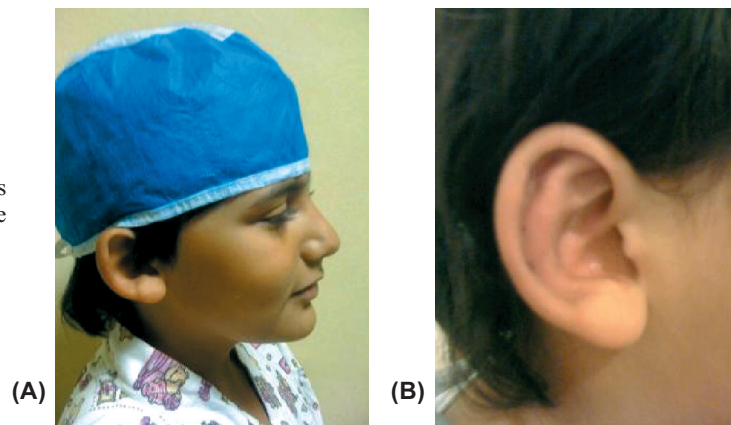


Fig. (4): A- Elevation of the perichondrial flap, B- Suturing the cartilage.

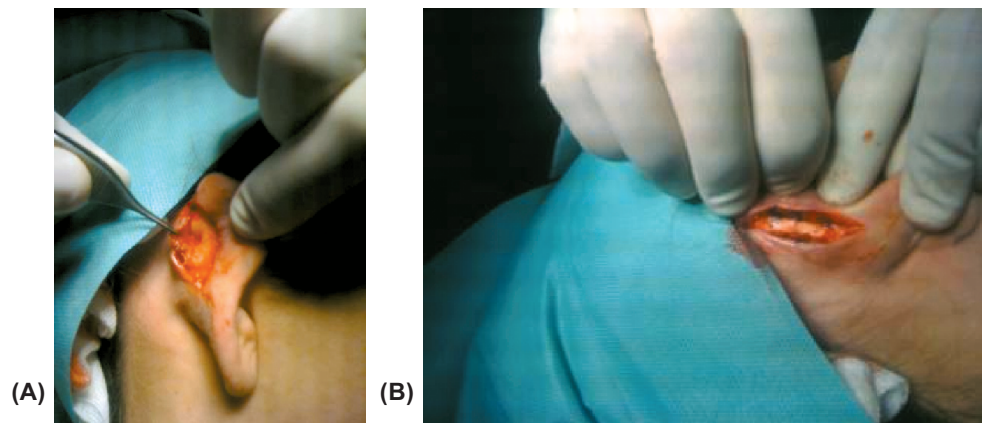
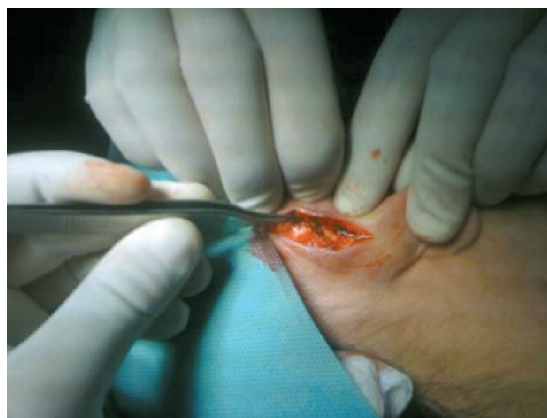

Fig. (5): Coverage of the sutures with the perichondrial flap.



Marking the skin using the transcutaneous sutures allows the surgeon to easily define the suture sites from the posterior surface and prevents the complications arising from the use of needles to mark [1], like needles going out or cutting through the cartilage and also helps to assess how much tension is needed to avoid over or under correction. Also the technique avoids the use of ink for marking which may dye the whole area and is not specific and might cause tattoo.

Our only hypertrophic scar was in a skin type 4 patient where no excessive tension was done, but it is important to note that the keloid formation has a higher occurrence rate in the patients of negroid descent [8], which happens to be the case in our patient.

Redo was done in one ear and was due to pulling on the ear 2 months following surgery, the incidence of redo in literature remains between 1.2%-12% [9].

We believe that the use of this transcutaneous marking technique and the use of the posterior perichondrial flap help to improve the outcome results of otoplasty and the long term results and decreases the incidence of complications and redo.

## REFERENCES

- 1- Attilio Carlo Salgarelli, Pierantonio Bellini, Alessandra Multinu, Barbra Landini, Eugenio Broccaioli and Ugo Consolo: Combined Techniques for the correction of prominent Ears: Results In 140 Patients. *Br. J. Oral Maxillofac. Surg.*, 47: 545-549, 2009.
- 2- Mustarde J.C.: The correction of different types of prominent ears. *Aesth. Plast. Surg.*, 7: 163-8, 1983.
- 3- Gibson T. and Davis W.B.: The distortion of autogenous cartilage grafts: Its cause and prevention. *Br. J. Plast. Surg.*, 10: 257-74, 1958.
- 4- Tolhurst D.E.: The correction of prominent ears. *Br. J. Plast. Surg.*, 25: 261-5, 1972.
- 5- Peker F.C. and Eliköz B.: Otoplasty: Anterior scoring and posterior rolling technique in adults. *Aesthetic Plast. Surg.*, 26: 267-73, 2002.
- 6- Thomas S.S. and Fatah F.: Closed anterior scoring for prominent-ear correction revisited. *Br. J. Plast. Surg.*, 54: 581-7, 2001.
- 7- Bogetti P., Boltri M., Spagnoli G., et al.: Otoplasty for prominent ears with combined techniques. *Eur. J. Plast. Surg.*, 26: 144-8, 2003.
- 8- Hoehn J.G. and Ashruf S.: Otoplasty: Sequencing the operation for improved results. *Plast. Reconstr. Surg.*, 115: 5e-16e, 2005.
- 9- Colpaert S.D. and Missotten F.E.M.: Otoplasty for prominent ears: Personal technique and review of 150 consecutive cases. *Eur. J. Plast Surg.*, 28: 179-85, 2005.