

## Simultaneous Three Layer Closure of the Vestibulonasal Fistula, Correction of the Deformed Lip and the Deformed Nose in Cleft Lip Nose Deformity Patient

AHMAD M. MOHAMAD, BDS,M.D.\* and MOHAMED A. OSMAN, M.D.\*\*

*The Departments of Maxillofacial & Plastic Surgery, Plastic Surgery Unit\*, El-Minia University and Paediatric Surgery\*\*, Assiut University*

### ABSTRACT

*Aim:* The aim of this work is to study the possibility of one stage correction of the deformed lip and the deformed nose together with three layer closure of the associated vestibulonasal fistula in cleft lip nose deformity patients.

*Patients:* Forty patients had cleft lip nose deformity and associated vestibulonasal fistula were chosen for this study. 22 were males and 18 were females. Their mean age at the time of surgical intervention was 10 years. One stage surgical correction of the deformities was done.

*Results:* The esthetics markedly improved in all patients. There were no serious complications of the skin or the mucosal flaps. All the fistulae sites healed properly. The deformed cartilage gained its symmetry. Partial loss of the bone graft from a partial dehiscence in the buccal mucoperiosteal flaps occurred in three patients without affecting the final stability of closure and without recurrence of the fistula. The bone defect completely ossified by the end of the six postoperative month. The overall results were stable and most patients were satisfied.

*Conclusion:* Cleft lip nose deformity patients who have associated vestibulonasal fistula should be surgically corrected all in one go without a need to postpone any.

### INTRODUCTION

Cleft lip nose deformity patients have deformed lip, nose, and alveolus but typically the most striking abnormality is in the nose. Nasal deformity associated with unilateral cleft lip is a complex problem and includes shortness in the vertical height of the columella, depressed tip, outward rotation of the alar base, deviated nasal septum and attenuated lower lateral cartilages in the form of low medial crus, flattened lateral segment, and deficient bulge of alar cartilage [1]. These problems are compounded by a repositioned lateral maxillary segment, maxillary hypoplasia, an alveolar

cleft, residual fistulas, and severe scarring in the nose and lip from previous operations [2].

The secondary deformity involves the lip. It is not uncommon to see patients with cleft lip nose deformity having the following characteristic abnormalities: Wide and vertically short prolabium with a lack of philtral and Cupid's bow definition, shallow buccal sulcus, tight upper lip, irregular scars, and central vermilion insufficiency [3].

Oronasal fistula (ONF) is probably the commonest complication associated with cleft palate surgery. The rate of ONF varies from 4-35% or even more in case of primary palatoplasty. The two main symptoms associated with ONF are nasal regurgitation and speech problems, mainly hypernasality. The site and size of the fistula are variable and so are the causes. ONF develops primarily because of repair under tension and in some cases, especially in adults, as a result of postoperative infection. Vascular accidents during palatoplasty can cause flap loss and is relatively an uncommon reason for development of ONF. Besides these, inadvertent use of diathermy, particularly near the greater palatine pedicle can compromise the blood supply of the mucoperiosteal flap and can result in an ONF [4]. Oronasal fistulas can be located in the labial vestibule [vestibulonasal fistula (VNF)], the alveolus, the hard palate, or at the junction of the hard and the soft palates [5].

Cleft lip and palate and their associated deformities are still treated by surgeons not trained in such operations. This often leads to disastrous results, Patients operated on by surgeons qualified in cleft surgery obtained better results with fewer secondary deformities. Various techniques have

been described for correction of these deformities, which usually involve rearranging of local tissues. Though the early postoperative results may be good, the deformity usually recurs because there is not enough local tissue for reconstruction and repair under tension, which also deforms the shape of the nostril [6].

It is essential to address the different elements of the problem: The bony defect of the maxilla, the nasal deformity and the labial deformity. We also have to keep in mind that the orbicularis muscle has a very significant effect on the growth of the maxilla. Muscular reconstruction is a key to balance the forces acting on the maxilla, the nasal tip and the lip. The lip has to be symmetrical not only at rest, but also on animation, and it has to grow symmetrically [7].

Closing the cleft maxillary defect from the incisor foramen, along the floor of the nose and reaching the labial sulcus allows the surgeon to build a stable base to adjust the lip. Placing the affected alar cartilage symmetrical to the normal side also has to be done before lip closure. Finally, during the muscular reconstruction, the lateral orbicularis is used to centralize the columella and lengthen the central segment [7].

The principal objective of correcting nasal deformities associated with cleft lip is to achieve nasal symmetry, projection of the tip, and an improved nasolabial relation [8]. Successful narrowing of the nasal root was achieved by open rhinoplasty and the simultaneous removal of the segments of bone from the ascending frontal process of the maxilla and the lateral side of the nasal bone [9].

The surgical repair of an alveolar cleft and oronasal fistula is a challenging issue for both orthodontists and maxillofacial surgeons. Management of alveolar clefts and associated oronasal fistulae is required for bone support of the teeth adjacent to the cleft site, maintenance of a bony matrix required for eruption of the teeth aligned with the cleft site, bone continuity in the maxillary arch and for creation of satisfactory alveolar bone contour. Arch width will be maintained and collapse of the maxillary arch will be prevented. Closure of the oronasal fistulae also improves the oral hygiene by separating the nasal and the oral cavities. Treatment is also necessary to improve facial symmetry, support the alar base, and to improve the nasolabial contour [10]. Secondary bone grafting at the stage of mixed dentition in conjunction with

orthodontic treatment has become a well-established treatment modality [11].

The anatomical and functional deformity of the orbicularis oris muscle also contributes to the nasal deformity [12]. So, union of the orbicularis muscle from the cleft and non cleft sides in unilateral cleft cases and from both lateral elements across the premaxilla in bilateral cleft cases should be given adequate emphasis [13].

## PATIENTS AND METHODS

This research work has been approved by the local ethical committee of the University Hospital and all patients signed and gave informed consent form.

*Inclusion criteria:* Forty patients had cleft lip nose deformity and associated VNF were seen at the Maxillofacial and Plastic Surgery Unit, General Surgery Department, El-Minia University. 22 were males and 18 were females. Their age at the time of surgical intervention ranged between 9 and 15 years. The mean was 10 years. 32 patients had unilateral deformity and 8 had bilateral deformity. 6 out of these 8 had bilateral VNF and 2 had unilateral VNF (Figs. 1,2). The total number of VNF were 46. Associated anterior palatal fistula was detected in 14 patients (Fig. 3). Patients were evaluated radiologically by an upper occlusal film and by panoramic X-ray.

Patients had esthetic deformity and functional defects. The esthetic deformities included the lip and the nose. The associated labial deformities were in the form of whistle deformity in 19 patients, short prolabium in 22 cases, malaligned Cupid's bow in 16 cases. The associated nasal deformities were in the form of depressed lower lateral cartilage in all cases, short columella with depressed tip in 17 cases and deviated nasal septum in 14 cases. Functional defects were in the form of nasal regurgitation and hypernasality in patients had associated VNF and anterior palatal fistula. Difficult breathing was due to the deviated septum, the depressed tip and the depressed lower lateral cartilage Table (1).

*Exclusion criteria:* Patients had cleft lip nose deformity not associated with VNF were excluded from this study. Younger patients who had wide VNF closed without bone grafting by just creation of a periosteally lined box were also excluded.

*Surgical technique:* All operations were done under general anaesthesia with oral intubation. The

lip was in need to be revised in 28 patients, so it was opened in a way that allowed excision of the old scar, preservation of the Cupid's bow, and its final closure with simultaneous correction of the lip defect. The lip was not in need to be revised in 12 patients, so it was left intact in these patients. To lengthen a short prolabium, the incision was done in a rhomboid fashion to be finally closed in a straight line. To level a malaligned Cupid's bow, it has been opened in a Z shaped manner to finally align it. The lip was opened down to the mucosa. Bilateral gingival envelop mucoperiosteal flaps were elevated on both sides of the fistulous tract. The edges of the fistula were incised to expose the rent in the nasal mucosa (Fig. 4). Two lateral cuts were made in the nasal mucosa so as to build four hinge flaps (Two were superiorly based and two were inferiorly based). The two superiorly based flaps were closed together water tight so as to build the floor of the nose. The two inferiorly based flaps were used to close the anteriorly situated palatal fistula if present after harvesting two lateral palatal mucoperiosteal flaps (Figs. 5-7). Cancellous bone graft was harvested from the anterior iliac crest and used to close the alveolar defect between the newly reconstructed nasal floor above and the palatal mucosa below (Fig. 8). It has been put as an onlay graft on the piriform rim to augment the depressed piriform aperture. Cases had bilateral VNF have been staged to avoid interference of the blood supply of the premaxilla (Fig. 9).

The lip incision was extended to complete a reverse U nasal vestibular incision (closed rhinoplasty) in 23 patients. By using blunt and sharp dissection, both lower and upper lateral cartilages were fully exposed as far as the lower part of the nasal bones. Suspension of the depressed lower lateral cartilage was done by prolene (4/0) stitch to the upper lateral cartilage. When the lower lateral cartilage was thin, rudimentary, or had been spoiled by previous surgery, a conchal or septal cartilage was shaped and used as an onlay graft to create a dome. Straightening of the septal cartilage was also done after submucous resection [14].

Open rhinoplasty was carried out in 17 patients using the bilateral reverse-U incision and transcolumellar rim incisions made bilaterally on the outer skin just above the upper end of the labial incision [15]. In order to lengthen the columella, a collumellar cartillagenous strut harvested from the conchal cartilage or from the caudal end of the septal cartilage was applied. A wedge excision of the nasal floor and alar cinch on the cleft side gave a good approximation of the alar base. The suspended

lower lateral cartilage was further protected by a transvestibular stitch tied over a piece of gauze fixed over the skin [16,17] (Table 2).

The nasal vestibular and collumellar incisions were then closed. Finally the labial incisions were closed after dissection, approximation and fixation of the orbicularis oris muscle at the base of the collumella.

Patients were followed-up for a mean of one and half year postoperatively. They were evaluated clinically for the improvement in their esthetics and function and for the recorded complications. They were also evaluated radiologically by panoramic X-ray and by upper occlusal films to detect the condition of the bone graft.

## RESULTS

*The immediate postoperative period:* Passed uneventful in all patients except for mild edema in the lip and nose. Patients were reassured that this is transient and will subside within days. The esthetics markedly improved in all patients and all were satisfied especially as regard the tip projection, the symmetry of the lower lateral cartillages and the symmetry of the lip and nose. Successful columella lengthening was achieved. The whistling deformity disappeared. The lateral profiles have been improved. Nasal regurgitation stopped, the voice improved and the breathing improved in all patients.

There were no serious complications of the skin or the mucosal flaps, such as necrosis, infection or any obvious scars. Although the nasal skeleton looked symmetrical, an alar web was noticeable in four patients. Three-dimensional reduction of the alar web was done.

*Late postoperatively:* All the fistulae sites healed properly (Fig. 10). The deformed cartilage gained its symmetry (Figs. 11,12). The columellar projection shortened to a mild degree in three patients. The memory of the lateral alar cartilage resulted in mild relapse in two cases. None of the cases needed revision. Partial loss of the bone graft from a partial dehiscence in the buccal mucoperiosteal flaps occurred in three patients without affecting the final stability of closure and without recurrence of the fistula. This partial dehiscence was managed conservatively. No donor site morbidity developed. Radiologically, the bone defect completely ossified by the end of the six postoperative month. The overall results were stable and most patients were satisfied.



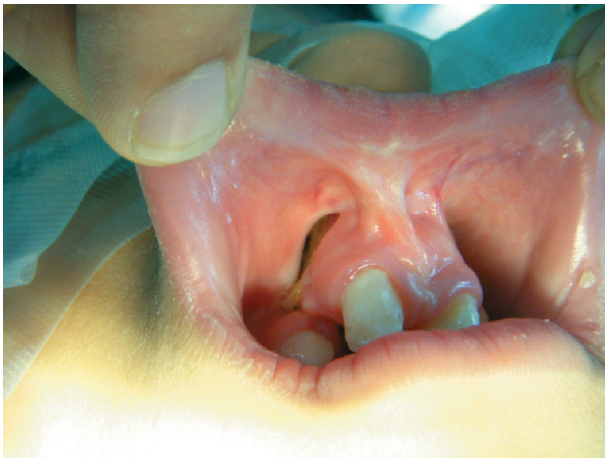

Fig. (1): Rt sided VNF.

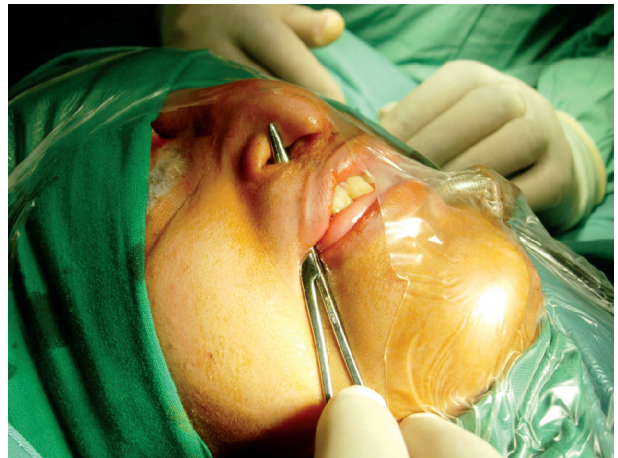

Fig. (2): Fistulous tract followed by a mosquito inside.

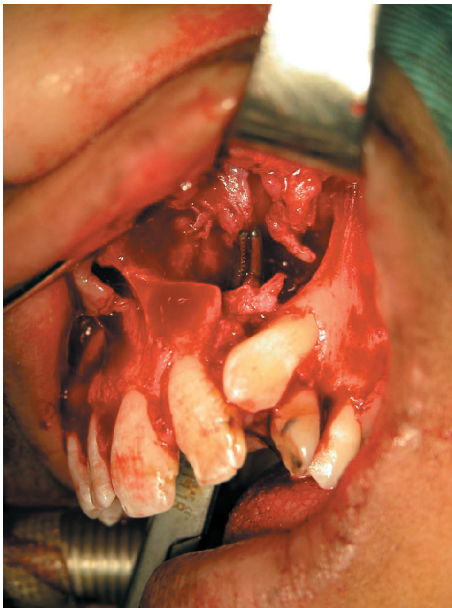

Fig. (3): Rent in the nasal mucosa appeared after dissecting the edges of the fistulous tract.

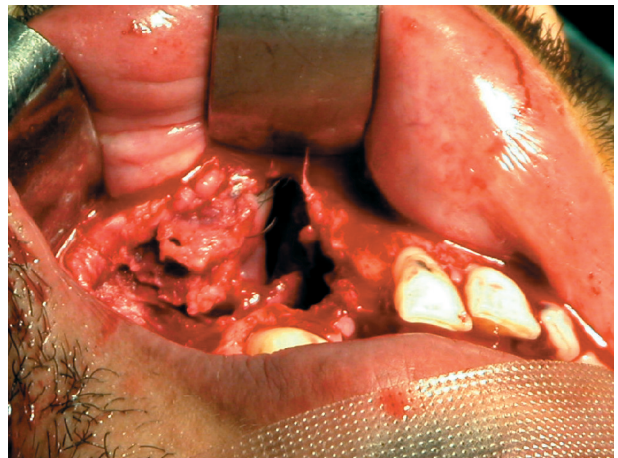


Fig. (4): Associated anterior palatal fistula identified by a mosquito inside.

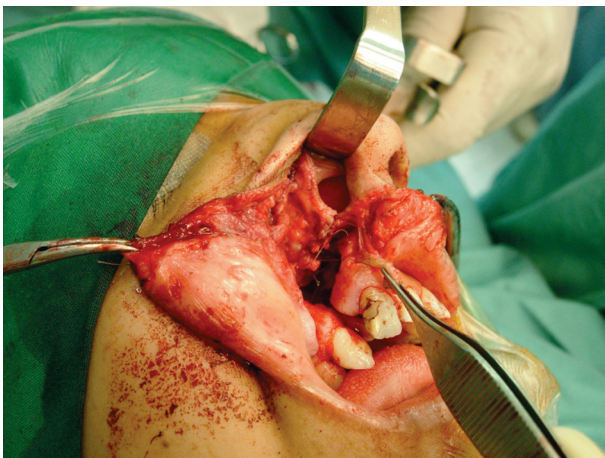


Fig.(5): Nasal mucosa accessed and repaired after opening the lip.

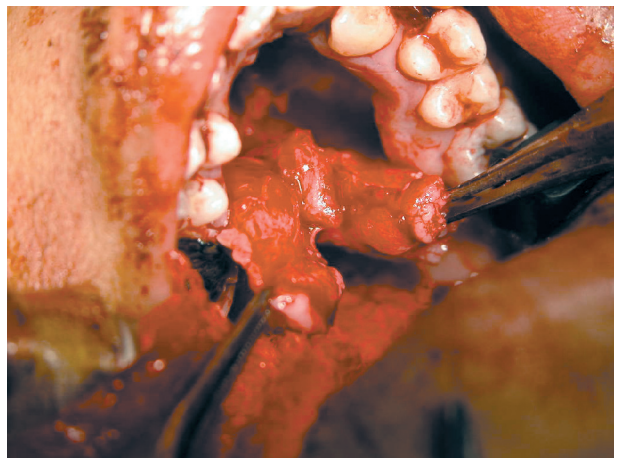


Fig. (6): Two palatal mucoperiosteal flaps raised so as to close the associated anterior palatal fistula.



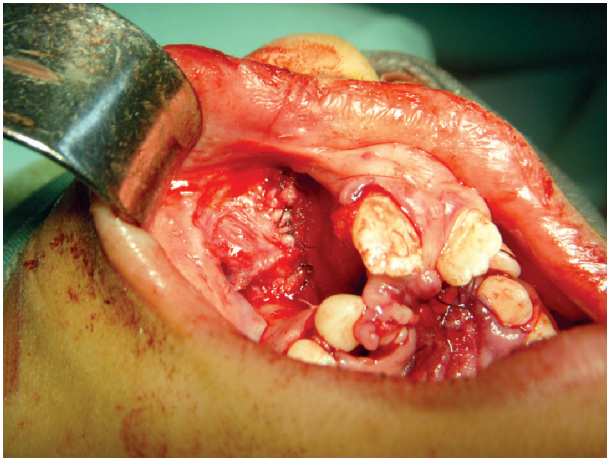


Fig. (7): Nasal mucosa accessed and repaired without opening the lip. The palatal mucoperiosteal flaps also has been closed thus creating a room for the bone graft.

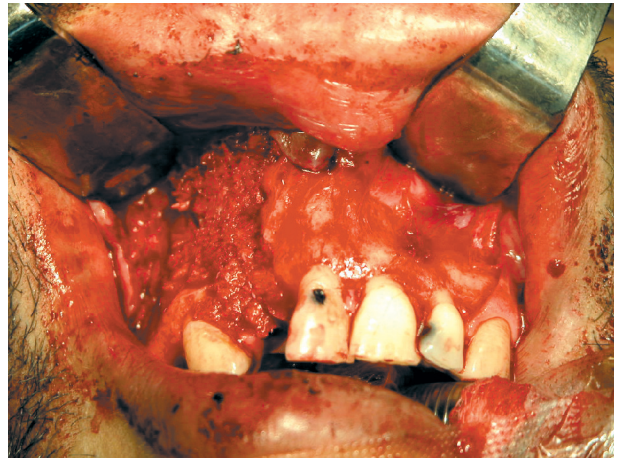


Fig. (8): Cancellous bone graft used to bridge the bony defect.

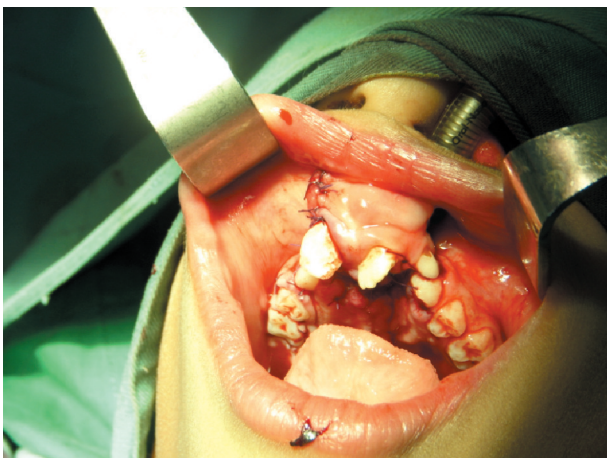


Fig. (9): A repaired VNF as appeared 2 months postoperative.

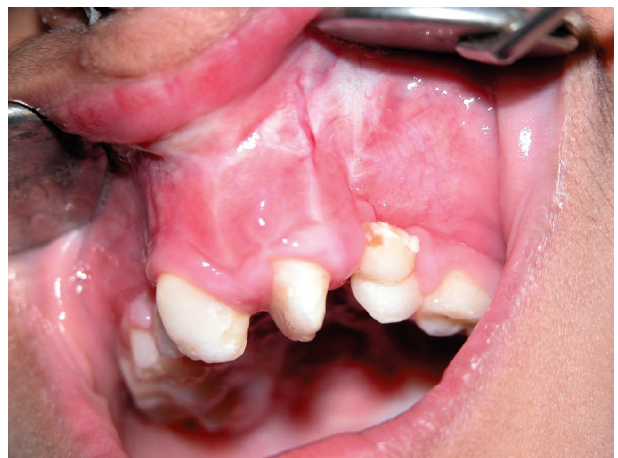

Fig. (10): A staged surgery for bilateral VNF. One side only repaired at a time.

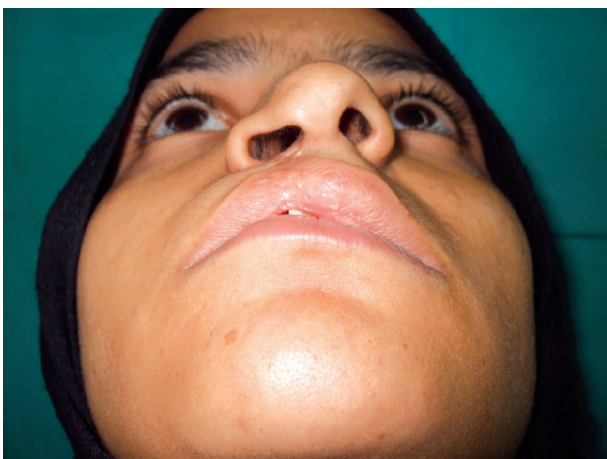


Fig. (11): Cleft lip nose deformity patient with depressed lower lateral cartilage.

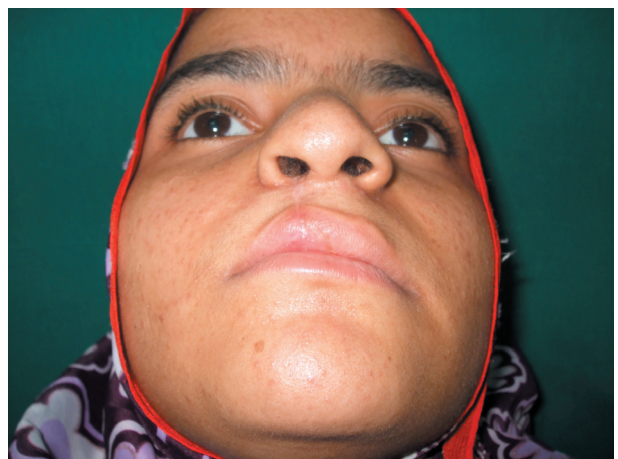

Fig. (12): A six month postoperative view of the same previous patient.

Table (1): Associated lip and nose deformities.

Lip Deformities	- Short prolabium	22
	- Whistle deformity	19
	- Malaligned Cupid's bow	16
Nose Deformities	- Depressed lower lateral cartilage	40
	- Short collumella with depressed tip	17
	- Deviated nasal septum	14

Table (2): Distribution of the associated deformity, associated fistulae and the access utilized for correction.

Sex	22 males	18 females
Deformity	32 unilateral deformity	8 bilateral deformity 6 with bilateral VNF 2 with unilateral VNF
Fistulae	46 total VNF	14 palatal fistula
Lip	28 revised	12 not revised
Rhinoplasty	23 closed	17 open rhinoplasty

## DISCUSSION

The main goal of surgical treatment of children with clefts is to restore symmetry, anatomy, and function of the face, particularly in the area of the cleft [18].

Despite early surgical intervention in bilateral cleft patients, lack of tip projection, an associated short columella, and displaced lower lateral cartilages often result. However the extent of secondary deformity is definitely less in those who have undergone primary correction [19,20].

In cases where the lip needs a revision surgery, it is always advisable to open the lip and do a revision along with the ONF repair. The access to the fistula becomes more direct and the nasal floor repair becomes easier and better. For patients with an anterior fistula, who present during mixed dentition period, it is preferable to prepare the child orthodontically and to perform an alveolar bone graft in the same sitting [21].

Most ONF adjacent to the residual cleft after palatal repair are seen in the anterior palate and the oral vestibule (VNF). These ONF cannot be neglected as they might cause speech problems as well as food regurgitation. The conventional surgical procedure for large fistulas consists of local mucoperiosteal turnover flap repair and tongue flap repair. Tongue flap is reliable, but it is burdensome for patients because of restrictions in mouth-opening and the need for a two-stage operation [5].

Secondary bone grafting combined with closure of the fistula in the residual cleft is a well-established procedure. The gingival mucoperiosteal flaps have a broad base and excellent vascularity and provide after adequate mobilization, a tension free closure [22].

Secondary bone grafting is usually done between the ages of 9 and 11 years (during mixed dentition) before eruption of the permanent canine to facilitate the eruption of the teeth, stabilize the dental maxillary arch and to improve the conditions for orthodontic and prothodontic treatment. The final corrections to the nose are made at the end of adolescence. Though a few centers still perform primary bone grafting, it was abandoned in most cleft palate centers worldwide as it causes serious growth disturbance of the middle third of the facial skeleton [18].

The nasal growth is complete at approximately 11 to 12 years of age in girls and 13 to 14 years of age in boys. The most common age for revision of the cleft lip nose is between four and five years. At this age, the child's social interactions are increasing and the stigmata associated with the deformity may cause problems for the child [23-25].

Bardach and Salyer [26] delayed secondary correction until the patient was eight to 12 years old for three reasons: (1) to allow completion of orthodontic correction of the skeletal base; (2) to allow as much growth and development of the lower lateral cartilages as possible and thus to have a stronger, more stable support for the reconstructed nasal tip; and (3) to allow bone grafting of the hypoplastic maxillary segment on the cleft side, which when performed in patients aged eight to nine years results in a more symmetric alar base.

Ortiz-Monasterio and Ruas [27] specified that besides repositioning the lower lateral cartilage, lengthening the columella and bringing it to midline, and correcting the asymmetries of the nasal floor, additional structural support in the form of bone and cartilage grafts are required to achieve adequate projection and angularity. Sheen [28], described a graft procedure by which a heart-shaped conchal or septal cartilage was fixed to both the domes with nonabsorbable sutures to obtain both projection and increased angulation at the columellar-lobar junction. Peck et al. [29], used an "umbrella graft" that consisted of a vertical cartilaginous strut between the medial crura and



a horizontal onlay graft that overlay the alar dome. Umbrella grafts support the nasal tip pyramid and re-establish the projection of the nasal tip. Takato et al. [30] in 1995 advocated the use of a strut graft to contour the columella and define the tip. The correction of the tip by anterior reinsertion of a septal chondral graft through open exposure of the nasal frame has been emphasised. Long-term stability of raised and repositioned cartilages is improved by direct suturing together by Skoog's mattress key stitch as reported by Ozcan [31]. Superior correction is possible in case of severe, septal, bony, nasal deformities. The scar is concealed by the modified transcolumellar incision at the root of the columella. V-Y plasty of the nasal mucosa on the cleft side gives exceptional correction of the alar webbing [33]. Lengthening of the columella provides structural support for the columella and reduces the tension on the redraped nasal skin. Correction of the soft tissue along with the bony and cartilaginous deformities gives a good contour to the nose. This relatively simple, one stage procedure is ideal for creating the optimal nose in patients with unilateral CLP [33].

## REFERENCES

- 1- Saha S.S., Kumar V., Khazanchi R.K. and Aggarawal A.A.: Correction of the nose in patients with unilateral cleft lip with composite grafts. *Scand J. Plast. Reconstr. Surg. Hand Surg.*, 39: 344-348, 2005.
- 2- Stal S. and Hollier L. Correction of secondary deformities of the cleft lip nose. *Plast. Reconstr. Surg.*, 109: 1386-93, 2002.
- 3- Lo L.J., Kane A. and Chen Y.R.: Simultaneous reconstruction of the secondary bilateral cleft lip and nasal deformity: Abbe flap revisited. *Plast. Reconstr. Surg.*, 112: 1219, 2003.
- 4- Sadhu P.: Oronasal Fistula in Cleft Palate Surgery, 42 (3): 123-128, 2009.
- 5- Fukuda M., Iino M. and Takahashi T.: Closure of oronasal fistulas at the time of secondary bone grafting in patients with cleft lip and palate. *Scand J. Plast. Reconstr. Surg. Hand Surg.*, 37: 339-343, 2003.
- 6- Cho B.C., Park J.W. and Baik B.S.: Correction of severe secondary cleft lip nasal deformity using a composite graft: Current approach and review. *Ann. Plast. Surg.*, 48: 131-7, 2002.
- 7- Laberge L.C.: Unilateral cleft lip and palate: Simultaneous early repair of the nose, anterior palate and lip. *Can. J. Plast. Surg.*, 15 (1): 13-18, 2007.
- 8- Takato T., Eguchi T., Omori M., et al.: Secondary correction of unilateral cleft lip nose. *Jpn. J. Plast. Reconstr. Surg.*, 43: 1183-1192, 2000.
- 9- Omori M., Takato T., Eguchi T., Mori Y. and Tomizuka K.: Secondary correction of the wide nasal root in bilateral nasal deformity associated with cleft lip in five oriental patients. *Scand J. Plast. Reconstr. Surg. Hand Surg.*, 37: 216-219, 2003.
- 10- Zafer Z.P., Hancioglu B.K., Bayram B., Kircelli C. and Uckan S.: Alveolar Cleft Closure by Distraction Osteogenesis with Skeletal Anchorage During Consolidation. *J. Oral Maxillofac. Implants*, 23: 147-152, 2008.
- 11- Aurouze C., Moller K.T., Bevis R.R., Rehm K. and Rudney J.: The presurgical status of the alveolar cleft and success of secondary bone grafting. *Cleft Palate Craniofac. J.*, 37: 179-184, 2000.
- 12- Sabry A.A. and Ramadn M.M.: Correction of Secondary Deformities of the Cleft Lip Nose. *Suez Canal Univ. Med. J.*, 11 (1): 1-7, 2008.
- 13- Thomas C. and Mishra P.: Open tip rhinoplasty along with the repair of cleft lip and palate cases. *British J. Plast. Surg.*, 53: 1-6, 2000.
- 14- S.M. Balaji: One-stage correction of severe nasal deformity associated with a unilateral cleft lip. *Scand J. Plast. Reconstr. Surg. Hand Surg.*, 37: 332-338, 2003.
- 15- Tajima S., Ueda K., Akamatsu J. and Ohba S.: Bilateral reverse U incisions and separately placed columella relaxation incision for correction of bilateral cleft lip nose deformity. *Eur. J. Plast. Surg.*, 20: 19-23, 1997.
- 16- McComb H.K.: Primary repair of the bilateral cleft lip nose: A 4-year review. *Plast. Reconstr. Surg.*, 94: 37-50, 1994.
- 17- McComb H.K. and Coghlan B.A.: Primary repair of the unilateral cleft lip nose: Completion of a longitudinal study. *Cleft Palate Craniofac. Surg.*, 33: 23-31, 1996.
- 18- Baeyens W., Daelemans A., Leloup T. and De May A.: Study of changes in nasal morphology in children with complete unilateral cleft lip and palate after secondary bone grafting measured with image analysis. *Scand J. Plast. Reconstr. Surg. Hand Surg.*, 40: 345-351, 2006.
- 19- Jablon J.H. and Sykes J.M.: Nasal airway problems in the cleft lip population. *Facial Plast. Surg. Clin. North Am.*, 7: 391-403, 1999.
- 20- Kumar A. and Singh A.K.: Bilateral cleft lip nasal deformity. *Indian J. Plast. Surg.*, 42 (2), 2009.
- 21- Sadhu P.: Oronasal fistula in cleft palate surgery. *Indian J. of Plastic Surg.*, 42 (3): 123-128, 2009.
- 22- Ochs M.W.: Alveolar cleft bone grafting (Part II): Secondary bone grafting. *J. Oral Maxillofac. Surg.*, 54: 83-88, 1996.
- 23- Stal S. and Hollier L.: Correction of secondary deformities of the cleft lip nose. *Plast. Reconstr. Surg.*, 109: 1386-92, 2002.
- 24- DE MEY A., MALEVEZ C., MANSBACH A.L. and GEORGE M.: Management of cleft lip and palate in Queen Fabiola Children's Hospital of Brussels. *Ann. Chir. Plast. Esthet*, 47: 134-7, 2002.
- 25- Swennen G., Berten J.L., Schliephake H., et al.: Midfacial morphology in children with unilateral cleft lip and palate treated by different surgical protocols. *Int. J. Oral Maxillofac. Surg.*, 31: 13-22, 2002.
- 26- Bardach J. and Salyer K.E.: Correction of nasal deformities associated with unilateral cleft lip. In Bardach J. and

- Salyer K.E. (eds) *Surgical Techniques in cleft lip and palate*. Chicago, Year Book Medical Publisher. 1987.
- 27- Ortiz-Monasterio F. and Ruas E.J.: Cleft lip rhinoplasty. *Clin. Plast. Surg.*, 16: 177-186, 1989.
- 28- Sheen J.H.: Tip graft: A 20-year retrospective. *Plast. Reconstr. Surg.*, 91: 48-63, 1993.
- 29- Peck G.C. Jr., Michelson L., Segal J. and Peck G.C. Sr.: An 18 year experience with umbrella graft in rhinoplasty. *Plast. Reconstr. Surg.*, 102: 2166-2168, 1998.
- 30- Takato T., Yonehara Y. and Susami T.: Early correction of the nose in unilateral cleft lip patients using an open method: A 10-year review. *J. Oral Maxillofac. Surg.*, 53: 28-33, 1995.
- 31- Ozcan G.: A modified technique to correct the cleft lip nasal deformity. *J. Craniomaxillofac. Surg.*, 17 (1): 14-16, 1989.
- 32- Cho B.C., Lee J.H., Cohen M. and Baik B.S.: Surgical correction of unilateral cleft lip nasal deformity. *J. Craniofac. Surg.*, 9: 20-29, 1998.
- 33- Cronin T.D. and Denkler K.A.: Correction of the unilateral cleft lip nose. *Plast. Reconstr. Surg.*, 82: 419-432, 1988.