

Evaluation of Joint Distractor in Distraction Histogenesis of Long-Term Flexion Contractures of Proximal Interphalangeal (PIP) Joint of the Hand

ISMAIL S. MOSTAFA, F.R.C.S., M.D.

The Department of Plastic and Reconstruction Surgery, Faculty of Medicine, Mataria Teaching Hospital

ABSTRACT

Materials and Methods: The study was conducted on 20 fingers, 12 males and 7 females (one female had post-burn contracture of PIP joint of the ring and middle fingers) between 21 and 50 years old, the average age was 30.5 years.

The cases were collected from the outpatient Clinic of Plastic and Reconstructive Surgery Department of Mataria Teaching Hospital in the period between March 2009 and October 2010.

Conclusion: In conclusion, soft tissue distraction is a simple and an excellent technique for managing long standing flexion contracture of the PIP joint. Low cost and low morbidity and as the procedure was done under local ring anesthesia makes this modality of treatment is a good alternative to the conventional technique used to treat such cases.

INTRODUCTION

Flexion deformity of the proximal interphalangeal (PIP) joint of different causes is usually completed by shortening of volar soft tissue and joint contracture [1,2]. The conventional treatment consists of a combination of arthrolysis, capsulotomy, tendon work, soft tissue coverage and physiotherapy [1,3]. Frequently this does not achieve good results [4,5,12].

The surgical release of a digital joint contracture can cause excessive stretching of the neurovascular bundle resulting in damage to these structures. Progressive gradual lengthening by distraction prevents such complication allowing the release of joint contractures [6].

This technique is not applicable in all patients' especially younger patients and those who have history of cut flexor tendon, as they need tendon repair [11]. Also patients who have bony ankylosis of the PIP joint are not candidates for such technique. Joint distraction technique was first reported

by Kalonaii and Miloslavskii in 1987 in the former Soviet Union [13].

In this study, long term PIP joint flexion contracture is managed by joint distraction to evaluate its efficacy for distraction histogenesis as a modality of treatment for such patients.

PATIENTS AND METHODS

This study was applied on 20 fingers presented with long standing flexion contractures of PIP joint due to either congenital (camptodactyly), trauma or burn. The patients in this study were selected according to certain criteria. The patients are between 20 to 50 years old from both sexes either previously exposed to skin graft operation or not. Preoperative X-ray for the PIP joint must show intact joint space.

Children and young patients who have a history (or clinically proved) of cut flexor tendon and those who have bony ankylosis or dislocation of PIP joint are excluded from this study. Informed consent was taken from each patient.

The study was conducted on 20 fingers, 12 males and 7 females (one female had post-burn contracture of PIP joint of the ring and middle fingers) between 21 and 50 years old, the average age was 30.5 years.

The cases were collected from the outpatient Clinic of Plastic and Reconstructive Surgery Department of Mataria Teaching Hospital in the period between March 2009 and October 2010.

The procedures were done using local ring anesthesia the distractor has two metal limbs with a joint in-between and two Kirschner wires (K-wires) of 1.5mm size in each limb. There are two

screw drivers, one is used for flexion and extension of the two metal limbs and the other one is used for adduction and abduction of the two metal limbs (Fig. 1).

After sterilization and draping the hand of the patient. The K-wires were inserted from the medial or lateral side of the phalanges using pneumatic drill. The distractor was applied and fixed to the Kirschner wires using the screw driver, confirming that the joint of the distractor is facing the PIP joint while the two limbs of the device were parallel to the proximal and distal phalanges.

The distractor was activated to extent the PIP joint using its screw driver. The activation of the device was done twice weekly to extent the PIP joint till pain sensation or pallor of the contracted volar tissue. Local antibiotic was applied around the k-wires during the post-operative period.

After full extension of the finger, the distractor was left for one week in place and removed after that. Physiotherapy was conducted till maximum rang of movement.

The 1st patient was suffering from post burn contracture of the PIP joint of the middle finger and the distal interphalangeal joint of the index finger. She was operated on by release and graft of the distal inter phalangeal joint of the index finger, while distraction histogenesis was done for the PIP joint of the middle finger to compare the esthetic results of the traditional technique with our procedure (Fig. 2). The 2nd patient presented with congenital flexion deformity (camptodactyly) of the little finger (Fig. 3). The 3rd patient was having post burn severe flexion deformity of the PIP joint of the little finger (Fig. 4). The 4th patient was suffering from post burn contracture of the PIP joint of both the middle and ring fingers.

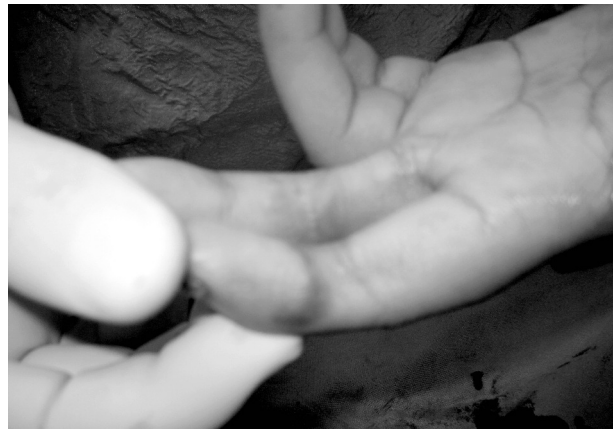

Fig. (2-A)

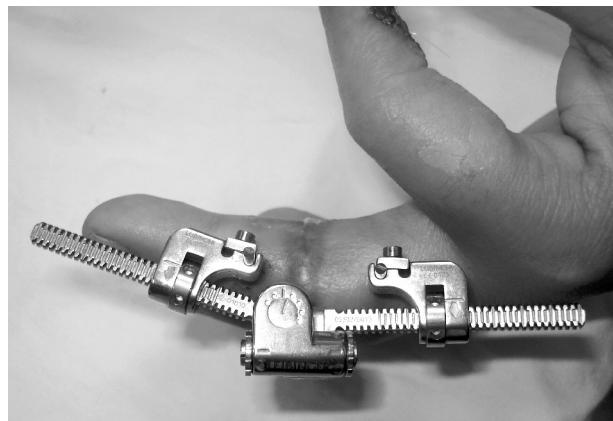


Fig. (2-B)

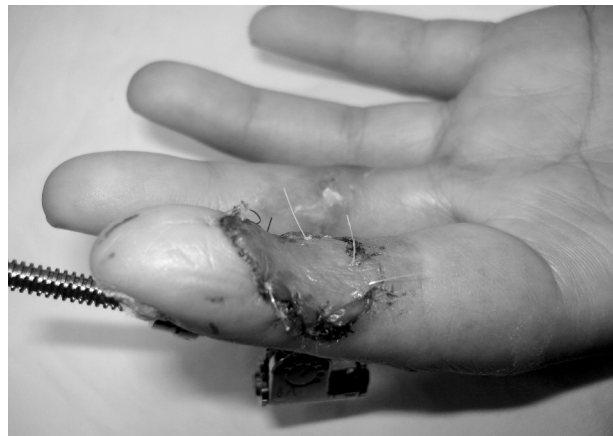

Fig. (2-C)

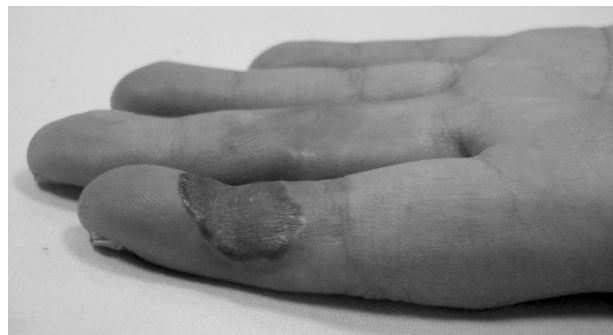

Fig. (2-D)

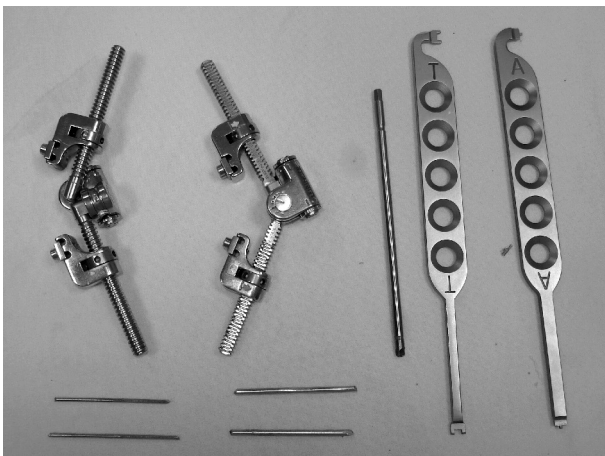


Fig. (1)

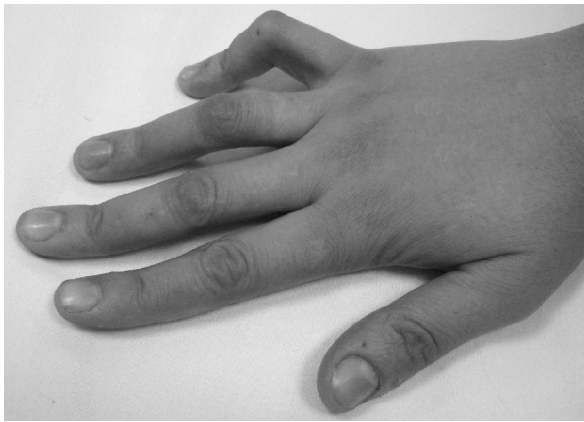


Fig. (3-A)

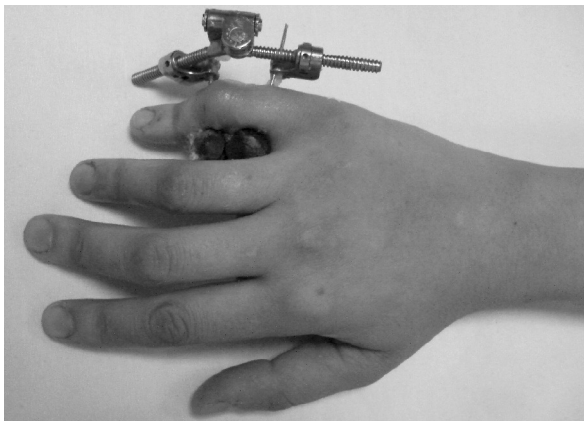


Fig. (3-B)

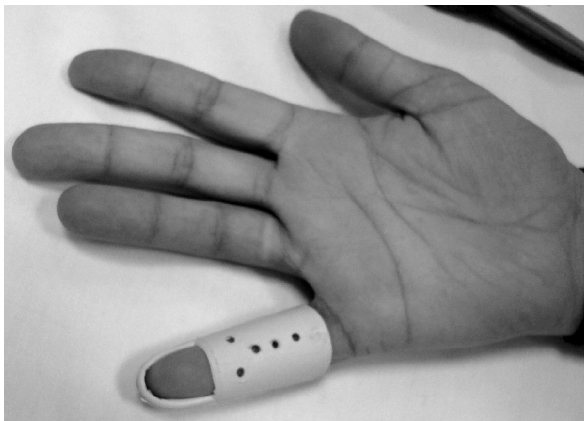


Fig. (3-C)

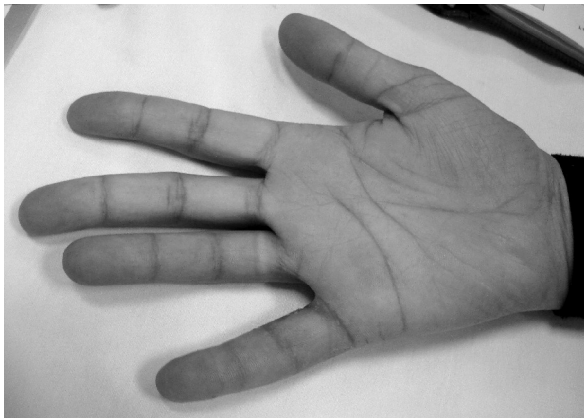


Fig. (3-D)

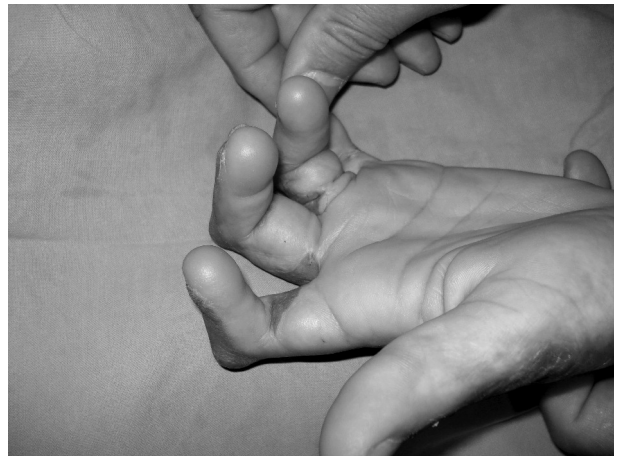

Fig. (4-A)

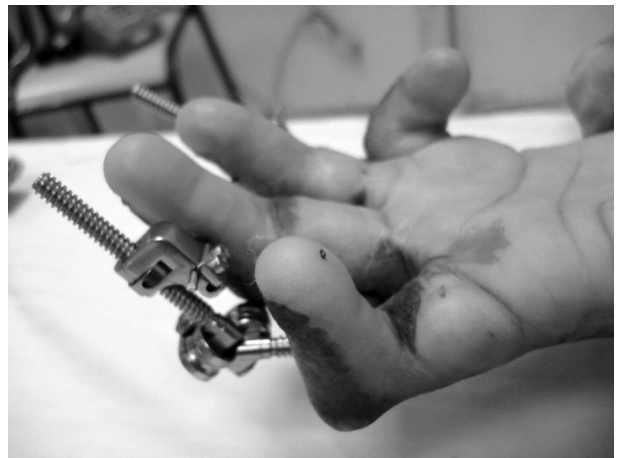

Fig. (4-B)

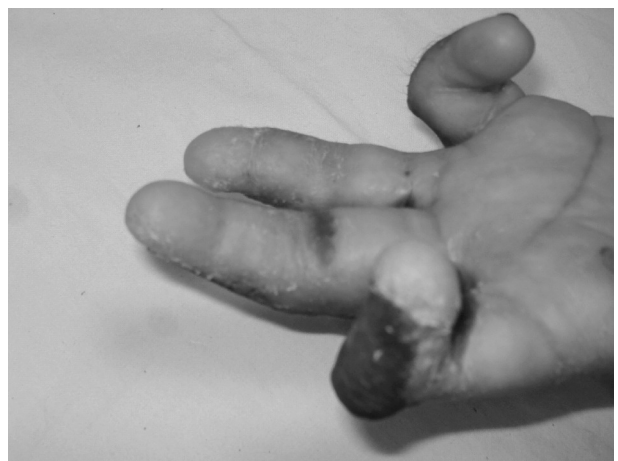

Fig. (4-C)

RESULTS

Distraction of volar soft tissue contracture of the PIP joint was performed to correct 20 fingers of 19 patients. The contracture was due to burn in 12 fingers in 11 patients, 5 fingers due to trauma in 5 patients and 2 fingers in 2 patients with campodactyly.

Full extension was achieved in all fingers. One patient needed Z-plasty in the medial side of the metacarpophalangeal joint of the little finger as there was a band in that area, another patient presented with local infection around the wires. This infection was controlled with local and systemic antibiotic.

The range of movement (ROM) in all patients was improved (10-35 degrees). In all patients a program of physiotherapy was followed after removal of the distractor. This program was needed for about 2 months with improvement in the ROM.

No relapse was found in any finger for about 2 months although 3 patients were lost during the post operative follow-up period. No surgical interference was needed in any case on the contracted area of the PIP joint. All patients reported better function and aesthetic results.

DISCUSSION

Soft tissues of the human body respond well to gradual lengthening. Post burn soft tissue contracture and congenital radial club hand respond well to distraction histogenesis [5,6,8]. Flexion contracture is a common deformity in palmar burns [1]. The pathogenesis of the congenital deformity of the PIP joint (camptodacty) is not clear, however all the structures around the joint are affected [9].

Traditional methods for management of long standing flexion deformity of the PIP joint involve multistage release, reconstruction and skin graft to avoid neurovascular insult. There are many mechanical factors that may limit the excursion of the joint. The progressive distraction at the joint allowed the lengthening of the contracted structures and at the same time caused the rupture of the flexor tendon adhesions without causing any damage to the neurovascular structures [10]. Gradual soft tissue distraction was used to lengthen post burn contracture of the foot [5] and the wrist [7].

In this study we used only one distractor for each finger as the distractor has a joint between its two limbs, so there was neither stress nor deviation of the articular surfaces of the PIP joint. Sherine et al., 2007 mentioned that the use of two distractors for each finger prevented deviation and articular surface compression.

The electron microscopic examination of the distracted tissue showed that the collagen fibers that were intact at the beginning of the distraction started by fragmentation with signs of immaturity and increased mitosis at the end [7].

In conclusion, soft tissue distraction is a simple and an excellent technique for managing long standing flexion contracture of the PIP joint. Low cost and low morbidity and as the procedure was done under local ring anesthesia makes this modality of treatment is a good alternative to the conventional technique used to treat such cases.

REFERENCES

- 1- Donelan M.B.: Reconstruction of the burned hand and upper extremity. In: McCarthy J.G., May J.W. and Littler J.W. (eds). Plastic Surgery. Philadelphia, Sydney, Tokyo. W.B. Saunders Company, Vol. 8: 2, Ch. 132, P. 545, 1990.
- 2- Upton J.: Congenital anomalies of the hand and forearm. In: McCarthy J.G., May J.W. and Littler J.W. (eds). Plastic Surgery. Philadelphia, Sydney, Tokyo W.B. Saunders Company, Vol. 8: 2, Ch. 132, P. 545, 1990.
- 3- Codivilla A.: On the means of lengthening, in the lower limb, the muscles and tissues which are shortened through deformity, *Am. J. Orthop. Surg.*, 2: 353, 1905.
- 4- Ilizarov G.A.: The tension-stress effect on the genesis and growth of tissues: Part 1. The influence of stability of fixation and soft tissue preservation. *Clin. Orthop.*, 238-249, 1989.
- 5- Calhoun J.H., Evans E.B. and Herndon D.N.: Technique for management of burn contractures with the ilizarov fixator. *Clin. Orthop.*, 280: 177, 1992.
- 6- Seitz W.H.: Distraction lengthening in the hand and upper extremity, In : Green D.P., Hotchkis R.N. and Pederson W.C. (eds.) *Greens operative hand surgery*. New York, Edinburgh, London and Philadelphia. Churchill Livingstone, Vol. 5, Ch. 54, 1913, 2005.
- 7- El-Deeb F.: Electron microscopic study of contracted scarred skin under distraction produced by ilizarov external fixator Egypt. *J. Plast. Reconst. Surg.*, Vol. 28 (1): 29, 2004.
- 8- Prokopovich V.S.: Aligning of length of the forearm bones in the congenital club-hand in children. *Orthop. Traumatol.*, 1: 51, 1980.
- 9- Smith R.J. and Kaplan E.B.: Camptodacty and similar atraumatic flexion deformities of the proximal interphalangeal joints of the fingers. *J. Bone Joint Surg.*, 50A: 1187, 1968.
- 10- Natividade P.D.S, Barbosa R., Ferreira P., Ferreira A., Reis J. and Ammarante J.: Correction of long term joint contractures of the hand by distraction. A case report. *Br. J. Plast. and Reconst. Surg.*, Vol. 58, P. 1148-1151, 2005.
- 11- Sherine M., Aboul Fotoh, Mohamed F. Mahmoud and Abd al-Aziz A. Ahmed: Distraction histogenesis for correction of long standing flexion deformities of the proximal interphalangeal (PIP) joint of the hand, Egypt. *J. Plast. and Reconst. Surg.*, Vol. 31 (1): P. 1-5, 2007.
- 12- Ghidella S.D., Segalman K.A. and Murphy M.S.: Long term results of surgical management of proximal interphalangeal joint contracture. *J. Hand Surg. (Am.)*, Vol. 27 (5): P. 799-805, 2002.
- 13- Kolonati I. and Kiloslavskii F.A.: Distraction tenoplasty in injuries of the flexor tendons of the fingers at the level of the osteofibrous synovial canal. *Ortop. Traumatol. Protez.*, Vol. 48, P. 1-3, 1987.