

Lateral Supramalleolar Flap for Reconstruction of the Distal Leg and Foot, Clinical Experience with 25 Cases

EHAB FOUAD ZAYED, M.D.

The Department of Plastic and Reconstructive Surgery, Faculty of Medicine, Tanta University, Egypt

ABSTRACT

The aim of this work is to present our experience with, and to evaluate the reliability of the lateral supramalleolar flap that was used in 25 patients for reconstruction of the distal leg and foot. There were 22 males and 3 females and age ranged from 7 to 74 years. The cause of the skin defects was trauma. Sites of defects were the lower fourth leg and ankle region (14 cases), the Achilles tendon (4 cases) and the dorsal and lateral aspect of the foot (7 cases). Twenty flaps survived completely and provided satisfactory coverage of the defect. Five flaps showed partial necrosis, two cases managed conservatively, two cases required revision with excision of the distal 1-2cm and direct suturing and the fifth case required flap coverage with distally based medial head hemisoleus muscle flap. The lateral supramalleolar flap has a large skin paddle and a wide rotation arc that reaches the distal areas of the foot. It is a rapid and reliable procedure and provides an excellent alternative to reconstruct soft tissue defects of the lower extremity.

INTRODUCTION

Many procedures have been described to resurface foot and ankle defects. The most commonly used procedures include skin graft, local pedicled flaps [1,2], distally and proximally based island flaps [3-6], cross leg flaps [7-9] and free skin and muscle flaps [10,11]. Although procedures have disadvantages, the lateral supramalleolar flap has been recently introduced as a new skin flap to make up for the disadvantages of the other operative methods [12-17].

The lateral supramalleolar flap is supplied by a cutaneous branch from the perforating branch of the peroneal artery [18-21]. It can be used as a rotation flap, a reversed pedicle flap, or as a free flap. When used as a rotation flap, it is based on a cutaneous branch of the perforating branch of the peroneal artery and when used as a reversed pedicle flap, it is based on a deep descending branch which anastomoses with a terminal branch of the anterior tibial artery.

The lateral supramalleolar flap is very useful for the treatment of various defects of the foot and the ankle joint areas. This flap has the following advantages than other procedures: It can be elevated as a large flap (20x8 cm), the vascular pedicle is large enough and easy to dissect, the pivot point of the flap is distal (sinus tarsi) and allow versatile rotation and it does not sacrifice any of the main arteries of the leg [12-17].

Compared with other flaps, it is believed that the lateral supramalleolar flap is versatile, effective and is a good addition to the available techniques used by reconstructive surgeons for coverage of the distal one fourth of the leg and the dorsum of the foot and ankle.

Anatomy:

The vascular supply is provided by the anastomotic arcade of the ankle. The key anatomic vascular structure is the perforating branch of the peroneal artery [18-21], which pierces the interosseous membrane at the tibiofibular ligament. It anastomoses at a variable level with the anterior lateral malleolar artery arising from the anterior tibial artery, courses on the anterior tibiofibular ligament, and then descends to the level of the sinus tarsi, where it anastomoses with the lateral tarsal artery and small branches issuing from the lateral planter artery. Between its emergence from the interosseous membrane and the tibiofibular ligament, the perforating artery gives off one or two ascending branches to the skin of the distal half of the lateral aspect of the leg, which constitute the territory of the flap.

The cutaneous branches issuing from the perforating branch run anterior to the fibula and anastomose with the vascular network that accompanies the superficial peroneal nerve. This enters the subcutaneous tissue at the junction of the middle

and distal third of the leg, and divides into medial and lateral branches at the level of the ankle joint [19].

These constant anatomic considerations allow clarification of the different varieties of the lateral supramalleolar flap, the territory of all varieties remains the same. The rotation flap maintains continuity of the perforating branch, and no vascular dissection is required. The pivot point of the flap is the emergence of the branch through the interosseous membrane. The rotation flap may be a peninsular flap with a distal skin hinge, or an island flap with a very short pedicle that need not be dissected. In both cases the rotation can't exceed 90°.

A distally-based island pedicled flap is based on the perforating branch, which is ligated and divide just proximal to the cutaneous branch and released as far as the sinus tarsi that constitutes the pivot point of the pedicle. The length of the pedicle is approximately 8cm; the venae committantes are sufficient to ensure venous return. When the perforating branch is interrupted in its course distal to the cutaneous branch to the flap, the skin paddle is designed proximally on the lower half of the leg, and the flap is supplied by a cutaneous fascial pedicle. In this case the pivot point is the emergence of the perforating branch. It is also possible to combine a subcutaneous fascial pedicle in continuity with the vascular axis of the perforating branch, until it reaches the sinus tarsi. The flap is designed at the middle of the leg, and the pedicle is approximately 15cm in length. This procedure is valuable for small and distal defects of the extremity [20].

Flap design and dimensions:

The boundaries of the largest flap are proximally, the middle of the leg, anteriorly, the crest of the tibia, posteriorly, the fibula and distally the emergence of the perforating branch. This later point is identified on the skin by the depression on the lower part of the tibiofibular space which can be palpated with the finger. Whatever the dimension, the design of the flap should include this landmark as the outline of the flap is traced 2 to 3cm distal to the landmark. Flap dimensions vary according to the proximal limit, the largest flap is about 20 x 8cm.

Operative technique:

The patient is supine and a tourniquet is applied. The design of the flap, as described above, should

include the landmark of emergence of the perforating artery distally. A line of incision is drawn anterior to the lateral malleolus and reaches the depression of the sinus tarsi on the lateral aspect of the hind foot. The skin, including the fascia, is incised in continuity along the anterior margin of the flap, and anterior to the lateral malleolus. A posterior skin hinge is maintained. The pedicle is first exposed, lying deep to the extensor retinaculum which is incised. The muscles of the extensor compartment are gently retracted exposing the lower part of the tibiofibular space in order to identify the vascular structures chiefly the cutaneous branch of the flap. If the flap has been used as a retrograde vascular flow, the perforating branch is ligated and severed just proximal to the cutaneous branch. It is sometimes necessary to incise the interosseous membrane in order to free the perforating branch. The anastomoses with the anterior lateral malleolar artery are ligated and divided. Then the posterior margin of the flap is incised including the fascia. If there is limitation of the arc of rotation of the flap, the superficial peroneal nerve is severed proximally, and its proximal end is buried in the muscles and the fascial septum which attaches the flap to the fibula is released from proximal to distal. At the level of the course of the cutaneous branch to the flap, the septum is sub-periosteally released to protect the supplying branches. The pedicle is isolated with its surrounding loose areolar tissue, until it reaches the sinus tarsi. The posterior edge of the fascia of the extensor digitorum brevis muscle should be divided in order to avoid compression of the pedicle when it is turned. Closure of the donor site is performed by approximating the peroneal and the extensor muscles together. A split thickness skin graft is applied immediately or a few days later. A distally based island flap with subcutaneous fascial pedicle is useful when the perforating artery is visible at its emergence, but is interrupted distally. In this case the pivot point of the pedicle is related to the emergence of the perforating branch. The subcutaneous fascial pedicle is subdermally dissected to 2cm in width. If the perforating artery is visible until the sinus tarsi, it can be dissected in continuity with the subcutaneous fascial pedicle; the total pedicle length is about 15cm when a small flap is raised at the middle of the leg. When used as an adipofascial flap, dissection starts in the subdermal plane and extends to the required width-to-length, and then the flap is either rotated or turned over to cover the defect. A skin graft can be applied immediately or later on.

PATIENTS AND METHODS

Twenty five patients with soft tissue defects over lower one fourth leg and dorsum of the foot underwent reconstruction using lateral supramalleolar flap. There were 22 males and 3 females. Patient ages ranged from 7 to 74 years. In all patients the soft tissue defects were caused by trauma, twenty one patients sustained acute traumatic soft tissue defect and 4 patients with chronic soft tissue defect. The size of the flap ranged from 4x8 to 8x20cm. Lateral supramalleolar flap was used as antegrade blood supply, pedicled fasciocutaneous flap in 18 patients and as a retrograde, island flap in 7 cases, three of which was adipofascial and 4 cases fasciocutaneous flap. The flaps were used for reconstruction of soft tissue loss over the lower one fourth leg and ankle region in 14 patients, tendo-Achillis in 4 patients and 7 cases with soft tissue defects over the dorsum and lateral surface of the foot.

Case presentation:

Case I:

A 48 year old male patient involved in road traffic accident that resulted in compound fracture of both bones right leg with soft tissue defect of the anteromedial aspect of the lower one fourth right leg, with exposed bone, fracture was stabilized using an external fixator (Fig. 1A). Design and elevation of pedicled lateral supramalleolar flap (Fig. 1B). Insetting of the flap and post operative view (Fig. 1C,D).

Case II:

A 14 year old male patient involved in road traffic accident that resulted in fracture right tibia, the bone got exposed after two and half months, (Fig. 2A). The soft tissue defect was reconstructed using pedicled lateral supramalleolar flap (Fig. 2B,C).

Case III:

A 12 year old male patient with post traumatic skin loss and exposed ankle and dorsum of right foot (Fig. 3A). Island lateral supramalleolar flap was used for covering the defect (Fig. 3B,C).

Case IV:

A 42 year old male patient with post traumatic chronic skin loss over Achilles region with past history of skin grafting twice (Fig. 4A). Design and elevation of the flap with preservation of sural

nerve and superficial peroneal nerve (Fig. 4B). Post operative view (Fig. 4C,D).

Case V:

A 74 year old male patient involved in road traffic accident that resulted in compound fracture of both bones right leg. The patient was referred to us 3 weeks after trauma with exposed plate and screws of the right leg, (Fig. 5A). The upper part of the defect was covered by extensor digitorum longus muscle flap and skin graft while the lower part was covered by lateral supramalleolar fasciocutaneous flap (Fig. 5B).

Case VI:

A 7 year old boy sustained road traffic accident resulted in skin loss over the ankle and dorsum of the right foot (Fig. 6A). Adipofascial lateral supramalleolar flap used to cover the exposed ankle and tendons over the dorsum of the foot (Fig. 6B,C,D) and skin graft applied immediately over the adipofascial flap, (Fig. 6E). Post operative result (Fig. 6F).

Case VII:

A 39 year old male heavy smoker patient, involved in road traffic accident that resulted in a compound fracture dislocation of right ankle. The fractures and dislocations were stabilized using plates and screws. The patient was referred to us 2 weeks after the accident, and after debridement twice by orthopedic team there was skin loss and exposed bone, screw and tendon over the medial malleolar area (Fig. 7A). Reconstruction of soft tissue defect with lateral supramalleolar flap (Fig. 7B,C). There was partial loss of the flap with exposed screw (Fig. 7D). Distally based medial head hemisoleus muscle flap with immediate skin grafting was used to cover the defect and to overcome the partial loss of the lateral supramalleolar flap. The muscle flap survived completely with good skin graft take (Fig. 7E,F).

RESULTS

All flaps had survived completely except five flaps showed venous congestion. Two of which were managed conservatively, two cases required revision of the flap with resection of the distal 1-2cm and direct suturing. One flap (Case VII), developed partial loss which necessitated reconstruction with distally based medial head hemisoleus muscle flap and skin graft.

CASE I

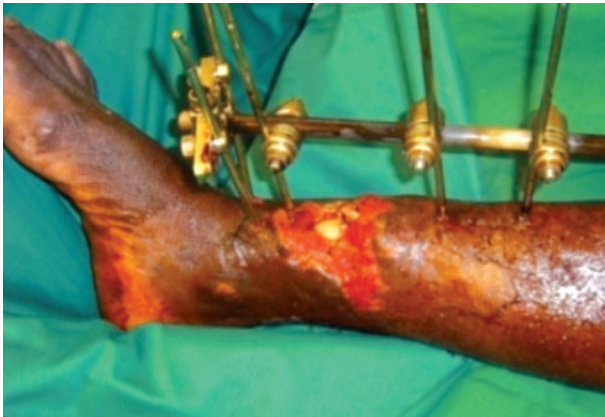

Fig. (1A): Soft tissue defect over the anteromedial lower one third right leg with exposed bone.

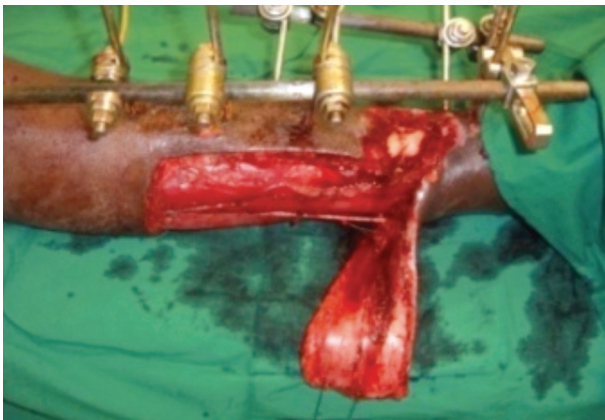


Fig. (1B): Elevation of the flap.



Fig. (1C): Post operative view (medial aspect).

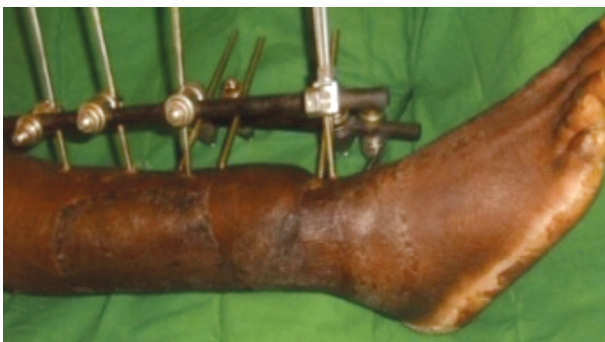

Fig. (1D): Post operative view (lateral aspect).

CASE II

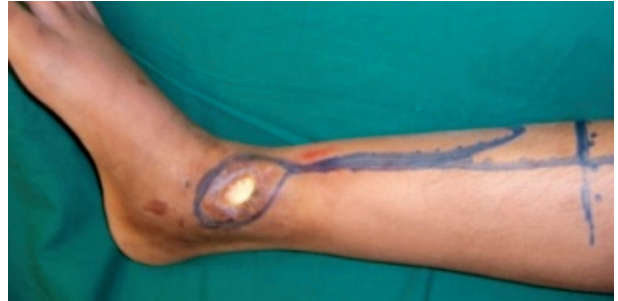

Fig. (2A): Post traumatic soft tissue defect right leg with exposed bone.

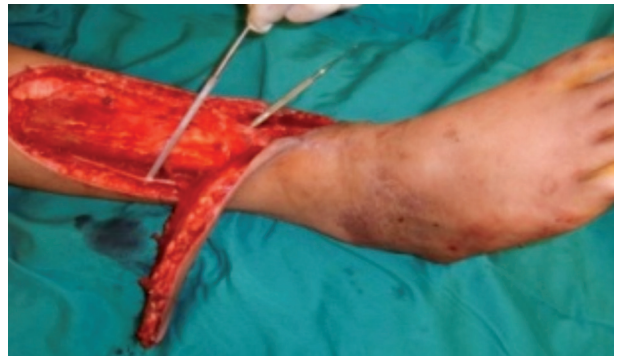

Fig. (2B): Elevation of the flap.

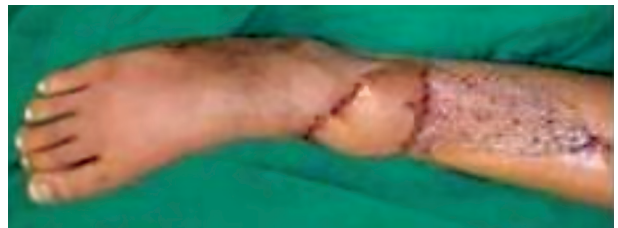

Fig. (2C): Post operative view.

CASE III

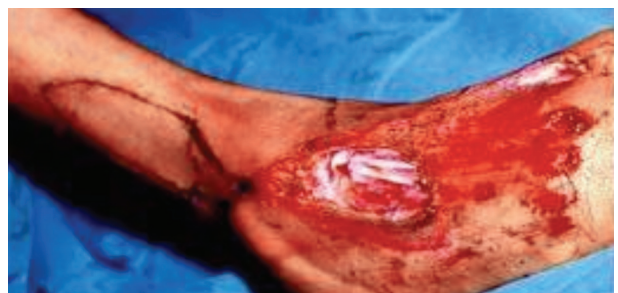

Fig. (3A): Post traumatic skin loss with exposed ankle and dorsum of the foot.

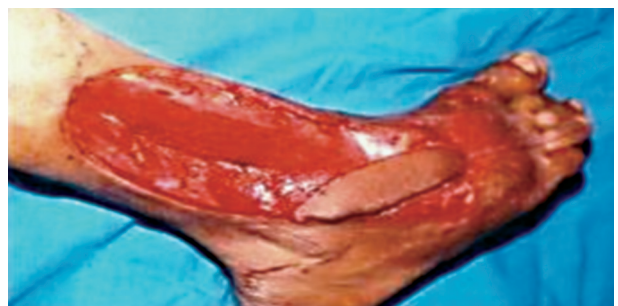


Fig. (3B): Insetting of the flap.

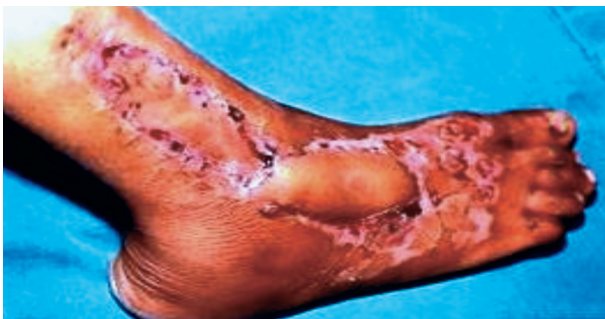


Fig. (3C): Post operative view.

CASE IV

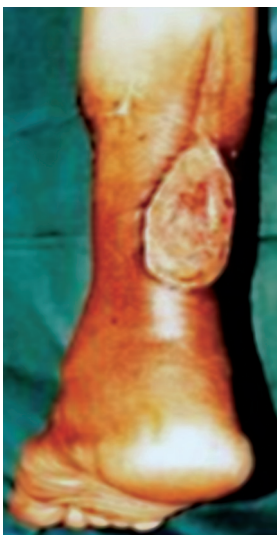

Fig. (4A): Post traumatic chronic skin loss over Achilles tendon.

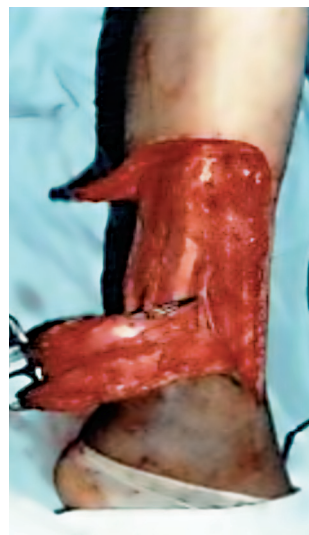

Fig. (4B): Elevation of the flap with preservation of sural and superficial peroneal nerves.

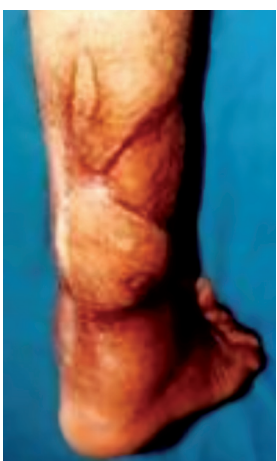

Fig. (4C): Post operative result, posterior view.

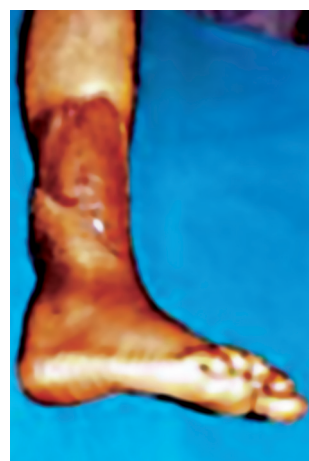

Fig. (4D): Post operative result lateral view.

CASE V

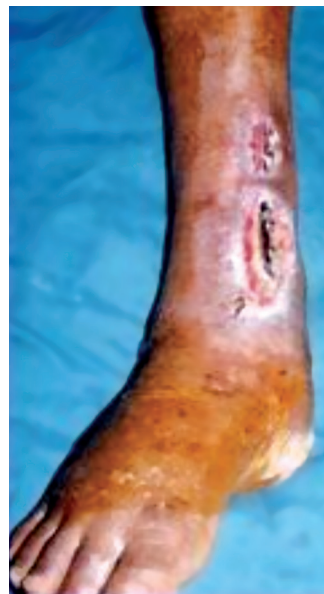

Fig. (5A): Post traumatic skin loss over medial malleolus right leg. The upper part of the defect was covered by ext. digit. longus muscle flap and skin graft, while the lower part was covered by lateral supramalleolar flap.

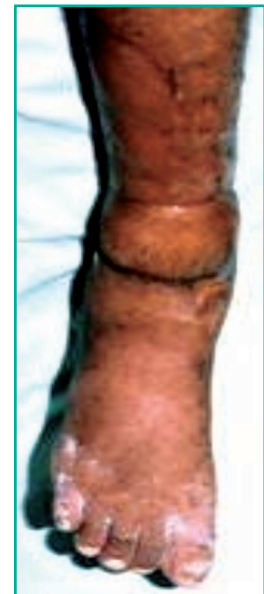

Fig. (5B): Post operative view.

CASE VI

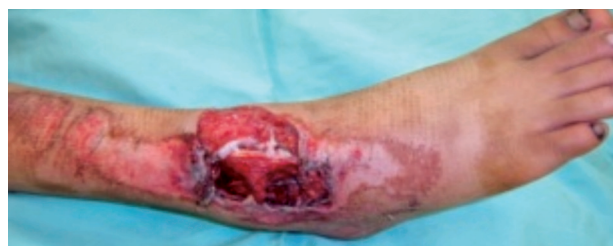

Fig. (6A): Skin loss over the right ankle.

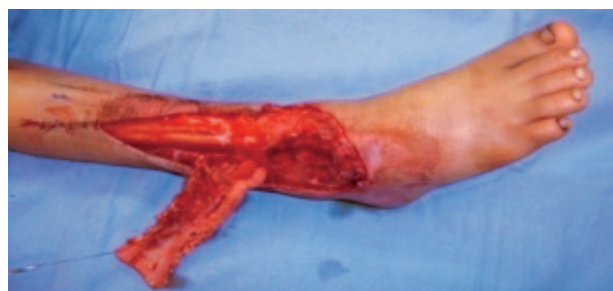

Fig. (6B): Elevation of the flap.

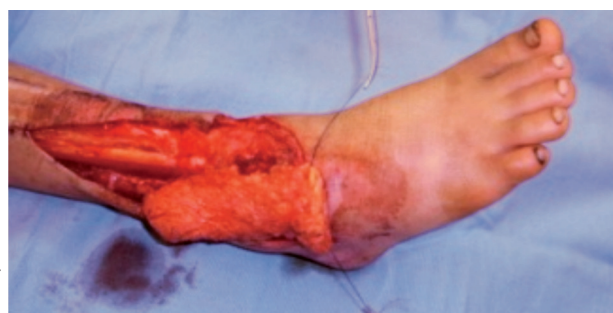

Fig. (6C): Insetting of the flap.

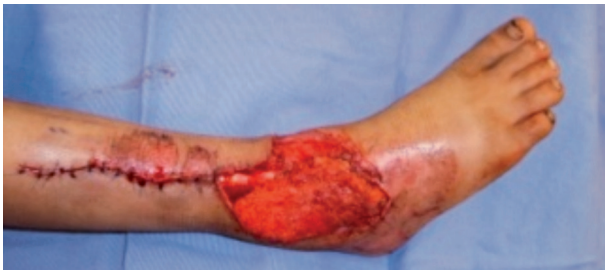

Fig. (6D): Donor site closed primarily.

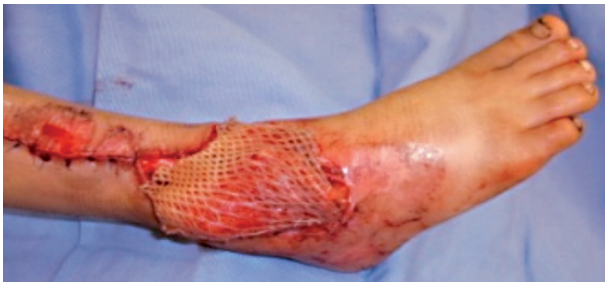

Fig. (6E): Immediate skin graft cover of the flap.

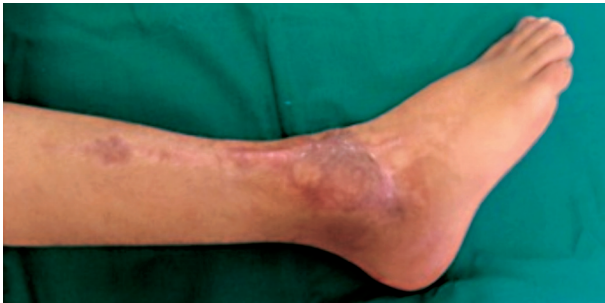

Fig. (6F): Post operative view.

CASE VII

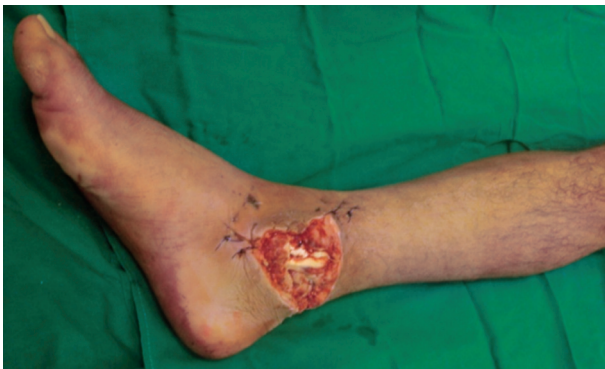

Fig. (7A): Open fracture of the right ankle.

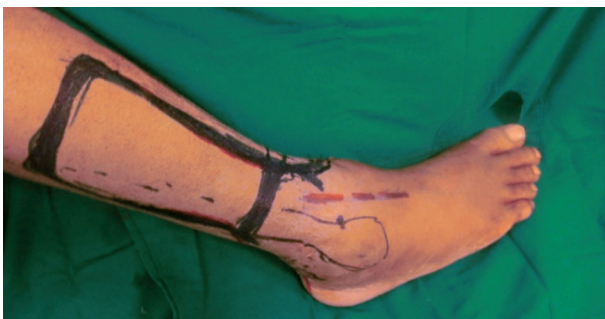

Fig. (7B): Design of the flap.

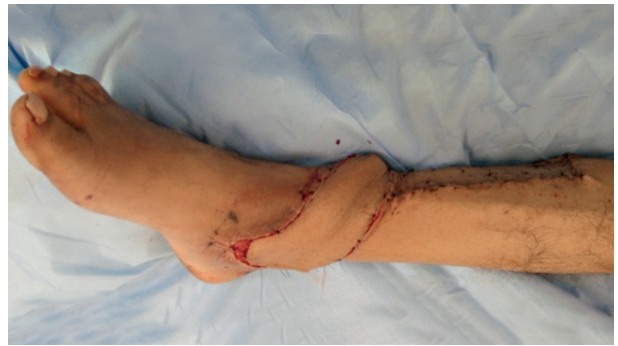

Fig. (7C): Insetting of the flap.

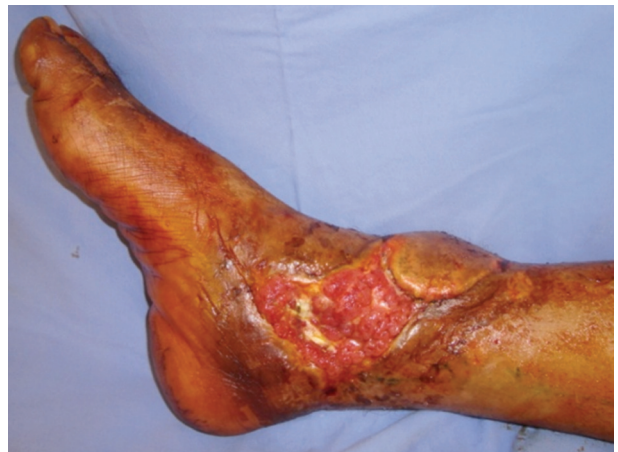

Fig. (7D): Partial flap necrosis.

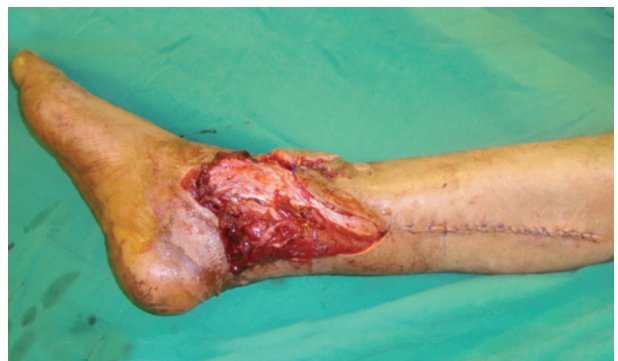

Fig. (7E): Distally based hemi soleus muscle flap.

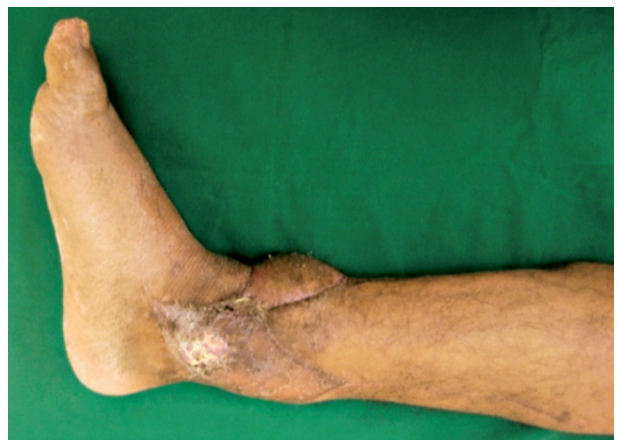

Fig. (7F): Post operative view.

DISCUSSION

Defects over the lower one fourth of the leg, ankle and over the dorsum of the foot have always been difficult to cover. Several local and loco-regional flaps have been described during the past two decades; however, some are too small to cover defects over the leg (e.g., muscle flaps from the flexors or the extensors of the toes), [20,21] or the defect is too distal to be reached. A distally based soleus or hemi-soleus flap [22,23] can be used only after confirming the size of the distal vessels at the time of surgery. As for the other options, the postoperative course can be demanding and poorly tolerated (cross-leg flap) [7-9] especially in elderly patients. Random-pattern flaps can be raised, but they have a high incidence of failure. The medial plantar island flap is the flap of choice for heel defects because it involves the transfer of skin that can tolerate considerable local pressure (i.e., is adaptable to weight-bearing and sensate). Free flaps, requiring teams of highly experienced surgeons and paramedical personnel and proper equipments hold a prominent place in the treatment of these defects, especially when they are extensive (large skin defects, extensive chronic ulcers).

The advantages of the lateral supramalleolar flap [12-17] are the rapid and reliable procedure provides an excellent alternative to a free flap in many instances. The principle disadvantages are the division of the superficial peroneal nerve and the scar resulting from skin grafting on the lateral aspect of the leg. Usually, the donor site is quite acceptable, but may be problem in young women.

Conclusion:

The lateral supramalleolar flap is reliable and versatile for the following reasons: (1) It does not require the sacrifice of the main artery to the leg or foot; (2) It is a relatively thin flap, with minimal morbidity of the donor site; (3) The pivot point of the flap allows a versatile rotation; (4) Can be elevated as a large flap (8x20cm) and (5) The technique for dissecting the flap is easy.

REFERENCES

- Hasegawa M., Torii S., Katoh H., et al.: The distally based superficial sural artery flap. *Plast. Reconstr. Surg.*, 93: 1012, 1994.
- Fix R.J. and Vasconez L.O.: Fasciocutaneous flaps in reconstruction of the lower extremity. *Clin. Plast. Surg.*, 18: 571, 1991.
- Landi A., Soragni O. and Monteleone M.: The extensor digitorum brevis muscle island flap for soft tissue loss around the ankle. *Plast. Reconstr. Surg.*, 75: 892, 1985.
- Giordano P.A., Argenson C. and Pequignot J.P.: Extensor digitorum brevis as an island flap in the reconstruction of soft tissue defects in lower limb. *Plast. Reconstr. Surg.*, 83: 100, 1989.
- Masquelet A.C., Romana M.C. and Wolf G.: Skin island flaps supplied by the vascular axis of the sensitive superficial nerves: Anatomic study and clinical experience in the leg. *Plast. Reconstr. Surg.*, 89: 1115, 1992.
- Harrison D.H. and Morgan B.D.: The instep island flap to resurface plantar defects. *Br. J. Plast. Surg.*, 34: 315, 1981.
- Morris A.M. and Buchan A.C.: The place of the cross-leg flap in reconstructive surgery of the lower leg and foot: A review of 165 cases. *Br. J. Plast. Surg.*, 31: 138, 1978.
- Ambroggio G., Oberto E. and Teich-Alasia S.: Twenty years' experience using the cross-leg flaps technique. *Ann. Plast. Surg.*, 9: 152, 1982.
- Barclay T.L., Sharpe D.T. and Chisholm E.M.: Cross-leg fasciocutaneous flaps. *Plast. Reconstr. Surg.*, 72: 843, 1983.
- Serafin D., Georgiade N.G. and Smith D.H.: Comparison of free flaps with pedicled flaps for coverage of defects of the leg and foot. *Plast. Reconstr. Surg.*, 52: 492, 1977.
- Khouri R.K. and Shaw W.W.: Reconstruction of the lower extremity with microvascular free flaps: A 10 years experience with 304 consecutive cases. *J. Trauma*, 29: 1086, 1989.
- Masquelet A.C., Beveridge J., Romana M.C. and Gerber C.: The lateral supramalleolar flap. *Plast. Reconstr. Surg.*, 81: 74, 1988.
- Lee Y.H., Rah S.K., Choi S.J., et al.: Distally based lateral supramalleolar adipofascial flap for reconstruction of the dorsum of the foot and ankle. *Plast. Reconstr. Surg.*, 114: 1478, 2004.
- Valenti P., Masquelet A.C., Romana C., et al.: Technical refinement of the lateral supramalleolar flap. *Br. J. Plast. Surg.*, 44 (6): 459-62, 1991.
- Yercan H.S., Ozalp T. and Okcu G.: Reconstruction of diabetic foot ulcers by lateral supramalleolar flap. *Saudi Med. J.*, 28 (6): 872-6, 2007.
- Philippe V., Michel M. and Jean-David S.: The lateral supramalleolar flap: Experience with 41 cases. *Ann. Plast. Surg.*, Vol., 54/1/pp 49-54, 2005.
- Demin E., Foroglou P., Dionyssiou D., et al.: Our experience with the lateral supramalleolar island flap for reconstruction of the distal leg and foot: A review of 20 cases. *J. of Plast. & Hand Surg.*, 40 (2): 106-110, 2006.
- Beveridge J., Masquelet A.C., Romana M.C., et al.: Anatomic basis of a fasciocutaneous flap supplied by the perforating branch of the peroneal artery. *Surg. Radiol. Anat.*, 10 (3): 195-9, 1988.
- Saitoh S., Hata Y., Murakami N., et al.: The 'superficial'

- peroneal artery: A variation in cutaneous branching from the peroneal artery, nourishing the distal third of the leg. *Br. J. Plast. Surg.*, 54 (5): 428-33, 2001.
- 20- Arnold P.G. and Hodgkinson D.J.: Extensor digitorum turn-down muscle flap. *Plast. Reconstr. Surg.*, 66: 599, 1980.
- 21- Leitner D.W., Gordon L. and Buncke H.J.: The extensor digitorum brevis as a muscle island flap. *Plast. Reconstr. Surg.*, 76: 777, 1985.
- 22- Townsend P.L.: An inferiorly based soleus muscle flap. *Br. J. Plast. Surg.*, 31: 210, 1978.
- 23- Wright J.K. and Watkins R.P.: Use of the soleus muscle flap to cover part of the distal tibia. *Plast. Reconstr. Surg.*, 68: 957, 1981.