

Repair of Wide Nerve Gaps Using Nerve Auto-Grafts and Vein Conduits: Evaluation of a New Technique

AHMED M. ALY, M.D. and AHMED A. AZAB, M.D.

The Department of General Surgery, Plastic Surgery Unit., Faculty of Medicine, Zagazig University, Egypt.

ABSTRACT

Purpose: Of this study was to assess the effectiveness of using nerve auto-graft and vein conduit as a new method of reconstruction of wide nerve defects to obtain the benefits of both techniques.

Patients and Methods: Eighteen patients with lacerated nerve injuries were included in this study. There were fourteen cases with fresh nerve injury were managed in the casualty unit and four cases were old nerve injuries. All were managed with the same idea and follow-up period was extended up to 24 months for both sensory and motor recovery.

Results: Good results were obtained in 39.1% of cases as regards both sensory and motor recovery of the repaired nerves.

Conclusion: This technique for nerve reconstruction yields a comparable result with other methods of nerve repair.

INTRODUCTION

Reconstruction of long distance nerve injuries represents a great challenge in nerve surgery. Primary repair, although it appears simple, but repair under tension impairs the blood supply to the nerve stump [1-4]. This results in an increased scar formation and impairment of axonal regeneration. So the best recovery following nerve damage is obtained by tension-free microsurgical repair of the cut ends with proper fascicular alignment [5-8].

For large nerve defects, cable grafting is widely accepted as the "golden" standard method for nerve reconstruction [9-16]. Many types of conduits have been used to reconstruct nerve defects and the use of vein graft represents one of them [17]. The use of auto-venous vein conduit provides mechanical and chemical support and prevents the sprouting of excessive nerve buds out from the repair zone, thus, aiding nerve regeneration [18-20].

Using vein graft in nerve reconstruction can accelerate the rate of healing of facial nerve and the result is superior when the graft is treated with

Agmatine [21]. This is explained by the elaboration of trophic factors from the endothelial and smooth muscle cells of the vein graft with very high collagen content that allows a suitable environment for axon regeneration [22,23]. Moreover the conduit allows the nerve to regenerate under the guidance of neurotrophism [24]. At histological level, using vein graft leads to thinner epineurium, more regenerated axons and fewer inflammatory cells [25-27].

In this study, a new technique is described using both cable nerve auto-graft and auto-genous vein conduit to reconstruct wide nerve gaps to get the advantages of both methods.

PATIENTS AND METHODS

This study was carried out in Zagazig University Hospitals, Plastic Surgery Unit, General Surgery Department, Zagazig University, from July 2007 through July 2010. Eighteen patients with lacerated nerves injuries were included in this study. Age, sex, mechanism of injury and the injured nerve are presented in Table (1). Totally we had operated 23 nerves. Those with sharp injury (5 cases), four of them were old cases and only one was recent injury with serrated blade. Most of our cases were males within the age of physical activity (17-40 years) while female patients were injured in home accidents.

There were four cases with old nerve injury: One case since one month, two cases for two months and one case for four months. All patients were operated upon under general anesthesia, given antibiotic chemoprophylaxis (all patients were given 1gm amoxacillin + 1gm cefotaxime) and then pneumatic tourniquet was applied above the elbow joint. Wound exploration was done under magnification using 4x Magnifying Loup in the standard way. Associated vascular and tendon injuries were managed in the usual ways.

Table (1): Age, sex, mechanism of injury and the injured nerve.

	Age			Sex		MI		IN		
	<17 Y	17-40 Y	>40 Y	♂	♀	S	CL	M	U	B
No	3	13	2	14	4	5	13	8	5	5
%	16.6	72.2	11.2	77.7	22.3	27.8	72.2	44.4	27.8	27.8
Total	100 (18/18)			100 (18/18)		100 (18/18)		100 (18/18)		

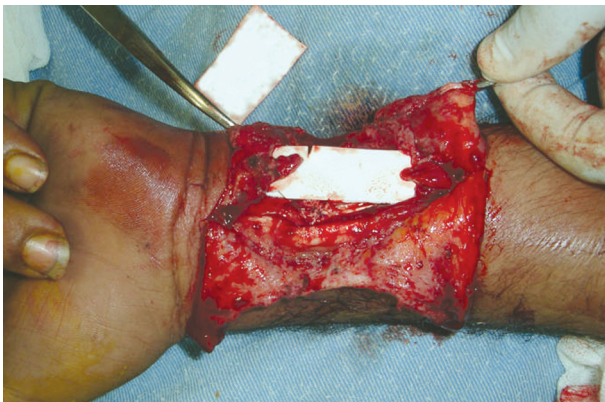
MI = Mechanism of Injury.
 S = Sharp.
 CL = Crushed Lacerated.
 IN = Injured Nerve.
 M = Median.
 U = Ulnar.
 B = Both.

After careful anatomical orientation in those with old injury, the length of defect was measured after complete resection of the neuroma reaching to healthy fascicles. While for the most recent injuries, the defect was measured after trimming of the lacerated ends, as conservatively as possible, till reaching a freely bleeding nerve stump, also the distance from the proximal end of defect to the tip of middle finger is measured (Table 2), (Fig. 1).

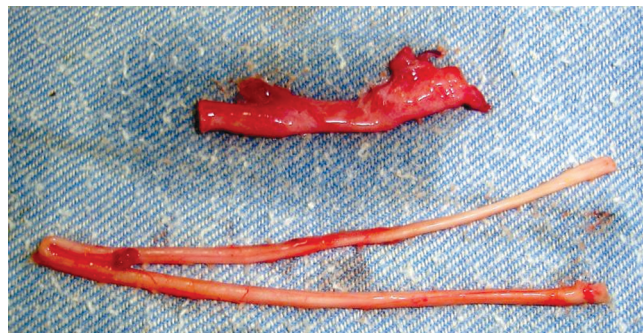
Table (2): Length of nerve gap and distal distance length.

Item	Length of gap				Distal distance		
	2cm	3cm	4cm	5cm	12-16cm	17-20cm	>20cm
No	5	7	6	5	8	12	3
%	21.75	30.4	26.1	21.75	34.8	52.2	13.0

Distal Distance = Distance from injury site to tip of middle finger.



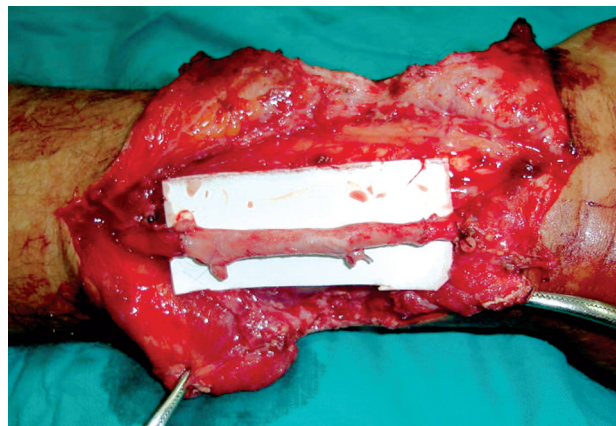
(A)



(B)



(C)



(D)

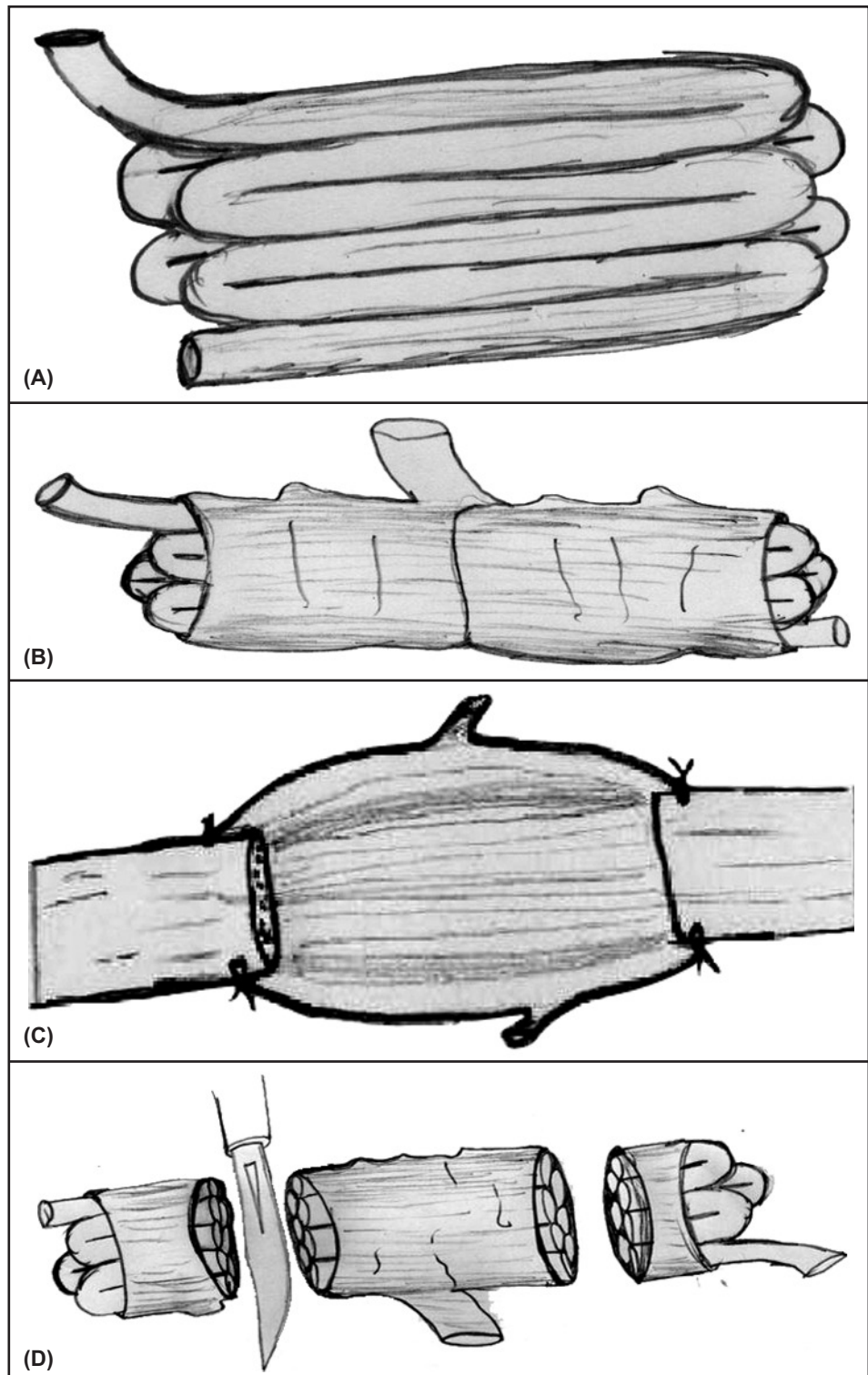
Fig. (1): Operative photos for the technique; (A) Left median nerve gap of 3.5cm, (B) Both; great saphenous vein (Up) and sural nerve (down) after harvesting, (C) Nerve packed inside the vein, (D) Graft put in place.

Donor nerve grafts were obtained from the sural nerve. Bilateral sural nerves were needed in five cases. The sural nerve is turned on itself several times (from five to seven) until it forms a cord whose diameter matches the injured nerve and with a length of about one centimeter longer than the nerve defect. A segment of the great saphenous vein, from its proximal part, was obtained and

dilated by hydrostatic pressure through injection of saline to one end while closing the other end.

The nerve cord is grasped by jeweler forceps from one end and passed through the vein graft. By a sharp knife, both ends of the vein that is packed with nerve cord are cut, to make a fresh cut section of both the vein and nerve inside it (Fig. 2).

Fig. (2): Diagramatic illustration for the technique; (A) The nerve cable turned on itself, (B) Nerve packed inside the vein, (C) Cutting of the turning ends of the nerve within the conduit, (D) Insetting of the graft with micro-suture fixation of the conduit.



Now the conduit is placed between the two ends of the injured nerve and by 8/0 ethilon threads the epineurium is sutured to venous wall under magnification. After skin closure, patients were put in static splint for three weeks and in dynamic splint for another three weeks.

Follow-up: Was done for all patients at regular intervals every 2 months in the first two years, then every six months thereafter. Evaluation of nerve recovery was done by detecting the degree of motor and sensory recovery. Different components of sensibility were tested by Semmes-Weinstein monofilament for light touch (1-normal sensation = 2.83; 2-diminished = 3.61; 3-diminished protective = 4.31 and 4-loss of protective = 4.56) [28], Disk-Criminator for two point's discrimination (2PD) (<5mm = Normal; 6-10 = Fair; 11-15 = Poor; one point = Protective sensation; no point = Anesthetic) [29] and using the advancing Tinel's sign was our crude guide for sensory recovery. We recorded the final results at the palmer side of the thumb as an indicator for median nerve and palmer surface of little finger as an indicator for ulnar nerve.

Testing the recovery of motor function of repaired nerve was done by evaluation of both muscle strength and size of first dorsal interosseous muscle (index abduction) as an indicator for ulnar nerve, and flexor pollicis brives (palmer abduction) as an indicator for median nerve. In strength evaluation we used the Medical Research Council (MRC) scale and we used a scale from 0 to 3 (no=0; mild=1; moderate=2; sever=3) to describe the degree of atrophy of the previous two muscles [30].

Formal consent was obtained from all cases after discussing full details of surgery with them. They were informed about the nature of the procedure, the need for opening the legs to obtain nerve grafts and the importance of strict follow-up and sticking to physiotherapy program postoperatively.

RESULTS

All of our patients passed the postoperative period well. There was no mortality at all and morbidity was nil. Complications of both donor wounds in the legs and wounds of hand and forearm are presented in Table (3).

Sensory recovery reached to the palm of the hand by the end of the 6th postoperative month and was established in the digits by the end of the 1st postoperative year. Final result of sensory

recovery was evaluated till 18 months postoperatively when it is recorded to be stable by this time (Table 4).

At the end of the follow-up period, most of our cases resumed adequate and useful 2-PD (60% with 2-PD <10mm) and over 82% resumed light touch with variable degrees.

When we looked to the motor power (Table 5), we found satisfactory recovery of the main hand functions. Good motor recovery was obtained in almost 56.2% of cases (MRC ≥ 3) with good muscle bulk and shape in 39% and acceptable muscle bulk in 34.7% of cases (collectively, 73.8%).

Table (3): Postoperative mortality and morbidity.

Item	Morbidity					
	Donor			Recipient		
	Mortality	S/H	WI	WD	WI	WD
No	0	2	1	1	2	1
%	0	11.1	5.5	5.5	11.1	5.5
Total	0 (0/18)		22.2 (4/18)		16.6 (3/18)	

S/H = Seroma / Hematoma.

WI = Wound Infection.

WD = Wound Dehiscence.

Table (4): Final sensory result 18 months postoperatively.

Item	2-PD			SW			
	7-10	11-15	>15m	1	2	3	4
No	14	7	2	8	1	10	4
%	60.8	30.4	8.6	34.8	4.3	43.5	17.4
Total	100 (23/23)			100 (23/23)			

Table (5): Final motor recovery 2-years postoperatively.

	Muscle power		Muscle bulk		
	<3	≥ 3	Good	Mild atrophy	Marked atrophy
No	10	13	9	8	6
%	44.4	56.2	39.1	34.7	26.1
Total	100 (23/23)		100 (23/23)		

DISCUSSION

Wide nerve defects create a dilemma facing the nerve surgeon. Vein graft represents famous option to bridge gaps less than 3cm [31-33], whereas for the larger gaps the ideal solution is reconstruction of it with cable grafts [9-16]. Although fashioning of a nerve graft by fibrin glue is simple,

rapid, effective and does not lead to suture granuloma, it carries the risk of transmitted serological disease from pooled and single-donor blood donors [34-37].

Functional results after nerve repair shows marked difference in clinical series. In this study, we achieved fair to good sensory recovery with good 2-PD in 60.8% and good to normal light touch in 39.1%. This result is a little superior to that mentioned by Wong et al., [38]. They reported a normal 2-PD in 10.7% and fair in 25%. This was not recorded in our series as we didn't obtain this normal 2-PD. However, we believed that 2-PD testing alone is not quite enough for sensory assessment following nerve surgery. This was mentioned also by Rosen, [39] who concluded that 2-PD should not be relied upon as a single tool for testing sensory recovery, because only four out of thirteen of his patients showed 2-PD less than 16mm while most of them obtained higher scores in shape and object recognition tests. Jerosch-Herold, [40] mentioned the same concept in her work and she told that a poor 2-PD doesn't necessarily mean a poor functional score. She achieved reasonably good results in almost 29% of her patients regarding 2-PD that was a little inferior to what we had got.

Kallio and Vastamäki, [41] reported that they obtained excellent or good results in 49.2% of cases in their series of delayed median nerve repair. Also Chassard et al., [42] reported that only 26.5% of cases with ulnar nerve injuries and 31% with median nerve lesions that were repaired by direct suture achieved S3+ or more. These differences in the outcomes of these studies from our work could be attributed to many factors. Of course the number of patients and the method used for nerve repair puts a direct impact on the results. In the former study, the number was quite big (132 patients) while in the second one direct suturing technique was used for nerve repair.

In a recent paper given by Klinik et al., [43], higher results were reported. Primary repair of injuries to the median and ulnar nerves at the wrist joint resulted in good to excellent sensory recovery in almost 71% of cases (S3+ or more) and near normal motor recovery in the same number of cases (70% of original strength of the affected muscles). These higher results in this report may be due to the fact that direct suturing techniques makes only one anastomosis in the injured nerve while cable nerve grafting results in two anastomotic sites that makes nerve regeneration much inferior [44].

Conclusion:

Using nerve auto-grafts and vein conduits is a new method of peripheral nerve repair that utilizes the patient's own tissue without hazards of using foreign materials. It yielded comparable results to those obtained by other methods of reconstruction regarding both sensory and motor recovery.

REFERENCES

- 1- Sinis N., Schaller H.E., Becker S.T., Schlosshauer B., Doser M., Roesner H., et al.: Nerve gaps limit the regenerative potential of bioartificial nerve conduits filled with Schwann cells. *Restorative Neurology and Neuroscience*, 25: 131-41, 2007.
- 2- Lundborg G. and Rydevik B.: Effects of stretching the tibial nerve of the rabbit. A preliminary study of the intraneural circulation and the barrier function of the perineurium. *J. Bone Joint Surg. Br.*, 55: 390-401, 1973.
- 3- Miyamoto Y., Watari S. and Tsuge K.: Experimental studies on the effects of tension on intraneural microcirculation in sutured peripheral nerves. *Plast. Reconstr. Surg.*, 63: 398-403, 1979.
- 4- Radek A.J.: Blood supply of transected rabbit peripheral nerve after end-to-end suture or autogenous grafting. A microangiographic study. *Scand J. Plast. Reconstr. Surg.*, 20: 273-7, 1986.
- 5- Millesi H., Meissl G. and Berger A.: The interfascicular nerve grafting of the median and ulnar nerves. *J. Bone Joint Surg. Am.*, 54: 727-50, 1972.
- 6- Millesi H., Meissl G. and Berger A.: Further experience with interfascicular grafting of the median, ulnar, and radial nerves. *J. Bone Joint Surg. Am.*, 58: 209-218, 1976.
- 7- Scherman P., Kanje M. and Dahlin L.: Bridging short nerve defects by direct repair under tension, nerve grafts or longitudinal sutures. *Restorative Neurology and Neuroscience*, 22: 65-72, 2004.
- 8- Sunderland I.R., Brenner M.J., Singham J., Rickman S.R., Hunter D.A. and Mackinnon S.E.: Effect of tension on nerve regeneration in rat sciatic nerve transection model. *Ann. Plast. Surg.*, 53: 382-387, 2004.
- 9- Millesi H.: Nerve grafting. *Clin. Plast. Surg.*, 11: 105, 1984.
- 10- Ruch D.S., Deal N.D., Ma J., Smith A.M., Castle J.A., Walker F.O., et al.: Management of Peripheral Nerve Defects: External Fixator-Assisted Primary Neuroorrhaphy. *J. Bone Joint Surg. Inco.*, 86A (70): 1405-13, 2004.
- 11- Daoutis N.K., Gerostathopoulos N.E., Efstathopoulos D.G., Misitizis D.P., Bouchlis G.N. and Anagnostou S.K.: Microsurgical reconstruction of large nerve defects using autologous nerve grafts. *Microsurgery*, 15: 502-5, 1994.
- 12- Mackinnon S.E.: New directions in peripheral nerve surgery. *Ann. Plast. Surg.*, 22: 257-73, 1989.
- 13- Millesi H.: Techniques for nerve grafting. *Hand Clin.*, 16: 73-91, 2000.
- 14- Trumble T.: Overcoming peripheral nerve defects. In: Gelberman R.H., editor. *Operative nerve repair and reconstruction*. Philadelphia: JB Lippincott, P 507-24, 1991.

- 15- Trumble T. and Vanderhooft E.: Nerve grafting for lower-extremity injuries. *J. Pediatr. Orthop.*, 14: 161-5, 1994.
- 16- Trumble T.E., Vanderhooft E. and Khan U.: Sural nerve grafting for lower extremity nerve injuries. *J. Orthop. Trauma.*, 9: 158-63, 1995.
- 17- Meek M.F. and Coert J.H.: Clinical use of nerve conduits in peripheral-nerve repair: Review of the literature. *J. Reconstr. Microsurg.*, 18: 97-109, 2002.
- 18- Wang K.K., Costas P.D., Jones D.S., Miller R.A. and Seckel B.R.: Sleeve insertion and collagen coating improve nerve regeneration through vein conduits. *J. Reconstr. Microsurg.*, 9: 39-48, 1993.
- 19- Xu J., Sotereanos D.G., Moller A.R., Jacobsohn J., Tomaino M.M., Fischer K.J., et al.: Nerve wrapping with vein grafts in a rat model: A safe technique for the treatment of recurrent chronic compressive neuropathy. *J. Reconstr. Microsurg.*, 14: 323-30, 1998.
- 20- Zhang F., Blain B., Beck J., Zhang J., Chen Z. and Chen Z.W.: Autogenous venous graft with one-stage prepared Schwann cells as a conduit for repair of long segmental nerve defects. *J. Reconstr. Microsurg.*, 18: 295-300, 2002.
- 21- Berenholz L., Sega S., Gilad V.H., Klein C., Yehezkeili E., Eviatar E., et al.: Agmatine treatment and vein graft reconstruction enhance recovery after experimental facial nerve injury. *Journal of the Peripheral Nervous System*, 10: 319-328, 2005.
- 22- Tang J.B., Gu Y.O. and Song Y.S.: Repair of digital nerve defect with autogenous vein graft during flexor tendon surgery in zone 2. *J. Hand Surg.*, 18: 449-453, 1993.
- 23- Xu J., Varitimidis S.E., Fisher K.J., Tomaino M.M. and Sotereanos D.G.: The effect of wrapping scarred nerves with autogenous vein graft to treat recurrent chronic nerve compression. *J. Hand Surg.*, 25: 93-103, 2000.
- 24- Seckel B.R., Ryan S.E., Gagne R.G., Chiu T.H. and Watkins E.: Target-specific nerve regeneration through a nerve guide in the rat. *Plast. Reconstr. Surg.*, 78: 793, 1986.
- 25- Dellon A.L.: Wound healing in nerves. *Clin. Plast. Surg.*, 17: 545, 1990.
- 26- Stahl S. and Goldberg J.A.: The use of vein grafts in upper extremity nerve surgery. *Eur. J. Plast. Surg.*, 22: 255-259, 1999.
- 27- Acar M., Karacalar A., Ayyildiz M., Unal B., Canan S., Agar E., et al.: The effect of autogenous vein grafts on nerve repair with size discrepancy in rats: An electrophysiological and stereological analysis. *Brain Research*, 1198: 171-81, 2008.
- 28- Callahan A.D.: Sensibility assessment: prerequisites and techniques for nerve lesions in continuity and nerve lacerations. In: Hunter J.M., Mackin E.J., Callahan A.D., eds. *Rehabilitation of the hand: Surgery and therapy*, 4th ed. St. Louis: Mosby, 129-152, 1995.
- 29- American Society for Surgery of the Hand: Clinical assessment recommendations, appendix 3. *The hand: evaluation and treatment*. New York: Churchill Livingstone, 106-107, 1983.
- 30- Medical Research Council: Peripheral nerve injuries. *Spec. Rep. Med. Res. Council*, 282, 1954.
- 31- Hentz V.R., Rosen J.M., Xiao S.J., McGill K.C. and Abraham G.: The nerve gap dilemma: A comparison of nerves repaired end to end under tension with nerve grafts in a primate model. *The Journal of Hand Surgery*, 18 (3): 417-425, 1993.
- 32- Chiu D.T.W. and Strauch B.: A prospective clinical evaluation of autogenous vein grafts used as a nerve conduit for distal sensory nerve defects of 3cm or less. *Plast Reconstr. Surg.*, 86: 928, 1990.
- 33- Walton R.L., Brown R.E., Mataroy W.E., Borah G.L. and Dolph J.L.: Autogenous vein graft repair of digital nerve defects in the finger: A retrospective clinical study. *Plast. Reconstr. Surg.*, 84: 944, 1989.
- 34- Suri A., Mehta V.S. and Sarkar C.: Microneural anastomosis with fibrin glue: An experimental study. *Neurology India*, 50 (1): 23-6, 2002.
- 35- Grayeli A.B., Mosnier I., Julien N., El Garem H., Bouccara D. and Sterkers O.: Long-term functional outcome in facial nerve graft by fibrin glue in the temporal bone and cerebellopontine angle. *Eur. Arch. Otorhinolaryngol.*, 262: 404-407, 2005.
- 36- Thompson D.F., Letassy N.A. and Thompson G.D.: Fibrin glue: A review of its preparation, efficacy, and adverse effects as a topical hemostat. *Drug Intell Pharm.*, 22 (12): 946-52, 1988.
- 37- Palm M.D. and Altman J.S.: Topical Hemostatic Agents: A Review. *Dermatol. Surg.*, 34: 431-445, 2008.
- 38- Wong K.H., Coert J.H., Robinson P.H. and Meek M.F.: Comparison of assessment tools to score recovery of function after repair of traumatic lesions of the median nerve. *Scand J. Plast. Reconstr. Surg. Hand Surg.*, 40: 219-224, 2006.
- 39- Rosen B.: Recovery of sensory and motor function after nerve repair: A rationale for evaluation. *J. Hand Ther.*, 9: 315-327, 1996.
- 40- Jerosch-Herold C.: Should sensory function after median nerve injury and repair be quantified using two point discrimination as the critical measure? *Scand J. Plast. Reconstr. Hand Surg.*, 34: 339-343, 2000.
- 41- Kallio and Vastamäki: An Analysis of the Results of Late Reconstruction of 132 Median Nerves. *Journal of Hand Surgery (British and European Volume)*, 18 (1): 97-105, 1993.
- 42- Chassard M., Pham E. and Comtet J.: Two-Point Discrimination Tests versus Functional Sensory Recovery in both Median and Ulnar Nerve Complete Transections. *Journal of Hand Surgery (British and European Volume)*, 18 (6): 790-796, 1993.
- 43- Kilinc A., Ben Slama S., Dubert T., Dinh A., Osman N. and Valenti P.: Results of primary repair of injuries to the median and ulnar nerves at the wrist. *Chir. Main.*, 28 (2): 87-92, 2009.
- 44- Millesi H.: Factors affecting the outcome of peripheral nerve surgery. *Microsurg.*, 26 (4): 295-302, 2006.