

## The Use of Expanded Mutter Flap for Postburn Cheek Reconstruction

KARIM K. EL-LAMEI, M.D.

*The Department of Plastic and Reconstructive Surgery, Faculty of Medicine, Ain Shams University.*

### ABSTRACT

Facial burns represent significant problems to the reconstructive surgeon. Despite many reconstructive procedures suggested to treat such deformities the outcome is usually not satisfactory to the patients. The author introduces the expanded Mutter flap as a solution to resurface whole cheek aesthetic unit. 20 flaps were applied in 12 patients with overall success in 10 patients while two patients suffered major flap loss due to congestion. The flap is thin with excellent colour and texture matching. The technique of expansion and flap inset is straightforward and the drawbacks are limited to possible flap congestion and widened scar at the donor site.

### INTRODUCTION

The face is the most exposed part of the human body. Our facial features identify us as humans and give every person his own individual characteristics. Moreover, the face is not just a mask that we are wearing but it conveys our most delicate emotion through the fine motions of the underlying facial muscles.

The patient who sustained major facial burn trauma is subjected to major psychological disturbances. He or she has to endure not only the diverse reactions of other people during every day contact but also his own individual rejection of his deformed features when looking in the mirror. Such patient seeks the help of the plastic surgeon with one aim to erase as much as possible the stigmata of burn with the least scarring possible. Frequently, some surgeons guided by the patient's concerns and words address the problems in a piecemeal fashion using traditional techniques i.e. Z plasties, full thickness skin grafts or cervical skin advancement. By doing so, they merely add new unsightly scars if not new deformities to the already mutilated face (Fig. 1). For optimum results resurfacing of the face should be performed in aesthetic units so that the final scars are hidden within the junctions of adjacent units [1].

In an attempt to provide a more aesthetic reconstruction, the author presents a modification to

Mutter flap for total cheek reconstruction [2]. In many cases, the skin in the area spanning between the neck and shoulder is intact. The expansion of the Mutter flap doesn't only increase the reach of the flap but also thins it as well as increases its blood supply, which makes it a safe and convenient armamentarium for the cheek and neck reconstruction.

### PATIENTS AND METHODS

From December 2007 to January 2010, 12 patients, all females with major burn scarring of the face mainly the cheek area were included in the study. The average age was 21 years, ranging from 9 to 35 years. All patients were victims of flame burns and all showed mature scarring of at least 15 months duration. Eight patients have already undergone other operations elsewhere (e.g. Z-plasties or full thickness skin grafting) to correct some deformities.

For each case, a rectangular expander was chosen according to the vertical and transverse facial dimensions. The vertical extent was measured as a straight line extending superiorly from the infraorbital rim at its lateral extent to the lower border of the mandible just anterior to the masseter muscle. The transverse extent was measured from the above the alar crease anteriorly to a point just above the tragus posteriorly. Once these dimensions were taken the expander was selected with its length and width matching the transverse and the vertical facial measurements respectively.

The rectangular expander was placed through a 5cm incision just distal to the acromion process. The plane of dissection is suprafascial and along the anterior border of the trapezius muscle which is considered to be the axis of the flap. The pocket formed should be well centred over the anterior border of trapezius so as not to expand too far from the original territory of the flap. The connection tube and valve were placed in a separate pocket in

the arm on the other side of the incision. Good haemostasis obviated the use of suction drain. The wound closure was done in three layers. The first row of suture consists of 3 sutures of 2-0 polyglactin 910 anchoring the under surface of elevated skin, few millimetres proximal to the incision, to the fascia just anterior to the expander in place. This row keeps the expander away from the suture line to minimize early scar expansion or exposure of the expander. The skin was then closed in 2 layers. The external interrupted skin sutures were removed at day fifteen and the expansion program is started after the third week. The inflation of expander is continued till 15-20% of overexpansion was achieved in order to compensate for the early contraction of the transposed flap.

Once the goal of expansion was reached, usually within 3 months, the patient returned to the operating room and whole aesthetic unit of the affected cheek was excised and the expanded Mutter flap was raised and transposed to the ipsilateral cheek. The skin along the vertical walls of the expander was used to close the donor defect primarily. The flap pedicle was based medially on a bridge of tissue 5-6cm in width along the cervical part of the trapezius muscle. During flap inset, the under surface of the flap is anchored to the facial periosteum at two points like a hammock via 3-0 polypropylene sutures to prevent lower eyelid ectropion. The first is situated along the nose-cheek junction at the most distal extent of the flap, the second point beside the lateral orbital rim above the level of the lateral canthus at the mid upper extent of the flap. No attempt was made to tube the pedicle as this issued immediate flap congestion in our first case. Dressing the raw surface with gauze and antibiotic ointment is quite sufficient to control any discharge from the pedicle. Two weeks later,

the pedicle was divided and the rest of the flap was inset (Fig. 2). The pedicle was sometimes used as a full thickness graft after defatting for any other region needing resurfacing like the nose or lower lip.

## RESULTS

Of the 12 consecutive patients in this study, 8 patients underwent bilateral cheek reconstruction while 4 had a unilateral procedure. Of the 20 flaps, 14 survived completely while 4 showed partial flap loss. Two patients suffered a major loss with nearly the distal half of the flap was debrided and left to heal by dressing. Its to be noted that during the mid expansion process small telangectatic vessels start to appear and continue to increase in size and number along the expanded skin as the expansion proceeds. Sixteen flaps showed early postoperative congestion especially at the upper distal corner near the medial canthus. Early management with chemical leeching resulted in salvage of this zone in most cases. In the 4 patients showing minor flap losses, a small triangular area under the inferior orbital rim showed superficial sloughing and it healed within a couple of weeks with daily application of topical antimicrobial with very acceptable result. No complications related to the expansion procedure such as exposure, extrusion, infection or deflation were encountered. In 6 of the 12 patients the pedicle was used during its division as a full thickness graft to resurface other areas of the face, mainly the lower lip. Ten patients were completely satisfied with the outcome (Fig. 3). The two patients with the major flap loss, asked for further corrective procedures. The scar at the donor site, although it widened during the late postoperative period, was never a concern to the patient.

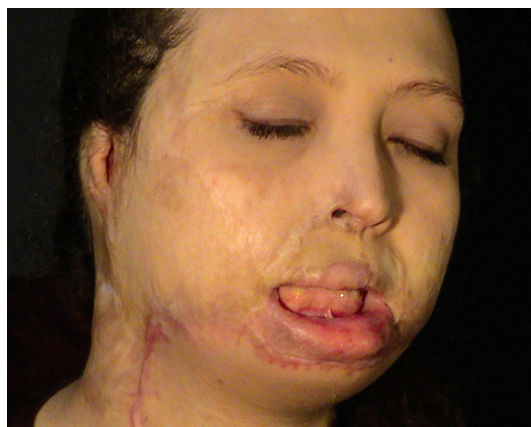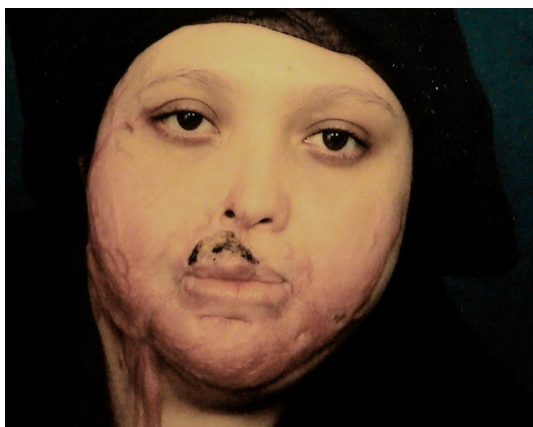


Fig. (1): (Left) A photograph provided by a patient who was a victim of chemical burn assault (not included in the study). (Right) The patient at the time of presentation after undergoing 5 operations elsewhere. The patchy effect of full thickness skin grafting on cheek and upper lip is evident as well as marked lower lip ectropion after cervical skin advancement.



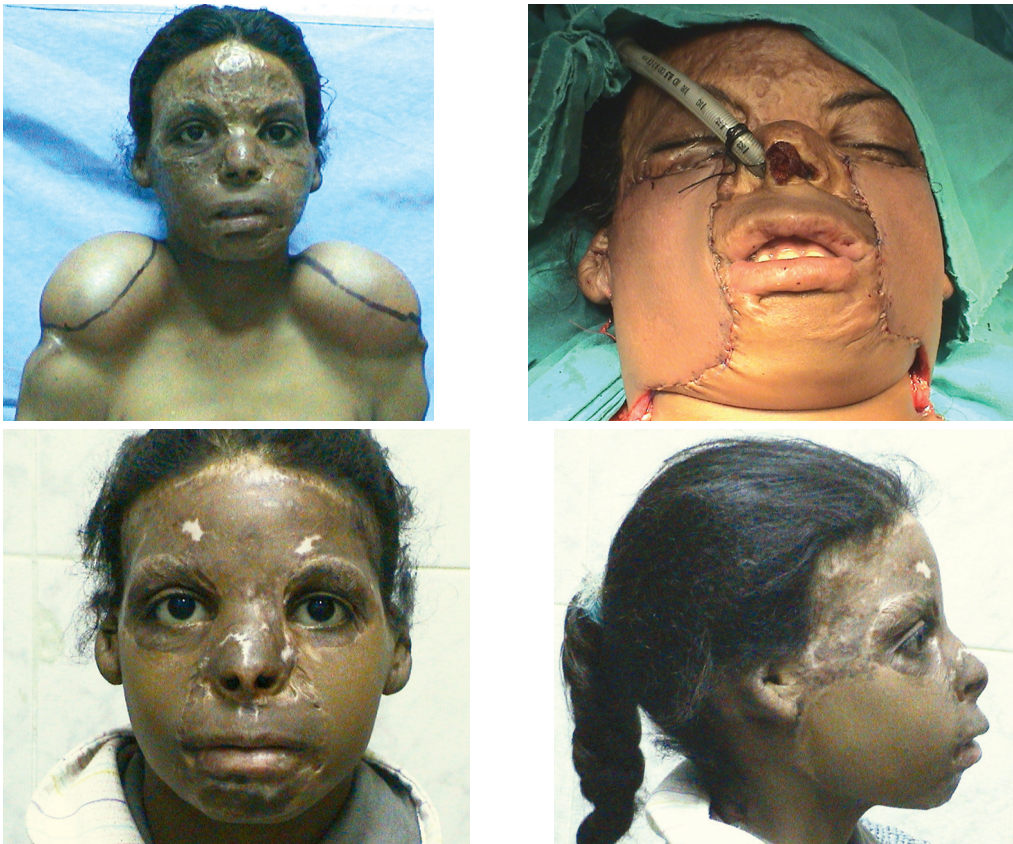

Fig. (2): (Above, left) A 9-year-old child with severe facial burn and two expanders in place. The borders of the flap are marked on the expanded skin. (Above, right) Intraoperative view after the two cheeks have been resurfaced by two expanded mutter flaps. (Below, left) 11 months postoperative front view and (Below, Right) right side view. The patient has also undergone expanded full-thickness skin graft from the abdomen for the forehead and nose.

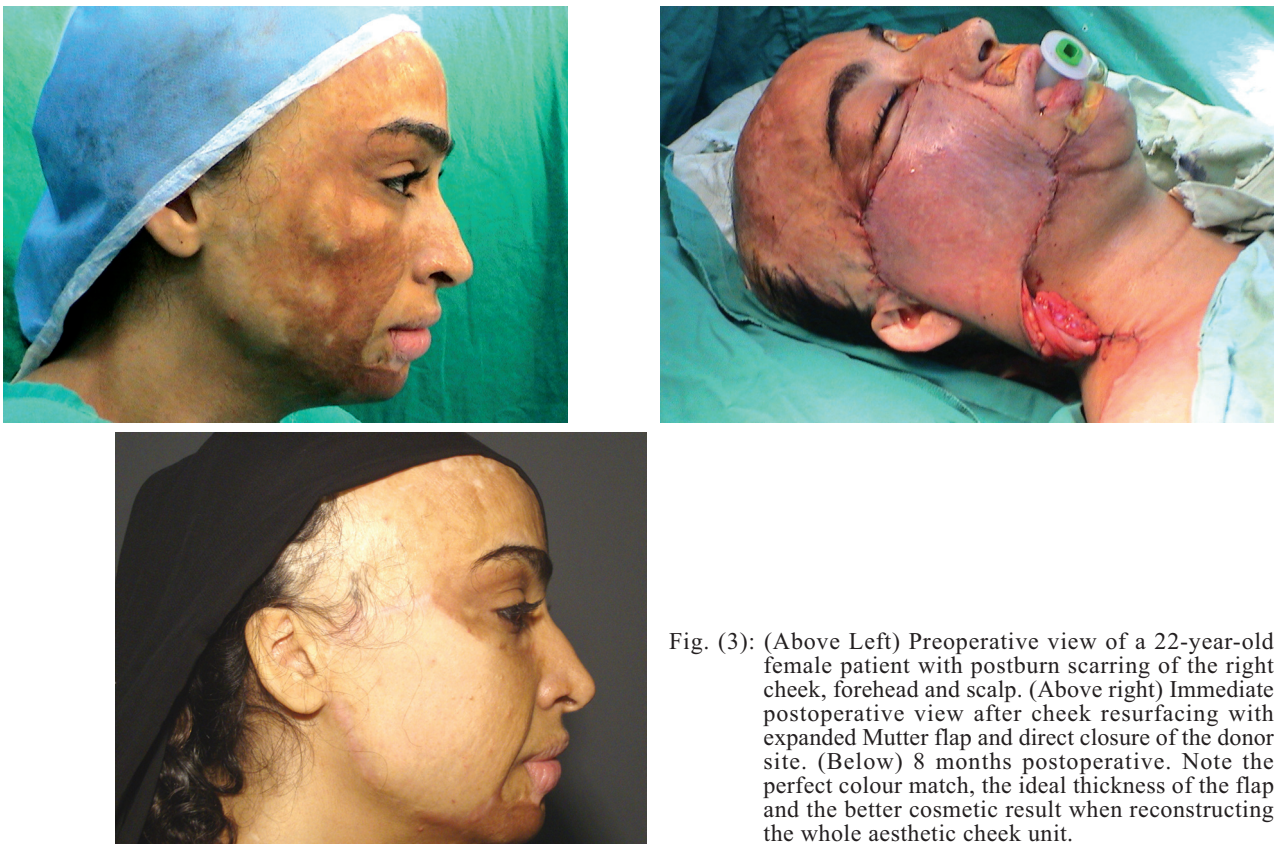

Fig. (3): (Above Left) Preoperative view of a 22-year-old female patient with postburn scarring of the right cheek, forehead and scalp. (Above right) Immediate postoperative view after cheek resurfacing with expanded Mutter flap and direct closure of the donor site. (Below) 8 months postoperative. Note the perfect colour match, the ideal thickness of the flap and the better cosmetic result when reconstructing the whole aesthetic cheek unit.

## DISCUSSION

The psychological trauma caused burn major facial burn is immense. Its impact on the self-confidence and productivity of the affected persons is devastating. The outcome is an individual seeking isolation, hiding behind veils and unable to lead a normal life.

Such patients present to the plastic surgery clinic, with hypertrophic and keloid scars all over the face especially the cheek areas and start complaining that these scars are their main concerns. Some surgeons deal with the patient problem as a simple resurfacing procedure. They think that by removing these small bumps and giving the patient a regular smooth surface they have solved the issue. Hence they start to use skin grafts or the available surrounding tissue whether in the neck or deltopectoral region ignoring the basic principles of any aesthetic reconstruction. The aesthetic reconstruction entails the replacement of the missing tissue with one having the same colour, texture and thickness and no other part of the body is concerned with this concept more than the human face. Feldman suggested a single large full thickness from the abdomen to avoid any incision lines on the face [3]. Spence used an expanded full thickness graft from the suprascapular/shoulder region [4]. Full thickness skin graft to the cheek tends to contract ending in a tight hyperpigmented shiny appearance of the cheek, which is accentuated during animation. They are best reserved for forehead reconstruction [5]. A thin flap thus seems the best solution. A Free flap, especially a thin perforator flap is another option but it is a complicated procedure and colour matching remains unsolved [6]. Cervical skin advancement flaps cause obliteration of the cervicomenal angle, ectropion of the lower lip and/or lower eyelid and transverse unsightly scar along the cheek [5]. The expanded deltopectoral flap although having a similar colour as that of the face, still appear thick and their long pedicles need to be tubed to decrease the discharge. Moreover the resultant distortion to the chest area is marked especially in females. Another regional flap suggested for cheek reconstruction is supraclavicular flap [7-9]. However the amount of tissue transferred with this flap cannot totally resurface the whole cheek aesthetic unit. Even with expansion, the arc of flap rotation limits the reach of flap high in the cheek and it is best reserved for postburn neck reconstruction. The use of expanded Mutter flap seems to be the most practical solution for cheek reconstruction. The flap is thin of similar colour and texture and allows reconstruction of

the whole cheek aesthetic unit with the least conspicuous scars. On the other hand the donor site morbidity is not disfiguring and well accepted by the patient. Spence reported a complication rate of 23% of the 58 shoulder flaps performed during a ten-year period [5]. The complications ranged from exposures of the expander or deflations to significant flaps losses. This seemed a little bit high for a relatively simple procedure. In this article, the author presents his own technique of expander application and flap transposition performed in 12 patients. The small incision for expander insertion, good haemostasis, port location and meticulous closure; all are essential for avoiding early complications with the expansion process. Centring the expander along the anterior border of the trapezius and not surpassing the distal border of acromion is important for flap survival. Spence stated that one vessel at least should be inspected along the pedicle and its preservation is important for flap survival [5]. It is the author's recommendation to base a 6cm pedicle along the cervical portion of the trapezius to ensure the inclusion of more than one vessel. Classically, the Mutter flap blood supply comes through the perforators of the trapezius muscles. The source of those perforators; whether the occipital artery and/or the transverse cervical artery is still an unclear issue and necessitates further anatomical investigation. Moreover, the transposition of the flap into the defect is facilitated by its relatively narrow posterior pedicle. The main drawback is the marked telangiectasia accompanying the expansion process and the subsequent congestion, which seems unavoidable in some cases. Early chemical leeching during the first 3 days seems the only solution available for a successful result. Another disadvantage is the resultant wide atrophic scar at the donor site. The hidden nature of this wound makes it well tolerated by most patients.

## REFERENCES

- 1- Gonzalez-Ulloa M.: Restoration of the face covering by means of selected skin in regional aesthetic units. *Br. J. Plast. Surg.*, 9: 212, 1956.
- 2- Mutter T.D.: Case of deformity from burns relieved by operation. *Am. J. Med. Sci.*, 4: 66, 1842.
- 3- Feldman J.J.: Facial resurfacing: the single sheet concept. In Brent B, editor, 1<sup>st</sup> edition. *The artistry of reconstructive surgery: selected classic case studies*, vol. 1. St. Louis (MO) Mosby, pp. 372-42, 1987.
- 4- Spence R.J.: Experience with novel uses of tissue expanders in burn reconstruction of the face and neck. *Ann. Plast. Surg.*, 28: 453, 1992
- 5- Spence R.J.: An algorithm for total and subtotal facial

- reconstruction using an expanded transposition flap: a 20-year experience. *Plast. Reconstr Surg.*, 121: 795, 2008.
- 6- Parrett B.M., Pomahac B., Orgill D.P., et al.: The role of free-tissue transfer for head and neck burn reconstruction. *Plast. Reconstr Surg.*, 120: 1871, 2007.
- 7- Pallua N., Machens H.G., Oliver R., Becker M. and Berger A.: The fasciocutaneous supraclavicular artery island flap for releasing postburn mentosternal contractures. *Plast. Reconstr. Surg.*, 99: 1878, 1997.
- 8- Zaki M.S.: The "Epaulet" flap: A technique for neck resurfacing. 23<sup>rd</sup> Annual Meeting of Egyptian Society for Plastic and Reconstructive Surgeons, Alexandria, 1998.
- 9- Heitland A.S. and Pallua N.: The single and double-folded supraclavicular island flap as a new therapy option in the treatment of large facial defects in Noma patients. *Plast. Reconstr Surg.*, 115: 1591, 2005.
- 10- Luce E.A.: Cervicohumeral Flap. In: Strauch B., Vasconez LO., Hall-Findlay EJ. And Lee BT., editors. *Grabb's Encyclopedia of Flaps*. Third edition, Vol.1. Philadelphia. Lippincott, Williams and Wilkins, pp 368-371, 2009.