

SMAS Advancement Flap for Reconstruction of Superficial Parotidectomy Defect

MOSTAFA EL-SAYED SALEH, M.D.

The Department of General Surgery, Benha Faculty of Medicine, Benha University, Egypt.

ABSTRACT

Benign parotid lesions are generally removed by superficial parotidectomy without reconstruction of the parotid bed. However, the disadvantage of this procedure is frequently a conspicuous hollow contour around the angle of the mandible in addition to Frey's syndrome. This non-randomized, uncontrolled, prospective study was designed to evaluate the aesthetic outcome and frequency of development of Frey's syndrome after superficial parotidectomy with superficial musculo-aponeurotic system (SMAS) advancement flap. The study included 20 patients assigned for superficial parotidectomy with reconstruction of the parotid bed using SMAS flap. Patients were observed for the development of Frey's syndrome and the aesthetic outcome with mean follow-up period of 21.3 ± 6.2 months. The mean patients' satisfaction score about the aesthetic appearance was 7.9 ± 1 ; range: 5-9. Only two females (10%) were partially satisfied. No patient developed Frey's syndrome. This technique is simple, reliable and improves the aesthetic and functional sequelae following superficial parotidectomy.

INTRODUCTION

Until now, aesthetic goals in parotid surgery have seldom been addressed because oncologic concerns have largely overshadowed aesthetic issues for patients with parotid masses. Fortunately, the majority of parotid masses are benign pleomorphic adenomas that rarely recur, leaving a large group of patients healthy after their parotid surgery, with some desiring aesthetic improvement in their facial appearance. Traditional parotidectomy incisions leave a visible scar on the neck as well as a visible hollow in the retromandibular region, which can extend onto the cheek [1].

Frey's syndrome is an unpleasant phenomenon characterized by recurrent episodes of facial gustatory flushing and sweating limited to the cutaneous distribution of the auriculotemporal nerve. It occurs in up to 20 per cent of patients who have undergone parotid surgery and is thought to be due to misdirected regeneration of parasympathetic fibres normally supplying the parotid gland to

innervate the cutaneous sweat glands [2-4]. The timing of its development ranged from 20 days to 22 months, median 11 months [5].

The superficial fascia of the face and neck overlying the parotid and cheek area is referred to as the superficial musculo-aponeurotic system (SMAS). This layer runs deep to the subcutaneous tissue and above the parotid capsule. It is continuous with the platysma inferiorly and inserts on the zygoma superiorly, with attachments to the temporoparietal fascia. It becomes attenuated medially, where it blends into the facial muscle investing fascia. The SMAS is attached to the deep fascia via parotid-cutaneous ligament-like tissue projections and it is connected to the dermis by multiple fibrous septa, and thus lifting and pulling the SMAS pulls the overlying skin to which it remains attached medially [4,6]. Application of SMAS flap in face lifting and rejuvenation is simple and has proven its safety and its relevance regarding the cosmetic outcome. However, the SMAS flap procedures have not yet a routine procedure for many surgeons [7-10].

This study was designed to evaluate the aesthetic outcome and frequency of development of Frey's syndrome after superficial parotidectomy with surgical bed reconstruction using SMAS flap.

PATIENTS AND METHODS

This non-randomized, uncontrolled, prospective study was conducted at the General Surgery Department; Benha University Hospital over a period of 3 years, started April 2007 and included 20 patients planned for superficial parotidectomy. Males accounted for 12 of the cases and 8 were females. The ages ranged from 12 to 53 years with a mean of 36.7 ± 9.7 years. All tumors were benign; there was no palpable lymph node and MRI had shown no evidence of spread. With Ethics

Committee approval, all patients were informed and consented for the SMAS flap operation after explanation and discussion of the procedure and possible complications of various surgical modalities.

All operations were performed under general endotracheal anesthesia. Patient's head was positioned to rest on a pillow on the healthy side and the external auditory meatus was plugged and ear lobule was folded and retracted for complete exposure of the swelling. A modified Blair incision was used, it begins as a vertical limb in front of the tragus extending under the ear and ending in front of the anterior border of the sternocleidomastoid muscle. The skin incision was deepened down to the capsule of the parotid gland, and the skin flap was raised under the periparotid fascia, using sharp scissor dissection as far as the anterior border of the gland (Fig. 1).

The main trunk of the facial nerve was found about 1cm medio-inferiorly to the pointed end of the trigonal cartilage of the ear, bisecting the angle between posterior belly of digastrics muscle and the bony tympanic plate, emerging in front of the mastoid process at about its mid-point as it passes forwards from under cover of the bone into the substance of the gland (Fig. 2). A straight mosquito artery forceps was used for dissection of the superficial parotid from deep parotid in the plane of the facial nerve, this allowed the superficial parotid tissue to be lifted away, gradually exposing the full anatomical distribution of the facial nerve. Haemostasis was done using bipolar diathermy in order to allow identification and visualization of the branches of the facial nerve. Bleeding near facial nerve branches was stopped by the pressure of wet gauze for few minutes. Dissection was continued till the parotid duct. Removal of the specimen after ligation and division of the parotid duct was done.

The SMAS flap was dissected sharply from the skin and subcutaneous tissue (Fig. 3) and then was stretched and advanced so as to cover the dissected raw area and fixed using vicryl 3/0 sutures to the anterior edge of the sternocleidomastoid muscle, (Fig. 4). Closed suction drainage was used, the suction drain tube was inserted through a separate stab into the sub-SMAS space, (Fig. 5) away from the dissected facial nerve to prevent damage to the nerve and the wound was closed using subcuticular proline 4/0 suture. Closed suction drainage with external pressure by gauge was maintained for 48 or 72 hours and, thereafter, a thin layer of gauze was placed on the wound. The sutures were removed one week after the operation, (Fig. 6).

Outcome evaluation:

- 1- Primary outcome: The surgical feasibility, intra-operative bleeding, operative time and postoperative complication namely; occurrence of facial nerve weakness, hematoma or seroma formation, local saliva accumulation, or salivary fistula.
- 2- Secondary outcome: The development of Frey's syndrome and the aesthetic outcome depending on subjective satisfaction with the incision scar and depth of the retromandibular dimple as assessed on a visual analogue scale ranged between 0=unsatisfied and 10=highly satisfied.

The follow-up was performed as outpatient clinic visits 1,2 & 4 weeks & 3 months after surgery and 6-monthly thereafter.

Statistical analysis: Data were analyzed using *t*-test and Chi-square test. Statistical analysis was conducted using the SPSS (Version 10, 2002) for Windows statistical package.

RESULTS

The study included 20; 12 men and 8 females with mean age of 36.7 ± 9.7 ; range: 12-53 years. Female patients were non-significantly ($p > 0.05$) older than males. All patients had smooth intraoperative course with mean operative time of 67 ± 10.5 ; range: 50-90 minutes. Intraoperative blood loss was minimal during both parotidectomy and dissection of SMAS flap. Suction drains were removed after a mean duration of 50.6 ± 15.2 ; range: 24-72 hours. Mean hospital stay was 56.6 ± 12.1 ; range: 40-72 hours. During the immediate postoperative period, only 2 cases with facial neuropraxia that extended for less than 2 weeks were reported. Mild cheek edema was noticed and resolved on conservative treatment with non-steroidal anti-inflammatory drugs. No wound infection or salivary fistulae or hematoma collection were noticed.

All patients completed the study and follow-up with no missing cases. The mean follow-up period was 21.3 ± 6.2 ; range 10-36 months. Throughout the postoperative follow-up period, no patient developed Frey' syndrome or complained of retromandibular recess or wound dimpling. The mean patients' satisfaction score about the aesthetic appearance was 7.9 ± 1 ; range: 5-9 (Table 1). There was a non-significant decrease of the mean satisfaction score of female patients (7.4 ± 1.3 ; range: 5-9) compared to that recorded for male patients (8.3 ± 0.6 ; range: 7-9).

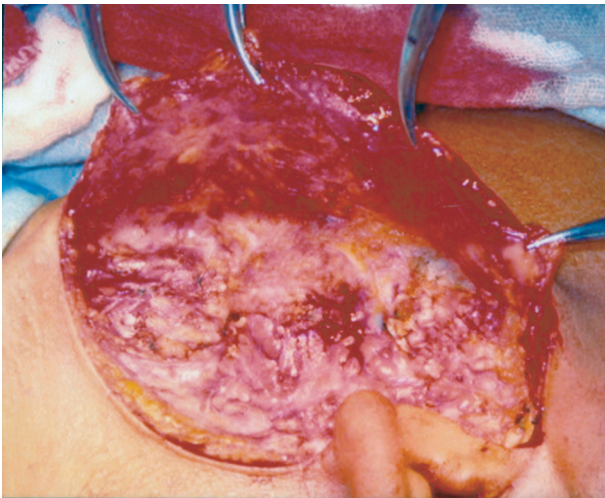


Fig. (1): Skin flap was raised under the periparotid fascia and the glandular tissues were exposed.

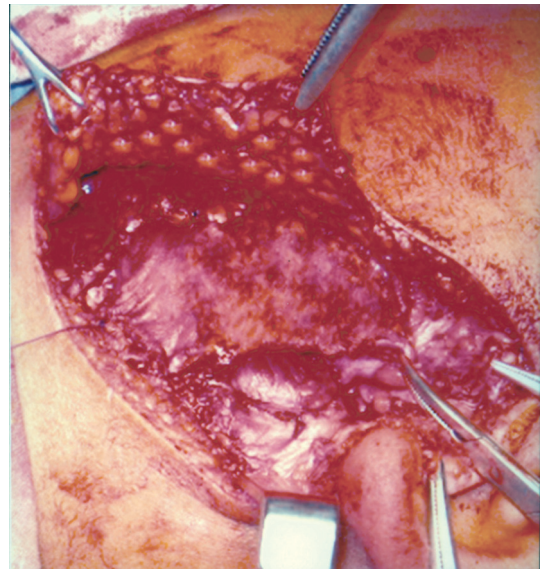

Fig. (4): SMAS flap advanced so as to cover the dissected raw area and fixed to the anterior edge of the sternocleidomastoid muscle.

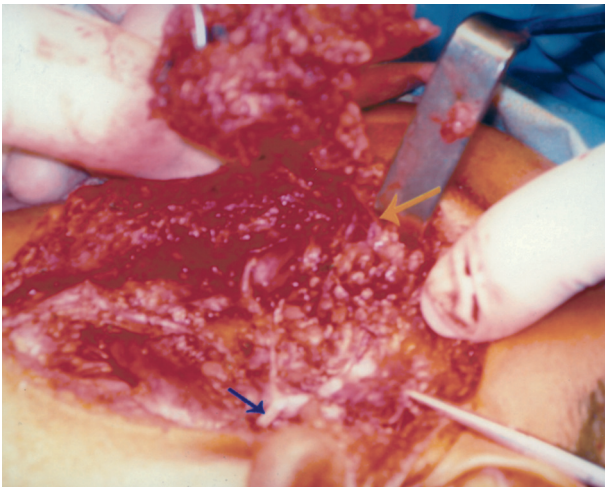


Fig. (2): Bifurcation of facial nerve (blue arrow) and Stensen's duct (yellow arrow) were exposed.

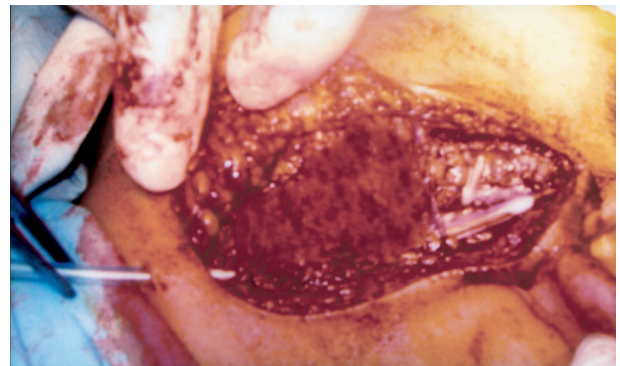


Fig. (5): Suction drainage tube was inserted through a separate stab into the sub-SMAS space.

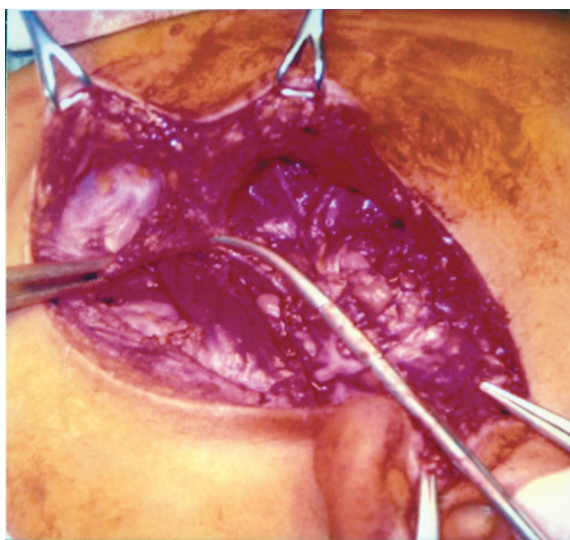


Fig. (3): SMAS flap was dissected sharply from the skin and subcutaneous tissue.

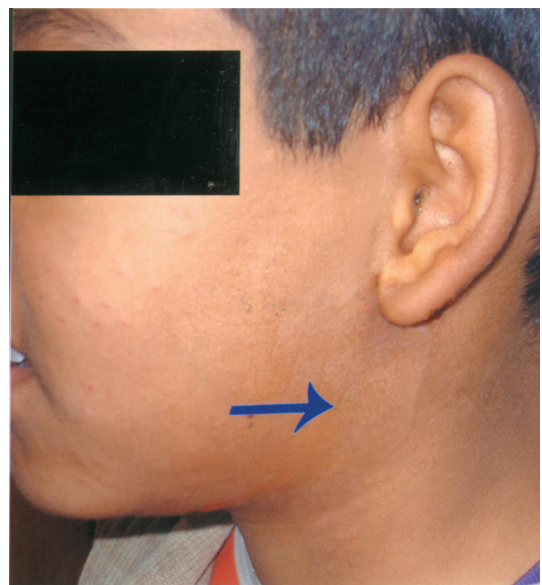

Fig. (6): Postoperative appearance of the wound showing no retromandibular recess or wound dimple (arrow).

Table (1): Patients' satisfaction scores.

Satisfaction scores	Number (%)
VAS score=9	5 (25%)
VAS score=8	11 (55%)
VAS score=7	2 (10%)
VAS score=6	1(5%)
VAS score=5	1 (5%)

DISCUSSION

Dissection and elevation of the skin flap at level of sub-SMAS space at the parotid fascia was easy but must be meticulous so as not to miss any of parotid-cutaneous ligament-like tissue projections that may be obstacle for completion of dissection up to the zygomatic arch. The used plane for dissection preserved the contents of the superficial fascia especially the frontal branch of the facial nerve and allowed identification of the zygomatic branch of the facial nerve at the zygomatic arch. One of disadvantages of such plane was perioperative bleeding [11], however, this was overcome by careful use of diathermy and identification of tissue projections that contains blood vessels. Dissection and separation of SMAS to be used as coverage flap for the operative raw area was easy, not time consuming with minimal bleeding. Similarly, Meningaud et al. [12] found that the dissection of SMAS flap was easy and rapid, provided undermining had carried out at the level of the parotid aponeurosis. The mean operative time was 67 ± 10.5 minutes, thus there was no meaningful time loss consumed for the elevation of the flap or for the dissection of the SMAS at end of surgery. This finding goes in hand with the previously reported in series used SMAS during facelift surgery.

Superficial parotidectomy for benign parotid lesions requires meticulous dissection to safeguard against injury of the facial nerve or its branches and to avoid missing of the minor salivary ducts or leaving remnant of the Stensen's duct leading to local salivary accumulation or salivary fistula. These complications were not encountered in the current study where dissection extended to expose the posterior belly of digastric using it as a landmark for identification of the main trunk of the facial nerve. Such technical rules agreed with Witt et al. [13] who identified both tympanomastoid suture and digastric muscle in cadaver and live parotidectomy as non-variable landmarks for facial nerve identification. Also, Gaillard et al. [14] re-

ported that during conservative parotidectomies with facial nerve dissection, only extent of surgery and particular local conditions of nerve dissection, especially the close contact of tumor with facial nerve and inflammatory conditions, were found to be associated with postoperative facial nerve dysfunction.

Throughout the observation period no case with salivary fistulae or local saliva accumulation was reported, this could be attributed to the application of SMAS flap, together with ligation of interlobular ducts. This agreed with Jianjun et al. [15] who reported no fistula or local salivary accumulation after use of a parotid fascia flap in superficial parotidectomy for benign tumors in the superficial lobe.

The rhytidectomy incision has recently been used to approach the parotid gland and has gained increasing popularity, particularly amongst facial-plastic surgeons. However, as the skin incision is placed further back with this approach than with the traditional incision, many surgeons remain concerned with reference to the adequacy of exposure [16]. In this study, the modified Blair incision used allowed full dissection of the parotid area and exposure of all gland boundaries. All patients had smooth postoperative course with good wound healing and no wound edge necrosis.

In the current study, the application of SMAS flap allowed disappearance of retromandibular defect and wound dimpling with mean patients' satisfaction score about the aesthetic appearance was 7.9 ± 1 ; range: 5-9. Moreover, throughout the follow-up period (mean; 21.3 ± 6.2 months) no patient had developed Frey's syndrome.

Such outcome were highly comparable to results obtained with conventional parotidectomy; Nitzan et al. [17] evaluated the quality of life of 125 patients underwent conventional parotidectomy for change in appearance, Frey's syndrome and pain that were reported by 70%, 57% and 30%, respectively. Also, Luna-Ortiz et al. [3] reported a frequency of Frey's syndrome in 61% of their series of superficial parotidectomy. Guntinas-Lichius et al. [18] retrospectively evaluated the frequency of Frey's syndrome in 610 patients underwent conventional parotidectomy and reported a frequency of 4% in that series. Also Bremerich et al. [19] reported a frequency of Frey's syndrome in 62% following superficial parotidectomy in 69 patients and minor's starch iodine test proved that 85% of the patients who did not notice Frey's syndrome after surgery actually had a subclinical manifestation.

Furthermore, the results of the current study were superior to that obtained by other maneuvers tried to overcome post-parotidectomy complications; Zaoli [20], used the temporoparietal fascia rotational flap is an interpositional barrier often proposed to prevent Frey's syndrome and to act as a soft tissue filler, but results were unsatisfactory. Jost et al. [21] proposed a procedure that combines displacement of the posterior belly of the digastric muscle, a flap with an upper pedicle taken from the sternocleidomastoid muscle and a double layer free graft, taken from the superficial and deep temporal fascias. This procedure seems complicated and time-consuming compared with the SMAS advancement flap. Gooden et al. [22] and Kerawala et al. [23] had shown that the sternocleidomastoid flap reconstruction following parotidectomy does not modify the incidence of Frey's syndrome and does not significantly improve facial contour and aesthetics. On contrarary, Han et al. [24] found immediate transplantation of the sternocleidomastoid muscle-great auricular nerve flap can repair the depressed deformity of the parotid area and Asal et al. [25] found reconstruction of the surgical defect after parotidectomy with a sternocleidomastoid muscle flap reduced the frequency of Frey's syndrome and provided good aesthetic results compared to those without flap. Zumeng et al. [26] tried to reduce the incidence of sensory deficits and Frey's syndrome by modifying the traditional superficial parotidectomy through elevation of the parotid gland fascia to form a posterior pedicle facial flap and then was replaced after the gland removal thus the great auricular nerve that runs within the parotid gland fascia was not separated and both the great auricular nerve and the parotid gland fascia were preserved. They reported that such modification abolished long-term sensory deficit totally and reduced the frequency of Frey's syndrome from 66.7% in control to 16.7% in modified group.

Moreover, the obtained results go in hand with that reported by Giannone & Muzio [27] and with Honig [28], who reported that the vascularized SMAS rotation advancement flap is clinically simple to perform and provides satisfactory cosmetic and functional results in patients undergoing conservative parotidectomy and were superior to that obtained by Angspatt et al. [29] who reported that the incidence of Frey's syndrome is substantially reduced from 48% by subjective review and 72% by objective measurement in patients underwent parotidectomy without using the SMAS preservation technique to 23.1 and 26.9%, respectively in patients had SMAS preservation. Zhao et al. [30] used a modified parotidectomy with conserving

the sub-SMAS and great auricular nerve reported an incidence of Frey's syndrome of 5.32%.

The advantage of the applied technique for abolishment of Frey's syndrome could be attributed to the fact that the SMAS flap used as a membrane guided tissue regeneration. Moreover, the SMAS flap seems to accelerate the nerve recovery, through provision of a supplementary blood flow inducing the formation of a capillary network around the ischemic nerve [31].

It could be concluded that SMAS advancement flap fixed to the anterior margin of sternocleidomastoid muscle should be performed for reconstruction of superficial parotidectomy defect as it is a quick procedure, simple, reliable and improves the aesthetic and functional outcome.

REFERENCES

- 1- Boynton J.F., Cohen B.E. and Barrera A.: Rhytidectomy and parotidectomy combined in the same patient. *Aesthetic Plast. Surg.*, 30 (1): 125, 2006.
- 2- Carpintero H.N., Sainz G.C., Garcia C.M. and Virto M.T.: Frey's syndrome: Report of three cases with two distinct etiopathogeneses. *An Pediatr. (Barc.)*, 64 (6): 588, 2006.
- 3- Luna-Ortiz K., Sanson-RioFrio J.A. and Mosqueda-Taylor A.: Frey syndrome. A proposal for evaluating severity. *Oral Oncol.*, 40 (5): 501, 2004.
- 4- Marks M.W. and Marks C.: *Aesthetic facial surgery*, Marks M.W., Marks C. (editors). In: *Fundamentals of Plastic Surgery*. Philadelphia, WB Saunders Company, 1998.
- 5- Henney S.E., Brown R. and Phillips D.E.: Parotidectomy: The timing of post-operative complications. *Eur. Arch. Otorhinolaryngol.*, 267: 131, 2010.
- 6- Ghassemi A., Prescher A., Riediger D. and Axer H.: Anatomy of the SMAS revisited. *Aesthetic. Plast. Surg.*, 27 (4): 258, 2003.
- 7- Mowlavi A. and Wilhelmi B.J.: The extended SMAS facelift: Identifying the lateral zygomaticus major muscle border using bony anatomic landmarks. *Ann. Plast. Surg.*, 52 (4): 353, 2004.
- 8- Bisaccia E., Khan A.J. and Scarborough D.A.: Anterior face-lift for correction of middle face aging utilizing a minimally invasive technique. *Dermatol. Surg.*, 30 (5): 769, 2004.
- 9- Khawaja H.A. and Hernandez-Perez E.: Transcutaneous face-lift. *Dermatol. Surg.*, 31 (4): 453, 2005.
- 10- Wang C.M., Nie J.Y. and Sheng H.M.: Application of platysma flap in face lifting. *Zhonghua Zheng Xing Wai Ke Za Zhi*, 22 (4): 292, 2006.
- 11- Yu G.Y.: Superficial parotidectomy through retrograde facial nerve dissection. *J. R. Coll. Surg. (Edinb)*, 46: 104, 2001.
- 12- Meningaud J.P., Bertolus C. and Bertrand J.C.: Parotidectomy: Assessment of a surgical technique including facelift incision and SMAS advancement. *J. Craniomaxillofac. Surg.*, 34 (1): 34, 2006.

- 13- Witt R.L., Weinstein G.S. and Rejto L.K.: Tympanomastoid suture and digastric muscle in cadaver and live parotidectomy. *Laryngoscope*, 115 (4): 574, 2005.
- 14- Gaillard C., Perie S., Susini B. and Guily J.L.: Facial nerve dysfunction after parotidectomy: The role of local factors. *Laryngoscope*, 115 (2): 287, 2005.
- 15- Jianjun Y., Tong T., Wenzhu S., Shanzhen S., Jianguo T., Fengcai W. and Xianliang C.: Use of a parotid fascia flap to prevent postoperative fistula. *Oral Surg. Oral Med. Oral Pathol. Oral Radiol. Endod*, 87 (6): 673, 1999.
- 16- Upile T., Jerjes W.K., Nouraei S.A.R., Grant W., Singh S., Sudhoff H. and Hopper C.: Further anatomical approaches to parotid surgery. *Eur. Arch. Otorhinolaryngol.*, 267: 793, 2010.
- 17- Nitzan D., Kronenberg J., Horowitz Z., Wolf M., Bedrin L., Chaushu G. and Talmi Y.P.: Quality of life following parotidectomy for malignant and benign disease. *Plast. Reconstr. Surg.*, 114 (5): 1060, 2004.
- 18- Guntinas-Lichius O., Gabriel B. and Klussmann J.P.: Risk of facial palsy and severe Frey's syndrome after conservative parotidectomy for benign disease: Analysis of 610 operations. *Acta. Otolaryngol.*, 126 (10): 1104, 2006.
- 19- Bremerich A., Eufinger H., Rustemeyer J. and Schaus M.: Frey-syndrome. *Oral and Maxillofac. Surg.*, 5: 33, 2001.
- 20- Zaoli G.: Le comblement des dépressions résiduelles après parotidectomie par un lambeau composé artériel sous-cutané. *Ann. Chir. Plast Esthet.* 34: 123, 1989.
- 21- Jost G., Guenon P. and Gentil S.: Parotidectomy: A plastic approach. *Aesthetic. Plast. Surg.*, 23: 1, 1999.
- 22- Gooden E.A., Gullane P.J., Irish J., Katz M. and Carroll C.: Role of the sternocleidomastoid muscle flap preventing Frey's syndrome and maintaining facial contour following superficial parotidectomy. *J. Otolaryngol.*, 30: 98, 2001.
- 23- Kerawala C.J., McAloney N. and Stassen L.F.: Prospective randomized trial of the benefits of a sternocleidomastoid flap after superficial parotidectomy. *Br. J. Oral Maxillofac. Surg.*, 40: 468, 2002.
- 24- Han S.Y., Song T., Wang Y.X. and Wang X.K.: Application the sternocleidomastoid muscle-great auricular nerve flap in radical parotidectomy. *Zhonghua Zheng Xing Wai Ke Za Zhi*, 20 (6): 425, 2004.
- 25- Asal K., Koybasioglu A., Inal E., Ural A., Uslu S.S., Ceylan A. and Ileri F.: Sternocleidomastoid muscle flap reconstruction during parotidectomy to prevent Frey's syndrome and facial contour deformity. *Ear Nose Throat J.*, 84 (3): 173, 2005.
- 26- Zumeng Y., Zhi G., Gang Z., Jianhua W. and Yinghui T.: Modified superficial parotidectomy: Preserving both the great auricular nerve and the parotid gland fascia. *Otolaryngol. Head Neck Surg.*, 135 (3): 458, 2006.
- 27- Giannone N. and Muzio L.L.: Extracapsular lumpectomy and SMAS flap for benign parotid tumours: An early outcome in a small number of cases on Frey's syndrome and facial nerve dysfunction. *J. Craniomaxillofac. Surg.*, 36 (4): 239, 2008.
- 28- Honig J.F.: Facelift approach with a hybrid SMAS rotation advancement flap in parotidectomy for prevention of scars and contour deficiency affecting the neck and sweat secretion of the cheek. *J. Craniofac. Surg.*, 15 (5): 797, 2004.
- 29- Angspatt A., Yangyuen T. and Jindarak S.: Chokrungravanont P., Siriwan P. The role of SMAS flap in preventing Frey's syndrome following standard superficial parotidectomy. *J. Med. Assoc. Thai.*, 87 (6): 624, 2004.
- 30- Zhao H.W., Li L.J., Han B., Liu H. and Pan J.: A retrospective study on the complications after modified parotidectomy in benign tumors of parotid gland. *Hua Xi Kou Qiang Yi Xue Za Zhi*, 23 (1): 53, 2005.
- 31- Cesteley L., Helman J., King S. and Van de Vyvere G.: Temporoparietal fascia flaps and superficial musculoaponeurotic system plication in parotid surgery reduces Frey's syndrome. *J. Oral Maxillofac. Surg.*, 60: 1284, 2002.