

Staged Division of Cross-Leg Flap to Enhance Flap Viability by Increasing its Contact with the Reconstructed Bed

KHALED S. ZAKARIA, M.D.; MOHAMMED FARAG, M.D.; AHMED ALI, M.D. and YEHYA M. ABDEL ROHMAN, M.D.

The Department of Plastic Surgery, Faculty of Medicine, Ain Shams University, Cairo, Egypt.

ABSTRACT

The covering of soft tissue defects of the lower leg and foot presents challenge for reconstructive surgeons, because of the paucity of local tissues especially in post-traumatic conditions. For this reason, several methods were used in reconstruction. In clinical practice, sometimes the surgeon becomes confronted with cases in which, the local anatomical conditions, are difficult and the free flaps cannot be used due to technical or resource problems. In such cases, one of the best surgical alternatives remains the cross-leg flap procedure. Yet, sometimes a technical problem emerges if the contact surface area of the cross leg flap and the recipient bed is small. This may result in partial or total flap loss after flap division. To overcome this problem, a new modification is introduced to increase the contact surface area between the cross leg flap and its recipient bed by staged division of the cross-leg flap. This article will describe the use of this technique in coverage of difficult leg and foot defects in 16 patients. The article will also elaborate the versatility of the technique in reconstruction of below knee amputation stumps with satisfactory aesthetic and functional results. We consider that this technique offers some advantages over the classical cross-leg flap.

INTRODUCTION

Soft-tissue defects of the lower third of the leg and foot is a major reconstructive challenge because of a paucity of local tissues that could be reliably used [1,2]. Since the original description of the cross-leg flap by Hamilton in 1854 [3] numerous refinements have been introduced to the technique [4,5]. It was considered for a long time to be the only option for covering defects of the distal third of the leg and foot [6]. With time, the cross-leg flap technique became a "lost art". It has been replaced by microsurgical composite-tissue transfer, which has evolved as the standard reconstructive procedure in such situations, with minimal morbidity and failure rates [7]. So the great enthusiasm generated microsurgical techniques made any talk about the cross-leg flap rather obsolete and did not allow the exploration of new concepts and applications. Free flaps, however, require special

skills and relatively expensive instrumentation not readily available in all reconstructive centres, particularly in under-privileged areas of the world. Moreover, in certain extreme conditions, free-tissue transfer is highly risky or even impossible to perform. In such eventualities, the cross-leg flap re-emerges as a likely option for reconstruction [8]. Disadvantages of the classic cross-leg technique include an unreliable random blood supply, a short and thick pedicle that greatly limits the arc of rotation, and the need for uncomfortable post-operative immobilization in an awkward posture [4,9]. Complications and failure to cover the wound are frequent [9,10].

The cross leg flap is safe and reliable in resurfacing of large defects of the lower limb and foot. [6]. Several modifications were introduced published to enhance vascularity and the versatility of cross leg flap as incorporating fascial extension in the flap [11] or muscle [12]. Other modifications included adapting the distally based sural fasciocutaneous flap as a cross-leg flap having the advantage of the comfortable leg positioning and the simplicity over the standard cross-leg flap [8]. Cross leg flaps based on the perforators of the posterior tibial artery were other recent modifications for the cross leg flaps [13].

Despite of all these options and modifications, the cross leg flap whether conventional or modified still faces some problems in practical application, especially if there is a small contact surface area between the flap and its underlying bed. The aim of this article is to introduce a modification in the use of the conventional cross leg flap by staged division of the flap after one week to enhance flap viability by increasing contact between the flap and the underlying reconstructed bed. The article will demonstrate the different applications of the

technique including its use in reconstruction of below knee amputation stumps.

PATIENTS AND METHODS

The study was conducted in the Department of Plastic Surgery of Ain Shams University Hospitals from January 2003 to December 2005 with follow-up of an average 9 months. It was carried on 16 patients with different skin defects along the leg and foot. Of these 16 patients there were 12 males and 4 females. The age ranged from 6 to 31 years. The causes of these defects were recent trauma except for one case the defect was unstable scar due to old trauma. The sites of these defects were in the lower third of leg (3 cases), lower 1/3 of the leg and ankle region (4 cases) combined middle and lower thirds (5 cases) below knee amputation stump (3 cases) and the heel area (one case) (Table 1).

Operative technique:

All cases were operated upon under general anesthesia at variable intervals according to the time of their presentation which ranged from few days up to three months. In cases presented with compound fractures, aggressive debridement of the wound was done with simultaneous removal of all non viable bones. External fixation was done and medial external fixation was replaced by lateral one by the aid of orthopedic surgeons. In one case presented with unstable scar, preoperative excision biopsy and histopathological examination was done to exclude any malignant change.

Operative technique:

Preoperative assessment of the patient was done. The expected defect site and size were determined and accurate design of the cross leg flap location and size was done, after putting the patient's legs in the optimum position for the flap to reach its future bed. Through a lateral approach and under pneumatic tourniquet using loupe magnification, the distal end of the flap is raised including about 1-2cm fascial extension. This extension was only included in the part of the flap that will have primary good contact with the reconstructed bed aiming to enhance flap neovascularisation (Fig. 1-A). Dissection then continues medially. The skin segment needed is divided proximally and distally and the short saphenous vein and the sural nerve are exposed and identified and then divided burying their cut ends under the proximal and distal leg skin. Careful haemostasis is done. Skin graft is applied to the cross leg flap donor with tie over.

The flap is then inset keeping the maximum contact between the flap and its bed. The fascial extension is tucked under the edge of the defect by transfixation sutures. The part of the flap that was not in contact with the defect is just left hanging or attached by loose stitches to the future bed to prevent it from being retracted or tubed upon itself (Fig. 1-B).

The first postoperative dressing is done after seven days under general anaesthesia. Curettage of the under surface of the hanging part of the cross leg flap is done. Then this portion is divided converting it to a random pattern flap with length to width ratio 1:1 (Fig. 1-C). The newly formed flap is then allowed to lie comfortably on the desired bed. In cases with below knee amputation the whole flap is turned up to cover the tip and the posterior surface of the stump (Fig. 1-D). The flap is then left for another two weeks then division of the remaining part of the flap is done.

RESULTS

The whole sixteen flaps survived completely without single flap loss (Figs. 2-3). In one patient persistent discharge occurred from underlying bone infection and partial disruption occurred. This was managed by flap elevation, further debridement of necrotic bone leaving bone defect about 5cm with application of illizarov fixator where segment transfer was done later.

Complete take of the skin grafts occurred in fifteen patients with complete healing of graft donors, except one patient had partial graft loss of the donor flap and needed another skin grafting session. All patients had stable wound coverage during the follow-up period without the need of secondary procedures, during the same follow-up period. No functional deficits were encountered and flap donor sites were aesthetically accepted.

Table (1): Location, etiology and number of defects.

Site of the defect	Etiology	No. of defects
Lower 1/3 of the leg	Trauma	3
Lower 1/3 of the leg and ankle region	Trauma	4
Combined middle & lower 1/3 of the leg	Trauma	5
Below knee amputation stump	Trauma	3
Heel	Unstable scar	1
Total		16

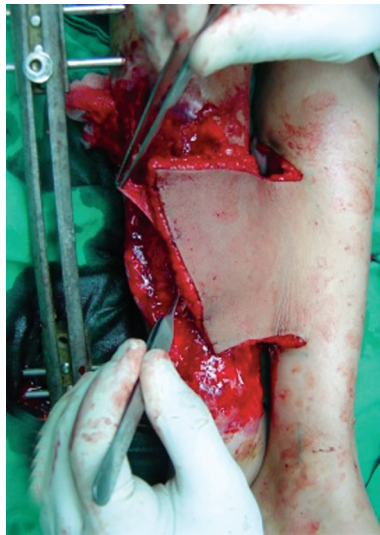


Fig. (1-A): Raised flap including [1cm] of the leg fascia in the part planned to have primary good contact with the reconstructed bed.

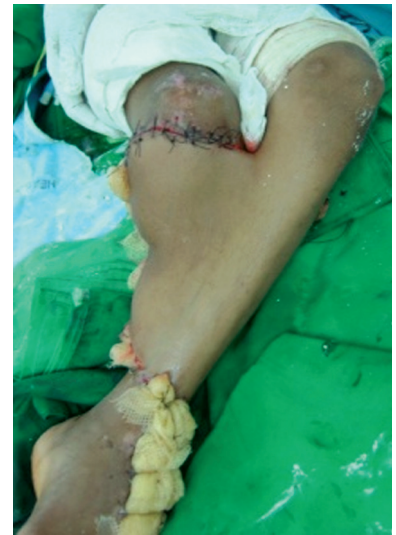

Fig. (1-B): In first stage distal part of the flap is spread and left attached distally to prevent flap retraction.

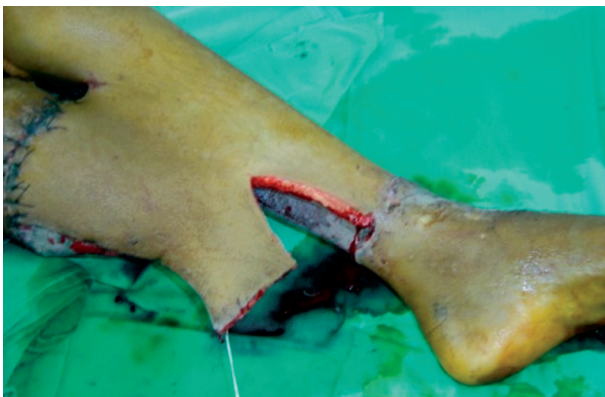

Fig. (1-C): Staged division of flap after 1 week, creating a random pattern flaps (width to length ratio 1:1).

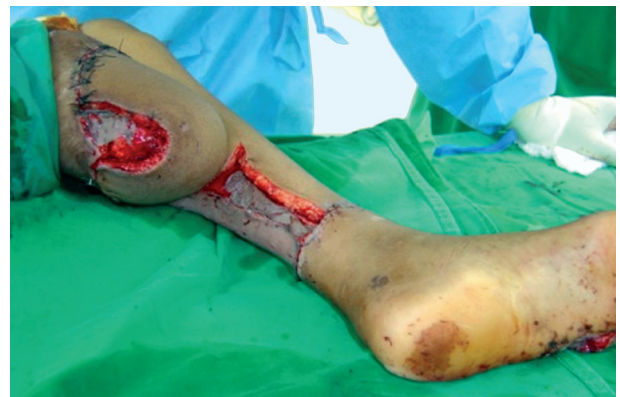

Fig. (1-D): Flap covering anterior, posterior surface and the tip of below knee amputation stump.

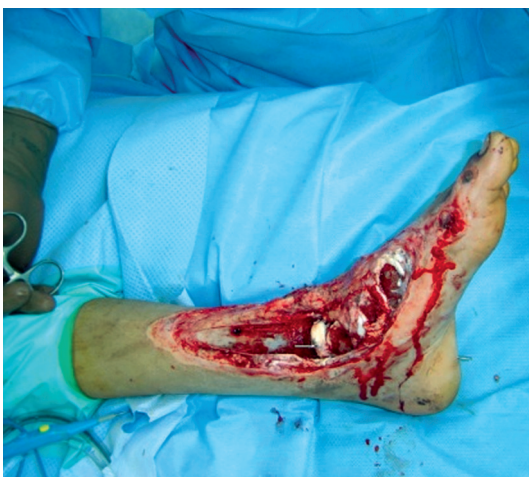

Fig. (2-A): Post traumatic exposed lower 1/3 leg, ankle and tarsal bones, notice an eaten part of the articular cartilage of ankle joint with tip of K-wire fixation.

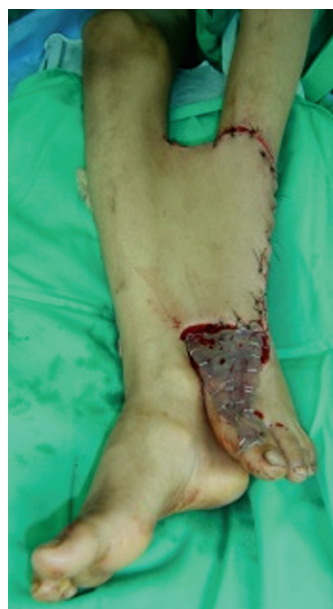

Fig. (2-B): Lower half of the flap attached to the distal point of the defect to prevent its retraction, the medial part of the distal half of the flap is left hanging with no contact.

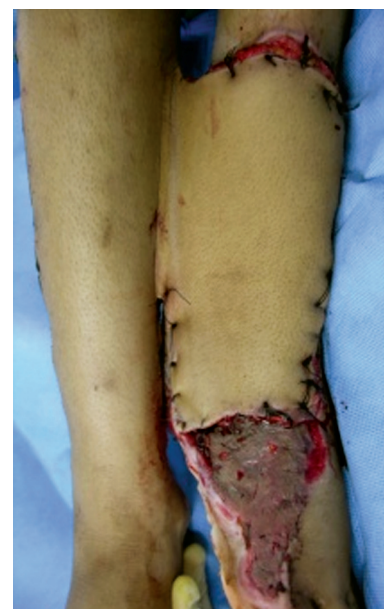

Fig. (2-C): Cross leg flap with staged division after 1 week. The hanging part of the flap is now in good contact with its bed.

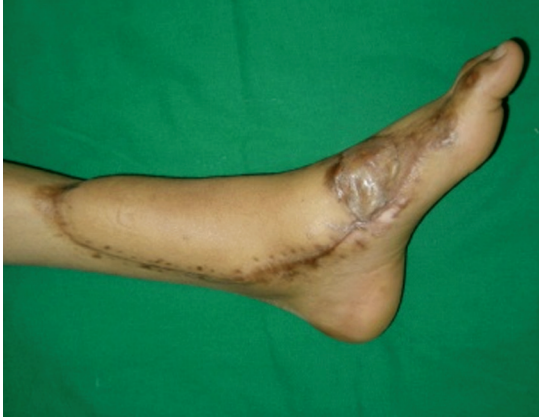

Fig. (2-D): Late postoperative with good cover of the lower third leg and ankle joint (lateral view).

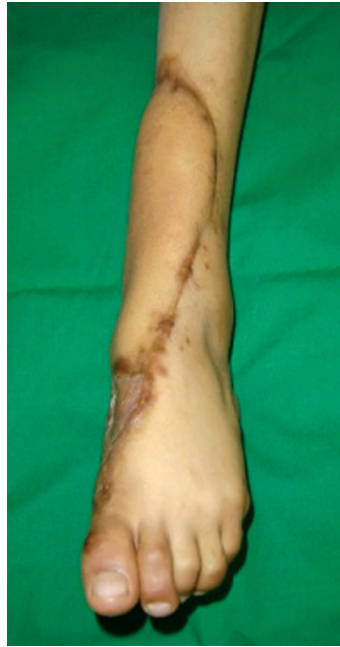

Fig. (2-E): Postoperative with good cover of the lower third leg and ankle joint (P-A view).

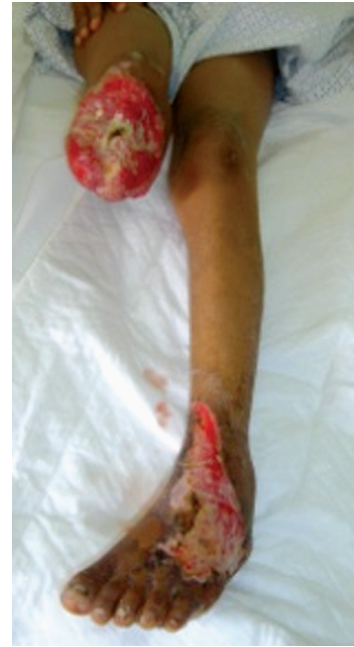

Fig. (3-A): Exposed below knee amputation stump of right leg.

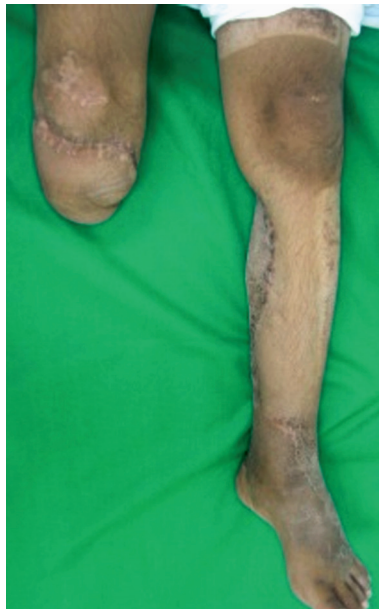

Fig. (3-B): Below knee amputation stump after reconstruction by staged division of cross leg flap.

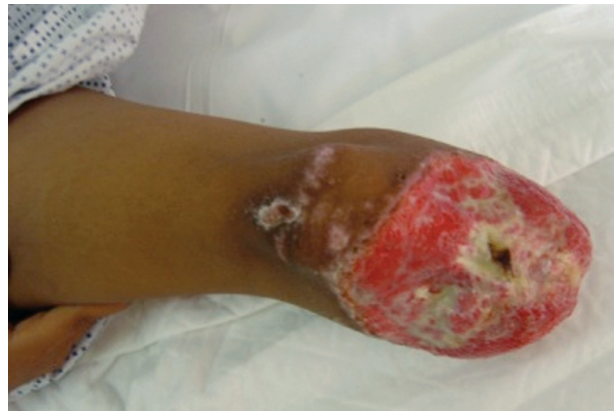

Fig. (3-C): Preoperative lateral view of the amputation stump.

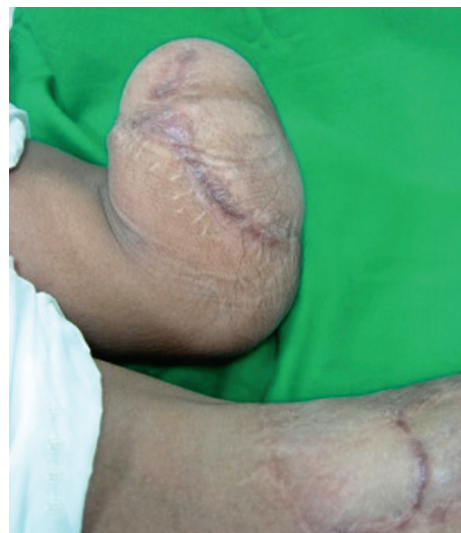
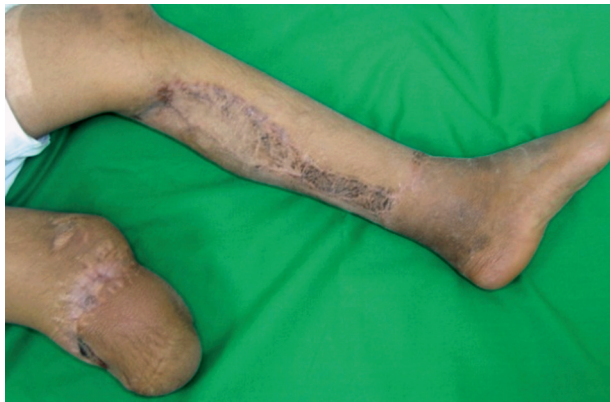
Fig. (3-D,E): Postoperative good cover of the amputation stump.

DISCUSSION

For a long period of time cross-leg flaps were the only reconstructive option for the difficult areas of the distal leg and foot, with high success rates and minimal morbidity in expert hands [6]. Cross leg flaps, however, are highly technique dependent, which explains the variable success rates described in the literature. These flaps were described as being handicapped by the inherent problems of positioning and immobilization [14], because of their short, thick and inextensible pedicles, awkward postures and bulky external fixation devices are invariably needed [15,16].

In comparison to one-stage reconstruction using free flaps [7,9,17,18] cross-leg flaps require at least two surgical stages. Moreover, they do not augment the blood supply of the recipient defect. Despite all the technical improvements and the experience gained in clinical practice over the last three decades, micro-anastomotic thrombosis with incidence of flap failure remains a source of frustration to most microsurgeons [16]. Some conditions carry higher risks for failure, such as traumatic defects in the sub-acute phase, lack of direct pulsatile inflow and lack of suitable vessels in the recipient bed, necessitating the use of inter-positional vein grafts [9,17,18,20]. To minimize free-flap failure, several guidelines, techniques and modifications have been proposed [9,17,18].

Despite the widespread use of microsurgery in management of lower leg injuries, still the cross leg flaps have their role. However they have the disadvantage of prolonged immobilization and incidence of partial or total flap loss. Several modifications were published to overcome this incidence of failure by delaying the division of the flap or incorporating fascial extension in the flap.

In this paper we described a new modification to enhance the vascularity of the flap and to minimize the incidence of partial or total flap loss. Staged division of the flap was done to enhance its contact with the receiving bed. This allowed us to have good success of all the flaps. This modification is especially indicated in large leg defects, particularly if they are including the distal third of the leg and foot in which the full contact between the flap and the bed is difficult to be achieved. This is also applicable in cases of amputation stumps where the geometry of the defect does not also allow complete contact of the flap with its bed.

It is safe and reliable procedure to cover large defects in the lower limb. At the same time this

technique avoided exposing the patients to a lengthy microsurgical procedure with all the hazards of this operation. Dividing the flap after one week did not have any drastic effect on the viability of the divided part of the flap because it was designed to respect all the rules of the random pattern flap with width to length ratio not exceeding 1:1.

Conclusion:

The cross-leg flap may prove to be a highly valuable reconstructive option in situations in which microsurgical free-tissue transfer is not possible. This may be due to problems related to the patient general conditions or lack of microsurgical facilities. The staged division of cross leg flap allows safe reconstruction of difficult defects that were partially not amenable to reconstruction by the conventional cross leg flap. It is also beneficial in cases of exposed below knee amputation stumps. The only disadvantage of the technique is adding another stage to the procedure of conventional cross leg flap.

REFERENCES

- 1- Musharafieh R., Atiyeh B., Macari G. and Haidar R.: Radial forearm fasciocutaneous free-tissue transfer in ankle and foot reconstruction: Review of 17 cases. *J. Reconstr. Microsurg.*, 17: 147, 2001.
- 2- Fracalvieri M., Verna G., Dolcet M., et al.: The distally based superficial sural flap: Our experience in reconstructing the lower leg and foot. *Ann. Plast. Surg.*, 45: 132, 2000.
- 3- Long C.D., Granick M.S. and Solomon M.P.: The cross-leg flap revisited. *Ann. Plast. Surg.*, 30: 560, 1993.
- 4- Stark R.B.: The cross-leg flap procedure. *Plast. Reconstr. Surg.*, 9: 173, 1952.
- 5- Pollock W.J. and Parkes J.C., II.: Technical details in the management of cross-leg flaps. *J. Trauma*, 10: 663, 1970.
- 6- Morris A.M. and Buchan A.C.: The place of the cross leg flap in reconstructive surgery of the lower leg and foot: A review of 165 cases. *Br. J. Plast. Surg.*, 31: 138, 1978.
- 7- Atiyeh B.S.: Microsurgical composite tissue transfer: An expanding horizon in reconstructive surgery. *J. Med. Liban.*, 42: 112, 1994.
- 8- Atiyeh B.S., Al-Amm C. A., El-Musa K.A., Sawwaf A.W. and Musharafieh R.S.: Distally Based Sural Fasciocutaneous Cross-Leg Flap: A New Application of an Old Procedure. *Plast. Reconstr. Surg.*, 113 (2): 1470-4, 2004.
- 9- Atiyeh B.S., Khalil I.M., Hussein M.K., et al.: Temporary arterio-venous fistula and microsurgical free tissue transfer for reconstruction of complex defects. *Plast. Reconstr. Surg.*, 108: 485, 2001.
- 10- Cannon B., Constable J.D., Furlow L.T., et al.: Reconstructive surgery of the lower extremity. In J.M. Converse (Ed.), *Reconstructive Plastic Surgery*. Philadelphia: Saunders, 1977.

- 11- Barclay T.L., Sharpe D.T. and Chisholm E.M.: Cross leg fasciocutaneous flaps. *Plast. Reconstr. Surg.*, 72: 843, 1983.
- 12- Orticochia M.: Immediate (undelayed) musculocutaneous island cross leg flaps. *Br. J. Plast. Surg.*, 31: 205, 1978.
- 13- Georgescu A.V., Irina C. and Ileana M.: Cross-leg tibial posterior perforator flap. *Microsurgery*, 27 (5): 380-383, 2007.
- 14- Dawson R.L.: Complications of the cross-leg flap operation. *Proc. R. Soc. Med.*, 65: 626, 1972.
- 15- Arnander C., Eriksson G., Korlof B. and Nylen B.: Transfixation in cross-leg procedures using Hoffman's instruments: Report of forty-two cases. *Scand. J. Plast. Reconstr. Surg.*, 9: 68, 1975.
- 16- Constant E. and Grabb W.: Steinmann pin fixation of tibia for cross-leg flap. *Plast. Reconstr. Surg.*, 41: 179, 1968.
- 17- Atiyeh B.S., Sfeir R.E., Hussein M.M. and Hussami T.: Preliminary arterio-venous fistula for free-flap reconstruction in the diabetic foot. *Plast. Reconstr. Surg.*, 95: 1062, 1995.
- 18- Atiyeh B.S. and Musharafieh R.S.: Staged arteriovenous fistula and free flap transfer (Letter). *Ann. Plast. Surg.* 38: 193, 1997.
- 19- Scotland M.A. and Kerrigan C.L.: The role of platelet activating factor in musculocutaneous flap perfusion injury. *Plast. Reconstr. Surg.*, 99: 1989, 1997.
- 20- Godina M.: Early microsurgical reconstruction of complex trauma of the extremities. *Plast. Reconstr. Surg.*, 78: 285, 1986.