

New Geometric Design for True Circumferential Lengthening of the Penis

KHALED SALEM, M.D. and WALID MOSTAFA, M.D.

The Departments of Urology and Plastic Surgery Unit, Faculty of Medicine, Tanta University.

ABSTRACT

Introduction: Patients with buried penis, micropenis or functional penile dysmorphism seek for penile augmentation surgery. The commonly used methods for penile lengthening include inverse V-Y plasty of the dorsal skin, Z plasty of the ventral skin, suprapubic lipectomy and suspensory ligament release. These methods work on the penis from one side or another without calculation or prediction of the actual gained length.

Patients and Methods: Between January 2000 and Mars 2007, a group of 53 patients complaining of short penis were managed by our new technique of penile lengthening. The new method is based on a geometric design that considers the penis as a cylinder required to be lengthened circumferentially. This design helps to gain the calculated desired length actually and truly. The suspensory ligament penis is released and the skin around the base of the penis is tailored circumferentially to fit around the base of the shaft after its lengthening. Results were assessed based on both patient satisfaction and the actual increase in penile length as determined by measuring the stretched penile length during flaccidity.

Results: A range of 2.5 to 4cm extra length of penile shaft was achieved with our new technique. Out of 53 patients, 67.9% 36 patients were satisfied with the result of the operation.

Conclusion: Penile lengthening should be based on a clear design and should involve the penis circumferentially to obtain true and satisfactory results.

INTRODUCTION

Patients with buried penis, micropenis or functional penile dysmorphism seek for penile augmentation surgery. In 1966 Masters and Johnson [1] wrote that, historically, the size of the male organ, both flaccid and erect, has been equated by widely diverse cultures to reflect the sexual prowess of the individual male. Even among the affluent and well educated, penis size is often equated to dominance, power and virility. Since no man whatever the level of his education would choose to have a smaller penis, more and more men are seeking surgery for a larger penis.

While penile lengthening was first described in the early 1970s as a reconstructive surgical

technique for congenital and acquired shortening of the penis [2,3], the technique gained a widespread and debatable popularity after a publication of the Chinese surgeon Long [4]. In 1994, the American Academy of Phalloplasty Surgeons was formed and its membership continues to grow as surgeons world-wide become interested in enhancement phalloplasty [5]. While controversy still rages over the utilization of penile augmentation procedures for cosmetic purposes, there has been increasing research into new procedures that can significantly and safely provide size changes that are real rather than apparent. In this work we describe our technique for penile lengthening by using a new geometric design that works on the penis circumferentially and report our experience and results using this method to obtain genuine increase in penile length.

PATIENTS AND METHODS

Selection of patients:

Between January 2000 and Mars 2007, a group of 53 patients complaining of short penis were managed by our new technique of penile lengthening. Selection of patients was based on a flaccid stretched penile length of 10cm or less.

Preoperative assessments:

A detailed medical and sexual history was obtained. A physical examination included measurement of the flaccid stretched penis (along the dorsal surface) from its base at the pubic penile junction to the tip of the glans under maximal stretch of the penis. This measurement during flaccidity was used to assess the preoperative and postoperative penile length because repeated intracavernosal injection of vasoactive drugs was not practical for just measuring penile length. In addition, the flaccid stretched penis has been demonstrated to be an accurate reflection of the penile length during erection [6].

The normogram of penile length [7] was shown to the patient and his concerns and expectations about the lengthening surgery were discussed.

Operative technique:

Under spinal anesthesia, the outlines of the skin incisions were marked. The possible lengthening of the penis was estimated (Fig. 1). A circle was drawn around the penis that should provide the desired length (Fig. 2). The difference between the circumference of the drawn circle and that of the penile base was calculated (Fig. 3) and divided by 4 to obtain 4 equal lengths. These lengths were marked on the circle at 2 perpendicular diameters. (Fig. 4). Four diamond shapes were drawn on the circle so that the proposed 4 equal lengths will constitute the short diameter of the diamond (Figs. 5,7).

The skin of the diamonds was excised and suprapubic lipectomy was done (in obese patient) through the proximal wounds. The subcutaneous tissue was split at the base of the penis to expose the fundiform and suspensory ligaments. Traction on the penis and blunt dissection down to the symphysis pubis delineated the restricting ligaments that were cut transversely close to the pubic bone. To prevent injury of the neuro-vascular bundle of the penis, the penis was kept stretched and both dissection and release of ligaments were limited to the inferior border of the pubis (Fig. 8).

At the end of the procedure, the created dead space between the corpora cavernosa and pubis was filled with a fat flap after meticulous hemostasis to prevent hematoma formation. This flap was drawn from the suprapubic fat. However, in thin patients the proximal skin diamond was not excised but it was de-epithelialized with scalpel and used as a dermal fat flap to fill the dead space. Then, the wound sides were approximated with polyglycolic acid sutures to close the subpubic dead space. Outward pulling of the penis closed the diamond wounds as 4 straight lines with nice fitting of the suprapubic and scrotal skin around the lengthened penis (Fig. 6). Skin was closed meticulously with 4/0 Polypropylene suture. No wound drain was applied (Figs. 9B,10B).

RESULTS

Preoperative flaccid stretched penile lengths (Figs. 9A,11A,12A). Had a range of 6 to 10cm with a mean value of 7.3cm (± 1.2). Postoperative flaccid stretched penile lengths (Figs. 9B,11B,12B) had a range of 9.5 to 13cm with a mean value of 10.4cm (± 0.7). With our new lengthening technique, the achieved extra length of the penis had a range of 2.5 to 4cm with a mean value of 3.1cm (± 0.6).

No major complications occurred during surgery such as severe bleeding or injury of the urethral or neurovascular bundle. Postoperative complications were minors and managed conservatively. These included penile edema in 6 patients (11%), transient (<one months) pain on erection in 4 patients (7.5%), skin ecchymoses in another 4 patients (7.5%) and superficial wound infection in two cases (3.7%).

Out of 53 patients, 36 patients (67.9%) were satisfied with the outcome of surgery, eleven patients (20.8%) felt no difference and the remaining six (11.3%) were not satisfied.

DISCUSSION

New developments in penile enlargement surgery have generated great interest and several techniques are evolved for penile lengthening [8,9,10]. Division of the penile suspensory ligament with or without suprapubic lipectomy and advancement of lower abdominal skin onto the penis, constitute the most popular method for penile lengthening. However, this is usually associated with three well known drawbacks [11].

The first one is reattachment of the suspensory ligament with postoperative loss of the gained length or even shortening of the penis [11-14]. In our technique, this problem was avoided by filling the dead space (created after release of the suspensory ligament) between the pubis and corpora cavernosa with fat or dermal fat flap. Various materials and tissues are used to fill this space. Synthetic materials such as polytetra-fluoroethylene (Gore-tex) [9] and solid silicone implants [13] are used but they are a potential source of infection. The used tissues included rectus fascia as a flap or fat graft obtained by liposuction and dermal-fat graft [12]. However, rectus fascia is not bulky enough to adequately fill the dead space while fat and dermal-fat grafts carry the risk that they may not take or survive leading to infection and wound disruption.

The second problem is genital disfigurement (Fig. 10A) due to advancement of the lower abdominal skin onto the penis from one aspect only. It usually results in 'scrotalization' of the penis due to advancement of hair-bearing skin onto the dorsal aspect of the penis with formation of dog-ears on the scrotal margins [11,15]. In our technique, no skin advancement was used but the lower abdominal and scrotal skin was tailored to fit circumferentially around the extruded part of the penis (Fig. 10B,C).

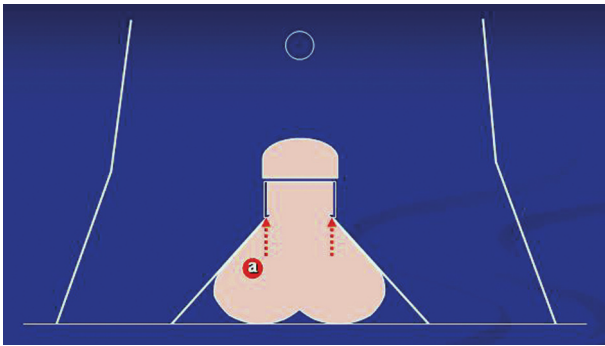


Fig. (1): Estimate the proposed lengthening of the penis (a).

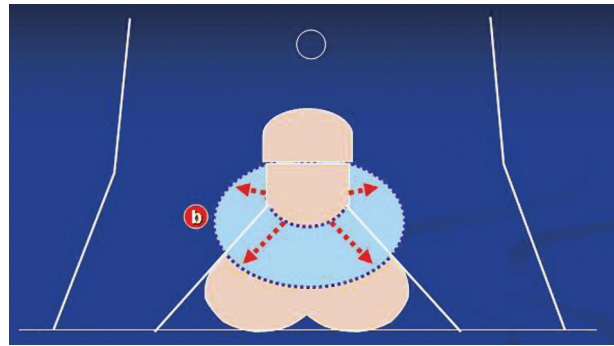


Fig. (2): Draw a circle around the penis that should provide the calculated length (b).

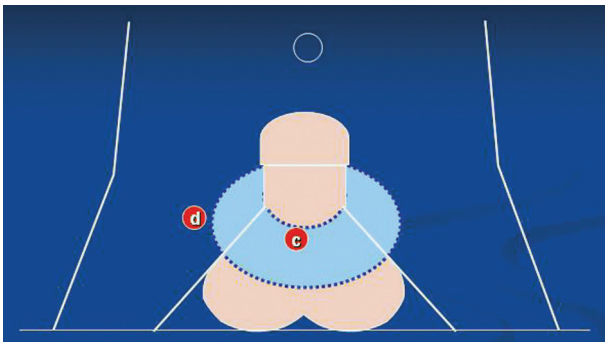


Fig. (3): Calculate the difference between the circumference of the base of the penis (c) and the circumference of the circle (d).

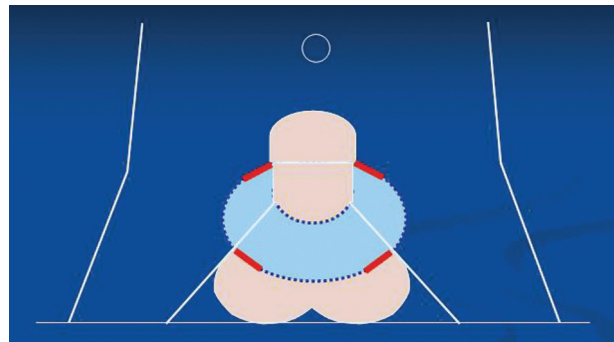


Fig. (4): Divide the difference by 4 to obtain 4 equal lengths. Mark these 4 equal lengths on the circle at 2 perpendicular diameters.

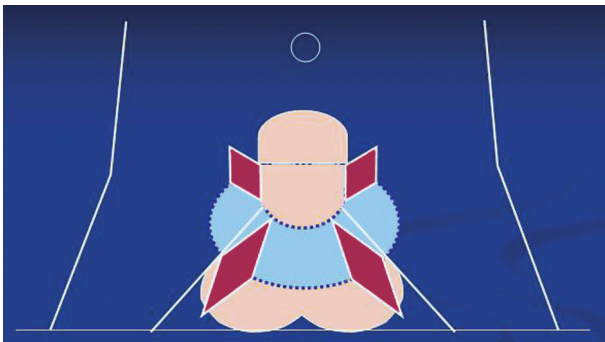


Fig. (5): Draw 4 diamond shapes on the circle so that the proposed 4 equal lengths will constitute the short diameter of the diamond. Excise the skin of the diamonds.

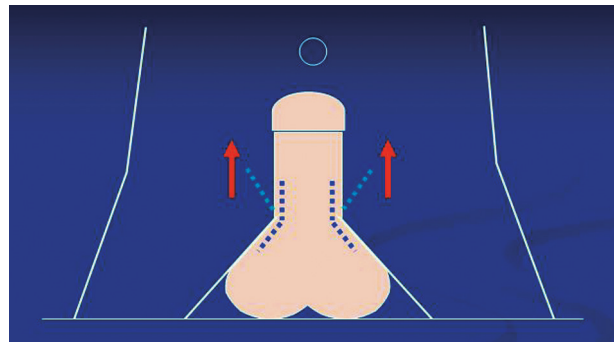


Fig. (6): Pull the penis outwards while closing the diamond shapes as 4 straight lines. The suprapubic and scrotal skin will fit nicely around the lengthened penis.

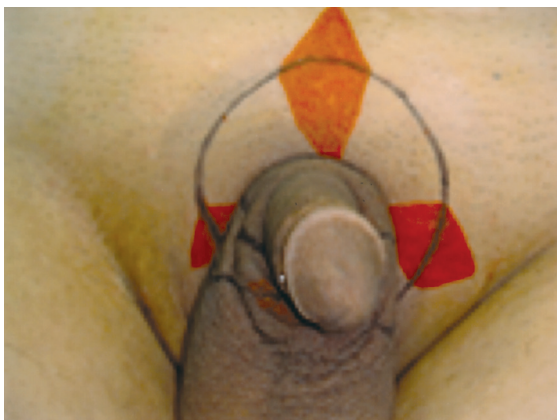

Fig. (7): Four diamond shapes were drawn on the circle.

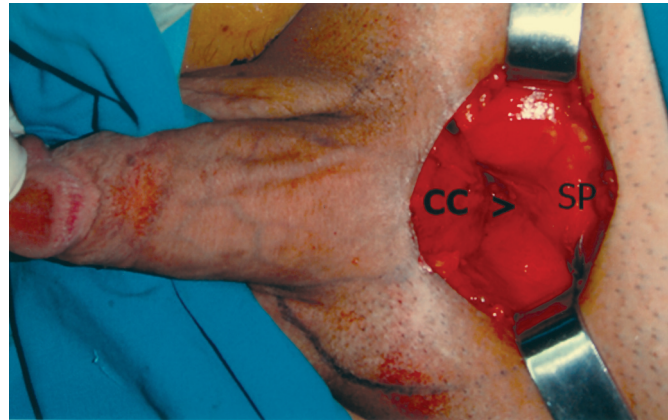


Fig. (8): Ligaments were cut transversely close to the pubic bone. (CC: Corpora Cavernosa-SP: Symphysis Pubis).

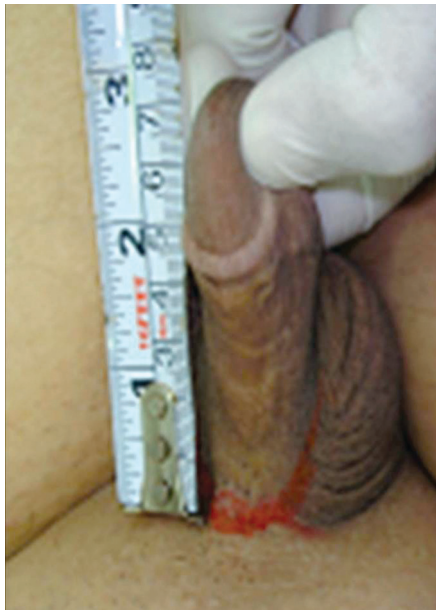

Fig. (9-A): Preoperative: Flaccid stretched penile length of 7cm.

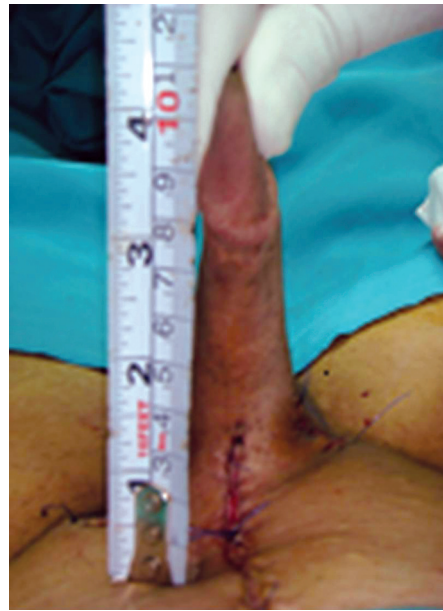

Fig. (9-B): Postoperative: Flaccid stretched penile length of 11cm.

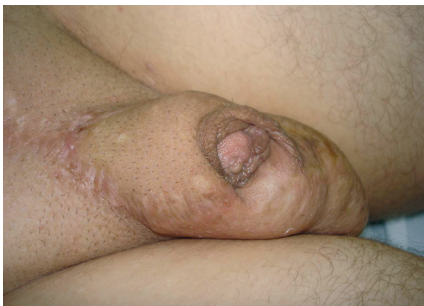
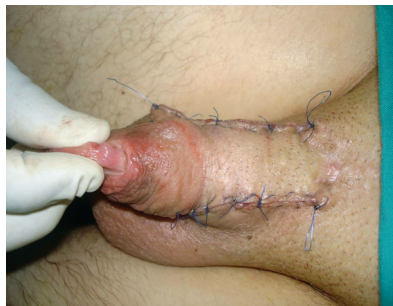
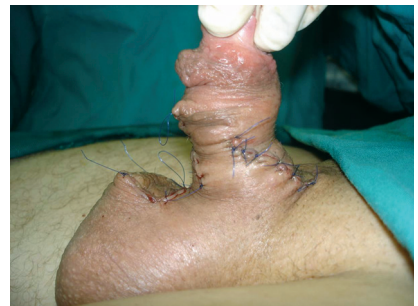Fig. (10-A): Preoperative: With previous V-Yplasty done elsewhere.



(B)



(C)

Fig. (10-B,C): Postoperative: Correction with our technique for circumferential lengthening of the penis.

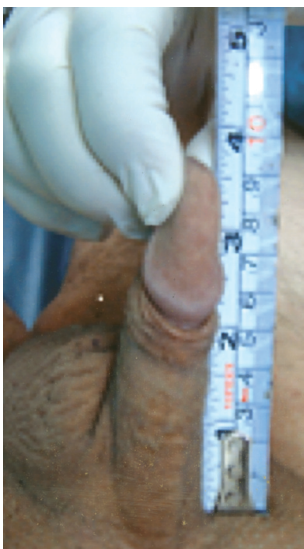

Fig. (11-A): Preoperative: Flaccid stretched penile length of 9cm.

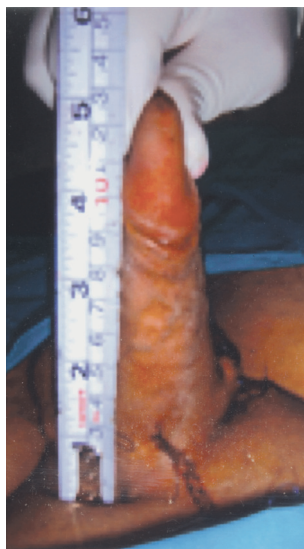

Fig. (11-B): Postoperative: Flaccid stretched penile length of 13cm.

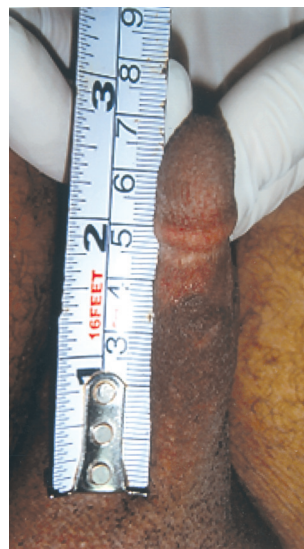

Fig. (12-A): Preoperative: Flaccid stretched penile length of 7cm.

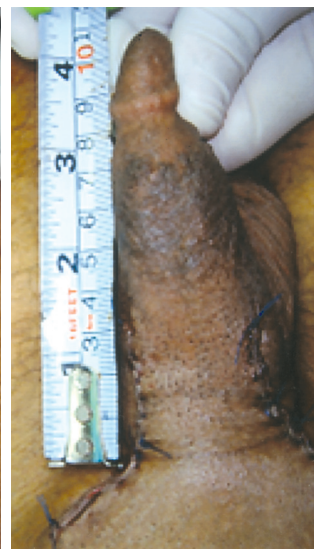

Fig. (12-B): Preoperative: Flaccid stretched penile length of 11cm.

The third problem is wound disruption with or without necrosis of skin flap as a result of wound closure under tension [9,11]. In our technique, skin tailoring resulted in minimal if any tension at wound closure because no axial (along the long axis of the penis) skin advancement was needed and skin on the scrotal aspect of the penis is pliable. On the abdominal aspect, skin excision for tailoring was limited and suprapubic lipectomy added more laxity to the abdominal skin.

Currently, as the media expose an exaggerated male figures it creates interest in phallic enlargement. Over the last years more and more people are asking for penile lengthening and augmentation surgery although its results are questionable [14,16,17]. Austoni et al. [18] reported a mean increase in erect penile length of 1.6cm, while, Spyropoulos et al. [17] and Li, et al. [13] achieved a significant increase in flaccid stretched penile length by 1.6cm and 1.3±0.9cm respectively. The opinion of Spyropoulos et al is that the technique of ligamentolysis and pubic skin advancement achieves an apparent and not real lengthening since penile structures remain unchanged [17]. Christiansen [19] reported that the penis is indeed advanced further out of the body, but the scrotum follows inevitably the penis. Thus, the penis might seem longer in a front view, but could look rather strange in a side view.

However, with our new technique an actual increase in penile length was achieved with a mean value of 3.1cm. The idea behind this technique is to work on the penis as a whole by extruding the hidden part of the base of the penis as much as possible and maintaining this extrusion by a bulky fat or dermal-fat flap fixed behind the extruded part. Tailoring of the skin around this part helped to obtain a good image and to keep the gain in length. Perovic et al. [20] using the penile disassembly technique achieved a mean penile length gain of 3.068 while, Randone et al. [21] obtained length gain from 2.5 to 3cm in the erect state by using the dermo-fat free graft method. These techniques work on the penis as a whole but rather aggressive and potentially hazardous.

Despite of the achieved extra length of 3.1cm (mean value) with minimal complications in our study, proportions of the patients (17 patients) had no difference (20.8%) or were not satisfied (11.3%) with the outcome of the surgery. The majority of these patients (15 patients out of 17) had preoperative penile lengths in the range of 9 to 10cm. Although these patients were informed preoperatively that they are normal and the penile lengths

normogram 7 was shown to them, they insisted on the surgical interference because they did not accept to be on the lower limit of norm.

This type of patients, who have a subjective altered body perception, rather than an objective clinical assessment that their penis is small, are described to have penile dysmorphophobia [22]. In body dysmorphic disorder, patients present with persistent preoccupation of an imagined defect in their physical appearance that causes marked lowering of their self-esteem with clinically significant distress or impairment in their social life [13]. Clearly, surgery is not a cure for all patients with penile dysmorphic disorder because some patients often have unrealistic expectations and any length gain would not be enough in the patient's view.

In our study, the highest satisfaction rate was achieved in patients with a preoperative stretched penile length of 9cm or less. This may be explained by observing that the mean postoperative gain in length was 3.1cm which represent an increase in penile length of these patients of more than one third of its original preoperative length. Accordingly, the figure of 9cm or less can be suggested as one of the patient's selection criteria for penile lengthening surgery.

Conclusion:

Penile lengthening should be based on a clear design and should involve the penis circumferentially to obtain true and satisfactory results. The idea behind our technique is to extrude the hidden infrapubic penis as much as possible and tailoring the skin circumferentially around the extruded part to obtain a good image and to keep the gain in length. Careful patient selection with honest description of the real expected results can minimize the rate of dissatisfaction.

REFERENCES

- 1- Masters W.H. and Johnson V.E.: Human Sexual Response. Toronto; New York: Bantam Books, 1966.
- 2- Kelley J.H. and Eraklis A.J.: A procedure for lengthening the phallus in boys with extrophy of the bladder, J. Pediatr. Surg., 6: 645, 1971.
- 3- Hinman Jr.: Microphallus: Characteristics and choice of treatment from a study of 20 cases, J. Urol., 107: 499, 1972.
- 4- Long D.C.: Elongation of the penis. Chinese J. Plast. Surg. Burns, 6: 17, 1990.
- 5- Burman S.O.: Enhancement phalloplasty: A brief history and state of the art: ISIR-Newsbulletin issue 4 September, p12, 2000.
- 6- Wessells H., Lue T.F. and McAninch J.W.: Penile length

- in the flaccid and erect states: Guidelines for penile augmentation. *J. Urol.*, 156: 995, 1996.
- 7- Schonfeld W.A. and Beebe G.W.: Normal growth and variation in the male genitalia from birth to maturity. *J. Urol.*, 48: 759, 1942.
 - 8- Roos H. and Lissos I.: Penis lengthening. *International Journal of Aesthetic and Restorative Surgery*, 2: 89, 1994.
 - 9- Alter G.J.: Augmentation phalloplasty. *Urol. Clin. North Am.*, 22: 887, 1995.
 - 10- Perovic S.V., Djordjevic M.L.J. and Djakovic N.G.: Real penile enlargement. *Br. J. Urol.*, 80 (Suppl 2): 308, 1997.
 - 11- Wessells H., Lue T.F. and McAninch J.W.: Complications of penile lengthening and augmentation seen at one referral center. *J. Urol.*, 155: 1617-20, 1996.
 - 12- Alter J.G.: Penile enlargement surgery, *Tech. Urol.*, 4 (2): 70, 1998.
 - 13- Li C.-Y., Kayes O., Kell P.D., Christopher N., Minhas S. and Ralph D.J.: Penile suspensory ligament division for penile augmentation: Indications and results, *Eur. Urol.*, 49: 729, 2006.
 - 14- Vardi Y.: Is Penile Enlargement an Ethical Procedure for Patients with a Normal-Sized Penis? *Eur. Urol.*, 49: 609, 2006.
 - 15- Alter G.J.: Reconstruction of deformities resulting from penile enlargement surgery, *J. Urol.*, 158: 2153, 1997.
 - 16- Perovic S.V. and Djordjevic M.L.J.: Penile lengthening, *Br. J. Urol. International*, 86: 1028, 2000.
 - 17- Spyropoulos E., Christoforidis C., Borousas D., Mavrikos S., Bourounis M. and Athanasiadis S.: Augmentation phalloplasty surgery for penile dysmorphophobia in young adults: Considerations and regarding patients selection, outcome evaluation and techniques applied, *Eur. Urol.*, 48: 121, 2005.
 - 18- Austoni E., Guarneri A. and Cazzaniga A: A new technique for augmentation phalloplasty: Albugineal surgery with bilateral saphenous grafts-Three years of experience, *Eur. Urol.*, 42: pp. 245-253, 2002.
 - 19- Christiansen E.: Some qualified information from an informed adult during the teen years could spare a lot of young men from later tragedies. *ISIR-Newsbulletin* issue 4 September, p18, 2000.
 - 20- Perovic S.V., Djordjevic M.L.J. and Djakovic N.G.: Penile lengthening: Myth or reality. *Eur. Urol.*, 33 (Suppl 1): 153, 1998.
 - 21- D. Randone, E. Giargia and D. Neira: Augmentation phalloplasty according to the G. Tritto technique, *Arch. Ital. Urol. Androl.*, 70 (5): 235, 1998.
 - 22- N. Mondaini, R. Ponchiatti, P. Gontero, et al.: Penile length is normal in most men seeking penile lengthening procedures, *Int. J. Impot. Res.*, 14: 283, 2002.