

Urethral Replacement with Vein Graft for Complicated Hypospadias Cripples

TAREK S. KESHK, M.D.*; WAEL M.R. SAKR, M.D.** and WAEL S. ABD EL NASER, M.D.***

The Department of Plastic Suregry, Menoufyia, Bani Suef** and Cairo*** Universities.*

ABSTRACT

Background: Repair of severe of hypospadias in one stage is among the most difficult challenges, a reconstructive surgeon may face. Ideally, the tissue for urethroplasty should be abundant to allow for a long urethra in proximal hypospadias, should be elastic to allow erection without curvature and it is better to be pre-tubularized to eliminate the need for a longitudinal suture line that may be a site for fistula formation and repair dehiscence.

A cylindrical vein graft may provide an alternative to the currently utilized tissues. Aim of this study is to evaluate the use of a vein graft as a urethral substitution for complex type of hypospadias.

Patients and Methods: Eight patients presented with complex type of hypospadias, 5 penoscrotal cases and 3 recurrent posterior-penile cases underwent a vein graft as a urethral substitution.

Results: The neo-urethra survived adequately in 5 cases. Meatal stenosis occurred in 1 case and repeated dilatation was required. Fistula occurred in 2 cases.

Conclusion: Substituting the urethra with a vein graft may provide a reliable and practical alternative to the current techniques. The saphenous vein graft is of sufficient length to serve the most ambitious urethroplasty and is of suitable caliber for an adequate urethra. The sufficient length and the inherent elasticity of the vein prevent the erection and curvature problems after urethroplasty. The multilayer structure of a vein provides a sturdy graft that may be less prone to ballooning. Being it is pretubularized, this eliminates the need for the longitudinal suture line thus decreasing the incidence of fistula formation.

Operative time is considerably less because the suture lines are minimized to those of the urethra-to vein proximally and the vein-to-skin distally. Also harvesting the saphenous vein is easy and fast.

INTRODUCTION

Hypospadias is a common anomaly occurring in 0.3-0.5% of viable newborn males. It is a developmental anomaly of unknown cause, although the high proportion of affected family members suggests genetic predisposition at least in some

instances. Hypospadias can be viewed as an arrest in the normal development of the penis [8]. It is usually an isolated anomaly, but there is a family incidence of 12-14% in first degree relatives [2]. It causes great concern because of the aesthetic deformity and because both parents and the patient profess insecurity about the sexual potential of the child [4]. From a physiological point of view repairs that result in the permanent orifice being at the corona are satisfactory; from a cosmetic point of view such repairs are not nearly as normal in appearance as those in which the meatus is centered on the tip of the glans [12]. Most hypospadias cases (90%) are distal, with the urethral meatus ending in the distal shaft or glans of the penis, only 10% of all hypospadias cases are in the mid-shaft or proximal in the scrotum or perineum.

Separation anxiety is usually at its peak in infants at about 18-30 months of age. However, it is probably best to perform elective hypospadias repair at 1 yr to 18 months of age if the penis is of adequate size. Stimulation with testosterone may be helpful for patients with small penises [6].

A wide variety of techniques have been proposed for hypospadias repair. Urethroplasty may be performed using local or distant tissues.

Hypospadias was successfully repaired in 1874 by Anger and Mettauer. This was followed by Thiersch "offset flap" and Duplay's operation which came into general use after 1880. These operations are mainly of historical interest now but since that time, at least 200 distinct techniques of hypospadias repair have been described. Repair of hypospadias in one stage is among the most difficult challenges, a reconstructive surgeon may face.

Most procedures in the past were done on several stages, each of which had its own complication

risks. Cecil during the mid 1940s introduced a three-stage repair for complicated hypospadias cripples [1,4].

In 1959, Horton and Devine presented a movie on their suggested technique for one-stage hypospadias repair horton, 1959. Devine has confirmed that one stage repairs are reliable and that chordee of hypospadias does not recur [4].

Complication of hypospadias repair can be divided into two groups: Those that occur immediately after the surgery and those that occur late. Of those that occur early, bladder spasm, infection, wound dehiscence and hematoma. Late complications include fistula, diverticulum, strictures, meatal stenosis and hair growth in the urethra [5].

There are many patients who have had prior unsuccessful hypospadias repairs. Preputial grafts or flaps are not an option.

Unfortunately, the limited availability of local tissues for re-do surgery forces the surgeon to search for alternatives for these hypospadias cripples. The extra-genital tissues are particularly needed in complex cases such as a circumcised patient, paucity of suitable shaft skin and a long defect.

Distant tissues include buccal mucosa [7], bladder mucosa [10], full thickness skin graft [4] and tunica vaginalis [9].

For successful repair, the suture line should be water-tight. On the other hand, sutures must not be too tight or else necrosis of edges of the anastomosis will ensue. It is also important to avoid overlapping suture lines to prevent fistula formation. Shaer et al., reported successful hypospadias repair using saphenous venous graft [14].

Ideally, the tissue for urethroplasty should be abundant to allow for a long urethra in proximal hypospadias, should be elastic to allow erection without curvature and it is better to be pre-tubularized to eliminate the need for a longitudinal suture line that may be a site of for fistula formation and repair dehiscence.

A cylindrical vein graft may provide an alternative to the currently utilized tissues. Aim of this study is to evaluate the use of a vein graft as a urethral substitution for complex type of hypospadias.

PATIENTS AND METHODS

This study was performed in the Plastic, Reconstructive and Burn Unit, Menoufiya University Hospital and Cairo University Hospitals. This study has included eight patients presented with complex type of hypospadias. 5 cases of Penoscrotal hypospadias and 3 cases of Recurrent posterior-penile hypospadias. All patients underwent a vein graft as a urethral substitution Their ages ranged from 2 to 12 years (mean: 5 years). From 2003 until 2007.

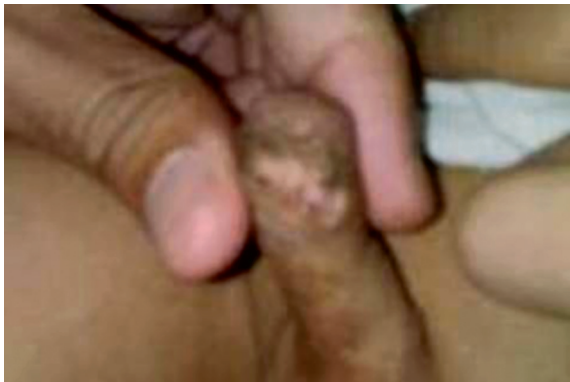Follow-up ranged from 6 months to 2 years. The mean follow-up was 15 months.

Technique:

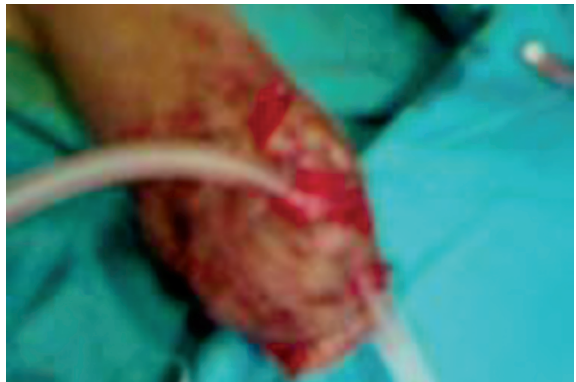The proximal urethra was mobilized by sharp dissection for a distance of 1cm. and the edges were freshened. The tunnel is created in the ventral skin and subcutaneous tissues and corpora cavernosa by a blunt-tip long scissor driven closed through from proximal to distal along the length of the penis, to emerge at the site of new meatus. The scissor was opened to split the tissues and withdrawn in the open position. The resulting track was then dilated into a tunnel using urethral dilators. A 16 dilator was eventually left in the tunnel while the vein graft was harvested.

The saphenous vein was exposed from the saphena varix downwards for a distance that was double that of the urethra to be reconstructed, the length of the urethra measured being in the stretched state. This abundance in length provides full length graft, with reserve elasticity to counteract possible graft contraction and to cope with morning erection.

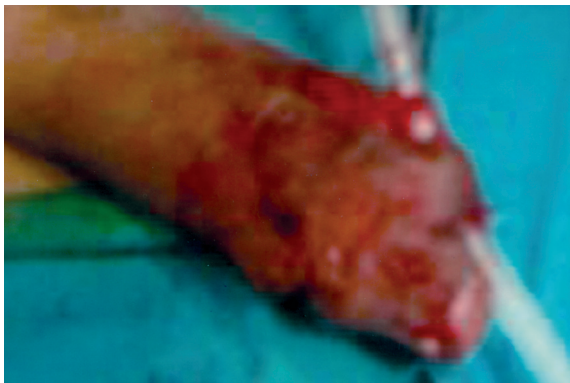The branches of the vein were ligated. The caudal end of the vein was marked and the vein was harvested. The vein was occluded from one orifice and saline injected from the other one to dilate the vein. Urethral catheter was inserted into the tunnel from the distal orifice. The tip of the catheter was received at the proximal end and was inserted through the vein graft, from the cranial orifice of the vein to the caudal orifice which was pre-marked. The tip of the catheter was then inserted into the original meatus and onto the urinary bladder. Mounted on the catheter, the vein graft was pulled through the tunnel using a hemostat or stay sutures. The cranial orifice of the vein was received at the distal opening of the tunnel, where it was sutured to the skin. The caudal orifice of the vein was spatulated and sutured to the original meatus. The anastomosis was covered by a layer of dartos muscle. The incision was closed. The urethral catheter was removed after 7 days Figs. (1,2).



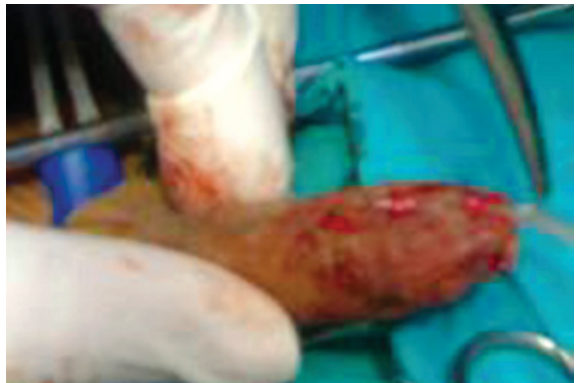
Recurrent hypospadias



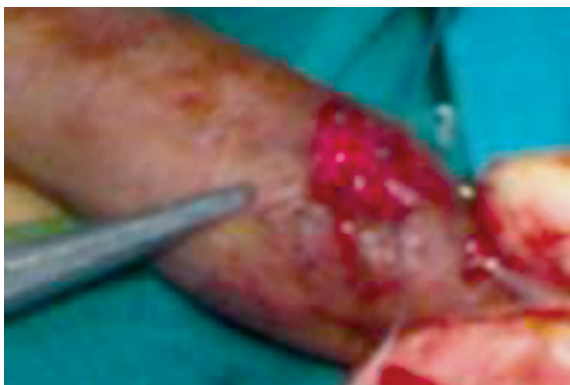The vein graft inset in place



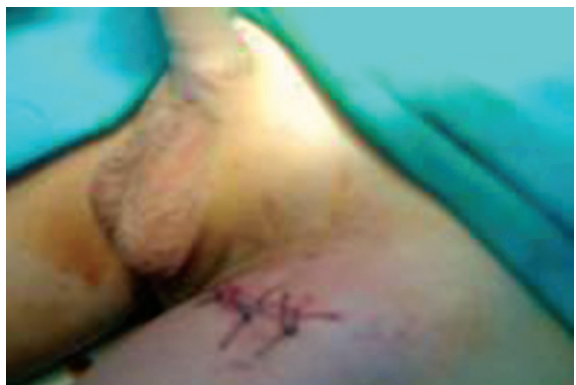Completion of distal anastomosis



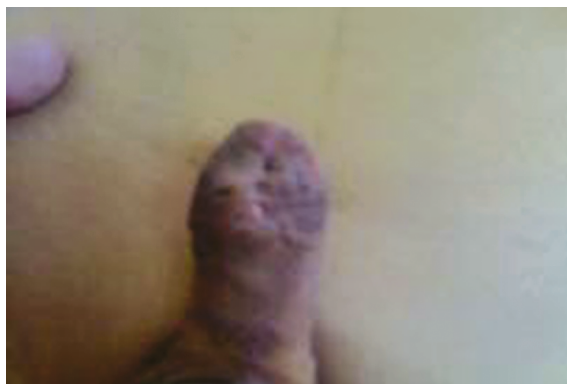Posterior layer of proximal anastomosis



Completion of proximal anastomosis

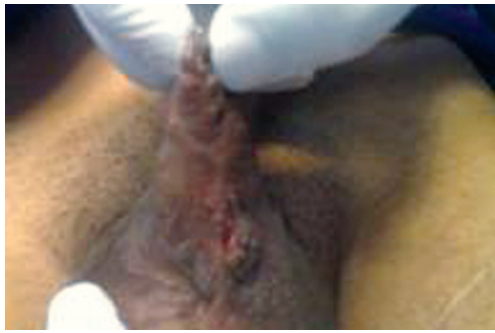

Wound closure after vein graft



Post operative 6 months

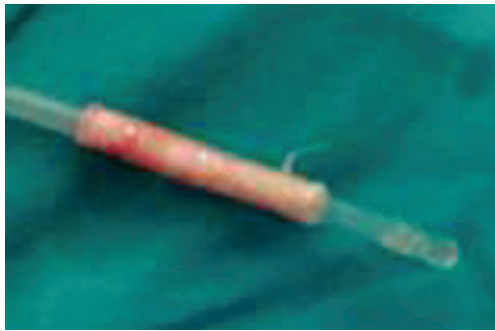Fig. (1): A case of recurrent hypospadias repaired by vein graft.



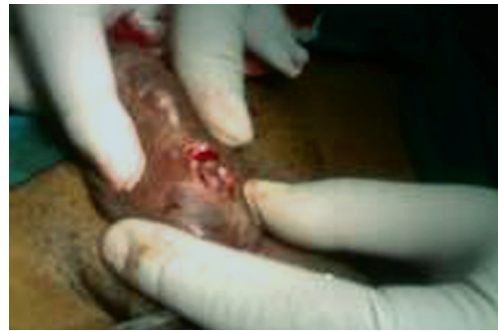Penoscrotal hypospadias



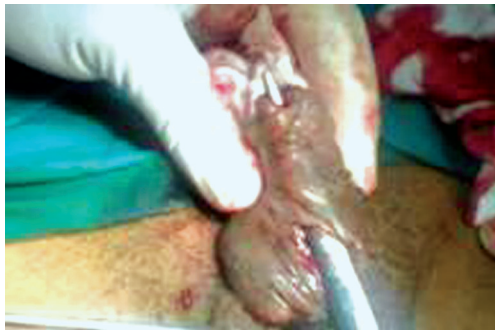Vein graft after harvesting



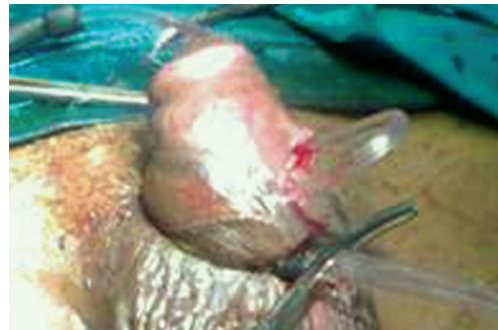
Vein after dilatation



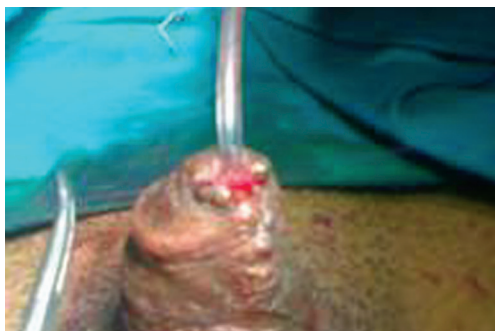Freshening of the edge



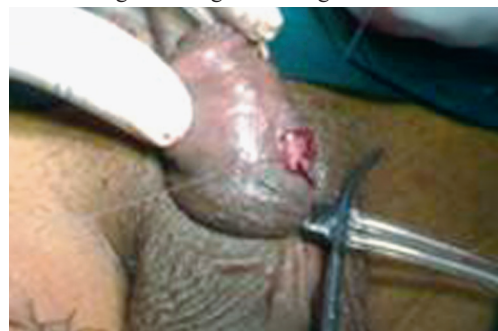Creation of the tunnel



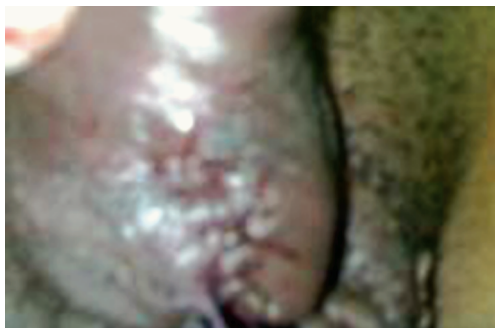Passage of the graft through the tunnel



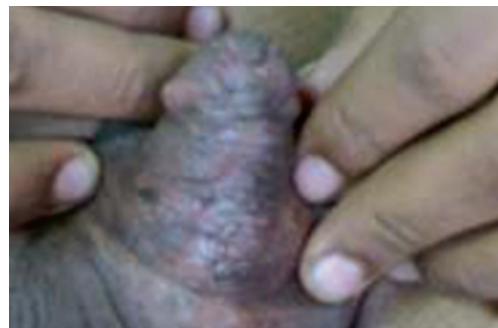Distal anastomosis



Proximal anastomosis



Closure of outer layer



Postoperative 6 months

Fig. (2): Penoscrotal hypospadias.

RESULTS

After a follow-up period which ranged from 6 months to 2 years, the neo-urethra survived adequately in 5 cases. Meatal stenosis occurred in 1 case for which repeated dilatation was required. Fistula occurred in 2 cases.

Table (1) shows complications of the technique.

Table (1): Complications of the technique.

Complication	Incidence
Meatal stenosis	1
Fistula	2

Table (2): Types of hypospadias cases included in the study.

Type	Incidence (8)
Penoscrotal	5
Recurrent posterior-penile	3

DISCUSSION

Not only is hypospadias a common congenital anomaly, affecting 3-5 per 1000 male birth, but post operative complications are common as well. Among the common complications are fistula formation, strictures, meatal stenosis, urethral diverticulum and hairy urethra [3,13].

The first skin graft urethroplasty was devised by Nove-Joserand. Stenosis and strictures occurred with this technique because of the inherent contracture of the skin graft so it was abandoned. It was later popularized by McIndoe, who recommended that the stent be left in place for 6 to 12 months to overcome the tendency for contracture [4].

Thiersche and Duplay have been given credit for the first successful hypospadias repairs (two stage repair). The deficiency of this repair was that it never adequately extended the urethra to the tip of the glans Duplay, 1880. The technique, however, was successfully reintroduced and popularized by Blair and Byars Blair, 1938. This operation was probably the most common type of hypospadias repair reported in the literature until one stage repairs became popular. Browne modified this technique by not making the ventral strip of skin into a tube Browne, 1949. All of these operations ended with subglanular meatus. Cecil during the mid 1940s introduced a three-stage repair for complicated hypospadias cripples [7,11].

Urethroplasty may be performed using local or distant tissues. Local tissues, especially the prepuce, are thought to offer the best results, being accustomed to both urine and air, stretchable so as to cope with erection and non-hairy to avoid stone formation. There are many patients who have had prior unsuccessful hypospadias repairs. Typically, they have insufficient penile skin remaining so that preputial grafts or flaps are not an option for these hypospadias cripples. Unfortunately, the limited availability of these tissues for re-do surgery forces the surgeon to search for alternatives [5,15].

The extra-genital tissues are particularly needed in such complex cases. Among those tissues are buccal mucosa [7] bladder mucosa [10] full thickness skin graft [4] and tunica vaginalis [9]. Skin grafts exhibit contracture and have low elasticity that is incompatible with the erectile function, and carry the hazard of a hairy urethra, even if harvested from an apparently non-hairy area [13]. Buccal mucosa is reported to have certain advantages in that it is hairless, leaves no donor site defect and have enhanced graft take because of the thin lamina propria dense capillary network. But buccal and bladder mucosa are relatively thin, predisposing to ballooning upon distal obstruction. The available area of mucosa may limit the possible length of the neo-urethra. More over, the longitudinal suture line used in urethral reconstruction using the above mentioned tissues represent a weak point predisposing to many complications.

Substituting the urethra with a vein graft may provide a reliable and practical alternative to the current techniques [14].

In this study, eight patients presented with complex type of hypospadias, 5 penoscrotal cases and 3 recurrent posterior-penile cases underwent a vein graft as a urethral substitution. The neo-urethra survived adequately in 5 cases. Meatal stenosis occurred in 1 case and repeated dilatation was required. Fistula occurred in 2 cases. The saphenous vein graft is of sufficient length to serve the most ambitious urethroplasty and is of suitable caliber for an adequate urethra. The sufficient length and the inherent elasticity of the vein prevents the erection and curvature problems after urethroplasty. The multilayer structure of a vein provides a sturdy graft that may be less prone to ballooning. Being it is pre-tubularized; this eliminates the need for the longitudinal suture line thus decreasing the incidence of fistula formation. Operative time is considerably less because the suture lines are minimized to those of the urethra-

to vein proximally and the vein-to-skin distally. Also harvesting the saphenous vein is easy and fast.

Conclusion:

Substituting the urethra with a vein graft may provide a reliable and practical alternative to the current techniques. The saphenous vein graft is of sufficient length to serve the most ambitious urethroplasty and is of suitable caliber for an adequate urethra. The sufficient length and the inherent elasticity of the vein prevent the erection and curvature problems after urethroplasty. Being it is pre-tubularized; this eliminates the need for the longitudinal suture line thus decreasing the incidence of fistula formation.

REFERENCES

- 1- Backus L.H. and DeFelice C.A.: Hypospadias; Then and now. *Plas Reconstr Surg.*, 25: 146-168, 1960.
- 2- Bauer S.B., Retick A.B. & Colodny A.H.: Genetic aspects of hypospadias. *Urol. Clin. North Am.*, 8: 559, 1981.
- 3- Czeiel A. and Toth J.: Correlation between the birth prevalence of isolated hypospadias and parental subfertility. *Teratology*, 41: 167, 1990.
- 4- Devine Jr C.J. and Horton C.E.: A one stage hypospadias repair. *J. Urol.*, 85: 166, 1961.
- 5- Duckett J.W.: Transverse preputial island technique for repair of severe hypospadias. *Urol. Clin. North Am.*, 7: 423-431, 1980.
- 6- Horton C.E. and Devine C.J.: One stage repair-111. In: Horton C.E. (Ed): *Plastic Reconstructive Surgery for the Genetic Area*. Boston, Little, Brown & Co., pp 273, 1973.
- 7- Humiy G.A.: A one-stage operation for hypospadias. *Br. J. Urol.*, 29: 84, 1941.
- 8- Kaplan G.W. and Lamm D.L.: Embryogenesis of chordee. *J. Urol.*, 114: 769, 1975.
- 9- Khoury A.E., Olson M.E., McLorie G.A. and Churchill B.M.: Urethral replacement with tunica vaginalis: A pilot study. *J. Urol.*, 142: 628, 1989.
- 10- King L.R.: Bladder mucosal grafts for severe hypospadias: a successful technique. *J. Urol.*, 152: 2338-40, 1994.
- 11- Koyanagi T., Nonmura K., Gotoh T., et al.: One-stage repair of perineal hypospadias and scrotal transposition. *Eur. Urol.*, 10: 364-367, 1984.
- 12- Olsson C.A. and Krane R.J.: The controversy of simple Vs. multistaged urethroplasty. *J. Urol.*, 120: 414, 1978.
- 13- Retik A.B. and Atala A.: Complications of hypospadias repair. *Urol. Clin. North Am.*, 29: 329-39, 2002.
- 14- Shaer O.K.Z. and El-Sadat A.: Urethral substitution using vein graft for hypospadias repair. *Journal of Pediatric Surgery*, 2: 518-521, 2006.
- 15- Snow B.W. and Canwright P.C.: The yoke hypospadias repair. *J. Pediatr. Surg.*, 29: 557-560, 1994.