

A Limited Scar Approach to Massive Gynecomastia

AMR MAGDY, M.D.

The Department of Plastic and Reconstructive Surgery, Faculty of Medicine, Ain Shams University.

ABSTRACT

Minimal scar techniques for the treatment of gynecomastia did not meet the requirements of patients with high grades, Simon grade III, or patients with redundant breast skin after massive weight loss. These techniques end up by only a circumareolar scar but may leave residual skin redundancy and widening of the areola might occur. On the other hand earlier techniques had good control on bulk and skin excess but were associated with extensive scarring that makes their use unfavorable. This article describes a relatively limited scar technique for patients with massive gynecomastia that is considered a compromise in terms of scar extension but with excellent control on the skin and gland excision. It is an additional useful modality in the hands of plastic surgeons to be used in the proper indication.

INTRODUCTION

The characteristic muscular arrangement of the male chest with the defined pectoralis major muscle and the lower serratus anterior with absence of any skin redundancy and fat deposits is a remarkable sign of masculine structure. Athletes exert much work out to achieve such a perfect figure. In patients with gynecomastia, concealment of these details by fat accumulation, glandular enlargement or skin redundancy refers to a deviation of norm and is a source of embarrassment.

The psychological stress of patients with huge gynecomastia, Simon's [1] grade III or Rodrich [2] grade VI, may even get worse after the formal surgical procedures with extensive scars that violate their hope to get rid of their feminine look.

The standard traditional treatment modality for those patients was subcutaneous mastectomy and free nipple grafting [1,3,4] with loss of nipple sensibility and the increased risk of non-take [5]. The other modality was the formal breast reduction techniques leaving extensive scars, mostly an inverted T scar [6].

The complexity of these scars and their presence around and in direct continuity to the areola refers without doubt to the presence of a breast problem

ruining the psychological benefit of the surgery (Fig. 1).

The use of liposuction [7,8] and its new modalities: Ultrasonic assisted [2,9,10] or laser assisted [11], was an important step in the evolution of the management of gynecomastia and gained much popularity as an effective surgical tool. Residual skin redundancy and the need for a second intervention, when liposuction alone was used, were reported in patients with grade III [11]. So, using liposuction alone is indicated for patients with Simon's grade I, IIa and selected cases of grade IIb [2].

Concentric de-epithelialization and skin gathering around the nipple with purse-stringing combined with different forms of liposuction or subcutaneous mastectomy through a limited approach became a standard procedure [12-15], but still skin redundancy was observed in the more severe cases [11].

Morbid obese patients with massive weight loss experience a different problem. There is great discrepancy in the skin-bulk load. In these patients there is no much gland or fatty tissue to be removed but it is the extensive lax skin that needs to be excised, where scars are inevitable. No special techniques are available regarding this problem [11]. These patients are merely treated, as those with severe forms of gynecomastia, with the current available methods; excision and free nipple grafting or transposing the nipple areola complex on a pedicles with extensive scarring, primarily the inverted T scar [6].

This article presents a technique for this category of patients with massive forms of gynecomastia or excessive lax breast skin after massive weight loss. It permits the excision of that massive skin excess and transposes the areola nipple complex on a vascularized pedicle with limited scars.

Idea:

Post operative photos of patients with high grade gynecomastia who were treated with different forms of scars were plotted on a computer. Using a photo editor program, each of the limbs of the scars was eliminated at a time and the degree of disfigurement and its acceptance by different viewers were evaluated. It was the vertical limb of the T, and those in direct continuity to the circumareolar scar, that were much noticeable and disfiguring

(Fig. 1). This is true because in males the scar is well apparent, unlike female breast, where most of the vertical scar is hidden behind the breast. In contrast, the transverse limb of the T or scars in the submammary sulcus are relatively away from the areola so can be related to other causes or traumatic incidence rather than a breast surgery. This was stimulating to design a technique for those patients to eliminate the vertical part of the scar.

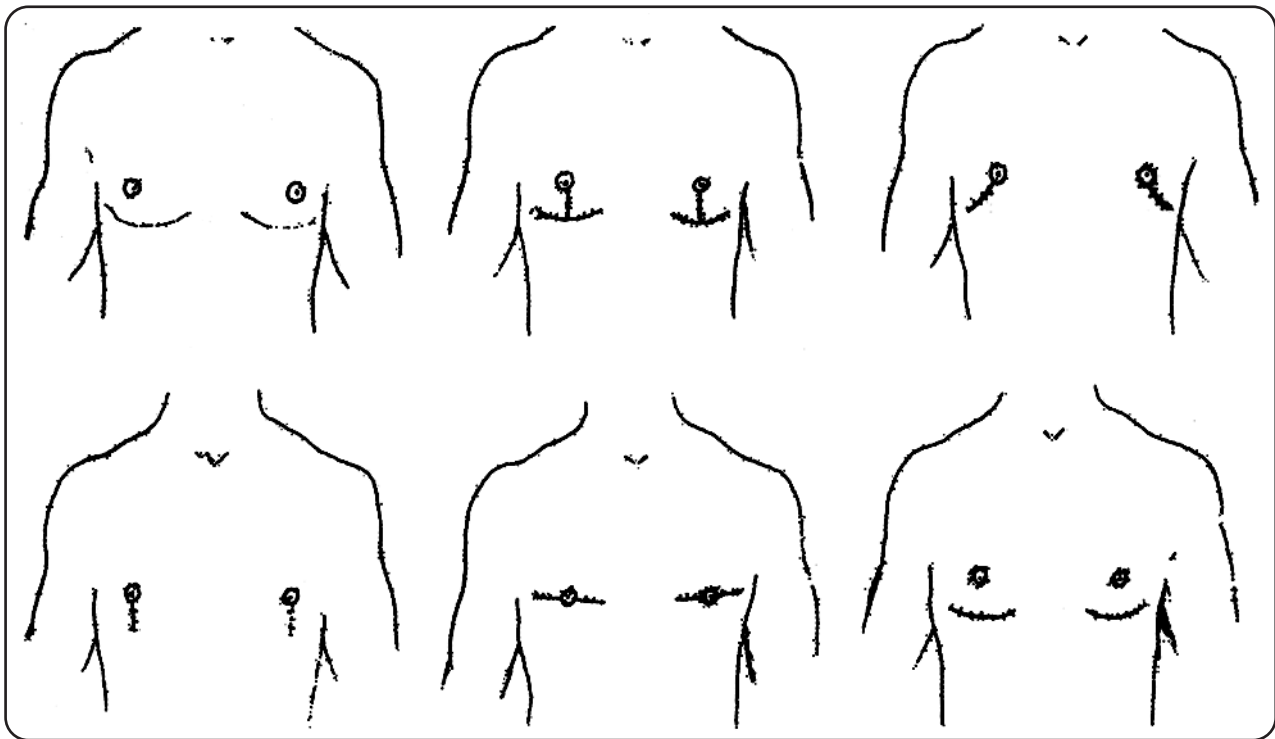


Fig. (1): Different scars of traditional operations for gynecomastia.

Concept:

To carry the nipple areola complex on a wide inferior de-epithelialized dermo-fascial pedicle with minimal thickness based at the infra-mammary crease. This is transposed superiorly to be fixed to the chest wall under a perfectly defatted upper flap after complete excision of the breast tissue from the undersurface of both flaps. The nipple/areola complex is then exteriorized at their proper position through the upper flap.

The vertical length of the upper flap includes the breast skin superior to the areola that is sufficient to reach for the infra mammary crease. The remaining excess skin, from this point to the submammary fold will be the inferior flap. The inferior flap is marked and is de-epithelialized except for the areola that may be reduced in size according to patient desire.

This eliminates the vertical skin excess. In the upper flap, the excess skin in the transverse direction is transposed laterally to be excised as a dog-ear at the anterior axillary line transforming the inferior incision to a transverse J or L that is concealed in the axilla.

MATERIAL AND METHODS

Eight patients with Simon's grade III gynecomastia (n=8) and four patients with post parietic surgery skin redundancy (n=4) were operated upon using this technique in the period between January 2006 and March 2007. Their age ranged between sixteen and forty seven years.

Pre and post operative measurements as well as the amount of excision are recorded. The final shape of the breast, the success in removing all the excess breast tissue especially at the site of the

pedicle, the location, the degree of acceptance of the scars and their quality were evaluated. Patients were followed-up for six months post operatively.

Design:

Two horizontal lines are drawn at the level of the supra-sternal notch and at the center of the infra-mammary creases (Fig. 2).

The distance between the two lines is measured. A point, having the same distance from the supra-sternal plane is marked on the breast at the mid clavicular line, point A. This is the length of the upper flap and the inferior limit of the breast.

The medial and lateral limits of the breast are marked at the level of the infra-mammary crease, points B and C respectively. Point C is made slightly higher than point B. Point D is marked on the infra-mammary crease in the same vertical plain as point A. An ellipse is marked, joining points A, B, C and D.

The new nipple position is marked over the fourth intercostal space in the same vertical plain as the present one unless there is a need to transpose it horizontally, point E. A circular mark is drawn around the areola at the desired size.

Two dotted circles are drawn on the skin delineating the contour of the breast to determine the limits of the excision and feathering.

Operative procedure:

The operation can be done under local or general anesthesia with the patient in the semi-sitting position. The points and lines are scored and the breasts are infiltrated with diluted epinephrine, 1/200,000.

The area between points ABC and D is de-epithelialized excluding the areola as in the female breast reduction. This will be the lower dermo-fascial flap (Fig. 3A).

The line BAC is incised down to and including the superficial fascia. All the breast tissue between the dermo-fascial layer and the pectoral fascia is removed with care not to disrupt the sensory nerves at the lateral part of the breast, creating the inferiorly based lower dermo-fascial flap (Fig. 3B). The excision is feathered at the margins, and the deep attachment of the infra-mammary crease is disrupted.

The upper flap is dissected as high as needed to excise all the remaining breast tissue and to allow fixing of the lower flap to the pectoral fascia (Fig. 3C). The thickness of the flaps can be in-

creased proportional to the amount of the subcutaneous fat elsewhere in the chest to prevent saucer deformity or nipple inversion.

The lower flap is fixed to the pectoral fascia high under the upper flap by 2/0 prolene® sutures (Fig. 3D). The transverse excess in the lower flap can be excised or tucked under the lateral margins of the upper flap to achieve smoothing of the contour. The upper flap is then sutured to the line BDC. If there is horizontal skin excess, it is excised at the lateral limit of the scar in upward direction creating an L or J scar.

The nipples are exteriorized through the upper flap and sutured at their marked position. If there is difficulty in transposing the nipple in the transverse direction, a medial or lateral back-cut is made as desired to facilitate its movement. A 3/0 burse-string prolene® sutures might be placed around the areolae but are not often necessary as there is no tension on the circumareolar sutures.

After careful hemostasis, wound is closed in two layers. Drains are not usually needed and compressive dressing is applied for a week to be followed by an elastic garment.

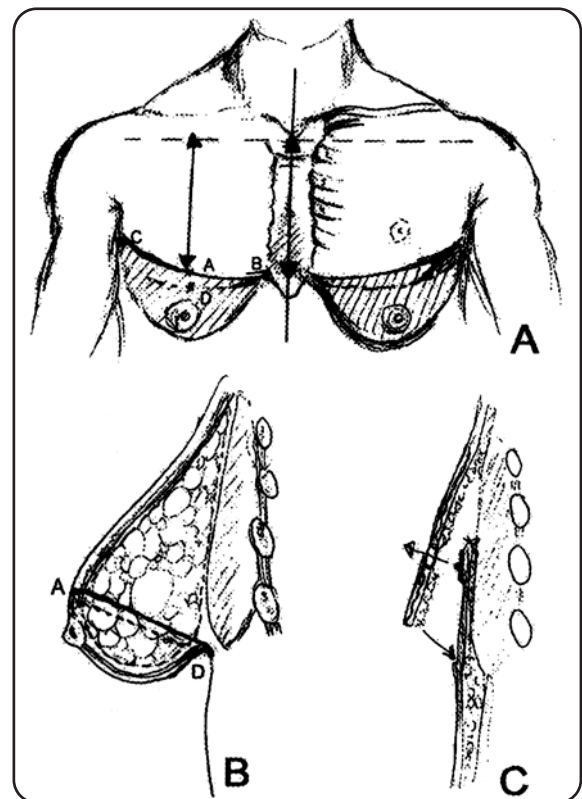


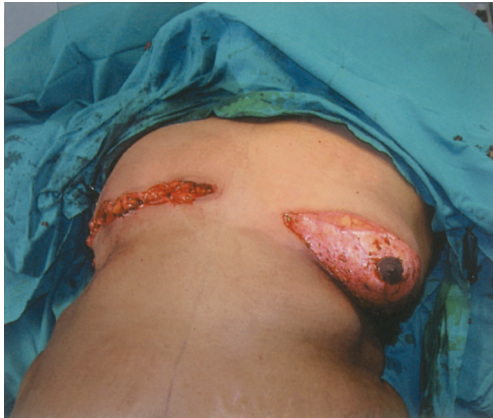Fig. (2): Diagrammatic illustration of the design of the technique.

A: Anterior view.

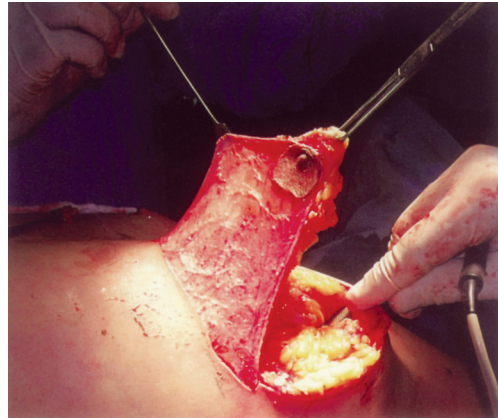
B: Lateral view.

C: Tucking of the inferior flap under the upper one and exteriorization of the nipple.

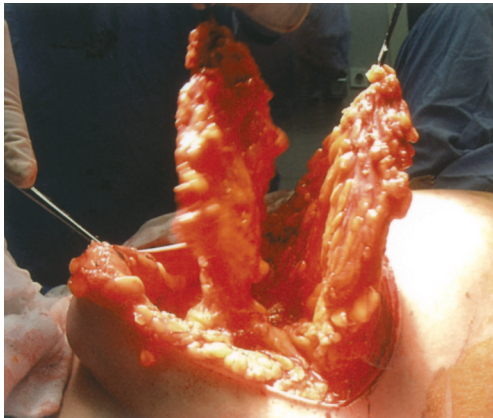
Fig. (3): Steps of the technique:



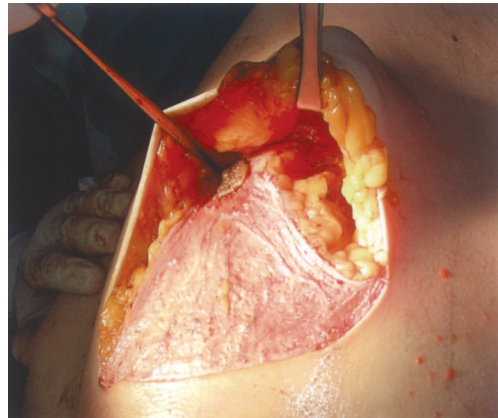
A: De-epithelialization.



B: Thinning and elevation of the lower dermo-fascial flap.



C: Excision of the breast tissue under the superior flap.



D: The inferior flap in place.

RESULTS

Twenty four breasts in twelve patients with grade three gynecomastia and massive weight loss were operated upon. The amount of excised tissue ranged between 270 and 450gms, and the distance for nipple transposition ranged from 5 to 8cm. All patients healed nicely with no infection, disruption or seroma formation, though no drainage was used in any case. Symmetry was excellent regarding breast contour, nipple areola position and size. There were no residual breast tissues, skin redundancy, saucer deformity or delayed enlargement of the areolae. All patients were satisfied by the results. Most of the scars were accepted by the patients regarding site, size and quality (Figs. 4,5). Only one patient developed hypertrophic scars and another had asymmetry of the scar level.

DISCUSSION

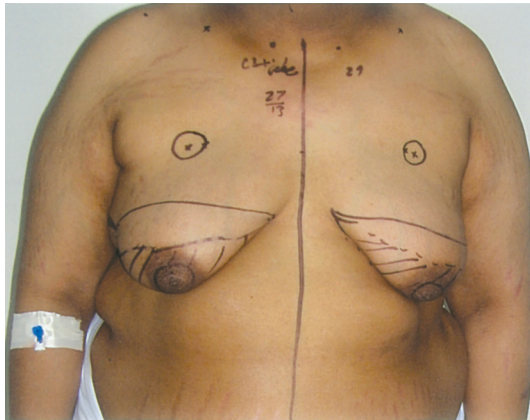
Numerous types of operations were designed for the patients with different grades of gyneco-

mastia (Fig. 6). Earlier techniques were excisional in nature. Webster [16] pointed out the value of the intra-areolar approach aiming to conceal the entry points of excision. His technique was followed by others who used a variety of designs all were centered on the areola with different forms of extensions [17,18] or tried remote incisions [19]. This was mainly for mild to moderate sizes.

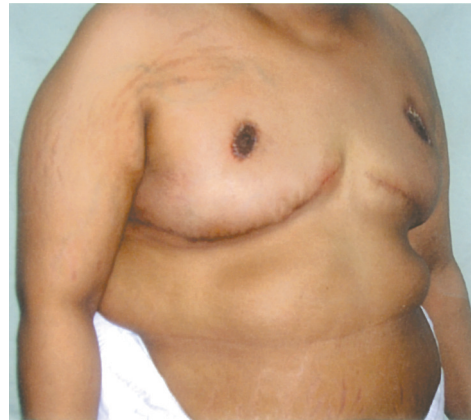In more severe types where skin needs to be excised, techniques that transpose the nipple areola complex were developed [20-22] but the transposition was limited and the scars needed to be larger to permits adequate skin excision.

The introduction of liposuction had a great impact on the outcome of these patients. Larger amounts of tissues whether fatty or glandular [23] could be removed from minute incisions with the hope of shrinkage of coopers' ligaments and skin retraction [7]. This is true for the young, but older patients with excessively redundant skin needed something more to be done.

Fig. (4): Eighteen years old male patient with grade three gynecomastia. The patient is on replacement steroid therapy after bilateral excision of the supra-renal glands.

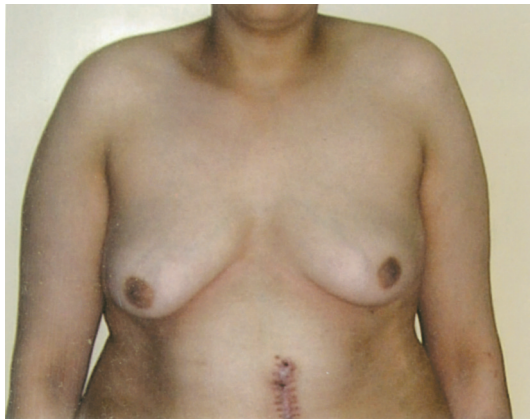

B: Three months postoperatively.

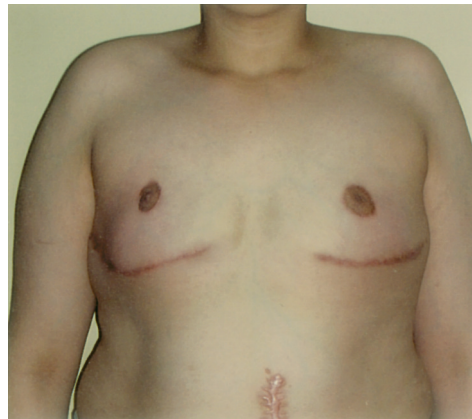

A: Preoperative view.

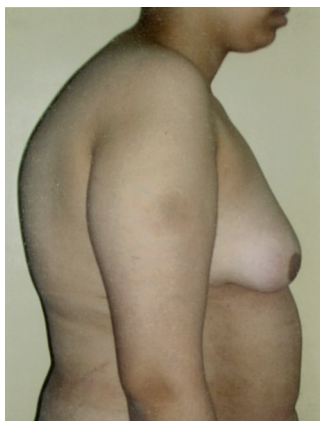Fig. (5): Twenty four years old patient with grade three gynecomastia.



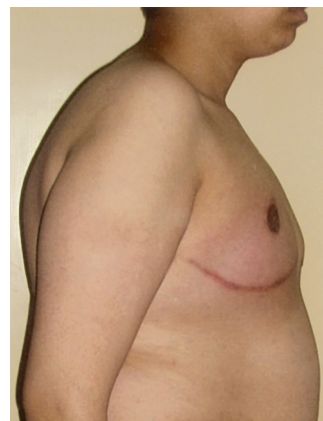A: Preoperative anterior view.



B: Postoperative anterior view.



C: Preoperative lateral view.



D: Postoperative lateral view.

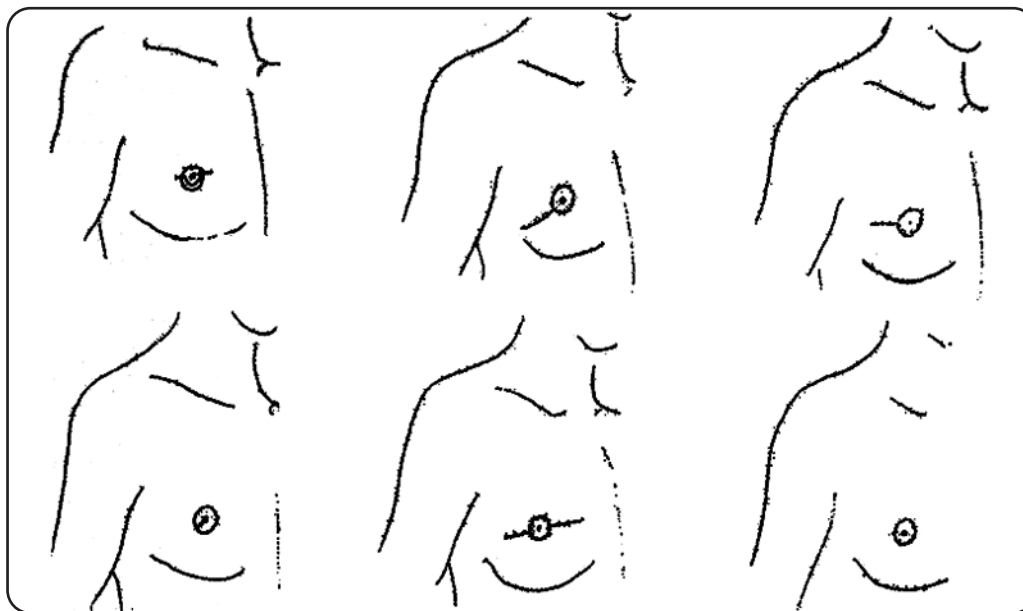


Fig. (6): Different techniques for the three grades of gynecomastia.

- A: Excision through an inverted omega incision for mild cases (Barsky, et al., 1964).
 B: Excision through a radial intra areolar incision for mild cases (Eade, 1974).
 C: Nipple transposition on a dermal pedicle for moderate cases (Letterman, et al., 1972).
 D: Nipple transposition on a vertical dermal bi-pedicle for moderate to large cases (Pers, et al., 1972).
 E: Nipple advancement on a dermal pedicle for moderate to large cases (Bretteville-Jensen, 1975).
 F: Block excision with free nipple grafting (Wary R.C., Hoopes, et al., 1974).

Circumareolar de-epithelialization combined with glandular excision or suction assisted lipectomy [12-15] offered a lot and considered the treatment of choice for most of the cases. It was proved to be superior in many hands who claimed that it is suitable even for the most severe cases [15]. After wide spread use of the techniques increasing reports about residual skin redundancy appeared and the need for a solution was demanded [24].

Pariatric surgery is now in vogue and patients with massive weight loss are presented more and more. The high expectations of these patients to have prompt and complete skin shrinkage is unrealistic to be achieved with only a circumareolar excision, justifies the traditional more radical surgeries.

The presented technique combines the benefit of extensive skin and glandular excision in massive forms, yet maintaining excellent vascularity of the nipple areola complex with acceptable limited scars.

The scar, placed in the infra-mammary crease, is relatively accepted being away and not as an extension of the areolar incision. The absence of tension or points of meeting of flaps, as in the inverted T scar, makes its healing smooth and nice. It is designed to be higher at its lateral end than

the medial one to mimic the contour of the pectoralis major muscle that is desirable and has an athletic masculine look.

The excess skin in the transverse direction is mainly present in the lower flap, so can be excised without additional scars or tucked under the upper flap in favor of smoothing of the final chest contour. Transverse excess skin at the level of the upper flap is not common as it is usually minimal and the skin retracts after glandular excision. In old patients or excessively damaged skin, the excess is transposed laterally and excised as a vertical extension of the lateral end of the scar. Placing it at the anterior axillary fold makes it concealed and inconspicuous.

The technique offers perfect control on the nipple position. The vertical repositioning is an integral part of the design. Back cuts at the medial or lateral ends of the lower flap can be done to allow the transverse mobilization, so the complex can be exteriorized at any desired position unlike the techniques with a smaller or central pedicle where nipple transposition is limited [11].

The diameter of the areola never enlarges by time and purse string sutures are not needed, as in the circum areolar techniques, as there is no tension exerted on the areola by the tissues gathered

around it. Reports about wound dehiscence in the other techniques are not uncommon [14].

The lower flap though thin, but its vascularity is excellent as proved by previous studies of the anatomy and vascular supply of the superficial fascia in the breast and the use of dermo-fascial flaps in the female breasts [25].

The width of the lower flap lines the whole upper flap so this in addition to its controllable thickness helps in preventing the nipple retraction or saucer deformity observed in other techniques [13].

Conclusion:

This technique is versatile and accommodates any amount of excess skin to be excised with good reproducible results. Yet, it is simple, can be easily mastered, and met with great patient satisfaction. It is only indicated for the most severe cases where other techniques will fail and the extent of the scars is weighed against the benefits of the large excision and the maintenance of nipple viability. It is to be added to the plastic surgery armamentarium.

REFERENCES

- 1- Simon B.E., Hoffman S. and Khan S.: Classification and surgical correction for gynecomastia. *Plast. Reconstr. Surg.*, 51: 48, 1973.
- 2- Rohrich R.J., Ha R.Y. and Kenkel J.M.: Classification and management of gynecomastia: Defining the role of ultrasound-assisted liposuction. *Plast. Reconstr. Surg.*, 111: 909, 2003.
- 3- Botta S.A.: Alternative for the surgical correction of severe gynecomastia. *Aesthetic Plast. Surg.*, 22: 65, 1998.
- 4- Wary R.C., Hoopes J.E. and Davis G.M.: Correction of extreme gynecomastia. *Br. J. Plast. Surg.*, 27: 39, 1974. Quoted from: McGarh M.H.: Gynecomastia. In: Jurkiewicz M.J., Krizek T.J., Mathes S.J. and Ariyan S., eds. *Plastic Surgery, Principles and Practice*. St. Louis: C.V. Mosby, p 1119, 1990.
- 5- Spear S.L., Gradinger G.P. and Mess S.: Breast reduction with the free nipple graft technique. In: Spear S.L., ed. *Surgery of the breast. Principles and art*, 2nd ed. Philadelphia: Lippocott Williams and Wilkins, p 1172, 2006.
- 6- Wiesman I.M., Lehman J.A., Parker M.G., Tantri D.P., Wagner D.S. and Pedersen J.C.: Gynecomastia, an outcome analysis. *Ann. Plast. Surg.*, 53: 97, 2004.
- 7- Rosenberg G.J.: Suction lipectomy as a contemporary solution. *Plast. Reconstr. Surg.*, 80: 379, 1987.
- 8- Lejour M.: Evaluation of fat in breast tissue removed by vertical mammoplasty. *Plast. Reconstr. Surg.*, 99: 386, 1997.
- 9- Maillard G.F., Scheflan M. and Bussien R.: Ultrasonically assisted lipectomy in aesthetic breast surgery. *Plast. Reconstr. Surg.*, 100: 238, 1997.
- 10- Apfelberg D.B.: Results of multicenter study of laser-assisted liposuction. *Clin. Plast. Surg.*, 23: 713, 1996.
- 11- Taskhandi M., Al-Qattan M.M., Hassanain J.M., Hawary M.B. and Sultan M.: The surgical management of high grade gynecomastia. *Ann. Plast. Surg.*, 53: 17, 2004.
- 12- Davidson B.A.: Concentric circle operation for massive gynecomastia to excise the redundant skin. *Plast. Reconstr. Surg.*, 63: 350, 1979.
- 13- Huang T.T., Hidalgo J.E. and Lewis S.R.: A circumareolar approach in surgical management of gynecomastia. *Plast. Reconstr. Surg.*, 69: 35, 1982.
- 14- Persichetti P., Berloco M., Casadei R.M., Marangi G.F., Di Lella F. and Nobili A.M.: Gynecomastia and the complete circumareolar approach in the surgical management of skin redundancy. *Plast. Reconstr. Surg.*, 107: 948, 2001.
- 15- Farag M., Ali A., Safe K. and Eleiwi M.D.: Combination of liposuction and excisional surgery as a standardized minimal scarring technique for gynecomastia: Experience with 150 cases. *Egypt. J. Plast. Reconstr. Surg.*, 31: 201, 2007.
- 16- Webster J.P.: Mastectomy for gynecomastia through a semicircular intra-areolar incision. *Ann. Surg.*, 124: 556, 1964. Quoted from: Riefkohl R. and Courtiss E.: Gynecomastia. In: Georgiade G.S., Georgiade N.G., Riefkohl R. and Barwick W.J. eds. *Textbook of plastic, maxillofacial and reconstructive surgery*. 2nd ed. Baltimore: Williams and Wilkins, p 877, 1992.
- 17- Barsky A.J., Khan S. and Simon B.E.: Principle and practice of plastic surgery, 2nd ed. New York: McGraw-Hill Book Co., 1964. Quoted from: McGarh M.H.: Gynecomastia. In: Jurkiewicz M.J., Krizek T.J., Mathes S.J. and Ariyan S., eds. *Plastic surgery, Principles and Practice*. St. Louis: C.V. Mosby, p 1119, 1990.
- 18- Eade G.G.: The radial incision for gynecomastia excisions. *Plast. Reconstr. Surg.*, 54: 495, 1974.
- 19- Morselli P.G.: "Pull-through": A new technique for breast reduction in gynecomastia. *Plast. Reconstr. Surg.*, 79: 450, 1996.
- 20- Letterman G. and Schurter M.: Surgical correction of massive gynecomastia. *Plast. Reconstr. Surg.*, 49: 259, 1972.
- 21- Pers M. and Bretteville-Jensen G.: Reduction mammoplasty based on vertical bipedicle and "tennis ball" assembly. *Scand. J. Plast. Reconstr. Surg.*, 6: 61, 1972. Quoted from: McGarh M.H.: Gynecomastia. In: Jurkiewicz M.J., Krizek T.J., Mathes S.J. and Ariyan S., eds. *Plastic surgery, Principles and Practice*. St. Louis: C.V. Mosby, p 1119, 1990.
- 22- Bretteville-Jensen G.: Surgical management of gynecomastia. *B. J. Plast. Surg.*, 28: 177, 1975.
- 23- Rosenberg G.J.: Gynecomastia. In: Spear S.L., ed. *Surgery of the breast, principles and art*, 2nd ed. Philadelphia: Lippocott Williams and Wilkins, p 1210, 2006.
- 24- Abdel Mageed M.: Surgical treatment for moderate and large-sized gynecomastia. *Egypt. J. Plast. Reconstr. Surg.*, 31: 45, 2007.
- 25- Magdy A.: Three slips dermo-fascial brassiere breast reduction technique. *Egypt. J. Plast. Reconstr. Surg.*, in press.