

## Acute Prevention of the Commonest Postburn Intrinsic Minus Deformity of the Hand

ASHRAF EL-SEBAIE, M.D.; AMR IBRAHIM FOUAD, M.D., M.R.C.S and TAREK A. AMER, M.D.

*The Department of General and Plastic Surgery (Burn Unit), Faculty of Medicine, Cairo University.*

### ABSTRACT

The hand is a beautiful artistic tool that is considered to be the main interface between man and his environment. Hand burn represents a small wound area with major potential for disability. The hand comprises about one percent only of the body surface area, despite this, a burn of the hand can represent a serious short or long-term disability. The management of hand burns is multidisciplinary, requiring the expertise of surgeons, nurses and occupational therapists. A burned hand that is not properly positioned, splinted or ranged will develop contractures. Proper management of hand burn is of extreme importance that it is stated that hand function is a strong predictor of quality of life after burn injury. The aim of this study was to reach a protocol for management of the acutely burned hand to prevent the commonest post burn hand deformity. The protocol should be as simple as possible, of low cost, with a proved efficiency and on a scientific basis that well-understand the underlying pathology that leads to the intrinsic minus deformity, thus preventing its occurrence. Fifty (50) patients with acute hand burn was included in this study. No case suffered from functional disability. Complications were in the form of mild degree of infection in 28 cases, that has no effect on the final outcome, 2 cases suffered from grade I hyperextension deformity of the MCPJ and 12 female patients were not satisfied by the cosmetic appearance. It was concluded that proper management of acute hand burns is the cornerstone in preventing intrinsic minus deformity of the hand and this need a multidisciplinary approach requiring the expertise of surgeons, nurses and physiotherapists. Our recommendations for prevention of post-burn intrinsic minus deformity of the hand is early proper therapy, oedema control, adequate hand position and splinting.

### INTRODUCTION

The hand is a beautiful artistic tool that is considered to be the main interface between man and his environment. Hand burn represents a small wound area with major potential for disability. Hands are the most commonly burned area of the body [1]. The hand comprises about one percent only of the body surface area, despite this, a burn of the hand can represent a serious short or long-term disability. The management of hand burns is multidisciplinary, requiring the expertise of surgeons, nurses, and occupational therapists [2]. Hand function evolves and improves continuously, and

the type of work and practice affect the way in which hand functionality develops (as an example; there is a big difference between a violinist's hand and that of a manual worker) [3]. A burned hand that is not properly positioned, splinted or ranged will develop contractures. The typical contracture is an "intrinsic minus" deformity [4]. Proper management of hand burn is of extreme importance that it is stated that hand function is a strong predictor of quality of life after burn injury [5].

#### *Aim of work:*

The aim of this study was to reach a protocol for management of the acutely burned hand to prevent the commonest post burn hand deformity. The protocol should be as simple as possible, of low cost, with a proved efficiency, and on a scientific basis that well-understand the underlying pathology that leads to the intrinsic minus deformity, thus preventing its occurrence.

#### *Review:*

In the overall number of burn cases, hand and wrist burns account for about 39%, usually as a part of a larger burned surface or as a self-standing local injury. They fall into the category of "functional burns" [6]. Due to the unique importance of the hand functions, the American Burn Association, the Advanced Trauma Life Support, and the Advanced Burn Life Support curricula; all recognize the severity of hand burns by classifying these as injuries requiring treatment at a burn center [7].

Hand burns may be caused by several agents, including fire, scalds, electrical injury, chemical injury, friction, and/or radiation [8]. The commonest mode of injury is the flame burns [9]. Hand burns occur more commonly in children as an overall age incidence, in males as an industrial accidents especially in manual workers, in females as a domestic injuries, and in the developing countries more than developed countries [10].

There are three zones of burn. The central area is called the zone of coagulation and is composed of nonviable tissue. Surrounding this central area is the zone of stasis. Initially blood flow is present here, but over the subsequent 24 hours hypoperfusion and ischemia prevail and part of this area combines with the zone of coagulation. Surrounding the zone of stasis is the outer zone of hyperemia, which contains viable tissue [11].

A burned hand that is not properly positioned, splinted, and/or ranged will inevitably develop contractures. These contractures represents a major disabilities that are not easily corrected by a later reconstructive surgery. The typical contracture is an "intrinsic minus" deformity (Fig. 1), where the metacarpophalangeal joints (MPJ) are fixed in hyperextension and the proximal and distal interphalangeal joints (PIPJ and DIPJ respectively) are fixed in a position of flexion [4].

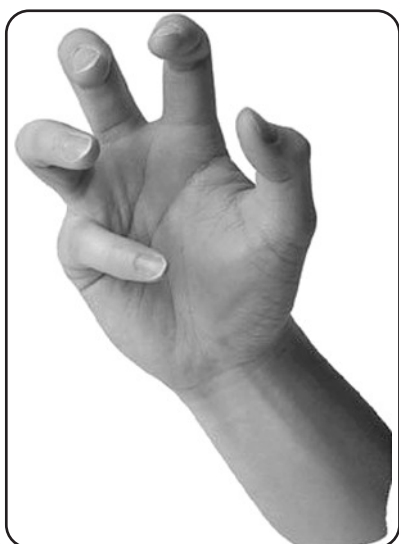

Fig. (1): Intrinsic minus position of the hand (www.acsu.buffalo.edu).  
<http://www.acsu.buffalo.edu/-mk10/images?S=A>

From the surgical point of view, deep dermal and subdermal hand burns are especially important. Deep dermal burns present a pale surface and a waxy appearance. The blisters are less clearly expressed, while paraesthesia together and other changes in sensibility are more manifest. Post-burn oedema can cause the Esmarch tourniquet effect. Intravenous coagulation causes eventual redness. The coagulation zone involves most of the dermal layer. The remaining dermis can be considered a zone of injury with a high risk of conversion. Oedema is widespread throughout the burn, and the necrotic tissue remains adherent. Subdermal burns destroy the entire epidermis and

dermis, leaving no space for residual epidermal cells to repopulate. Vascular burn tissue is waxy-white in colour and painless. If the burn produces charring or extends into the fat, it is leathery brown or black, with surface coagulation veins. Subdermal fat tissue and other deep structures are affected and require special treatment methods. The depth is established by assessing the colour of moist and non-macerating surfaces, by the touch and pain test and by the capillary refilling test [12].

The clinical manifestation of hand burns is directly related to the aetiology of the burn (thermal, electrical, chemical and radiation). There are two main clinical types of hand burn:

- 1- Exposed-burns mainly on the dorsal side.
- 2- Contact-burns mainly on the volar side.

Dorsum hand burns are usually in both hands. The hand by reflex action clenches and covers the face. Dorsum skin is thin, has less subcutaneous tissue, and is therefore liable to deeper burns. The burn usually affects tendons, muscles, bones, and joints. Digital adhesion and joint stiffness are the consequence of burn depth, long-lasting oedema, and local bacterial infection, causing connective tissue proliferation, stiffness, and contractures, with various hand deformations. Oedema impairs the hand in "intrinsic minus position" and such a type of joint ankylosis is difficult to be corrected.

Palmar burns are usually isolated injuries in one hand only, and are rarely part of a larger burned surface. In most cases these are deep burns affecting deep functional structures. Generally speaking, they are not life-threatening, but their total treatment is complicated and complex [13].

#### *Burn oedema:*

Significant fluid shifts occur from the intravascular to the extravascular space soon after a burn. This altered state persists for the first 48 hours post-injury. The rate and amount of edema formation depends on burn depth and size. Early increased vascular permeability is in part related to histamine, but many of the local effects are similar to a reperfusion injury [14]. Re-establishment of blood flow to ischemic areas triggers a sequence of events that produce irreversible damage. The mechanism accounting for this increased vascular permeability is likely related to polymorphonuclear leukocytes (PMNL) and their adhesion to the endothelium. PMNL have been identified as contributing to the microvascular occlusion seen both systemically and locally following burn injury. The adherence of PMNL to vascular endothelial cell surfaces creates a microenvironment in which PMNL de-

rived proteases and toxic oxygen radicals, hydrogen peroxide and hydroxyl radicals are released by both endothelial cells and PMNL. These radicals trigger peroxidation of lipids in cell membranes and resultant cell lysis, to the detriment of vessel lining. Intercellular gap formation, which increases the microvascular permeability, results in edema and thrombosis [15]. Fluid is lost through a "capillary leak" in the burn wound and underlying tissue. The pathophysiology of the loss of capillary integrity is complex and only partially understood [16].

Local vascular damage is the direct result of heat applied to the tissues, but more profound vascular effects are related to both systemic and local factors. Endothelial cells swell, form gaps, and allow extravasation of fluid into the perivascular space. The altered cell transmembrane potential causes sodium to be drawn into cells, which consequently swell. At the same time significant hypoproteinaemia causes a decrease in capillary hydrostatic pressure and plasma oncotic pressure, with a corresponding increase in interstitial oncotic pressure. Any injury and burns are no exception—elicits a massive systemic inflammatory response "in which cytokines and other metabolic products of activated leukocytes can act either beneficially to provide for enhanced host resistance or deleteriously to depress the function of remote organs". Local tissue trauma, i.e. the burn, activates the release of an array of systemic mediators such as complement, arachidonic acid, and cytokines, particularly IL-1 and TNF. A number of local mediators, including oxidants and arachidonic acid metabolites, appear to be involved in burn edema. These local mediators of inflammation also influence the production of systemic mediators, with resultant increases in substances such as PGE2 [17].

*Relation between burn induced hand oedema and intrinsic minus deformity:*

The metacarpal head is uniquely shaped in that it is ovoid in the sagittal plane, and it widens from the dorsal to the volar dimension. The collateral ligaments are eccentrically mounted dorsal to the axis of rotation of the MCPJ. This anatomy causes variable degrees of tightness on the collateral ligaments based on the position of the joint by a camlike effect. When the joint is in extension, the collateral ligaments are lax. In flexion, the collateral ligaments span a greater distance and are tight (Fig. 2). In addition, the MCPJ is also curved in 2 planes to permit abduction, adduction, and rotation, as well as flexion and extension. In flexion, bone surface area contact is greater than in extension, producing a more stable joint [18].

Proximal interphalangeal joint (PIPJ) collateral ligaments originate close to the axis of rotation, providing a smaller change in length with joint position and providing lateral stability (Fig. 3). The PIPJ ranges in only 1 plane, and its trochlear shape also adds to its lateral stability [19].

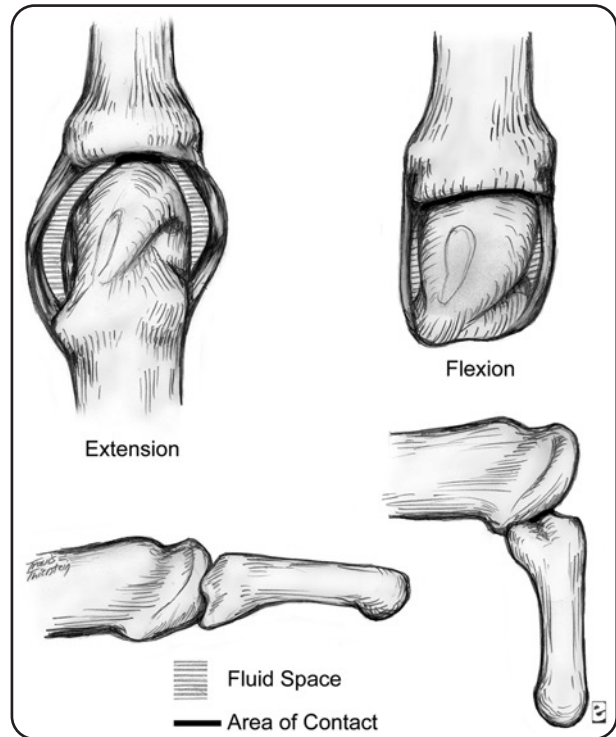


Fig. (2): Collateral ligaments of the MPJ both in flexion and extension [18].

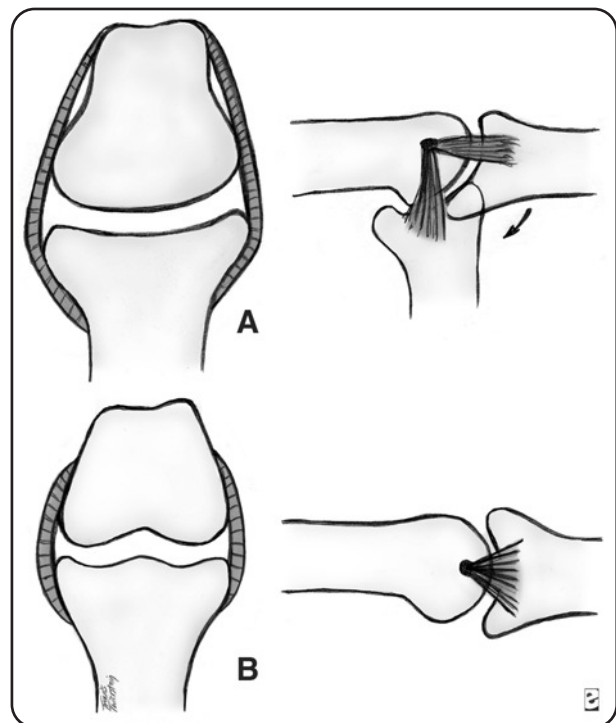


Fig. (3): Collateral ligaments of the PIN in flexion and extension [19].

*Joint pathology:* Edema is the initial response to hand burn (Fig. 4) and leads to adverse sequelae. Joint stiffness develops as intra-articular hematoma and fluid accumulate within the synovial space, distending the capsule. Increased fluid content within the articular capsule and collateral ligaments effectively shortens these structures, favoring extension. The fluid in the joint space also serves to hydraulically drive the MCPJ into extension. That's to be concluded that in MCPJ extension, the joint is able to accommodate this increased fluid capacity. As the MCPJ joints extend, the flexor tension on the IPJ increases and the extensor tension decreases. This causes the PIPJ and DIPJ to flex. The resultant late deformity is the intrinsic minus (or intrinsic negative) hand, consisting of MCPJ joint extension, IPJ flexion, thumb adduction, and wrist flexion [20].

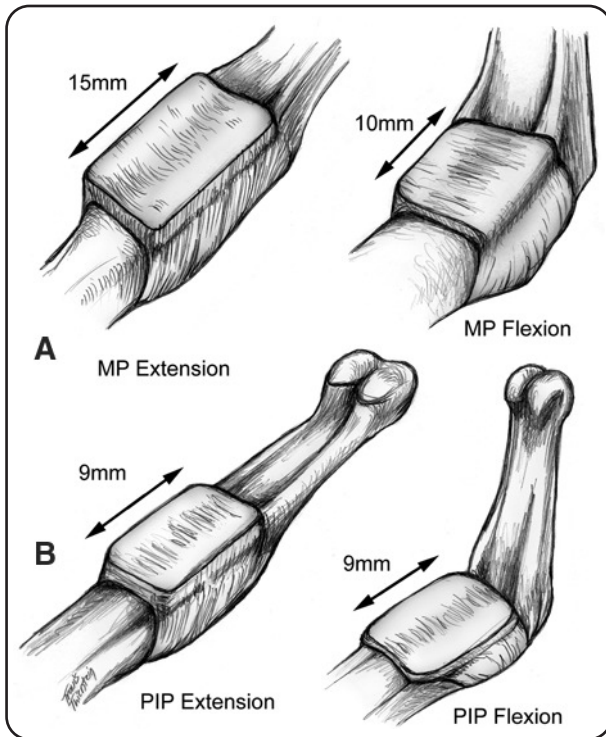


Fig. (4): Oedema is the initial response to hand burn, increased fluid content within the articular capsule and collateral ligaments effectively shortens these structures, favoring MPJ extension [20].

With injury, checkreins form at the IPJ (Fig. 5). Checkreins are collagenous bands connecting the lateral sides of the proximal volar plate to the assembly lines on the volar lateral surfaces of the phalanx. Assembly lines are the 2 ridges along the volar lateral surfaces of the phalanx to which are attached volar ligamentous structures such as the flexor sheath, Cleland and Grayson ligaments, and the oblique retinacular ligaments of Landsmeer. The volar plate pocket behind the MCPJ volar plate

is smaller than at the IPJ, and checkreins do not develop at the MCPJ (Fig. 5) [21].

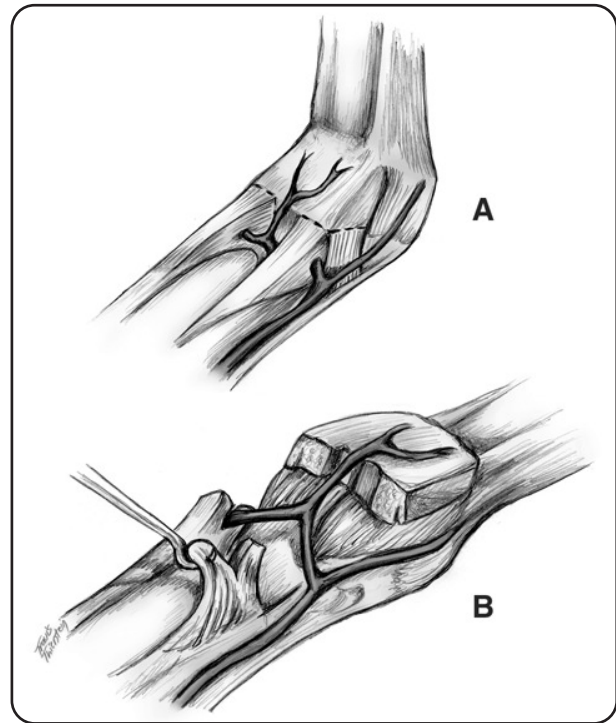


Fig. (5): With injury, checkreins form at the IP joints connecting the lateral sides of the proximal volar plate of the phalanx.

Thus, oedema developed during the first 48 hours will develop in favor of the intrinsic minus position, and the oedema components will lead to later organization and hence a fixed intrinsic minus deformity will develop [22].

For this reason, early oedema prevention by hand elevation with proper positioning and splinting of the hand during the initial 48 hours is essential to prevent the intrinsic minus deformity. Positioning is maintained by volar splinting of the MCPJ, PIPJ, and DIPJ in the intrinsic plus position (MCPJ in 90° degrees of flexion, PIPJ, and DIPJ in extension) to maximally stretch the collateral ligament. The wrist is extended for 70° to 80° degrees to pull the MCPJ and IPJ to the safe intrinsic plus position. The thumb is kept in abduction. The splints is secured to the over the burn dressing with straps, helping further odema minimization. After the initial 48 hours, the wrist is splinted to 30° degrees of extension [2].

**PATIENTS AND METHODS**

Fifty patients with acute hand burn was included in this study. Thirty patients were males, and twenty were females. The patients' age ranged from 19-48 years, while children were excluded from the

study. Twenty six patients were manual workers. The burn percent of the included cases ranged between 1% and 15%, and higher percents were excluded to concentrate the management of the burned hand rather than the general state of the patient (although initial resuscitation was done for all patients as in major burns).

Regarding depth of burn, ten patients with superficial burn, twenty four patients with deep partial thickness, and sixteen patients with deep full thickness burn. Forty patients were admitted (those were the patients with deep partial or full thickness burn). All the patients were photographed on the initial presentation, during the healing process and follow-up, and after complete healing.

Each patient was subjected to the following management protocol: In all patients, the first step was assessment of the vital signs including airway, breathing, and circulation to ensure the patients' stability. All patients received a dose of strong intravenous analgesia. Circulation of the hands was assessed by evaluation of both radial and ulnar pulses by palpation at the time of the initial evaluation and hourly thereafter. Escharotomy was done for six patients, in which the hand was manifested with pulse changes or loss (in case of circumferential burn), it was done using sterile surgical scalpel at bedside. The arm was placed in the anatomical position and elevated above the level of the heart, aiming to minimize oedema formation.

After that, the hands were cleansed by sterile water or saline, evacuation of the blisters was done by aspiration of the fluid leaving the skin to act as an autogenous burn dressing. Hands with clear superficial burn, silver sulfadiazine 10% cream were applied. Patients with intermediate burn were covered by alternating chemotherapeutic agents; silver nitrate 0.2% cream (Nitrofurzone®) at night. Burns that were clearly full thickness were treated with twice daily silver nitrate 0.2%. The hands then were covered by Vaseline gauze tulle with exposure of finger tips and separation between fingers.

The hands were initially splinted using a static volar splint extending from the forearm to the proximal interphalangeal joints (PIPJ), maintaining the wrist in 70° to 80° degree of extension, and the metacarpophalangeal joints (MCPJ) maintained at 90° degree of flexion, the interphalangeal joints (IPJ) in extension, and the thumb was abducted and the first web-space opened. After 48 hours,

the wrist extension is decreased to 30° degree of extension.

Later on, further cleansing of the hand was done twice daily with sterile saline followed by application of the local chemotherapeutics. In all cases with deep burn, a broad spectrum antibiotics was administrated in the form of benzyl penicillin two-million units every six hours after performing sensitivity test.

Physiotherapy was done for all cases with deep partial or full thickness burn. During the acute stage, in the form of hydrotherapy and ultrasonic pulsed or continuous waves. The usual daily activity started from the first day. Later on, active and passive exercises were performed. Pressure therapy in the form of pressure garments was applied for sixteen patients, and silicon sheets were prescribed for eight patients.

Discharge of patients was done after complete healing. Follow-up was done for 3-6 months, during which physiotherapy was continued together with clinical assessment of hand function (in the form of free and painless hand movement, buttoning, unbuttoning, hair combing, tying shoes, power grip, pinch grip, and hook grip).

## RESULTS

From this study, it was found that males were more than females. The commonest age group was between 26 years and 35 years. All cases were of a lower socioeconomic status. In most cases, direct flame burn was the cause of injury (42 patients). More than 50% of patients were manual workers (26 patients). Most patients were suffering from isolated hand burn (intentionally selected). Twenty four patients were having deep partial thickness burn, while sixteen patients were having full thickness burn. Forty patients presented on the day of burn, and two cases presented 2-3 days later. A single case was having an associated injury in the form of fracture of the proximal ulna. Healing time ranged between one and five weeks, in 48%, complete healing was achieved within 2 weeks and in 24% it was extended to 4-5 weeks. Forty patients was subjected to physiotherapy program (only superficial burn cases were not subjected to physiotherapy). Escharotomy was done for six cases, representing about 12%. Complications were in the form of mild degree of infection in 28 cases, that has no effect on the final outcome, 2 cases suffered from grade I hyperextension deformity of the MCPJ, and 12 female patients were not satisfied by the cosmetic appearance. No case suffered from functional disability (Table 1).

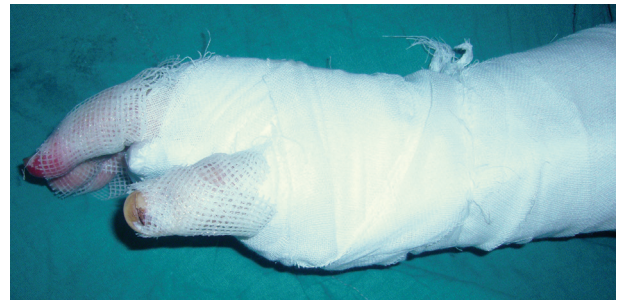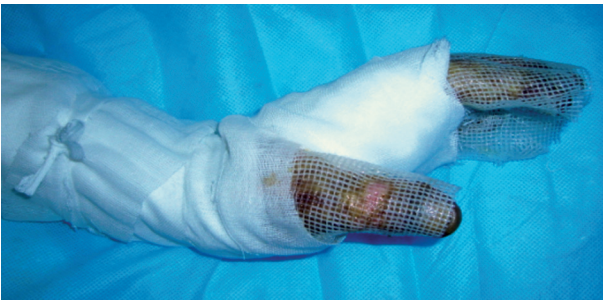

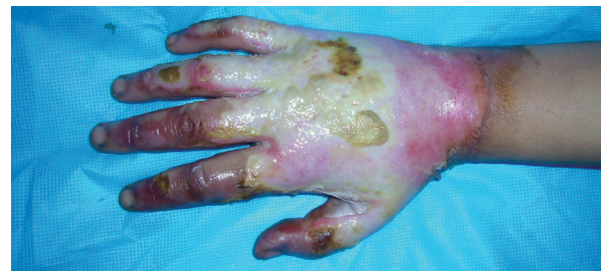
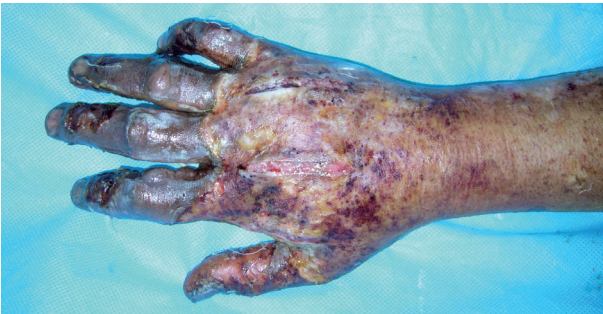Fig. (6): Hand positioning in a volar splint after the usual occlusive dressing.

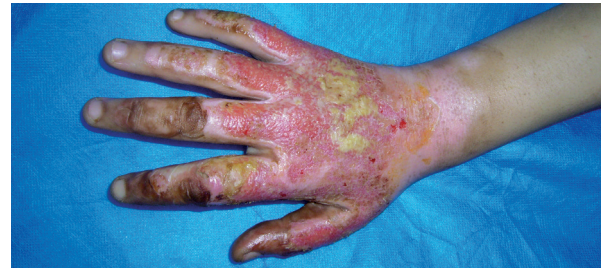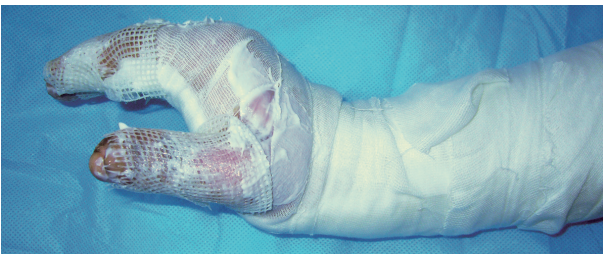Case (1): A deep hand burn in a male presented 2 days after-direct flame burn.

Case (2): Hand of a female patient with a deep burn caused by a scald burn.



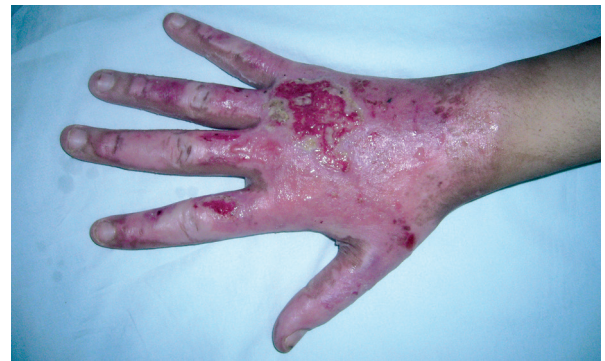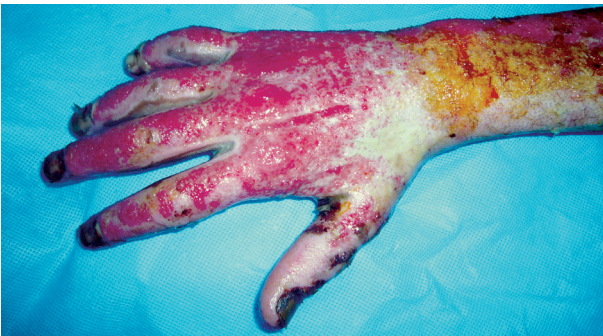A- Escharotomy incisions can be seen.

A- Immediately after burn.



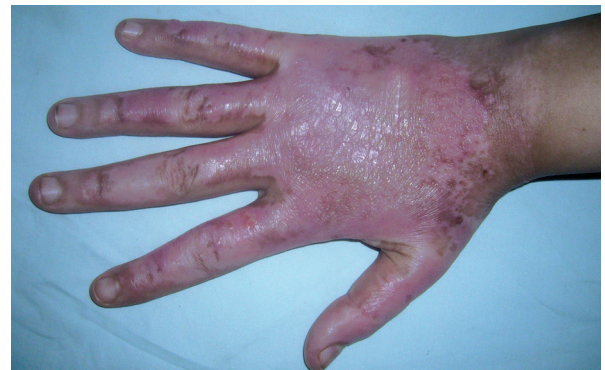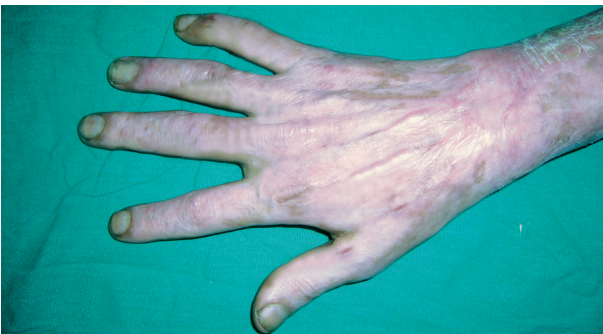B- Hand is splinted by a volar splint wrist 80°, MCPJ 90°, IPJ extended thumb abducted, 1<sup>st</sup> web space opened.

B- Same hand after 2 weeks.



C- Same hand 2 weeks later.

C- After 3 weeks.



D- After complete healing without grafting. Note healing of escharotomy incisions.

D- After 5 weeks with complete healing.

Table (1): Complications of the studied cases.

Complications	Infection	Poor cosmetic appearance	Grade I MCPJ hyperextension	Functional disability
Yes	28	12	2	–
No	22	38	48	50
Total	50	50	50	50

## DISCUSSION

Intrinsic minus deformity of the hand is the commonest deformity following hand burns. In spite of this fact, it can be easily prevented by simple maneuvers based on simple facts. First, it is essential to know that the collateral ligaments of the metacarpophalangeal joint (MCPJ) is the most important structure affecting the fate of a burned hand. Keeping this ligament lax allows for accommodation of more fluid in the synovial capsule of the MCPJ [2]. The second fact is the role of oedema in development of a further deformity. As the resultant oedema that follows burns accommodate in the position of rest of the hand, such oedema will organize later due to its constituents leading to development of a later intrinsic minus deformity [22]. Understanding of these facts helped in finding the simple methods for deformity prevention. The first issue can be counter-acted by reversing the intrinsic minus position by flexing the MCPJ 90 degree and extending the IPJ and static splinting the hand in that position (intrinsic plus position) thus allowing for stretch of the collateral ligaments of MCPJ preventing accommodation of more fluid. This is superadded with exaggerated wrist extension (70-80 degrees) during the first 48 hours, thus helping to pull on the MCPJ and the PIPJ in the safe intrinsic plus position. Later on, the patient is encouraged to use the hand for self-care activities. The second issue is preventing as possible early oedema, this can be done by hand elevation, strapping the volar splint around the forearm and hand, thus minimizing the oedema development. Also, the position of the splinted hand by itself prevent excess fluid accumulation. The role of physiotherapy cannot be missed in prevention of intrinsic minus deformity. It has a major impact on hand function following thermal injuries, and proper hand therapy is more important than surgical or non-surgical utilized methods to address the wound itself. Physiotherapist should evaluate the patient within 24 hours of admission if not on the first day of admission [23]. Early-on the course of therapy, the authors impress upon their patients

that the role of the burn team is to re-establish the normal anatomy of the hand. Re-establishment of function is the responsibility of the patient and is directly dependent upon the effort extended during physical therapy sessions. In practical terms, the function present post-injury is likely what the patient will live with for the rest of his or her life [2].

*As a conclusion:* Hand burn and subsequent deformity is an injury of the working class with major potential for disability. This may affect the whole community in regard economics and development. The proper management of acute hand burns is the cornerstone in preventing intrinsic minus deformity of the hand, and this needs a multidisciplinary approach requiring the expertise of surgeons, nurses, and physiotherapists.

Our recommendations for prevention of post-burn intrinsic minus deformity of the hand is early proper therapy, oedema control, adequate hand position and splinting until complete healing.

## REFERENCES

- 1- Rossiter N.D., Chapman P. and Haywood I.A.: How big is a hand? Burns; May, 22 (3): 230-1, 1996.
- 2- David J.B. and Stephan M.P.: Management of Burns to the Hand, Wounds, 15 (1): 4-9, Health Management Publications, Inc., 2003.
- 3- John H., Gary P. and Ross Z.: Acute Burns, Burn Surgery, and Postburn Reconstruction, Selected Readings in Plastic Surgery, Vol. 9, Number 12, Baylor University Medical Center, 2000.
- 4- Robson M.C. and Smith D.J.: Burned hand. In: Plastic Surgery: Principles and Practices, Jurkiewicz M.J. (ed), St Louis, MO: C.V. Mosby Co., 1990.
- 5- Anzurant W.J., Chen M., Shankowsky H. and Tredget E.: Quality-of-life and outcome predictors following massive burn injury, Plast. Reconstr. Surg., 116 (3): 791-7, 2005.
- 6- Salisbury R.E.: Burns of the upper extremity. In: "Burns: A Team Approach", Artz C.P., Moncrief J.A., Pruitt B.A. (eds), W.B. Saunders, Philadelphia, 320-9, 1979.
- 7- American Burn Association: Advanced Burn Life Support Course. Chicago, IL: American Burn Association, 2001.
- 8- Belcher H.: Hand Burns, <http://www.pncl.co.uk/~belcher/teaching/burns.htm>, 1995.
- 9- Ahuja R. and Bhattacharya S.: Burns in the developing world and burn disasters, BMJ, 329: 447-449 (21 August), 2004.
- 10- Gokalan L., Ozgor F., Gursu G. and Kecik A.: Factors affecting results in thermal hand burns, Annals of Burns and Fire disasters, Vol. IX, N. 4, December, 1996.
- 11- Roje Z., Petricevic, Roje Z. and Karanovic N.: Deep Burns of the Hand: Preference and Quality of Mesh over Sheet

- Skin Grafts, *Annals of Burns and Fire Disasters*, Vol. XVI N. 2, June, 2003.
- 12- Heimbach D., Engrav L., Grube B. and Marvin J.: Burn depth: A review. *World J. Surg.*, 16: 10, 1992.
- 13- Arturson M.G.: The pathophysiology of severe thermal injury, *J. Burn Care Rehabil.*, 6: 129, 1985.
- 14- Peterson R.A. (1990): Electrical burns of the hand. *J. Bone and Joint Surg.*, 48A: 407-24, 1966.
- 15- Neville R.M. and Boswick J.A.: The management of electrical injuries of the extremities. *Surg. Clin. North Am.*, 53: 1459-68, 1973.
- 16- Hunt J.L., Mason A.D. and Pruitt B.A.: The pathophysiology of acute electrical injuries. *J. Trauma*, 16: 335-43, 1987.
- 17- Gobet R., Raghunath M. and Altermatt S.: Efficacy of cultured epithelial autografts in pediatric burns and reconstructive surgery. *Surgery*, 121: 654, 1997.
- 18- Brody G.S.: Management of stiff metacarpophalangeal and interphalangeal joints. In: McCarthy J.G., May J.W. Jr., Littler J.W., eds. *Plastic Surgery*. Vol 7. The Hand, Part 1. Philadelphia, Pa: WB Saunders, Co., 4655-4670, 1990.
- 19- Bowers W.H., Wolf J.W., Nehil J.L. and Bittinger S.: The proximal interphalangeal joint volar plate. I. An anatomical and biomechanical study. *Am. J. Hand Surg.* Jan., 5 (1): 79-88, 1980.
- 20- Jessica G.: Why Intrinsic Plus Position is the safe position?, In: *Intrinsic Plus Hand*, Michael S.C., Homas R., Hunt III, Rancisco T., Dinesh P. and Harris G. (eds), Nov., 16, In: <http://www.emedicine.com/orthoped/topic507.htm>, 2005.
- 21- Smith R.J.: Intrinsic Contracture. In: Green D.P., ed. *Green's Operative Hand Surgery*. 4<sup>th</sup> ed. Philadelphia, Pa: Churchill Livingstone, 604-618, 1999.
- 22- Nossier A., Borhan W., Mowafy Z. and Khalaf M.: Physical therapy modalities to manage burn cases, In: *Rehabilitation of Burn Injuries*, 2<sup>nd</sup> edition, Nossier A., Borhan W., Mowafy Z. and Khalaf M. (eds), Page 56-79, Tiba Press, 2004.
- 23- Achauer B.M.: *Burn Reconstruction*, New York, NY: Thieme Medical Publishers, 1991.