

## The Extended Latissimus Dorsi Flap in Breast Reconstruction: Technical Refinements

NASSER A. GHOZLAN, M.D.\*; NABIL S. BAHNASY, F.R.C.S.\*\* and MOHSEN K. ABO EL-DAHAB, M.D.

*The Department of Plastic and Reconstructive Surgery\*, Faculty of Medicine, Alexandria University and Alexandria Medical Centre\*\*.*

### ABSTRACT

In this study, we evaluated our institutional experience with the extended latissimus dorsi flap for breast reconstruction to better understand its indications, limitations, complications, and clinical outcomes. During a 3-year period (2004-2007), 15 extended latissimus dorsi myocutaneous flap breast reconstructions were performed, 14 for delayed unilateral post mastectomy breast reconstruction, and one for a patient with Poland's syndrome. Patient's age ranged from 16-57 years with an average age of 46.3 years. Complications developed in 4 patients (26.7%). Flap complications occurred in 2 patients. One patient developed partial flap loss because of fat necrosis resulting in partial wound disruption that was managed conservatively. In another patient, partial injury of the vascular pedicle occurred during its dissection. The flap suffered marked congestion in the immediate post-operative period. The congestion resolved within a week and resulted only in a small area of superficial necrosis that healed spontaneously. Donor-site complications included donor site wound necrosis in one patient due to overthinning of the lower skin flap that was also managed by conventional dressings, and one case of donor site seroma that required aspiration.

The aesthetic results were evaluated as 'good' for twelve patients, 'fair' for two other patients, and 'poor' for one case. The contour change on the back region was insignificant in eleven cases, and noticeable in four others. Three patients mentioned reduced soft tissue padding on the back, yet the condition was not serious enough to cause discomfort during sleep. There were no complaints about disturbance of upper limb function or limitation of shoulder joint movement on the operated side.

In conclusion, our preliminary experience reconfirms those reported with the extended latissimus dorsi flap breast reconstruction. With the described technical refinements the flap can offer sufficient volume and shape to provide good aesthetic result in most patients with minimal flap and donor site complications. The extended latissimus dorsi flap is a reliable method for total autologous breast reconstruction in most patients and should be considered more often as a primary choice for breast reconstruction.

### INTRODUCTION

Breast reconstruction is an essential part of the multidisciplinary treatment of breast cancer. The latissimus dorsi myocutaneous flap was one of the

first methods of breast reconstruction described. It was used as early as 1906 by the Italian surgeon Tansini [1-3].

However, with the increasing popularity of transverse rectus abdominis musculocutaneous (TRAM) flap breast reconstruction in the mid-1980s and early 1990s [4,5], the latissimus dorsi (LD) flap was gradually driven to the back seat becoming a secondary choice for autologous breast reconstruction. One reason for this has been that the standard LD flap alone often does not provide sufficient volume for breast reconstruction. In fact, it is a common practice to combine the LD flap with an implant to achieve adequate breast volume [6].

With all its merits however, the TRAM flap also has limitations. Complications such as abdominal weakness or flap necrosis remain a constant threat, especially among obese individuals [7,8]. Furthermore, for patients with multiple previous abdominal incisions, patients suffering from chronic back pain, or young women expecting pregnancy in the future, this operation is problematic. For such cases, the latissimus dorsi flap is a valuable alternative, which would be even more satisfactory if the tissue bulk of the flap could be increased to reduce the need for an alloplastic implant [9].

Variations of the LD flap have been described to increase the volume and avoid the addition of an implant. The first "extended" LD flap was described by Hokin [10,11], and included lumbar fat extensions of the LD flap. Marshall et al. [12] published a T-shaped flap design. Papp et al. [13] suggested harvesting the maximally available skin paddle and using the de-epithelialized dermal-fat pad to augment the tissue bulk. McCraw and Papp [14] modified this technique by using a fleur-de-lis skin paddle design to carry additional fat on the surface of the LD muscle, creating the totally

autogenous LD breast reconstruction. The design of an extended LD flap has further evolved to include the parascapular and scapular "fat fascia" in addition to the lumbar fat for additional volume [15,16].

The concept of an extended latissimus dorsi (ELD) flap has added new dimensions to the use of this flap and helped further its resurgence. In the present study, the role of ELD flap in breast reconstruction will be evaluated to better understand its indications, limitations, complications, and clinical outcomes.

### PATIENTS AND METHODS

The present study included 15 patients who underwent breast reconstruction using an extended latissimus dorsi myocutaneous flap.

Patients were admitted to the Plastic and Reconstructive Surgery Unit of the Alexandria Main University Hospital and the Alexandria Medical Centre through the years 2004-2007.

#### *Preoperative planning:*

The markings were performed with the patient standing. The boundaries of the mastectomy defect were defined and drawn (Figs. 1A, 2A). Provided the mastectomy scar was not too high, it was usually marked for excision to recreate the mastectomy defect (Fig. 2A). Otherwise, the skin paddle was inset in such a way to preserve maximum natural breast skin cover for the new breast in the cleavage area (Fig. 1A). A mirror image of the contralateral inframammary crease was marked on the mastectomy side.

In relation to the other breast, the dimensions of the missing skin segment on the mastectomy side were determined. This should take into account the retraction of the mastectomy skin flaps after excision of the scar

#### *Flap design:*

A horizontal line was drawn in the dorsal bra line. The largest available ellipse-shaped transverse skin paddle allowing primary closure of the donor site was marked out along this line to conceal the scar (Figs. 1-3B). The skin defect after raising the ELD flap must be able to be closed with relative ease. The size of the skin paddle usually ranged from 6-10cm wide and from 20-25cm long, depending on the patient's body habitus. The flap extended from near the posterior axillary fold to the vicinity of the spinous process. The skin island may be extended 5-7cm over the anterior edge of the latissimus dorsi without compromising its blood

supply [11]. The position of the skin island can be moved within the scar "concealment" area" to vary the dimensions of the flap above and below or in front and behind the skin paddle according to the needs of the mastectomy defect.

The peripheral limits of the ELD were then determined and marked on the surface (Figs. 1-3B). Two areas of fat were included with the flap; the scapular fat that overlies the trapezius muscle above the superior border of the LD, and the fat above the iliac crest [17,18].

#### *Operative technique:*

The patient was first positioned supine with the arms in a comfortable abduction position. The old mastectomy scar was excised and the mastectomy skin flaps were dissected to recreate the mastectomy defect and the breast pocket. Care was taken with the dissection of the inferior flap toward the inframammary crease which was kept symmetrical with the other side.

After the dissection of the mastectomy site was completed, attention was diverted to the axilla and lateral chest wall with the patient still in the supine position. Just above the lateral end of the inframammary fold, the plane between the LD and serratus anterior (SA) muscles was entered. The two muscles were separated superiorly to reach the level of the bifurcation of the thoracodorsal vessels and inferiorly to below the angle of the scapula. The lateral border of the LD muscle in the axilla was then identified and dissected free from the subcutaneous tissues from slightly below the level of bifurcation and superiorly for about 5-6cm above it. The fibrofatty tissue in front of this part of the muscle contains the main thoracodorsal pedicle. Close dissection of the pedicle is not necessary and must be avoided. The fascia over the anterior surface of the LD muscle and the tissues containing the neurovascular pedicle were dissected free from the muscle superiorly for 3-5cm and a safe loop of narrow surgical swab was passed around it to lift it up while the plane between the LD and teres major (TM) muscles was identified and the two were separated. This preparation was necessary to facilitate the division of the muscle to island the flap.

Bevel islanding of the muscle was then performed starting 1cm above the entry of the protected pedicle into the muscle and progressively slanted in an inferioposterior direction to completely divide the muscle in a beveled fashion toward the inferior angle of the scapula [18]. After the muscle division was achieved, a surgical swab was left between the

two surfaces of the divided muscle to protect the pedicle when the axilla is approached from the back.

The chest wound was closed with staples temporarily and dressed to allow for a change of position for the next stage of the dissection to raise the flap. The patient was then put in a lateral position, and the arm on the reconstruction side was rested on an arm rest, level with the shoulder in about 90 degrees of flexion.

The extended latissimus dorsi flap elevation was begun by incising around the skin island. The wound was deepened with cutting diathermy until the distinct dorsal thoracic fascia was identified [19]. The dissection of the flap was either carried superficial or deep to this fascia (Fig. 1C).

The dissection of the back skin was continued in this plane until the peripheral limits of the flap were reached as marked on the skin. The dissection was carried inferiorly to the iliac crest and superiorly to the teres major muscle. The dimensions of the fat and fascial extension above the superior border of the latissimus dorsi muscle can vary, spanning from the midline to the posterior axillary fold and up to 10cm above the superior border of the latissimus dorsi muscle (Fig. 1D) [18].

The flap was rotated 180 degrees and passed under the skin tunnel to the mastectomy site. The medial end of the skin ellipse was rotated in a clockwise direction on the left side and in a counterclockwise direction on the right side.

A quilting technique was applied to close the back to eliminate seroma formation [20]. One suction drain was inserted. The skin edges were closed in layers with buried monofilament absorbable sutures. The patient was then returned to the supine position for inseting and shaping of the flap to create the breast mound.

#### *Inseting of the flap:*

The most proximal part of the muscle, which is the thinned beveled edge of the muscle at the entry of the neurovascular pedicle was advanced toward the lateral border of the pectoralis major muscle and fixed with two stitches away from the pedicle. Each ELD shaping is different, and there is no standard all-purpose shaping technique. However, the shaping was always performed with the patient in the upright position, using the opposite breast as a model.

Typically, the proximal part of the muscle was used to restore the anterior axillary fold and the upper breast fullness. The free anterior margin of

the muscle was attached progressively to the clavicular fascia and sternum to prevent early sagging of the flap. If necessary the distal end of the LD was folded under itself in the lower breast to increase projection. Care was taken to recreate a posterior lateral breast border. This border should join the inframammary fold in a gentle curve, giving the breast a rounded shape. The skin paddle was inset in such a way as to preserve maximum natural breast skin cover for the new breast in the cleavage area and to produce a natural profile.

Once reshaping of the flap was achieved, two suction drains were inserted, one draining the axilla and the lateral aspect of the breast, and the other draining under the flap and the inframammary fold area. Final skin closure was achieved in layers with buried absorbable sutures.

Patients were followed-up for a period that ranged from 6 months up to three years. Contralateral breast reduction or mastopexy was done when indicated at least six months following the reconstruction. The aesthetic result of the reconstruction was evaluated. The evaluation results were rated as good, fair or poor. A good result was a symmetrical appearance with similar size and shape of both breasts; a fair result showed a moderate disparity in size or shape which could be easily camouflaged by clothing or was even negligible; a poor result reflected an objectionable appearance or ugly scarring which might require further corrective surgery.

## RESULTS

During the 3-year study period, 15 extended latissimus dorsi myocutaneous flap breast reconstructions were performed, 14 for delayed unilateral post mastectomy breast reconstruction, and one for a patient with Poland's syndrome. In the patient with Poland's syndrome the reconstruction was combined with a silicone breast implant, while in the remaining 14 patients it was totally autologous. Patient's age ranged from 16-57 years with an average age of 46.3 years.

The reasons for selecting the ELD for breast reconstruction in our study group included patients who wished to have autologous breast reconstruction but who were poor candidates for the TRAM flap or patients who simply did not desire to have TRAM flap breast reconstruction (Table 1).

Complications developed in 4 patients (26.7%). Flap complications occurred in 2 patients. One patient developed partial flap loss because of fat necrosis resulting in partial wound disruption that

was managed conservatively (Fig. 3C). In another patient, partial injury of the vascular pedicle occurred during its dissection. The flap suffered marked congestion in the immediate post-operative period. The congestion resolved within a week and resulted only in a small area of superficial necrosis that healed spontaneously. Donor-site complications included donor site wound necrosis in one patient due to overthinning of the lower skin flap that was also managed by conventional dressings, and one case of donor site seroma that required aspiration.

The aesthetic results were evaluated as ‘good’ for twelve patients (Figs. 2,4), ‘fair’ for two other patients, and ‘poor’ for one case (Fig. 3). The contour change on the back region was insignificant in eleven cases, and noticeable in four others. Three patients mentioned reduced soft tissue padding on the back, yet the condition was not serious enough to cause discomfort during sleep. There were no complaints about disturbance of upper limb function or limitation of shoulder joint movement on the operated side.

Fig. (1): 50 years old female patient with right mastectomy (high mastectomy incision)

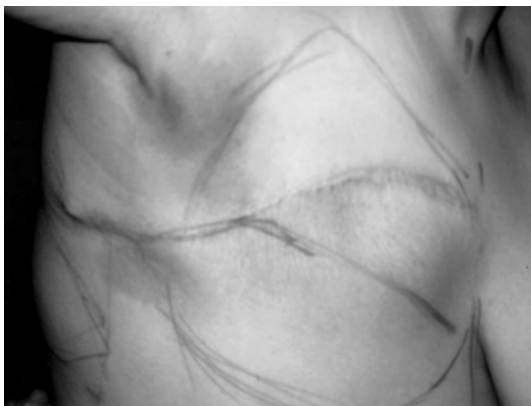

Fig. (1-A): Boundaries of the mastectomy defect defined and drawn.

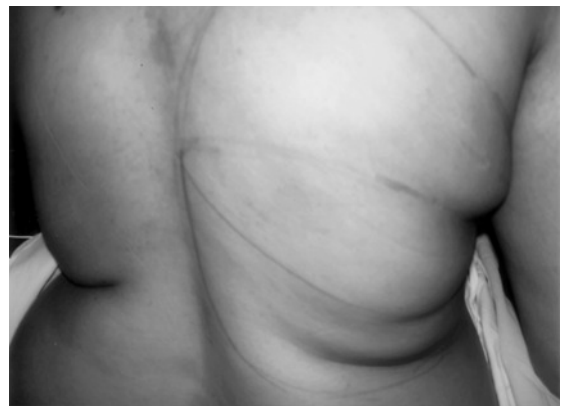

Fig. (1-B): Design of the ELD flap.

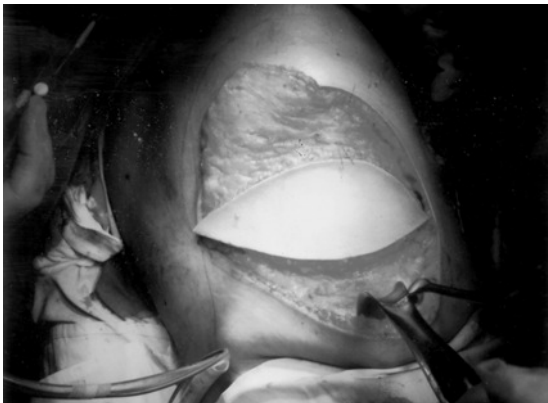


Fig. (1-C): Dissection of the flap at the level of dorsal thoracic fascia.

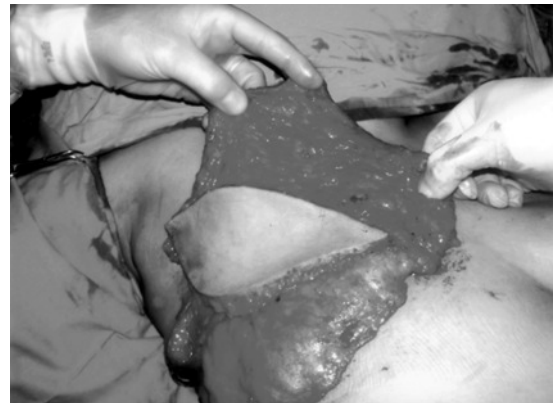

Fig. (1-D): Complete raising of the flap.

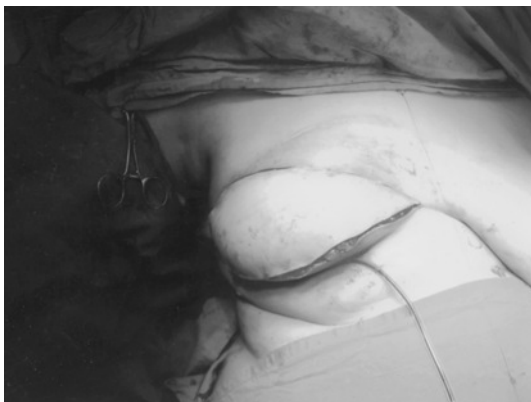


Fig. (1-E): Insetting of the flap.

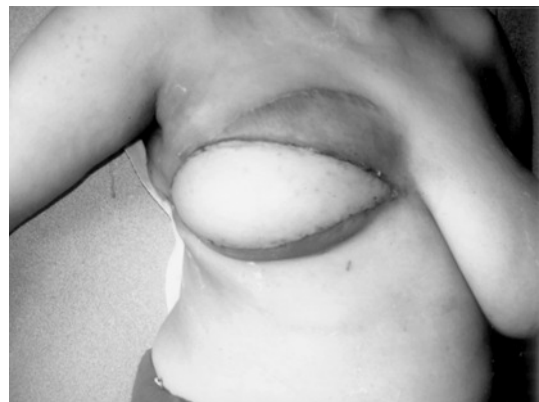

Fig. (1-F): Early post operative view.

Fig. (2): 31 years old female patient with right mastectomy.

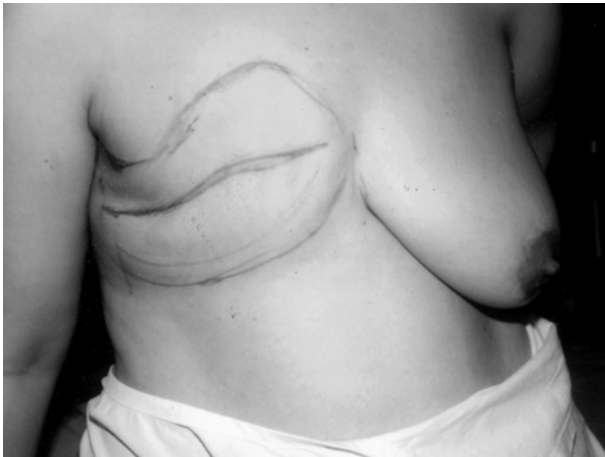

Fig. (2-A): Boundaries of the mastectomy defect.

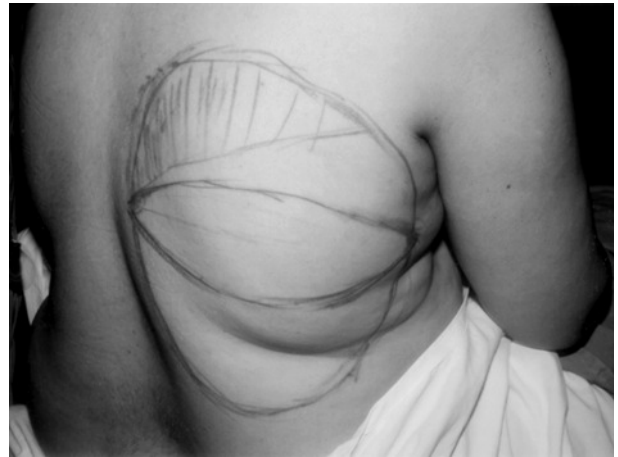


Fig. (2-B): Design of the ELD flap.

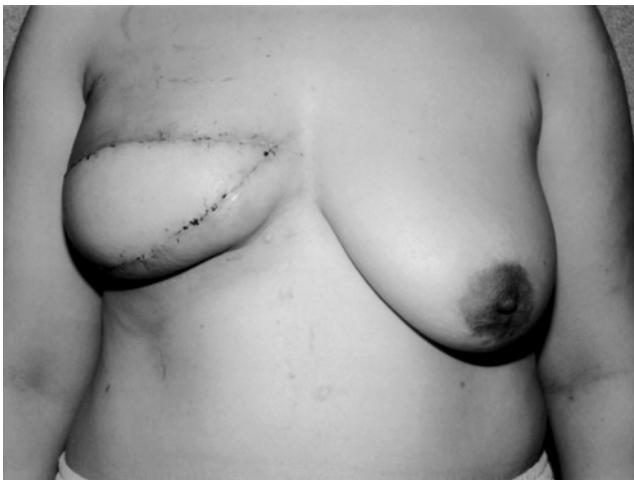

Fig. (2-C): Early post operative.

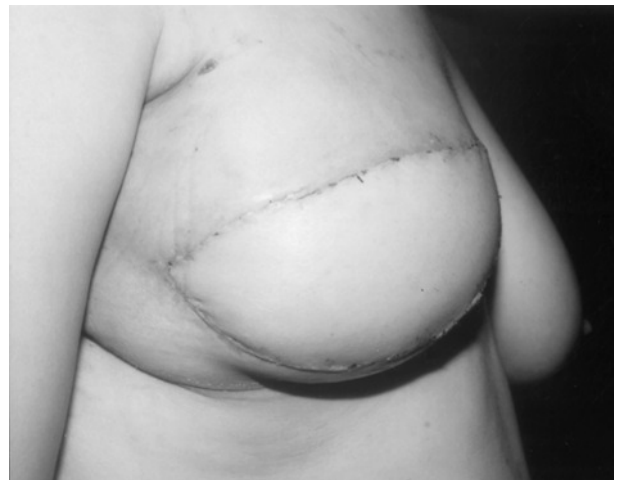

Fig. (2-D): Lateral view.

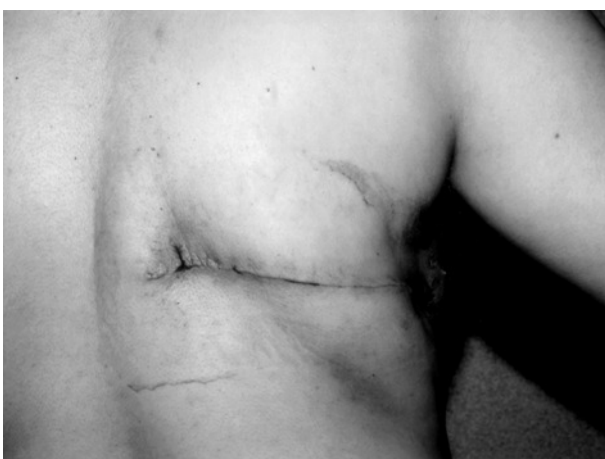

Fig. (2-E): Donor site scar.

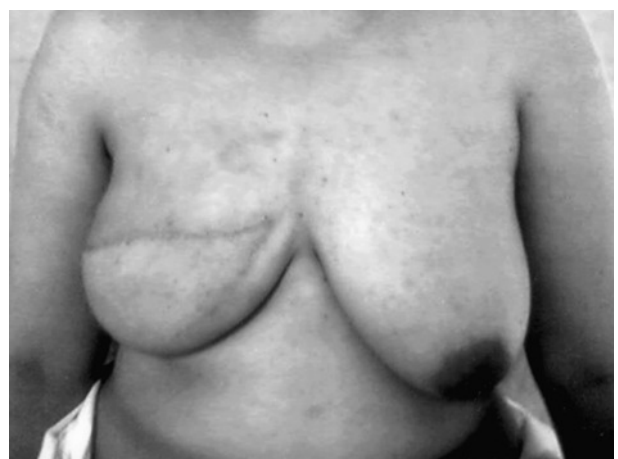

Fig. (2-F): Late post operative view.

Fig. (3): 27 years old female patient with left mastectomy.

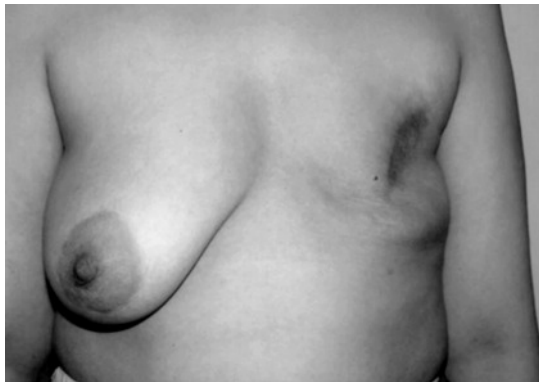

Fig. (3-A): Pre operative view.

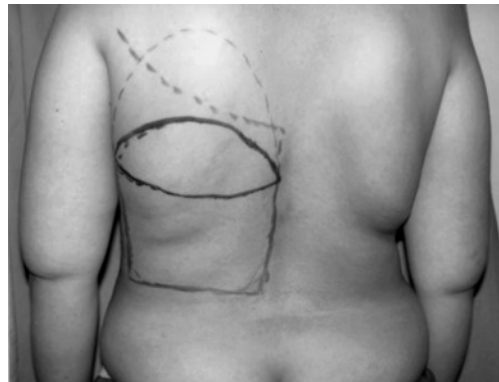

Fig. (3-B): Design of the ELD flap.

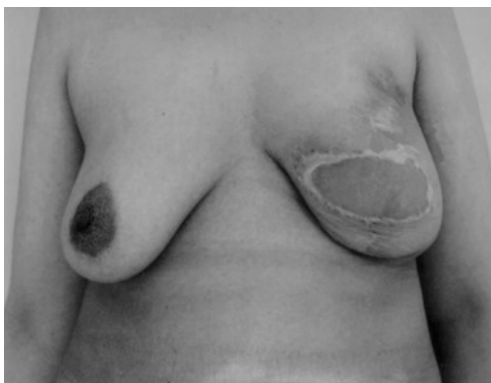

Fig. (3-C): Late post operative view. (partial flap necrosis with spontaneous healing).

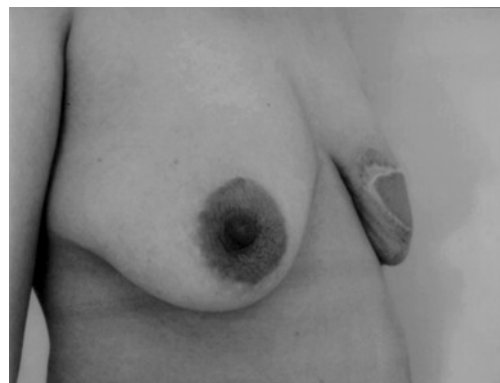

Fig. (3-D): Lateral view.

Fig. (4): 34 years old female patient with left mastectomy.

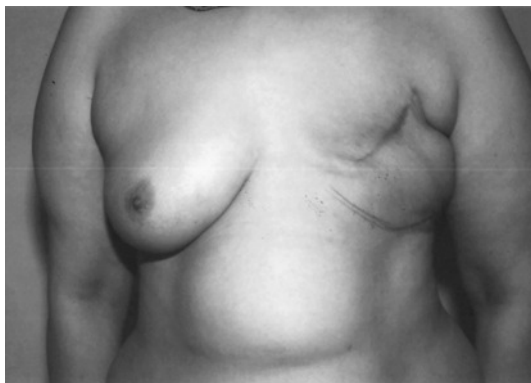

Fig. (4-A): Pre operative view.

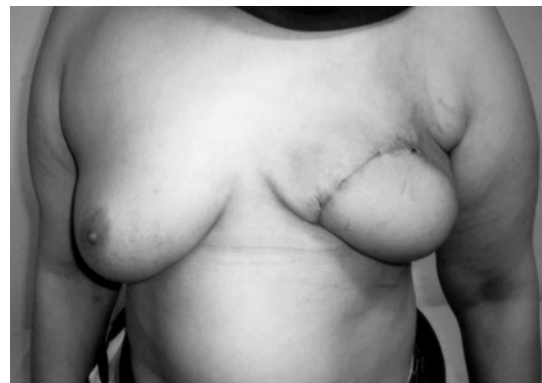

Fig. (4-B): Early post operative.

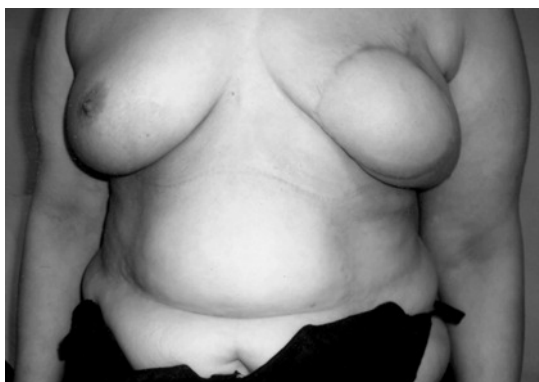

Fig. (4-C): Late post operative.

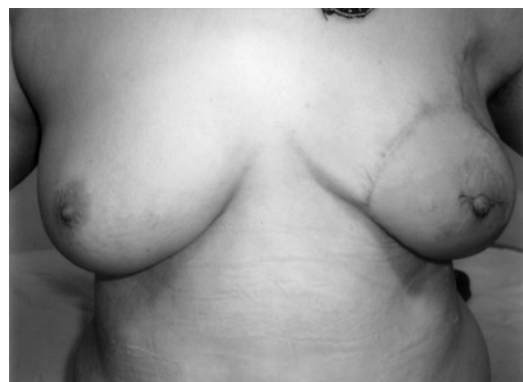

Fig. (4-D): After nipple reconstruction.

Table (1): Reasons for selecting the ELD flap for breast reconstruction

Reasons	No. of patients
Patient preference	5
<i>Poor candidate for TRAM flap:</i>	
Obesity	5
Thin	1
Previous abdominal surgery	2
Advanced age	1
Salvage procedure	1
Total	15

## DISCUSSION

Currently, autogenous tissue transfer is widely accepted as the first choice for post-mastectomy breast reconstruction. The transverse rectus abdominis musculocutaneous (TRAM) flap, with its abundant tissue bulk, has become the gold standard for breast reconstruction since the 1980s [21,22].

However, there remains a considerable number of patients who are not suitable for the TRAM flap procedure. Such were the cases in our series. Of the 15 cases, four were unmarried ladies; one was newly married and wished to have children. Nine patients were considered poor candidates for the TRAM flap, while in one patient it was carried out as a salvage procedure after partial loss of a pedicled TRAM flap.

Chang et al. [6] evaluated their experience with 75 ELD flap breast reconstructions. They stated that the most common use of the ELD flap for breast reconstruction has been in patients who wish to have autologous tissue reconstruction but are less-than-ideal candidates for a TRAM flap. These include patients who do not have adequate abdominal tissue because they are too thin or have had previous abdominal surgery with resulting abdominal scars that preclude the use of a TRAM flap. However, many of their patients had breast reconstruction with the ELD flap because they were considered to be high-risk patients for TRAM flap reconstruction. In 20 patients, the primary reason for performing an ELD flap reconstruction was that patients were considered too obese for the TRAM flap (body mass index greater than or equal to 30kg/m<sup>2</sup>).

Several different skin paddle designs for the ELD flap have been described. The fleur-de-lis skin paddle design was initially described by McCraw et al. [14]. A superior extension increases the

amount of skin harvested with the flap while allowing primary closure of the donor site. However, the fleur-de-lis skin paddle has been mostly abandoned because of resulting extensive scarring of the donor site [6,17]. Some have advocated the use of crescent-shaped skin paddles [23]. The paddle is centered over the fat roll of the back and follows the curve of the ribs throughout its course. This places the donor site closure parallel to the lines of skin tension and to the ribs and improves the appearance of the eventual scar. In this study, a simple ellipse-shaped transverse skin paddle marked out along the bra line was used. Placement of the incision along the bra line helps to conceal the scar [6,18].

Technical refinements of the ELD breast reconstruction included isolating the pedicle and bevel islanding of the flap, identification of the dorsal thoracic fascia and dissection of the flap either superficial or deep to this distinct fascial layer, and adopting the quilting technique for the donor site closure [18,20,24].

The bevel islanding of the muscle allows for better contouring of the posterior axillary fold and the axillary tail of the new breast; it eliminates a bulky stump in the axilla from retraction of a conventionally truncated proximal part of the muscle because its posterior surface remains attached to the skin of the posterior axillary fold [18]. Many surgeons have advocated division of the humeral insertion of the LD tendon and all the branches of the thoracodorsal vessels to improve the excursion and the rotation of the flap and to eliminate a "bulky" stump in the axilla [11,12,18, 23].

On the other hand, Chang et al. [6] debated the necessity for the division of the LD humeral attachment. They stated that, even without the division of the humeral insertion, most ELD flaps have more than adequate excursion to create the breast mound needed. Also except in very thin patients, the LD attachment adds very little noticeable bulk in the axilla, and much of this "bulkiness" decreases as the muscle atrophies with time. Furthermore, when the humeral muscle attachment is divided, the entire weight of the ELD flap may place severe tension on the pedicle, even when the flap is secured to the chest wall. Particularly in patients with large ELD flaps, this tension can be substantial and may lead to pedicle injury. There is also a risk of twisting the pedicle as the ELD flap is passed through the tunnel to the mastectomy site. For these reasons, they stated that division of the humeral attachment of the LD muscle should be considered only when it is necessary to obtain adequate excursion of the

flap to fill the medial and superior cleavage regions or in thin patients where the bulkiness in the axilla may be readily noticeable.

Clough et al. [25] described partial or total sectioning of the LD tendon to increase the mobility of the flap and to provide for easier positioning and shaping. They observed contractions of the reconstructed breast during arm movements in cases in which the tendon had not been completely separated from the humerus. Hence, complete section of the tendon has become their standard protocol.

The division of the thoracodorsal nerve also remains an issue of controversy. Some authors feel that the intact nerve may preserve maximum volume of the flap in the long term. They also argue that because the LD is fixed to the chest wall in a relaxed manner, very little contraction is noticed in the flap postoperatively [18,25]. On the other hand, other authors reported involuntary undesirable breast movements related to this preservation that can be significant and may cause disturbance for many patients. They therefore recommended the division of the nerve [6,23]. Postoperative muscle atrophy of 20 to 25 percent was taken into consideration during the inset of the flap [16,23]. In the present study, the thoracodorsal nerve was preserved to avoid secondary atrophy of the muscle and loss of volume of the flap. None of our patients reported undesirable fasciculations of the muscle.

With extended LD flaps, donor site complications, including seroma and wound necrosis, can be a significant problem [6,11,16,25]. The cosmetic disadvantage of the back must be kept to a minimum and "over harvesting" of tissues and leaving very thin skin flaps must be resisted. Excessive thinning can give the back a skeletonized look and can also lead to insufficient blood supply, with resultant skin necrosis and wound breakdown. In one of our earlier patients we tried to enhance the harvested volume of the flap and we were not careful enough with the fascia superficialis with inadvertent overthinning of the skin. This resulted in a dorsal skin slough. Therefore, it is recommended to leave the dorsal thoracic fascia on the back skin flaps to minimize donor site contour deformity and skin necrosis of the donor site [19]. However, in obese patients, significant added volume can be harvested by dissecting through the fat above this layer and still leaving a thick layer of subcutaneous fat [6,18,25].

There is a relatively high incidence of seroma formation in the donor site of an ELD flap. Chang

et al. [6] reported an incidence of 25.3% with a significantly higher incidence in obese patients (38.6%) with a body mass index greater than or equal to 30kg/m<sup>2</sup>, compared with an incidence of (8.7%) in patients with a body mass index less than 30kg/m<sup>2</sup>. Clough et al. [25] reported the highest incidence of seroma formation (72%), but stated that they did not try to prevent seromas by any of the proposed methods and they simply performed repetitive aspirations, with a satisfactory result. Lee and Chang [9] described the application of multiple bolster sutures with a compressive dressing to avoid this problem. Fatah [18] presented his experience with 118 ELD breast reconstructions and advocated the use of quilting sutures to eliminate the incidence of seromas. In the present study a quilting technique was routinely adopted for the closure of the donor site. Only one patient (6.7%) developed seroma of the donor site.

The aesthetic results were evaluated as 'good' for thirteen patients, 'fair' for two other patients, and 'poor' for one case. The contour change on the back region was insignificant in eleven cases, and noticeable in four others. Three patients mentioned reduced soft tissue padding on the back, yet the condition was not serious enough to cause discomfort during sleep. There were no complaints about disturbance of upper limb function or limitation of shoulder joint movement on the operated side.

Clough et al. [25] presented their long-term functional results after harvest of an extended LD flap for breast reconstruction. No late complications occurred. The quality of the dorsal scar was satisfactory in most of the cases. With the help of a physiotherapist, they could demonstrate that 70 to 87 percent of the patients showed no objective limitation in muscular function. Subjectively, 60 percent of the patients experienced no limitation in everyday life.

The ELD flap is ideal for small and medium sized breasts, and in most patients, the flap can be expected to match the opposite breast of a B or C cup size, without any implant [9-16]. However, the ELD flap can also be used for reconstruction of larger breasts in selected patients. Most women with larger breasts have a heavier build and will have a substantially thicker flap. Nevertheless, a larger breast means a larger flap. Because most of the bulk of an ELD flap is from the fat overlying the LD muscle, with some from beyond the borders of the LD muscle, a higher incidence of fat necrosis is expected in larger flaps [6]. In the present study one patient developed partial flap loss due to fat necrosis.



In summary, our preliminary experience confirms those reported with the extended latissimus dorsi flap breast reconstruction. With the described technical refinements the flap can offer sufficient volume and shape to provide good aesthetic result in most patients with minimal flap and donor site complications. The extended latissimus dorsi flap is a reliable method for total autologous breast reconstruction in most patients and should be considered more often as a primary choice for breast reconstruction.

## REFERENCES

- 1- Maxwell G.P.: Iginio Tansini and the origin of the latissimus dorsi musculocutaneous flap. *Plast. Reconstr. Surg.*, 65: 686-92, 1980.
- 2- Tansini I.: Sopra il mio nuovo processo di amputazione della mamella. *Riforma Medica (Palermo, Napoli)*, 12: 757, 1906.
- 3- Muhlbauer W. and Olbrisch R.: The latissimus dorsi myocutaneous flap for breast reconstruction. *Chir. Plast.*, 4: 27, 1977.
- 4- Hartrampf C.R., Sheflan M. and Black P.W.: Breast reconstruction with a transverse abdominal island flap. *Plast. Reconstr. Surg.*, 69: 216-24, 1982.
- 5- Watterson P.A., Bostwick J., Hester T.R., et al.: TRAM flap anatomy correlated with a 10-year experience with 556 patients. *Plast. Reconstr. Surg.*, 95: 1185-94, 1995.
- 6- Chang D.W., Youssef A., Cha S. and Reece G.P.: Autologous breast reconstruction with extended latissimus dorsi flap. *Plast. Reconstr. Surg.*, 110: 751-9, 2002.
- 7- Kind G.M., Rademaker A.W. and Mustoe T.A.: Abdominal wall recovery following TRAM flap: A functional outcome study. *Plast. Reconstr. Surg.*, 99: 417-28, 1997.
- 8- Kroll S.S. and Netscher D.T.: Complications of TRAM flap breast reconstruction in obese patients. *Plast. Reconstr. Surg.*, 84: 886-92, 1989.
- 9- Lee J.W. and Chang T.W.: Extended latissimus dorsi musculocutaneous flap for breast reconstruction, experience in the Oriental patients. *Br. J. Plast. Surg.*, 52: 365-72, 1999.
- 10- Hokin J.A.B.: Mastectomy reconstruction without a prosthetic implant. *Plast. Reconstr. Surg.*, 72: 810-18, 1983.
- 11- Hokin J.A.B. and Silfverskiold K.L.: Breast reconstruction without an implant: Results and complications using an extended latissimus dorsi flap. *Plast. Reconstr. Surg.*, 79: 58-66, 1987.
- 12- Marshall D.R., Anstee E.J. and Stapelon M.J.: Soft tissue reconstruction of the breast using an extended composite latissimus dorsi myocutaneous flap. *Br. J. Plast. Surg.*, 37: 361-8, 1984.
- 13- Papp C., Zanon E. and McCraw J.: Breast volume replacement using the de-epithelialized latissimus dorsi myocutaneous flap. *Eur. J. Plast. Reconstr. Surg.*, 11:120-5, 1988.
- 14- McCraw J.B. and Papp C.T.: Latissimus dorsi myocutaneous flap: "Fleur de lis" reconstruction. In: Hartrampf CR (Ed.), *Breast Reconstruction with living tissue*. Norfolk, Va.: Hampton Press, 221-48, 1991.
- 15- Barnett G.R. and Gianoutsos M.P.: The latissimus dorsi added fat flap for natural tissue breast reconstruction: report of 15 cases. *Plast. Reconstr. Surg.*, 97: 63-70, 1996.
- 16- Germann G. and Steinau H.U.: Breast reconstruction with the extended latissimus dorsi flap. *Plast. Reconstr. Surg.*, 97: 519-26, 1996.
- 17- McCraw J.B., Papp C., Edwards A. and McMellin A.: The autogenous latissimus breast reconstruction. *Clin. Plast. Surg.*, 21: 279, 1994.
- 18- Fatah F.: Extended Latissimus dorsi flap in breast reconstruction. *Oper. Techn. Plast. Reconstr. Surg.*, 6: 38-48, 1999.
- 19- Kim P.S., Gottlieb J.R., Harris G.D., Nagle D.J. and Lewis V.L.: The dorsal thoracic fascia: Anatomic significance with clinical applications in reconstructive microsurgery. *Plast. Reconstr. Surg.*, 79: 72-80, 1987.
- 20- Titley O.G., Spyrou G.E. and Fatah M.F.T.: Preventing seroma in the latissimus dorsi flap donor site. *Br. J. Plast. Surg.*, 50: 106-8, 1997.
- 21- Kroll S.S. and Baldwin B.: A comparison of outcomes using three different methods of breast reconstruction. *Plast. Reconstr. Surg.*, 90: 455-62, 1992.
- 22- Trabulsky P.P., Anthony J.P. and Mathes S.J.: Changing trends in postmastectomy breast reconstruction: A 13-year experience. *Plast. Reconstr. Surg.*, 93: 1418-27, 1994.
- 23- Papp C. and McCraw J.B.: Autogenous latissimus breast reconstruction. *Clin. Plast. Surg.*, 25: 261-5, 1998.
- 24- Bostwick J.: Aesthetic and technical aspects of breast reconstruction with the latissimus dorsi flap. In: Bohmert H & Gabka C (Eds.). *Plastic and Reconstructive Surgery of the Breast*. New York: Thieme, 209-20, 1997.
- 25- Clough K.B., Louis-Sylvestre C., Fitoussi A., Couturaud B. and Nos C.: Donor Site Sequelae after Autologous Breast Reconstruction with an Extended Latissimus Dorsi Flap. *Plast. Reconstr. Surg.*, 109: 1904-11, 2002.