

## **Improving Aesthetics in Lateral Tension Abdominoplasty**

EL-SAYED IBRAHIM EL-SHAFFEY, M.D.

*The Department of Plastic Surgery, Faculty of Medicine, Mansoura University.*

### **ABSTRACT**

The number of insufficient results and the relatively high complication rate of classic abdominoplasty explain the high rate of surgical reoperation. The problems that generate complaints include fullness of epigastrium and flanks with or without dog-ears, lack of waist definition, depressed scar and hanging skin over the incision line and large bulging ptosed mons pubis. Based on analysis of these problems and the aesthetic potentials of high lateral tension abdominoplasty, the purpose of this study is to develop and merge means and ways to overcome these problems, decrease complications and improve aesthetic outcome of abdominoplasty. Key features of our approach include truncal liposuction as needed to remove fat deposits, skin resection pattern with significant lateral resection to improve flanks and waist, multi-layer closure including the fascia with the highest tension wound closure placed along the lateral limbs to avoid depressed scars, mons pubis and inguinal lift. Thirty-nine patients underwent abdominoplasty according to these concepts over a two-year period. (The average age was 38 years and the average weight was 82kg). Of these, 24 patients (including 10 overweight patients prepared with truncal liposuction, in a separate stage, 4-6 months before abdominoplasty) had a full abdominoplasty with umbilical transposition, 9 had miniabdominoplasty with adjunctive liposuction and 6 were revision operations; mainly truncal liposuction, mons pubis lift and reconstruction of a depressed scar and skin overhang. Except for one small seroma, there were no other early complications due to removal of excess fat. One patient required liposuction of lateral fatty excess and extension of the scar to remove excess skin and improve the flanks. The results showed improved anterior abdominal contour and enhanced waist definition and lumbar curve. The smooth curvilinear scar was well placed, in level with mons pubis and without the stigma of depressed scar with skin overhang. Patients were particularly pleased with the youthful appearance of their mons pubis lift and the smooth mons pubis-hypogastrium transition. Comprehensive liposuction in concert with high lateral tension abdominoplasty or in presence of large adiposities in a separate stage is likely to eliminate problems of classic abdominoplasty, decrease complications, maximize aesthetics and avoid the need for revisions. Overall, harmony between the hip and waist and between mons pubis and hypogastrium is achieved.

### **INTRODUCTION**

Abdominoplasty has become a frequent, appearing to be technically easy operation but nevertheless a source of potentially annoying problems and

complications clearly affecting the aesthetic results and the satisfaction rate of the patients. The problems that generate complaints from patients and dissatisfaction with classic abdominoplasty are: Fullness of epigastrium, fullness of flanks with or without dog-ears, lack of waist definition, depressed scar and hanging skin over the incision line, large bulging and ptotic mons pubis and visible scar beyond underwear coverage. Careful analysis of these problems relates them to operating on thick skin with excess fat, design of the skin resection pattern, lack of multiple layer closure and not tackling the mons pubis region. In presence of excess fat and regardless of how tight the skin may be pulled, over time, there will be some loss of shape or contour.

Many techniques to address the skin and subcutaneous tissue have been described. Adjunctive liposuction [1], different skin resection patterns, alteration of the sites of maximal tension on skin closure and selection of layers to close all contribute to the final appearance [2,3]. The high lateral tension abdominoplasty addresses the practical and theoretic concerns of standard abdominoplasty design. Key elements include: Skin resection pattern with significant lateral skin resection, truncal liposuction when needed, direct undermining limited to the paramedian area, discontinuous undermining to costal margins and flanks as needed, superficial fascial system repair along the entire incision with highest-tension wound closure along the lateral limbs [4,5].

Certain abdominal aesthetics are timeless and together with smooth transitions form the ideal feminine figure. They include: Well-defined waist and tight lateral trunk, central tissues not as tight with mild concavity above and mild convexity below umbilicus, midline epigastric valley between evident rectus muscle bulges, vertically oriented umbilicus, mons pubis with no ptosis, large fat deposits or concealed vulva and gentle

lazy S-shaped outlines of the anterior and lateral silhouette. Removal of fat deposits, thinning out the skin and tailoring abdominoplasty according to the lateral tension design will help achieve the goal of a uniform aesthetic result. So, our objective is to develop and merge means and ways to diminish the problems of classic abdominoplasty, improve aesthetic outcomes and decrease revisions.

## PATIENTS AND METHODS

Thirty-nine female patients with anterior abdominal redundancy, with or without fat deposits, were operated for abdominoplasty during the period from June 2004 to November 2006. The average age was 38 years (range 29-61 years) and the average weight was 82kg (range 68-90kg) at the time of the operation. Morbidly obese patients were not included in this study. Ten overweight patients had liposuction of the abdomen, mons pubis, flanks, waist and back rolls performed 4-6 months before the operation to remove excess fat, decrease fullness of epigastrium, mons pubis, flanks and waist and enhance lumbar curve.

*Marking:* Areas of concomitant liposuction of upper abdomen, costal margin, flanks and mons-pubis are marked as indicated. The midline of the abdomen is marked from xiphoid to anterior vulvar commissure. This vertical midline will be used as a reference for the new position of the umbilicus. The lower incision line crosses the upper part of the pubis, 7cm above the anterior vulvar commissure with the mons pubis under modest upward stretch, and proceeds laterally toward anterior superior iliac spine and then, when needed, parallel to iliac crest in a smooth gentle curve with an upward lift of inguinal and anterior thigh skin laxity. To obtain the maximum amount of skin resection laterally, the estimated resection line courses superomedially from the lateral extent of the inferior line at an angle of 60 to 90 degrees for several centimeters. Further markings depend on the need to transpose the umbilicus. Patients with mild to moderate epigastric laxity associated with significant lateral truncal laxity may not require umbilical transposition; in these patients more tissue is resected laterally than centrally and the upper resection line will be around 10cm below umbilicus. Patients with moderate to severe epigastric laxity require umbilical transposition with nearly as much tissue resected laterally as centrally. In these patients the upper resection line will be above the umbilicus. The skin resection pattern will be rhomboid like rather than the ellipse of classic abdominoplasty.

*Operative technique:*

*Lateral tension abdominoplasty:*

The marks are confirmed with superficial skin scratches to avoid losing them during the operation and liposuction of adjacent flanks is performed when needed. Overweight patients with large adiposities had comprehensive liposuction for contouring of the abdomen and waist and thinning out the flap 4-6 months before abdominoplasty. Using skin hooks, circumscription of the umbilicus is carried out. The inferior incision line is incised through subcutaneous fat and Scarpa's fascia, identifying and preserving this fascia inferiorly for closure. Avoid undercutting the mons pubis to provide foundation for wound closure in this area. The inferior abdomen is undermined to the umbilicus preserving the flimsy areolar layer over the anterior abdominal muscles to preserve lymphatics. Direct undermining above the umbilicus is limited initially to the medial rectus border and continues to the xiphoid. Rectus muscle plication using nylon loop is done from xiphoid to umbilicus and from umbilicus to pubis in one or two layers. The table is flexed 30 degrees and redundant abdominal flap is resected with more tension placed along the lateral incision limbs. Again avoid undercutting the flap above umbilicus where there is no distinct fascia. Any restricting fibrous septae dimpling the skin may be released deeply prior to wound closure with vertical spreading scissors. Two large closed suction drains are brought out below the wounds laterally to allow for use of abdominal corset especially in cases of concomitant truncal liposuction. The flap is temporarily tacked to the inferior skin incision and a 2.5cm vertical incision is made over the umbilicus for the umbilicoplasty. Wound closure is completed in 3 layers: 0 PDS for Scarpa's fascia, 3-0 Monocryl for dermis and 4-0 PDS or Monocryl on a straight needle for subcuticular skin closure. Emphasis is placed on layered closure at the mons pubis to avoid depressed scar in this area. Wound adhesive is next applied to the skin and then Steri Strips (Figs. 1-4).

*Miniabdominoplasty and liposuction:*

Patients are marked for miniabdominoplasty and the area to be suctioned, which include epigastrium, hypogastrium, mons pubis, flanks, waist and back rolls. After infiltration of tumescent fluid, free liposuction is carried out using 4mm cannulas. On completion of liposuction, abdominal flap is undermined to the umbilicus and redundant skin excised according to the rhomboid-like lateral tension skin resection pattern with the upper resection line around 10cm below umbilicus, depending

on tissue laxity. Closure is performed as described above (Figs. 5-7).

*Revision abdominoplasty:*

These patients underwent classic abdominoplasty in other centers with (5 patients) or without liposuction elsewhere 1-4 years before their revision. They presented with an aesthetic deformity triad of large ptotic pubis, depressed scar with overlying skin overhang in addition to fullness of anterior abdomen, waist and flanks. Areas of lipo-

suction are marked including anterior abdomen, mons pubis, flanks and waist. Lateral tension skin resection pattern is designed, as in miniabdominoplasty, with the lower line 7cm above anterior vulvar commissure for mons pubis lift. The upper incision line depends on skin laxity and is usually 10cm below umbilicus. No umbilical transposition was required in revision patients. Liposuction was performed and revision was carried out with reconstruction of the depressed scar and mons pubis lift (Fig. 8).

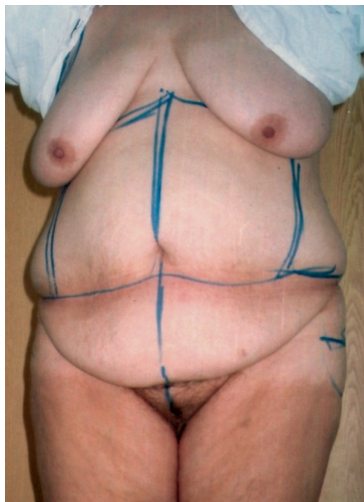


Fig. (1-A): A 61-year-old patient with severe skin laxity and fat deposits in the abdomen, mons pubis and flanks before preparatory liposuction.

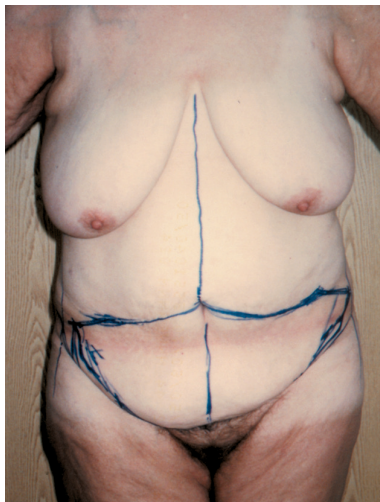

Fig. (1-B): The same patient 6 months after a separate stage liposuction and before lateral tension abdominoplasty.

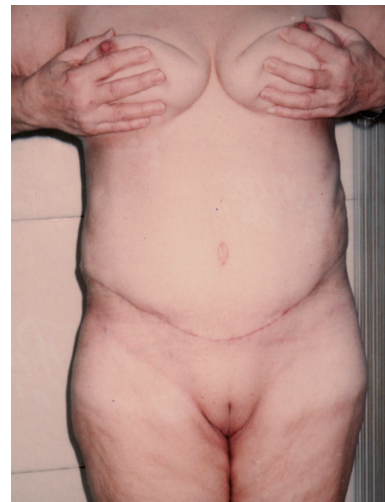

Fig. (1-C): Postoperative photo 9 months after abdominoplasty with natural-looking abdomen, improved flanks and mons pubis lift.

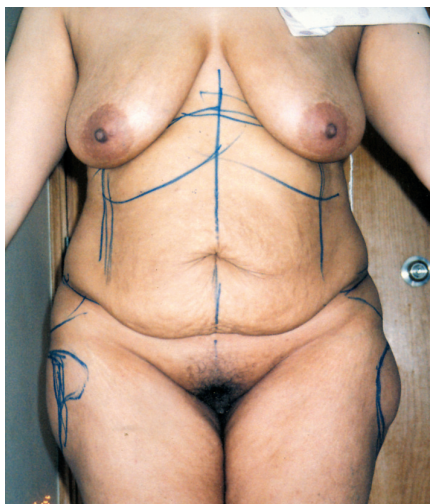


Fig. (2-A): Preoperative view of a 42-year-old patient with skin laxity and fat deposits abdomen and flanks.

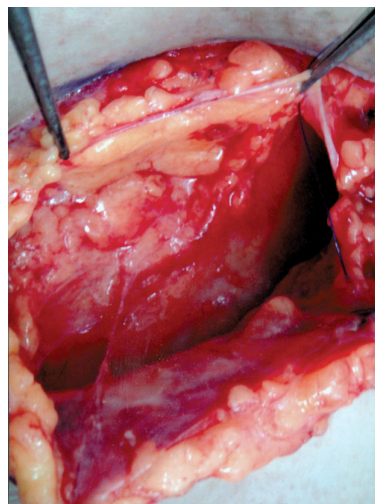


Fig. (2-B): Well-developed fascia in the upper and lower flaps laterally where highest tension wound closure is placed.

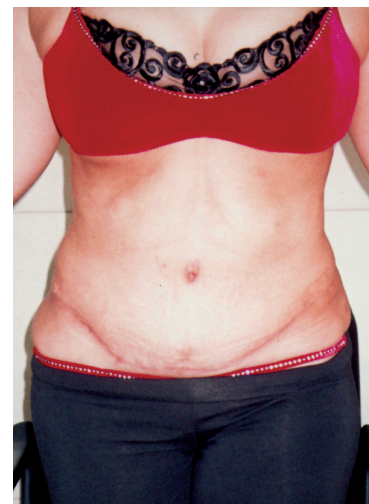

Fig. (2-C): One-year follow-up after liposuction in a separate stage and then abdominoplasty 6 months later.

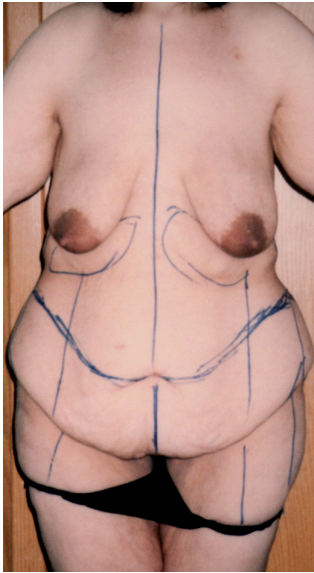


Fig. (3-A): Preoperative photo of a 29-year old patient with severe skin laxity after weight loss. Note skin resection pattern with more lateral resection.

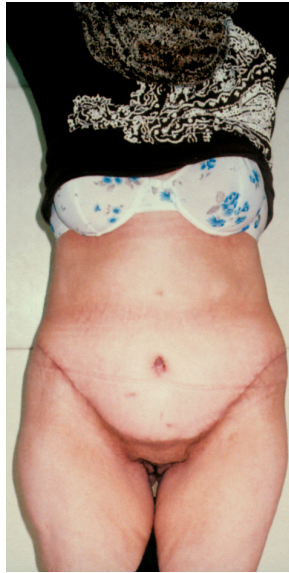

Fig. (3-B): Postoperative view after lateral tension abdominoplasty and mons pubis lift.

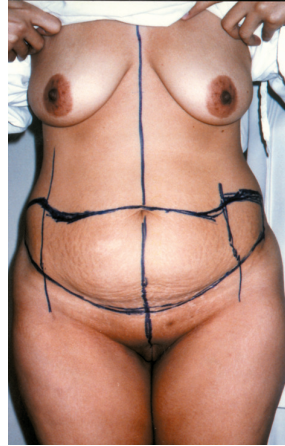


Fig. (4-A): Preoperative view of a 38-year-old patient with skin laxity and fat excess in flanks; design of lateral tension abdominoplasty.

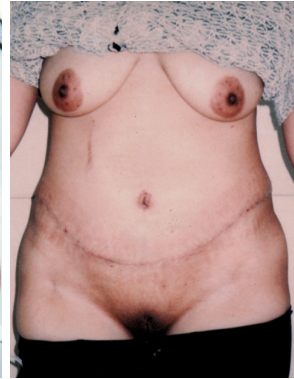

Fig. (4-B): Postoperative view after abdominoplasty and flank liposuction.

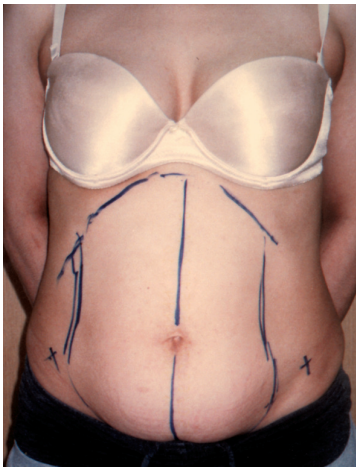


Fig. (5-A): Preoperative view of a 30-year old patient with fat excess abdomen and flanks and skin laxity below umbilicus.

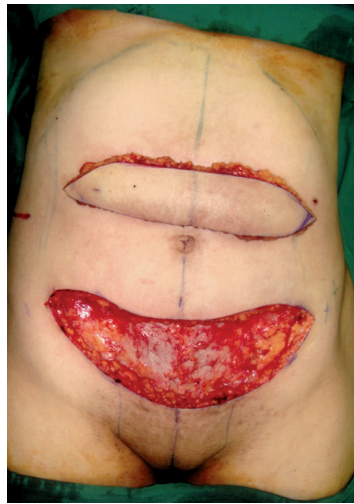

Fig. (5-B): Rhomboid like skin resection pattern with areolar layer left over the muscles.

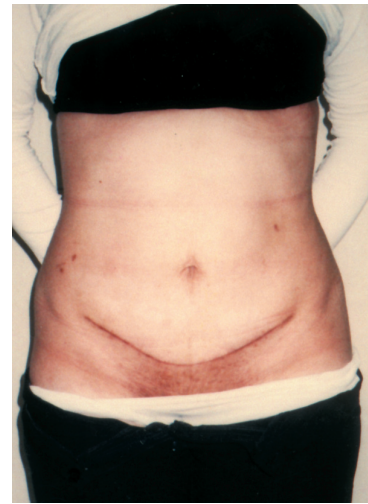


Fig. (5-C): The 4-month postoperative result after liposuction and mini-abdominoplasty with enhanced waist definition.

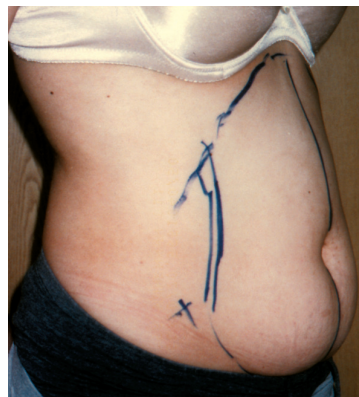

Fig. (5-D): Preoperative oblique view of the same patient.

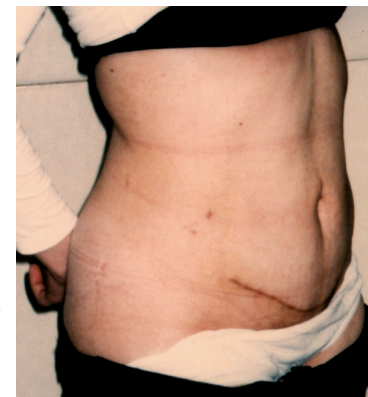


Fig. (5-E): Postoperative oblique view of the same patient with central depression between recti.

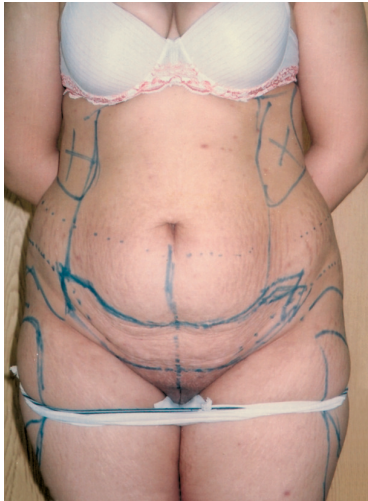


Fig. (6-A): A 36-year patient with fat deposits abdomen and flanks and skin laxity lower abdomen.

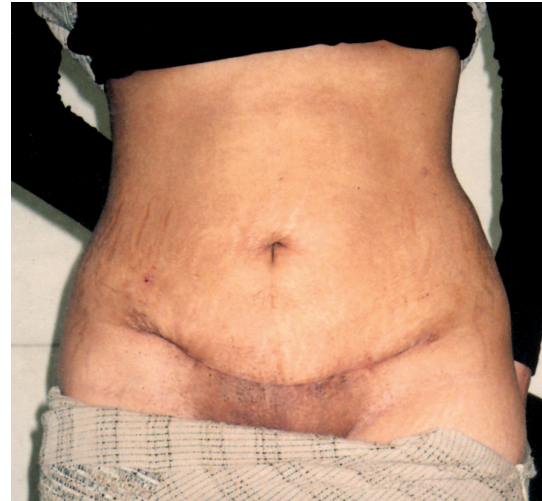

Fig. (6-B): Follow-up 6 months after liposuction and miniabdominoplasty with improved flanks and waist.

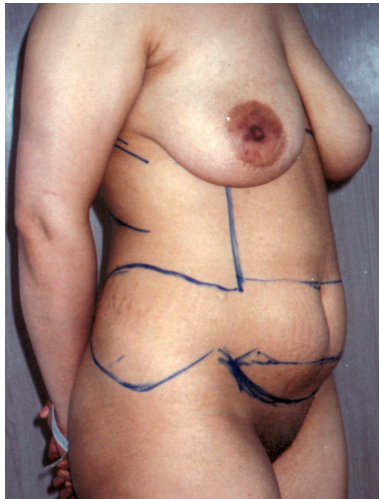


Fig. (7-A): A 34-year old patient with fat deposits abdomen and flanks and skin laxity hypogastrium.

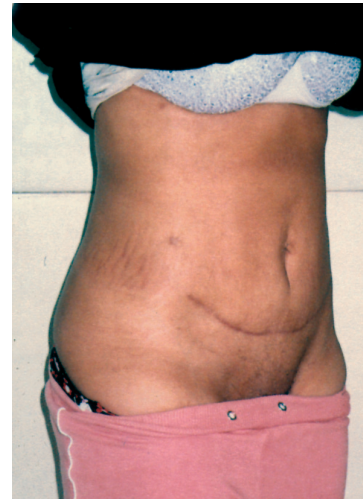


Fig. (7-B): The 5-month follow-up with improved abdominal, contour, flanks and waist.

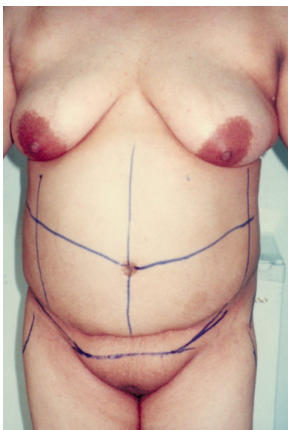


Fig. (8-A): Preoperative view of a 35-year old patient after classic abdominoplasty with fullness of abdomen and flanks, depressed scar and large ptotic mons pubis with concealed vulva.

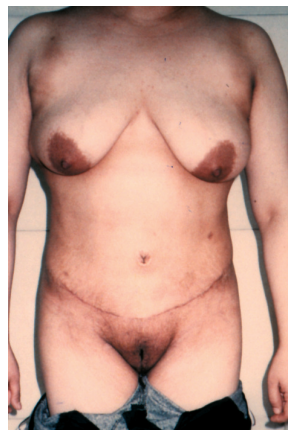

Fig. (8-B): The postoperative result after liposuction and revision abdominoplasty with natural-looking abdomen, mons pubis lift and enhanced waist definition.

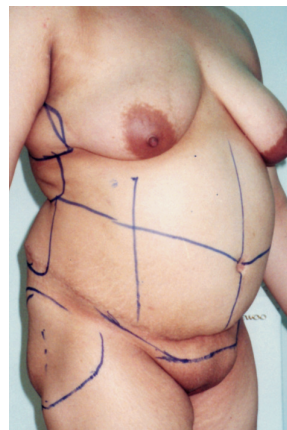


Fig. (8-C): Preoperative oblique view of the same patient.

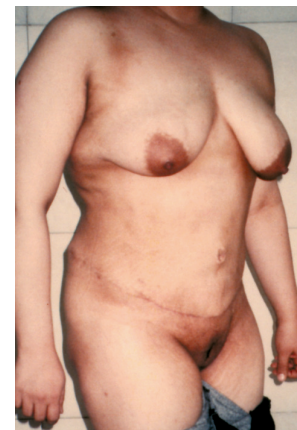

Fig. (8-D): Postoperative oblique view of the same patient with youthful appearance of mons pubis and enhanced waist and lumbar curve.

## RESULTS

Follow-up ranged between 4 and 18 months. Twenty-four patients (of these, 10 overweight patients underwent truncal liposuction 4-6 months before operation) had a full abdominoplasty with umbilical transposition, 9 patients had miniabdominoplasty with adjunctive liposculpture and 6 patients were revision operations; mainly mons pubis lift, reconstruction of a depressed scar and skin overhang and truncal liposuction. None of the patients required intraoperative or postoperative transfusions and the median hospital stay was one day. One patient had seroma in lower abdomen after miniabdominoplasty and liposuction, which resolved with conservative treatment. There were no other early complications as hematoma, skin or fat necrosis, wound infection, wound dehiscence or delayed healing. One patient required minimal liposuction of localized lateral fat deposit with extension of the scar to remove excess skin and improve the flank; otherwise there were no other surgical revisions. All patients were particularly pleased with their mons-pubis lift, which gave a youthful appearance to the area and harmony with the tummy tuck. The smooth curvilinear scar was in level with the mons pubis without the stigma of hanging skin over a depressed scar. A smooth, natural mons-hypogastrium transition added to the improved anterior abdominal contour and enhanced waist definition. Overweight patients with significant truncal adiposities who had their skin thinned out with comprehensive liposuction in a separate stage prior to abdominoplasty showed reduction of complications due to removal of excess fat. Also improvement of abdominal contour, flanks and waist were better than patients who did liposuction after abdominoplasty as part of their revision operation. All the patients were uniformly satisfied with their results.

## DISCUSSION

Most patients feel relieved of their functional deformity after classic abdominoplasty, but their level of expectation falls short of a satisfactory, let alone an ideal, aesthetic outcome. Abdominal contour is a byproduct of the contour of the underlying muscles, the overlying adipose layer and the skin [6]. To this is added the fat content of the abdominal cavity. To maximize aesthetics of abdominoplasty, some issues need to be considered. The skin should not be too thick; otherwise it will not drape as nicely and will not reveal contouring of the musculoaponeurotic layer. Likewise epigastric fullness, fat deposits over costal margins and

fullness of the flanks have to be suctioned with abdominoplasty or in a separate stage before the operation. Also marking of incision lines with emphasis on mons pubis and inguinal lift and more lateral tissue resection [4]. Finally, multi-layer wound closure with superficial fascial system suspension to avoid wide depressed scar. In the current series, we applied these concepts to patients with anterior skin laxity, with or without fat excess, resulting from repeated pregnancies, obesity and weight fluctuations that were candidates for an anterior-only procedure. For some surgeons, the safety of combined abdominoplasty and liposuction of the undermined flap remains an unresolved issue. In miniabdominoplasty, concomitant truncal liposuction, in appropriate patients can be done freely to improve flanks, enhance waist definition and shorten the scar without any compromise of the flap. All cases of miniabdominoplasty in this series were associated with liposuction of epigastrium, hypogastrium, mons pubis, flanks and back rolls as indicated. A shorter incision line, more natural-looking abdomen and enhanced waist and lumbar curve were consistently achieved.

In full abdominoplasty, under the proper circumstances, I am of the opinion that maintains that some liposuction of the undermined flap and adjacent areas, not in and of itself the "major" portion of the operation, is feasible [5]. Simultaneous liposuction of adjacent flanks was carried out when needed in most of our full abdominoplasty patients without increasing the risk of seroma formation. Overweight patients with significant truncal adiposities had liposuction performed as a separate stage 4-6 months prior to full abdominoplasty. The reduction of adiposities and subcutaneous fat of the flap contributed to better abdominal contouring and waist definition with subsequent abdominoplasty. It also contributed to reduction of complications as fat necrosis, seromas and other wound complications compared to historical controls [7,8]. This is in agreement with the findings that obesity at the time of abdominoplasty has a profound influence on the wound complication rate following surgery [9]. If otherwise concomitant liposuction is undertaken for significant adiposities, it is likely to be partial and the patient will be heading for an additional liposuction, which is a reverse of the natural sequence of fat removal first and then resection. Many reports adopt concomitant truncal liposuction with abdominoplasty and mention precautions as limited direct undermining above the umbilicus [10-12], or doing liposuction of adjacent areas without flap liposuction [13]. The dilemma is likely to continue and sensible judgment is

required. The patient weight, amount of excess fat and skin laxity are used, among other factors, to determine on simultaneous or separate liposuction. In overweight patients with significant adiposities, liposuction in a separate stage before abdominoplasty will be more comprehensive with reduction of complications, better body contour and less need for revisions.

Although most of the revision cases in this series did concomitant liposuction with their tummy tuck they all needed additional liposuction of anterior abdomen, mons pubis, waist, flanks and back rolls as the main part of their revision. However, the final results would have been better if excess fat was removed before, not after, abdominoplasty.

The youthful anterior abdominal contour is not flat or board-like. Instead it shows the contour of the rectus muscle bulges with a midline epigastric valley. Wide vertical rectus plication reduces the width of the rectus muscle bulges and leaves the abdomen oddly flat [6,14]. Plication of the oblique muscles can be added to further enhance waist definition [15]. Applying this concept to our patients, plication is done only to the extent that the rectus muscles are brought into opposition to correct the diastasis and preserve the natural outline of the rectus muscles.

Significant lateral truncal skin resection results in epigastric tightening. As the fascia is well developed in the upper and lower flaps laterally, it allows a strong superficial fascial suspension laterally to take tension off the central closure where the fascia is less developed in the upper flap. In addition it improves waist, flanks and inguinal areas. Furthermore, proper closure of superficial fascial system takes tension off skin closure, prevents depressed wide scar and provides smooth mons pubis-hypogastrium transition. On the other hand one-layer skin closure [13] will lead to retraction of subcutaneous fat and superficial fascia with wide depressed scar being inevitable due to absence of the foundation for skin closure. To prevent depressed scar at the mons pubis we avoid undercutting of the mons pubis and identify the fascia for closure. The fascia in the abdominal flap is not distinct in the midline, coming from above the umbilicus, but well developed laterally. So, we make sure of proper closure of this fascia with the well-developed fascia of the mons pubis and along the entire incision in addition to subcutaneous fat approximation, dermal and skin closure for proper reconstruction of the wound in the mons pubis area. The highest tension wound closure being

placed along the lateral limbs where the fascia is well developed. Simultaneous or prior liposuction also prevents fat deposits above and below from outgrowing the scar.

So the key features of our approach are: Removal of fat deposits with concomitant liposuction or, in presence of significant adiposities, with liposuction in a separate stage 4-6 months before abdominoplasty, use of high lateral tension skin resection pattern to improve flanks and enhance waist definition, preserving rectus muscle bulges during repair of rectus diastasis, multi-layer reconstruction with strong superficial fascial system suspension with the highest tension placed along the lateral limbs to reduce tension on central closure and avoid wide depressed scar and mons-pubis and inguinal lift to have youthful appearance and give smooth mons pubis-hypogastrium transition. In overweight patients with large adiposities, insisting on a one-stage procedure will only be at the expense of complete liposuction and a revision operation will be inevitable with less than optimal final results. Body contouring with simultaneous or separate stage liposuction in concert with lateral tension abdominoplasty and mons-pubis lift will optimize abdominoplasty aesthetics, decrease complications, avoid revisions and enhance patient satisfaction.

## REFERENCES

- 1- Avelar J.M.: Abdominoplasty combined with lipoplasty without panniculus undermining: Abdominoplasty-a safe technique. *Clin. Plast. Surg.*, 33; 79, 2006.
- 2- Ramirez O.M.: Abdominoplasty and abdominal wall rehabilitation: A comprehensive approach. *Plast. Reconstr. Surg.*, 105: 425, 2000.
- 3- Pascal J.F. and Louran C.: Remodeling body lift with high lateral tension. *Aesthetic Plast. Surg.*, 26: 223, 2002.
- 4- Lockwood T.: High lateral tension abdominoplasty with superficial fascial system suspension. *Plast. Reconstr. Surg.*, 96: 603, 1995.
- 5- Matarasso A.: Liposuction as an adjunct to a full abdominoplasty. *Plast. Reconstr. Surg.*, 95: 289, 1995.
- 6- Yousif N.J., Lifchez S.D. and Ngyyen H.H.: Transverse rectus sheath plication in abdominoplasty. *Plast. Reconstr. Surg.*, 114: 778, 2004.
- 7- Stewart K.J., Stewart D.A., Coghlan B., Harrison D.H., Jones B.M. and Waterhouse N.: Complications of 278 consecutive abdominoplasties. *Plast. Reconstr. Aesthet. Surg.*, 59: 1152, 2006.
- 8- Roje Z., Roje Z., Karanovic N. and Utrobicic I.: Abdominoplasty complications: A comprehensive approach for the treatment of chronic seroma with pseudobursa. *Aesthetic Plast. Surg.*, 30: 611, 2006.
- 9- Rogliani M., Silvi E., Labardi L., Maggiulli F. and Cervelli

- V.: Obese and nonobese patients: Complications of abdominoplasty. *Ann. Plast. Surg.*, 57: 336, 2006.
- 10- Hafezi F. and Nouhi A.: Safe abdominoplasty with extensive liposuctioning. *Ann. Plast. Surg.*, 57: 149, 2006.
- 11- Graf R., de Araujo L.R., Neto L.G., Pace D.T. and Cruz G.A.: Lipoabdominoplasty: Liposuction with reduced undermining and traditional abdominal skin flap resection. *Aesthetic Plast. Surg.*, 30: 1, 2006.
- 12- Cardenas-Camarena L.: Aesthetic surgery of the thoraco-abdominal area combining abdominoplasty and circumferential lipoplasty: 7 years' experience. *Plast. Reconstr. Surg.*, 116: 881, 2005.
- 13- Kim J. and Stevenson T.R.: Abdominoplasty, liposuction of the flanks, and obesity: Analyzing risk factors for seroma formation. *Plast. Reconstr. Surg.*, 117: 773, 2006.
- 14- Nahas F.X.: An aesthetic classification of the abdomen based on the myoaponeurotic layer. *Plast. Reconstr. Surg.*, 108: 1787, 2001.
- 15- Santos E. and Muraira J.: The waist and abdominoplasty. *Aesthetic Plast. Surg.*, 22: 225, 1998.