

Balanced Rhinoplasty of the Arabic Nose: Endonasal Approach with Key Maneuvers

EL-SAYED IBRAHIM EL-SHAFFEY, M.D.

The Department of Plastic Surgery, Faculty of Medicine, Mansoura University.

ABSTRACT

As demand for aesthetic rhinoplasty of the Arabic nose increases, associated complications and unsatisfactory results also increase along with revisions and secondary rhinoplasties. The nose is not particularly forgiving and a conservative approach in primary surgery is the key for a successful result. To achieve a natural looking nose without the stigmata of the operated look, rhinoplasty was performed for 34 patients with features of the Arabic nose: Long slightly humped nose with pendant low tip and small nasolabial angle. The frequent use of the muscle motors of the lower third of the nose may exaggerate plunging tip. Endonasal transcartilaginous approach with certain key maneuvers was used in all patients. Key maneuvers include; (1) Conservative long keel cephalic resection of lateral crura to narrow a wide tip and avoid a pinched tip. (2) Thin triangular caudal septal cartilage excision including mucosa to allow cephalad rotation, sustain projection and correct a plunging tip. (3) Conservative hump reduction with chisel to preserve the middle vault. (4) Trimming of the cranial border of medial crura in case of true hanging columella. (5) Interruption of the insertion of the levator muscle and depressor septi muscle to correct plunging tip on speaking or smiling and (6) Alar wedge excision, if needed, that preserves alar curve and interrupts levator muscle in its depth. The technique will be described and the basis behind these maneuvers discussed. Most patients had refined tip with cephalad rotation, sustained projection and open naso-labial angle. The short recovery period enables patients to adjust rapidly in their conservative society. There were no cases of pinched tip, supratip deformity, saddle nose or internal valve obstruction. Patients were satisfied with the results both functionally and aesthetically. These positive results were maintained during the long-term follow-up. A natural looking nose was the common theme without the operated look. The technique combines the best features of a balanced rhinoplasty with the minimal wounding afforded by a closed approach.

INTRODUCTION

A pendant low tip is a standard feature of the long, slightly humped Arabic nose especially in the Gulf where the climate is hot and nasal allergy is common due to sand storms. The tip is more caudal than normal and underprojected at the same time. The nasolabial angle is abnormally small with hanging columella in some patients. When a person smiles, the levator labii superioris alaeque nasi muscle, inserted in the nasal ala, moves the

alar base upward and the depressor septi nasi muscle, inserted into the medial crus, pulls the tip caudally exaggerating plunging of the tip [1]. It seems that, in order to overcome breathing difficulty during allergic attacks, these muscles are activated pulling the tip caudally to widen the internal valve. This, repeated during nasal growth, may lead to plunging of the nasal tip and bowing of the columella caudally.

Many methods are used to correct plunging tip: Caudal septal cartilage excision in cases of excessive caudal septum and cutting the union of the lateral crus of the alar cartilage with the accessories to make the nasal tip turn upward. Also, cutting the levator labii superioris alaeque nasi [2] and the depressor septi nasi muscle to correct plunging of the nasal tip exaggerated on speaking or smiling.

Observing some of the results of open rhinoplasty and alar wedge excision, we were able to discern some disagreeable features peculiar to the operated nose in these patients: Sausage shaped dorsum, pinched tip and absence of the gentle curve of the ala at the alar facial groove giving a straight side to the ala and a triangle-stuck-on appearance to the base (Fig. 1). Above all, saddle nose, nasal tonation and internal valve obstruction were not infrequent findings. Patients pushing for small noses met with overzealous surgery were behind these "trademark" results. Surgery, however, should preserve the expression, being more dynamic and different from patient to patient [3]. Concerned with the frequency of these trademark results, rising rates of unsatisfied patients and hence secondary rhinoplasty, we felt a need for more insight into conservative approaches to avoid more overly done noses. Our approach is to simplify the surgical procedure; using only necessary steps and certain maneuvers to achieve a balanced natural looking nose by means of endonasal approach in primary rhinoplasty of Arabic nose.

PATIENTS AND METHODS

Among rhinoplasty patients from March 2005 onward, 34 female patients were operated for rhinoplasty of Arabic nose and included in this study. The age range was between 17 and 38 years. All patients had the features of the Arabic nose. Plunging of the nasal tip exaggerated on speaking or smiling was evident in 12 patients. True hanging columella was present in 8 patients. A true hanging columella is characterized by a relative curvature of the columella greater than the curvature of the alar rim. Most patients had thick skin and preservation of structural support was important for the patency of nasal valves. Endonasal transcartilaginous rhinoplasty with certain key maneuvers for the Arabic nose was used in all patients.

Surgical technique:

The alar cartilages and the parts to be removed are marked on the lobular skin noting any asymmetries. Also the dorsal hump and lateral basal lines are marked. Alar cartilages are marked inside and asymmetries checked. Everting the nostril rim and using the back of scalpel handle a step-off can be felt in the vestibular skin which delineates the borders of the alar cartilages.

The endonasal intracartilaginous incisions to be made in the vestibular skin are marked at a distance of about 5mm from the lower margin of the lateral crus. The incision lines, lateral wall of the vestibulum, base of the nose, caudal septum and dorsum are injected with lidocaine adrenaline to facilitate the next steps. An incision is made into the vestibular skin and lateral crus at a distance of at least 5mm from the causal margin of the lateral crus under direct view and simultaneous outside control.

The skin overlying the cranial part of the lateral crus is undermined in a supraperichondrial plane and the vestibular skin on its under surface is undermined in a subperichondrial plane. Finding the right subperichondrial plane is important for a bloodless field. Judicious resection of the cephalic part in the shape of a long keel is performed avoiding right angles at the ends of the resection to prevent turned-in rotation of the remaining alar cartilage (Fig. 2,A). This will allow rotation of the tip, enhance projection and refine a wide tip. Care is taken to leave a continuous strip of alar cartilage intact.

The right intracartilaginous incision is connected with transfixion or caudal septal incision and bilateral subperichondrial and subperiosteal septal

tunnels are developed to allow extramucosal resection of cartilaginous and bony hump. A small part of the caudal septum is resected in the form of a triangle with the base anteriorly. A small piece of septal mucosa in the same shape is removed from the upper edge of the transfixion incision on both sides for the same purpose. This helps to shorten the nose, decrease columellar show, open the nasiolabial angle and allow cephalad rotation and correction of a plunging nasal tip. Septoplasty is performed as needed.

To further improve the plunging of the nasal tip, which is more evident on speaking or smiling, the muscles acting on the lower third of the nose have to be dealt with. The transcartilaginous incision is extended laterally toward the pyriform aperture and medially toward the base of the columella, the lateral portion of the arch is dissected free from the skin and the mucosa exposing accessory cartilages and the levator labii superioris alaeque nasi muscle insertion is dissected and a section of the muscle, and if necessary, a section of the accessories is removed to allow cephalad rotation of the domes. The medial portion of the arch is also dissected free from the anterior nasal spine and the membranous septum, and when necessary, insertions of the depressor septi nasi are freed and sectioned (Fig. 2,B).

If a true hanging columella is present, the excess medial crura are addressed by retrogradely dissecting the nasal lining from cranial to caudal. The cranial margins of the medial crura are exposed and a crescent of cartilage is trimmed as required from the cranial margin of the exposed medial crura.

The cartilaginous dorsum is exposed superficial to perichondrium and bony hump deep to periosteum. The upper lateral cartilages are separated from the cartilaginous septum and resection of cartilaginous hump is done but left attached to the nasal bones. Using strong angulated scissor, the upper border of the septal cartilage is lowered by an oblique cut leaving more septum caudally than cranially to sustain the alar cartilages and support the tip. The two medial margins of the upper lateral cartilages are trimmed as required. Care should be taken not to overresect. A broad chisel is introduced under the resected cartilage and resection of bony part starts with the bevel up. The chisel then tends to go down while proceeding. Care is taken not to go too deep, however. Halfway, we turn the bevel down. The instrument will slowly come up while proceeding. The resected piece is mobilized and

removed in continuity with the cartilaginous hump (Fig. 3,B). The margins of the open nasal roof are equalized and smoothed with a rasp.

Using a 7-mm chisel with the flat surface toward the septum, paramedian osteotomy is carried out well into the hard nasal process of the frontal bone (a change to higher pitch is heard when the chisel is hit) to facilitate infracture of the lateral walls after lateral osteotomy. Lateral and transverse osteotomies are then performed. Lateral osteotomies are completed on both sides before transverse osteotomy to avoid an indirect fracture line. Some crushed cartilage or fascia is inserted on top to smooth the contours and to reinforce the skin.

In cases of alar wedge excision, the lower incision is usually made 1-2mm above the crease to preserve the natural groove and gentle alar curve. The muscle in the depth of the excision is cut if there is plunging of the nasal tip. Anterior nasal packing is left for 2-3 days. A narrowing tape is applied to keep the triangular cartilages in position and a nasal splint is left for one week.

RESULTS

The period of follow-up ranged from 7 months to 24 months. Trimming of the cranial border of the alar cartilages was asymmetric in 14 patients to have symmetric alar rim strips. Resection of the triangular part of the caudal border of the septum was done in all patients to correct pendant tip. In addition, cutting of the depressor septi nasi muscle with or without the levator labii superioris alaeque nasi muscle was carried out in 12 patients to allow cephalic rotation of the nasal tip and open the nasolabial angle especially on smiling (Fig. 4). The cranial border of the medial crus was trimmed to improve a hanging columella in 8 patients (Fig. 5). One patient complained of a visible scar of alar wedge excision, which improved after 4 months with conservative treatment. The short recovery period enabled patients to adjust rapidly in their conservative society. A smooth appearance of the middle third of the nose was present with no cases of internal valve obstruction. There were no cases of saddle nose, pinched tip, internal valve obstruction or nostril show. The results were satisfactory with definition and rotation of the nasal tip (Figs. 3-9). No revisions or secondary rhinoplasty were needed. Patients were satisfied with the balanced natural look of the nose and absence of the operated look or any of postrhinoplasty stigmata. A difference among all the results can be appreciated and the identity of the Arabic nose is preserved.

DISCUSSION

As Arabic population becomes more open, demand for aesthetic rhinoplasty increase and secondary rhinoplasties also increase. Aggressive procedures in primary cases are more likely to be followed by complications as pinched tip, nostril show and saddle nose [4,5]. A more conservative approach is, therefore, needed in primary cases to avoid these stigmata. Endonasal approach with key maneuvers achieves balanced rhinoplasty of the Arabic nose and avoids complications.

Cephalic resection of alar cartilages has been the traditional workhorse of nasal tip surgery. This can help reduce nasal bulbosity, create a subtle supratip break and achieve small degrees of cephalic tip rotation. Caution must be exercised in patients with significant alar cartilage asymmetry, cephalic lateral crural positioning and very thin alar cartilages. Focusing on how much cartilage is left behind is helpful to ensure adequate symmetry. If symmetric bilateral excisions are performed on asymmetric alar cartilages, the resultant anatomy remains asymmetric. One must be cognizant of variant anatomy and fashion incisions more carefully according to the anatomy present.

There are many methods for resection of the cranial cartilage strip from the lateral crus during rhinoplasty [6]. One is the right angle technique that leaves a pressure wing. The pressure wing may cause the outside to inside force responsible for a turned-in rotation on the axis of the remaining alar cartilage. This event may change the alar morphology and contribute to the pinched tip-a stigma we want to avoid. The other method removes the cranial strip of the alar lateral crus in a shape very similar to a sailboat long keel (Fig. 2,A). This avoids a turned-in rotation on the long axis of the remaining alar cartilage. In this report we used the long keel method with good results minimizing cartilage resection to only what is absolutely necessary. Overresection of alar cartilages can result in long-term development of alar collapse, supratip pinching, bosses, asymmetries, and elevated or notched alar rim and nostril show. The spring must be weakened but not broken. Often, there is a fine line between a tip that remains too bulbous and one that is pinched [7]. We are of the opinion that no excision of vestibular skin is undertaken to avoid stenosis of the internal valve and prevent dislocation of the lateral crural component and pinched tip [8]. With these maneuvers, we were able to avoid pinched tip and nostril show-two undesirable stigmata of postrhinoplasty patients.

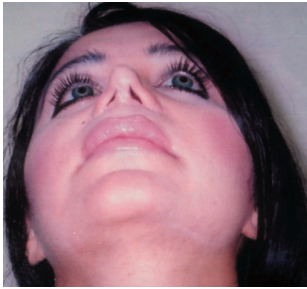

Fig. (1): The operated look we want to avoid: Absence of alar curve, pinched tip and asymmetric slit-shaped nostrils after overzealous open rhinoplasty and alar wedge excision in another country.

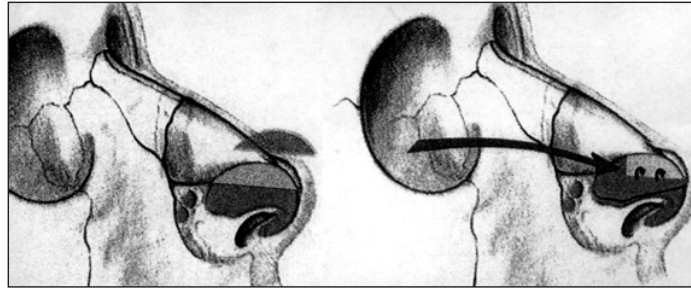


Fig. (2-A): Cephalic resection of lateral crus: Long keel technique (left) and right angle technique (right). The latter leaves a pressure wing responsible for a turned in rotation on the long axis of the remaining alar cartilage.

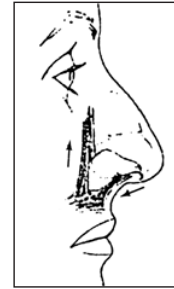


Fig. (2-B): The depressor septi nasi muscle pulls the tip caudally while the levator moves the alar base upward. Cutting these muscles improves plunging tip.

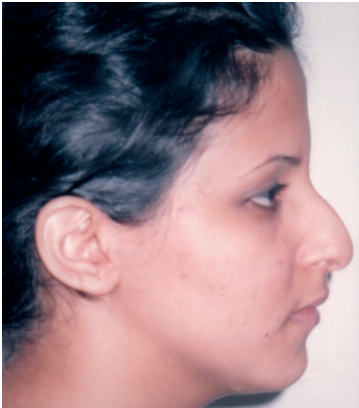

Fig. (3-A): Preoperative lateral view: Moderate hump, pendant wide tip, moderately thick skin and hanging columella.

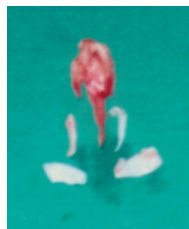


Fig. (3-B): Resected lateral crura, upper lateral cartilages and cartilaginous and bony hump. Note how minimal the resection is.

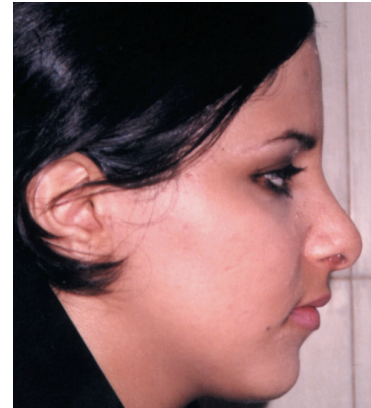

Fig. (3-C): Postoperative lateral view after endonasal long keel cephalic resection of lateral crura, triangular caudal septal cartilage excision including mucosa and hump reduction. The lobule is refined with open nasolabial angle.

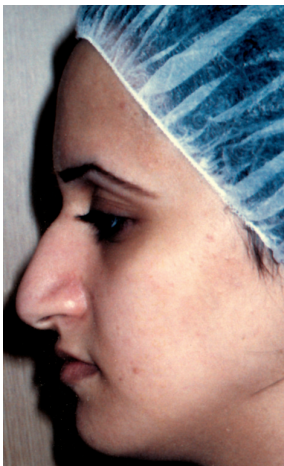


Fig. (4-A): Preoperative lateral view: Large nose with hump and plunging tip.

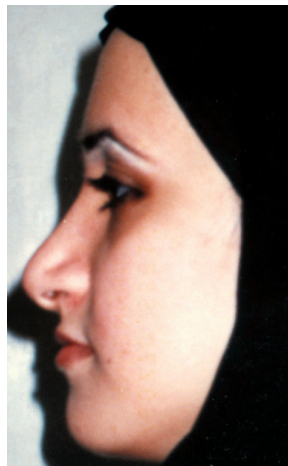

Fig. (4-B): Postoperative lateral view after endonasal rhinoplasty using the same technique with cutting of depressor septi muscle showing gently concave dorsal line, open nasolabial angle and rotation of the tip.

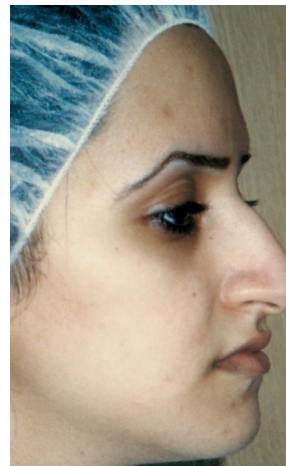

Fig. (4-C): Preoperative oblique view.

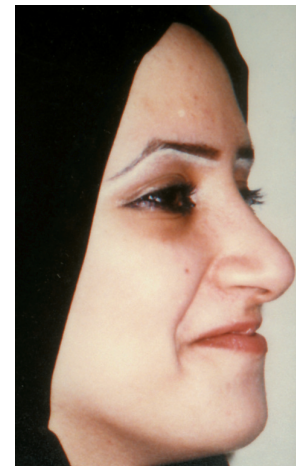

Fig. (4-D): Postoperative oblique view: Plunging tip improved even with smiling.

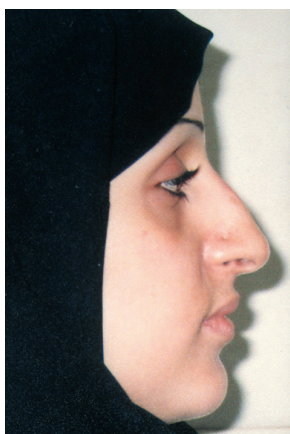

Fig. (5-A): Preoperative lateral view: Large nose with hump, plunging broad tip and hanging columella.

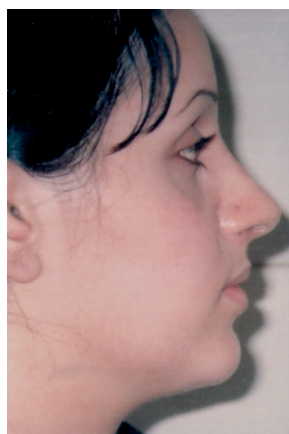

Fig. (5-B): Postoperative lateral view after balanced rhinoplasty using the same technique with minimal trimming of cranial border of medial crura: Refined tip and dorsum, open nasolabial angle, cephalad rotation of the tip and improved columella.

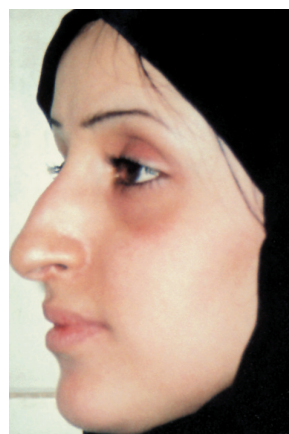

Fig. (5-C): Preoperative oblique view.

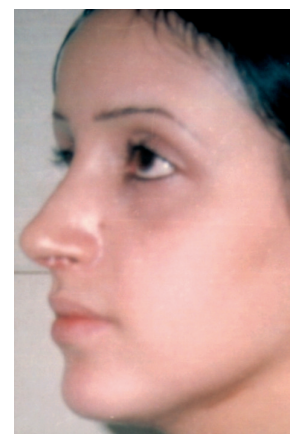

Fig. (5-D): Postoperative oblique view: No turned-in rotation on the long axis of the alar cartilage.

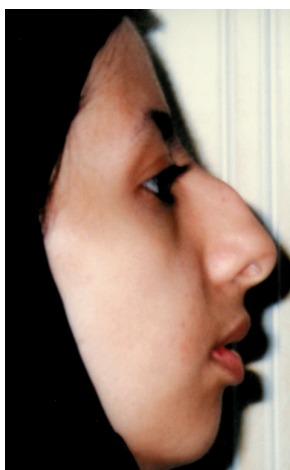

Fig. (6-A): Preoperative lateral view with hump, pendant tip and hanging columella.

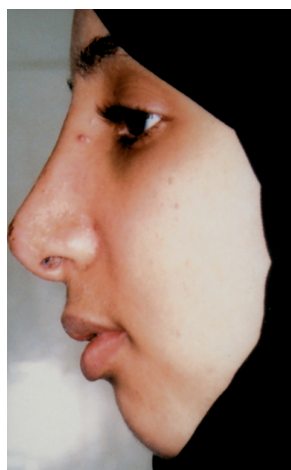

Fig. (6-B): Postoperative lateral view after same technique with trimming of the cranial border of medial crura: Improvement of hanging columella with refined tip and dorsum.

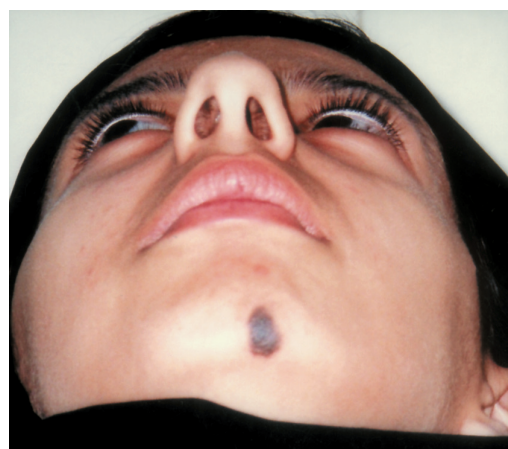


Fig. (6-C): Preoperative basal view with broad tip.

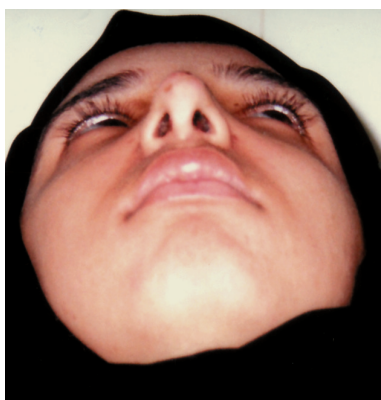


Fig. (6-D): Postoperative basal view with natural tip definition. Chin mole removed.



Fig. (7-A): Preoperative lateral view: Long nose with moderate hump and broad tip.

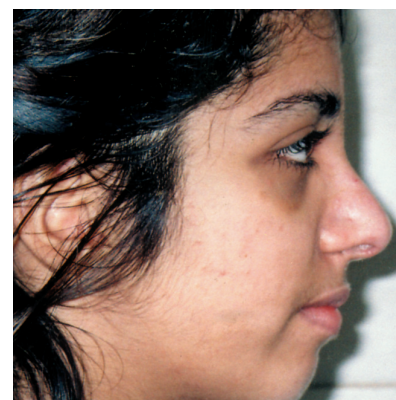

Fig. (7-B): Postoperative lateral view after same technique: Refined tip and dorsum with short nasion-tip distance.

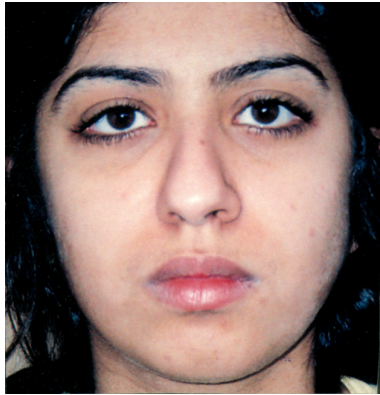

Fig. (7-C): Preoperative frontal view with broad tip and hump.



Fig. (7-D): Postoperative frontal view with refined tip and dorsum.

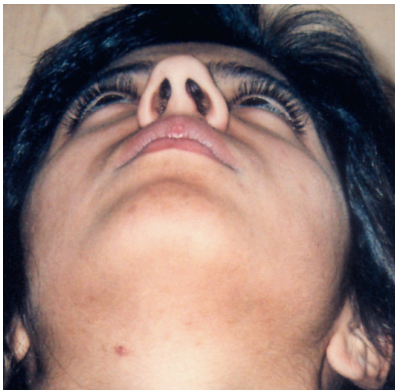

Fig. (7-E): Preoperative basal view with broad tip.

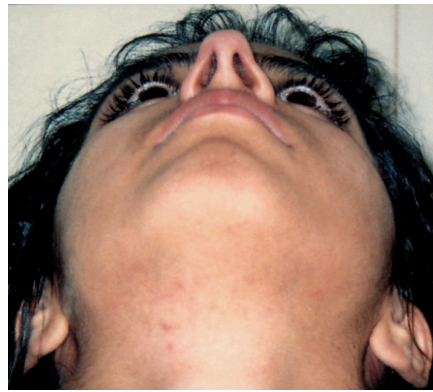

Fig. (7-F): Postoperative basal view with natural tip definition.

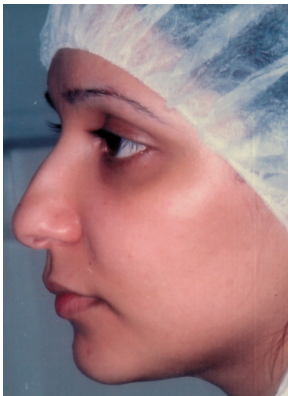

Fig. (8-A): Preoperative oblique view with hump, plunging tip and flared ala nasi.

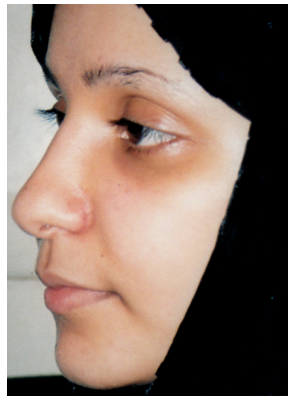

Fig. (8-B): Postoperative oblique view after same technique with release of depressor septi and levator muscles and alar wedge excision: Tip rotation and definition, refined dorsum and preservation of the natural alar curve.

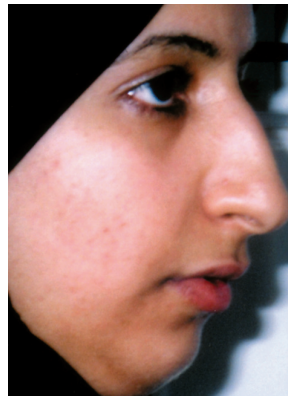


Fig. (9-A): Preoperative oblique view with plunging broad tip, hanging columella and hump.

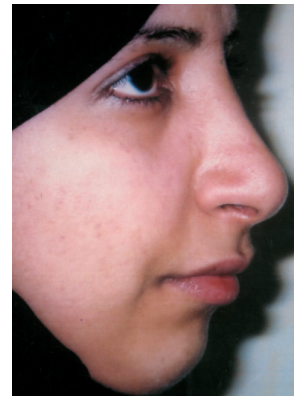

Fig. (9-B): Postoperative oblique view after same technique with trimming of cranial border of medial crura and release of depressor septi muscle: Improved columella, refined tip and dosum with cephalad rotation of the tip and open nasolabial angle.

To correct pendant tip, conservative resection of the caudal border of the septal cartilage is done in away to allow tip rotation but sustain projection at the same time. Shortening of the septal cartilage alone may not appreciably alter the tip. Without removal of the triangular piece of septal lining, desirable shortening or rotation may not be achieved.

When a person speaks or smiles, the levator labii superioris alaeque nasi moves the alar base upward and the depressor septi nasi muscle pulls the tip caudally, both acting simultaneously in opposite directions to rotate the tip caudally and elevate the nasal base. With freeing the medial and lateral portions of the alar arch, cutting the arch laterally at the level of the accessories and resecting muscle insertions, the continuity of the arch is interrupted and the muscle action is eliminated to allow the spontaneous cephalad rotation of the tip, shorten the nasion-tip distance and open the nasolabial angle. A cartilaginous arch with a new shape and position to which the muscular insertions are adapted will modify the functional unity of the lower third of the nose [1,2]. In our patients, we cut the muscle insertions at the tip (mainly) and ala. This maneuver together with cephalic resection of lateral crura and caudal septal excision allows cephalad rotation of the tip and improve plunging tip. Better results are obtained in the nasal profile from both a dynamic and a static point of view. The alar arch is left intact to sustain projection.

The transfixion incision provides a direct approach to true hanging columella through conservative trimming of a crescent of cartilage from the cranial border of the medial crura. This approach to medial crura avoids a noticeable scar from the lower incision used to trim the caudal border of the medial crura, can be achieved with the medial crura in place and hides any irregularities as a result of cartilage trimming [9,10].

During cartilaginous hump removal, more septum is left caudally than cranially to support the tip and sustain projection. The upper border of the septal cartilage, properly shaped, may sustain the alar cartilages without sutures, preventing supratip deformity. Some authors fashioned a small trapezoid at the lower part of the upper border of the septal cartilage to sustain the alar cartilages [11]. No instance of supratip deformity was seen in our cases.

Preservation of the middle vault has become a topic of concern in rhinoplasty [12,13]. Resection of even a minute amount of roof during hump

removal disturbs the stabilizing effect of the upper lateral cartilages, which fall medially toward the anterior septal edge, restricting airflow at the internal valve [14,15]. Use of chisels (beveled on one side only) in the series enables conservative reduction of bony hump as one can better control the direction of cutting. Resection of the bony hump starts with the bevel up and then halfway along the resection, we turn the bevel down. The instrument will slowly come up while proceeding. With this maneuver, there were no saddle noses or overresected dorsum in our results. It is surprising to see how minimal hump reduction is needed to achieve a refined dorsum.

In alar wedge excision, incision in the groove will always show as a scarred alar facial junction with absence of the gentle alar curve above giving a triangle-stuck-on appearance to the base. Incision 1-2mm above alar crease avoids this stigma by leaving a foundation on which the alar curve is recontoured. To help correct plunging tip on smiling the levator muscle in the depth of the incision is cut.

The movement toward minimal procedures should also include the nose [16,17]. Limitations imposed by the endonasal approach are far less than presupposed and the results are better than generally recognized. This approach is simple and can permit us to manage cartilages to refine a wide tip, enhance rotation and sustain projection of the pendant tip without columellar scar, hard struts or violating interdomal ligament. It is reproducible, gives pleasant natural results and reduces complications and secondary operations. For the average primary rhinoplasty, the technique has significantly reduced our use of the open approach. It combines the best features of a balanced rhinoplasty with the minimal wounding afforded by an endonasal approach. The Arabic nose can be managed successfully by combining key maneuvers to address its features and preserve its identity. A natural looking nose, being different from patient to patient, avoids "trademark" results.

REFERENCES

- 1- Arregui J.S., Eejalde M.V., Regalado J., Ezquerria F. and Berrazueta M.: Dynamic rhinoplasty for the plunging nasal tip: Functional unity of the inferior third of the nose. *Plast. Reconstr. Surg.*, 106: 1624, 2000.
- 2- Pessa J.E.: Improving the acute nasolabial angle and medial nasolabial fold by levator alae muscle resection. *Ann. Plast. Surg.*, 29: 23, 1992.
- 3- Papadopoulos A., Harada C. and Papadopoulos A.A.: Biomechanics and classification of the cartilaginous structures to project the nasal tip. *Aesthetic Plast. Surg.*, 24: 106, 2000.

- 4- Constantian M.B.: Differing characteristics in 100 consecutive secondary rhinoplasty patients following closed versus open surgical approaches. *Plast. Reconstr. Surg.*, 109: 2097, 2002.
- 5- Sevin A., Sevin K., Erdogan B., Deren O. and Adanali G.: Open rhinoplasty without transcolumellar incision. *Ann. Plast. Surg.*, 57: 252, 2006.
- 6- Fontana A.M. and Muti E.: Our "idees fixes" in rhinoplasty: The nasofrontal angle and alar lateral crus. *Aesthetic Plast. Surg.*, 25: 1, 2001.
- 7- Cutting C.B.: Cerclage suture method for closed – tip rhinoplasty. *Plast. Reconstr. Surg.*, 104: 1839, 1999.
- 8- Papanastasiou S. and Logan A.: Management of over-projecting nasal tip: A review. *Aesthetic Plast. Surg.*, 24: 353, 2000.
- 9- Gruber R.P.: Trimming the hanging columella. No single technique prevails. *Aesthetic Surg. J.*, 19: 81, 1999.
- 10- Matarasso A., Greer S.E. and Logaker M.T.: The true hanging columella: Simplified diagnosis and treatment using a modified direct approach. *Plast. Reconstr. Surg.*, 106: 469, 2000.
- 11- Campus G.V., Rarace F., Rubino C. and Sana M.P.: A technical refinement to prevent supratip deformity in aesthetic rhinoplasty: The trapezoid peak. *Aesthetic Plast. Surg.*, 31: 88, 2007.
- 12- Daniel R.K.: Rhinoplasty: A simplified, three-stitch, open tip suture technique Part II: Secondary rhinoplasty. *Plast. Reconstr. Surg.*, 103: 1503, 1999.
- 13- Daniel R.K.: Rhinoplasty: Septal saddle nose deformity and composite reconstruction. *Plast. Reconstr. Surg.*, 110: 1029, 2007.
- 14- Sen C. and Iscen D.: Use of the spring graft for prevention of mid vault complications in rhinoplasty. *Plast. Reconstr. Surg.*, 119: 332, 2007.
- 15- Fischer H. and Gubisch W.: Nasal valves-importance and surgical procedures. *Facial Plast. Surg.*, 22: 266, 2006.
- 16- Adamson P.A. and Galli S.K.: Rhinoplasty approaches: Current state of the art. *Arch. Facial Plast. Surg.*, 7: 32, 2005.
- 17- Bruschi S., Bocchiotti M.A., Verga M., Kefalas N. and Fracalvieri M.: Closed rhinoplasty with marginal incision; Our experience and results. *Aesthetic Plast. Surg.*, 30: 155, 2006.