

## Reconstruction of Hand and Forearm Defects by Abdominal Thin Skin Flaps

AHMED ALI, M.D.; MAHAMMED FARAG, M.D. and KHALID SAFE, M.D.

*The Department of Plastic Surgery, Faculty of Medicine, Ain Shams University.*

### ABSTRACT

Posttraumatic hand and forearm defects always represent a challenging problem in reconstructive surgery. Different reconstructive methods have been used to treat these defects considering the functional and cosmetic aspects. Local flaps were used to reconstruct the hand and forearm at the expense of donor site morbidity. Reconstruction by free flaps was also used; however, they are bulky and necessitate revision surgery. Pedicled abdominal flap was one of the initial methods of reconstruction for hand and forearm defects. Two-stage transfer, bulkiness of the flap that usually needs defatting at further stage, and donor site morbidity are the pitfalls of the flap. In this study, 30 patients had 23 posttraumatic hand defects and 7 forearm defects were reconstructed by abdominal ultra thin skin flap. The flaps were elevated ultra-thin, keeping a very thin layer of fat that ensures the existence of the subdermal plexus. Length-width flap dimension was in the average of 7X3cm. Twenty seven flaps completely survived. Two flaps had distal necrosis that healed conservatively. One flap had wound infection and dehiscence. It could be an ideal choice for the repair of hand and forearm defects with abdominal ultra-thin skin flaps.

### INTRODUCTION

The reconstruction of skin defects of the hand and forearm aims at restoring their function with a good aesthetic appearance. Several surgical techniques using local flaps have been developed to resurface hand and forearm defects. The dorsal aspect of forearm offers the dorsal interosseous artery flap to reconstruct the skin defect on the dorsum of the hand [1]. The Chinese radial forearm flap provides effective one-stage coverage of defects on the dorsum of the hand [2,3]. Abdominal flap is a simple, easy, and versatile distant flap that took a great place in the beginning era of reconstructive surgery [4]. Free flaps are single-stage procedure with a marked flexibility in size, shape, and positioning [5,6].

Several years ago, there was a declining in the use of abdominal flap in the reconstruction of soft tissue defects on the dorsum of the hand and fore-

arm due marked bulkiness of the flap that was frequently subjected to secondary debulking [7,8]. Ideally, a flap is elevated along a tissue plane. If the donor skin is thin, it will be easy to transfer and will be thin at its final place. However, if the skin of the donor site is not thin, then the choice lies between raising a fat flap with subsequent thinning or transferring skin as a flap-graft principle [9].

It is well accepted that a skin flap is usually dependant on a subdermal circulation. Colson and Coworkers [10], studied the use of defatted flaps for the coverage of hand defects. They stated that if the subdermal plexus is undamaged, the flap should have an adequate blood supply. In this study, pedicle ultra-thin abdominal flap is used in the reconstruction of soft tissue defects of the hand and forearm in an attempt to avoid the bulky abdominal flap, providing a thin flap that match the skin of the hand and forearm, and minimizing the donor site morbidity of abdominal flap.

### PATIENTS AND METHODS

#### *Patients:*

The study included thirty patients. Twenty-three patients had hand defects and seven patients had forearm defects. Hand defects were in the form of postburn scar contracture (15 hand defects) and posttraumatic injury (8 defects). Forearm defects were in the form of crush wounds of the forearm (7 defects) (Table 1). Twenty-six patients were males while four patients were females. The age of the patients ranged from 17 to 46-year old with an average of 23-year. The study was conducted in the department of plastic surgery Ain Shams University from May, 2004 till August, 2006 with an average follow-up period of 16 months. The size of defects was ranged from a minimum of 5x8 and a maximum of 9x16 centimeters.

Table (1): The type and number of defects in the hand and forearm.

Defect	Number
Postburn scar of dorsum of hand	15
Crush hand injury	8
Crush wound of forearm	5
Electric injury of forearm	2

**Methods:**

All patients were operated upon by general anesthesia. In cases of postburn scarring of the hand, excision of scar tissue was done. In cases of posttraumatic skin loss of the hand and forearm, the wounds were debrided. Measurement the dimension of the defects was taken. Random pattern ultra thin abdominal skin flap was raised at the level of subdermis. A very thin layer of subcutaneous fat underneath the flap was kept. In-setting of

the flap with silk sutures was performed. With Elastoplast and bandage, the limb was kept in a position that does not make tension on the flap. The pedicled-flap was dressed after one-week postoperatively.

All the flaps were divided after 15 days. The first inseting sutures were removed and new sutures were taken at the site of divided flap.

**RESULTS**

Thirty soft tissue defects in the hand and forearm were reconstructed by ultra thin abdominal flap. All flaps had complete survival at the time of division. One flap had distal necrosis involving two centimeters that needed debridement and re-suture to the edge of the defect. One flap had disruption that needed secondary sutures. All flaps gave a satisfactory coverage with excellent contouring (Figs. 1,2,3).

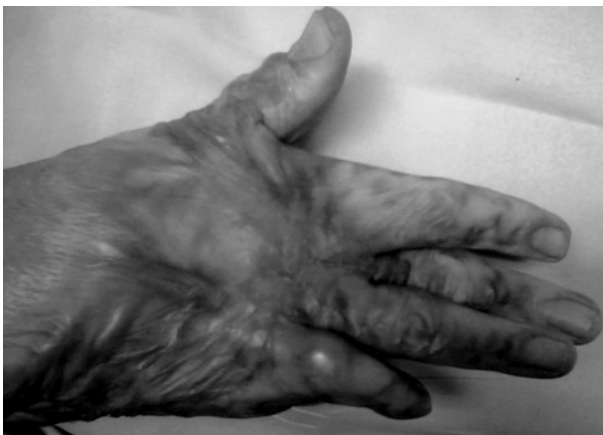

Fig. (1-A): Postburn scarring and contracture deformity of the right hand with flexion deformity of the little finger.

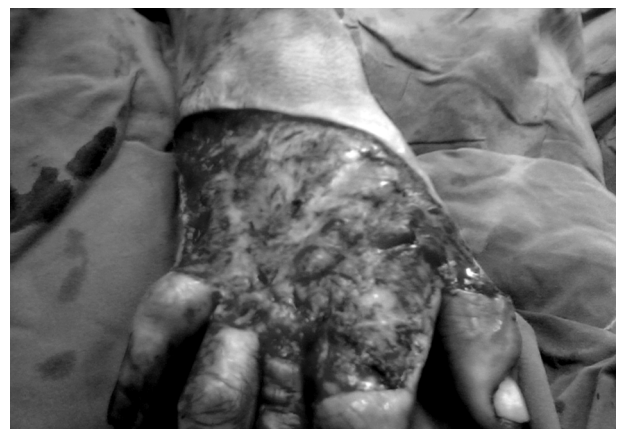

Fig. (1-B): Excision of the burn scar and release of the contracture.

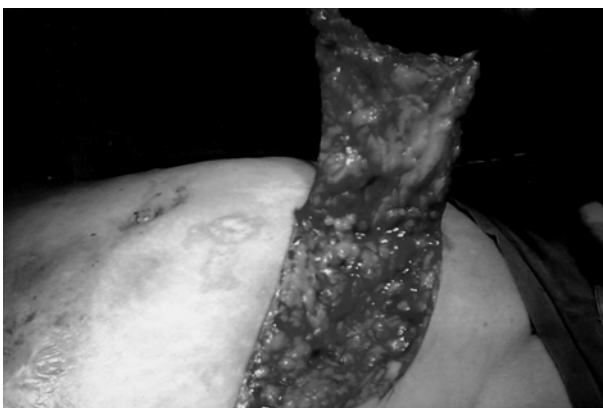


Fig. (1-C): Elevation of ultra-thin abdominal flap. Flap dimension was 10x17cm.

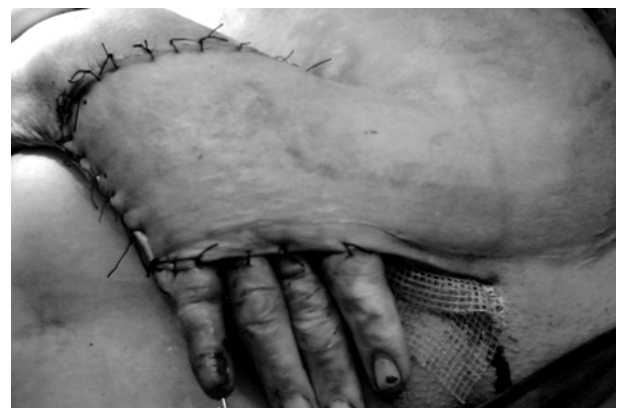

Fig. (1-D): Coverage of the hand by the abdominal flap and fixation of the little finger in extension by K-wire.

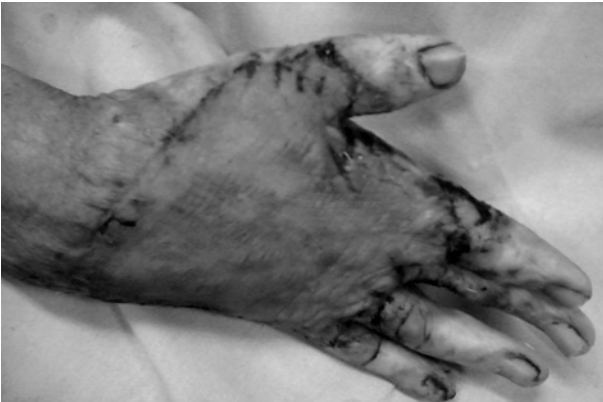

Fig. (1-E): Postoperative view of the hand after division of the abdominal flap.

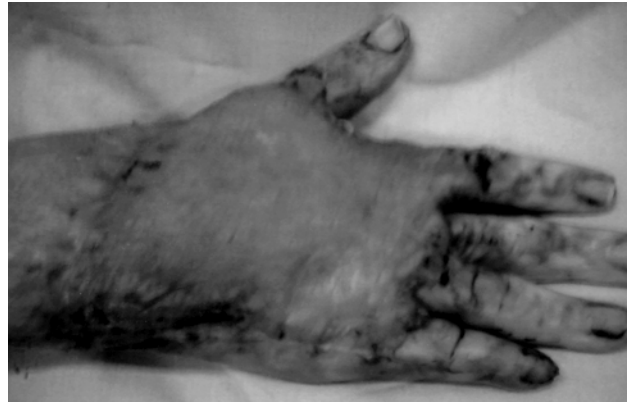

Fig. (1-F): The flap is thin and completely survived.

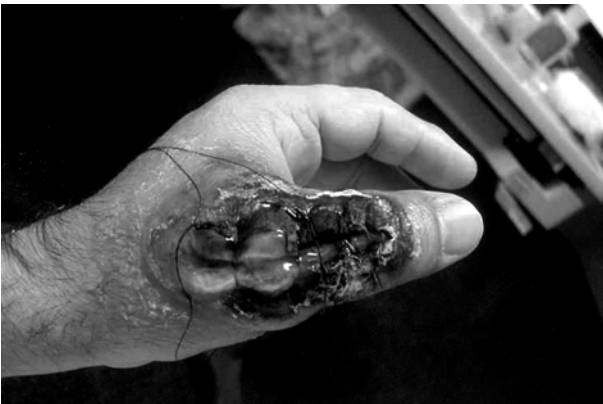

Fig. (2-A): Posttraumatic soft tissue defect on the dorsum of lift thumb.

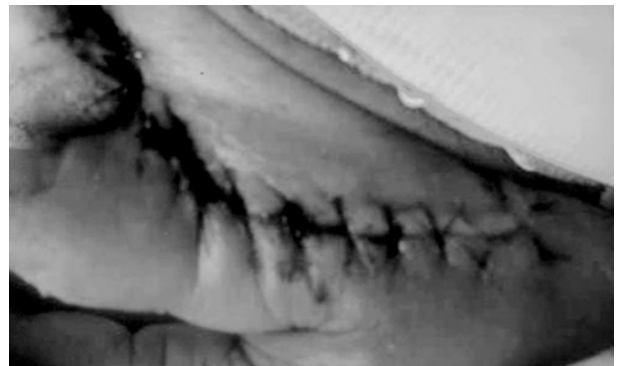

Fig. (2-B): Coverage of the defect by ultra-thin abdominal flap.

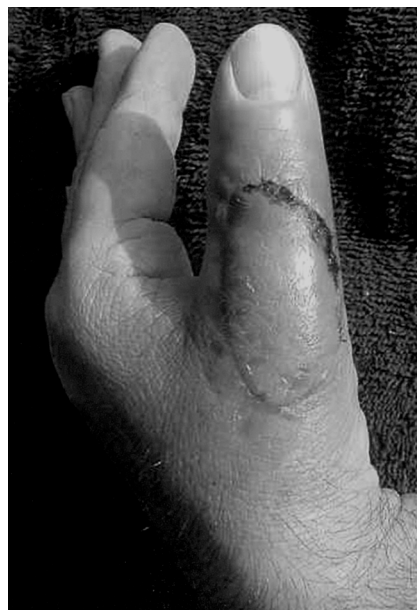

Fig. (2-C): The flap completely survived. The flap is not bulky and has a good contour.

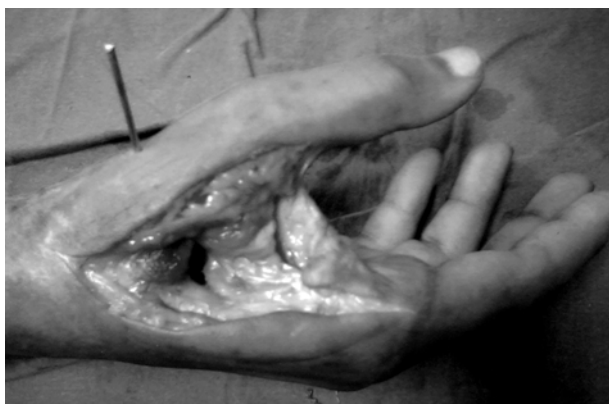

Fig. (3-A): 23-year old patient with a soft tissue defect after release of contracted first web space.

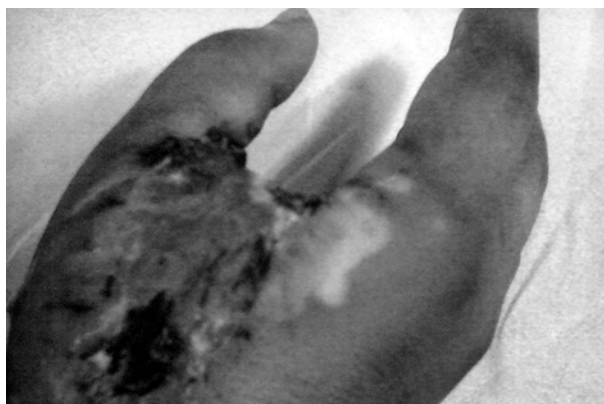

Fig. (3-B): Reconstruction of the first web space by ultra-thin abdominal flap. The flap completely survived with good contour and not bulky.

## DISCUSSION

Soft tissue reconstruction of the hand and forearm remains a challenge for plastic and reconstructive surgeons. Dorsal skin defects on the dorsum of the hand as well as defects of the forearm may be covered by local, distant, or free flaps, depending on the general condition of the patient and the local condition of the wound and donor site. Several surgical techniques use local flaps to resurface dorsal skin defects of the hand. One group of local flaps is distally based that are raised from the volar aspect of the forearm. The axial pattern reverse radial forearm flap [11] provides a good amount of tissue coverage, and one of the primary flaps used for the reconstruction of soft tissue defects of the hand. The advantages of this flap are that it is safe, simple, and effective one-stage procedure providing thin, pliable, relatively hairless, good quality skin with a robust blood supply. The main disadvantages of this flap are sacrifice of a major artery, which may jeopardize hand viability, and the morbidity of the donor site. The axial pattern reverse fascial forearm flap procedure [12,13] includes the fascial forearm flap and split-thickness skin graft for coverage of the hand. Although this procedure minimized the donor site morbidity, it also involves sacrificing a major artery. The distally based radial forearm fasciocutaneous flap with preservation of the radial artery [14] is based on the septocutaneous perforators of the distal radial artery. This method substantially avoids the two main drawbacks of the reverse radial forearm flap, however, it has the donor site morbidity.

The other group of local flaps involves distally based flaps raised from the dorsal aspect of the forearm. The posterior interosseous artery flap [15] is suitable for coverage of dorsal skin defects of

the hand and avoids interference with the two main arteries of the forearm. However, the dissection of the vascular pedicle is frequently quite complex and tedious beside the donor site morbidity at the dorsum of the forearm.

Free flaps are alternative option to reconstruct soft tissue defects of the hand and forearm. Free flaps offer flexibility in size, shape, and positioning and do not add donor site morbidity to the injured hand. Free flap coverage is a time-consuming procedure, requires a more difficult technique and complicated postoperative care [16].

Back to abdominal flap for the reconstruction of soft tissue defects on the dorsum of the hand and forearm as a distant flap that had a role for long time in the past. Random pattern abdominal flap was frequently used to cover traumatic defects involving the hand. However, bulkiness of the flap and two-stage procedure was the main disadvantages of abdominal flap. In particular, bulkiness of the flap is bothersome to the patient and is frequently subjected to debulking surgery. In this work, abdominal thin skin flaps were raised and reconstructed (thirty soft tissue defects on the dorsum of the hand and forearm). with a maximum of 9x16cm flap dimension, all flaps have survived. Furthermore, the flaps were thin that did not require revision. Lin and his colleagues used the pedicled skin flaps of subdermal vascular plexus for reconstruction of hand defects [17]. They achieved complete survival in all the flaps used to reconstruct 22 hand defects.

Ultra thin abdominal flap is safe, easy to harvest, gives a good skin that match the quality of skin of the dorsum of the hand and forearm, has no donor site morbidity of local flaps based on the forearm, and does not need a debulking surgery.

## REFERENCES

- 1- Costa H. and Soutar D.S.: The distally based posterior interosseous flap. *Br. J. Plast. Surg.*, 41: 221, 1988.
- 2- Timomons M.J., Missotten F.E., Poole M.D. and Davies D.M.: Complications of radial forearm flap donor sites. *Br. J. Plast. Surg.*, 39: 176, 1986.
- 3- Landi A., Luchetti R., Soragni O., De Santis G. and Sacchetti G.L.: The distally based posterior interosseous island flap for the coverage of skin loss of the hand. *Ann. Plast. Surg.*, 27: 527, 1991.
- 4- Yilmaz S., Saydam M., Seven E. and Ercocen A.R.: Paraumbilical perforator-based pedicled abdominal flap for extensive soft-tissue deficiencies of the forearm and hand. *Ann. Plast. Surg.*, 54: 565, 2005.
- 5- Chen H.C., Tang Y.B., Mardini S. and Tsai B.W.: Reconstruction of the hand and upper limb with free flaps based on musculocutaneous perforators. *Microsurgery*, 24: 270, 2004.
- 6- Flügel A., Kehrer A., Heitmann C. and Germann G.: Sauerbier M Coverage of soft-tissue defects of the hand with free fascial flaps. *Microsurgery*, 25: 47, 2005.
- 7- Barillo D.J., Arabitg R., Cancio L.C. and Goodwin C.W.: Distant pedicle flaps for soft tissue coverage of severely burned hands: An old idea revisited. *Burns*, 27: 613, 2001.
- 8- OlaOlorun D.A.: Abdominal fasciocutaneous flap for upper extremity wound coverage in the developing world: Indications and complications. *Trop. Doct.*, 31: 45, 2001.
- 9- Forli A., Voulliaume D., Comparin J.P., Papalia I. and Foyatier J.L.: The abdominal flap-graft for coverage of soft tissue defects of the dorsum of hand and fingers in burn patients. Six cases reports. *Ann. Chir. Plast. Esthet.*, 50: 146-53, 2005.
- 10- Thomas C.V.: Thin flaps. *Plast. Reconstr. Surg.*, 65: 747-752, 1980.
- 11- Reid C.D. and Moss L.H.: One stage repair with vascularised tendon grafts in a dorsal hand injury using the "Chinese" forearm flap. *Br. J. Plast. Surg.*, 36: 473, 1983.
- 12- Soutar D.S. and Tanner N.S.B.: The radial forearm flap in the management of soft tissue injuries of the hand. *Br. J. Plast. Surg.*, 37: 18, 1984.
- 13- Jin Y., Guan W., Shi T., Quian Y., Xu L. and Chang T.: Reverse island forearm fascial flap in hand surgery. *Ann. Plast. Surg.*, 15: 340, 1985.
- 14- Weinzweig N., Chen L. and Chen Z.: The distally based radial forearm fasciocutaneous flap with preservation of the radial artery: An anatomic and clinical approach. *Plast. Reconstr. Surg.*, 94: 675, 1994.
- 15- Buchlar U. and Frey H.: Retrograde posterior interosseous flap. *J. Hand Surg. Am.*, 16: 283, 1991.
- 16- Zhou L.R., Li J. and Wang W.: Microsurgical repair of skin-degloving injury of whole hand or foot. *Zhongguo Xiu Fu Chong Jian Wai Ke Za Zhi*, 17: 321, 2003.
- 17- Lin W., Zheng T. and Wang Q.: Study on the effect of pedicle skin flap of subdermal vascular plexus on repairing the hand injury. *Zhongguo Xiu Fu Chong Jian Wai Ke Za Zhi*, 19 (7): 528, 2005.